

Clinical spectrum, diagnosis, and sexual dysfunction after repair of fracture penis: Is no news good news?

Aditya Prakash Sharma*, Tushar Aditya Narain, Sudheer Kumar Devana, Shantanu Tyagi, Kalpesh M. Parmar, Girdhar Singh Bora, Ravimohan S. Mavuduru, Shrawan Kumar Singh

Department of Urology, PGIMER, Chandigarh, India

*E-mail: aditya.p.sharma@gmail.com

ABSTRACT

Introduction: Penile fracture is a rare urological emergency, best managed by early surgical intervention, but the data on subsequent sexual function is sparse. This study was designed to analyze the clinical spectrum and sexual function after penile fracture repair at our tertiary care center.

Materials and Methods: Ambispective observational study was undertaken from July 2002 to August 2019 which included patients admitted with a history of trauma to the penis in the erect state. The clinical presentation, etiology and the details of the surgical management were noted. Patients were contacted telephonically and were called for follow-up. They were evaluated for the presence of penile nodules or curvature, and the erectile function was objectively recorded using the Sexual Health Inventory for Men (SHIM) questionnaire and the Erection Hardness Score (EHS).


Results: Median age at injury was 37 years, and injury during the sexual intercourse (33/43) was the most common etiology. Five patients presented with blood at the meatus. Ultrasound was performed in 27 patients and could detect the injury with a 55% sensitivity. All but one case were repaired through a subcoronal degloving incision. At a median follow-up of 36 months, follow-up data of 20 patients were available. Of the 20 patients, 14 were sexually active. The mean SHIM score was 21.36 ± 1.33 and the mean EHS was 3.21 ± 0.43 . Four of the 20 patients developed penile nodule while 2 of them had penile curvature which was not bothersome.

Conclusion: Penile fracture remains primarily a clinical diagnosis. Although prompt diagnosis and an emergent surgical exploration provides good outcomes in terms of preservation of erectile function, patients should be apprised about the problems of penile nodule and curvature.

INTRODUCTION

Penile fracture, although a misnomer, refers to the disruption of tunica albuginea with rupture of the corpora cavernosa of the penis, usually in an erect state, resulting in sudden detumescence. The reported incidence of this entity is 1 in 175,000.^[1] The fracture penis most commonly results from injury during the sexual intercourse or masturbation and from rolling over the erect penis on the bed and from falling onto the erect penis.^[1,2] All these result in an

abnormal bending of the erect penis. Patients may present late due to fear and embarrassment and this delay may result in long-term cosmetic and functional impairment. Fracture penis is one of the few urological emergencies, managed best by early surgical intervention. The data on the use of imaging, subsequent erectile function, and the development of penile plaque are sparse. We report the clinical presentation, etiology, surgical management, and sexual function in patients with penile fracture presenting to our tertiary care center. We also provide a brief review on the available literature describing postoperative erectile

Access this article online	
Quick Response Code:	Website: www.indianjurol.com
	DOI: 10.4103/iju.IJU_333_19

This is an open access journal, and articles are distributed under the terms of the Creative Commons Attribution-NonCommercial-ShareAlike 4.0 License, which allows others to remix, tweak, and build upon the work non-commercially, as long as appropriate credit is given and the new creations are licensed under the identical terms.

For reprints contact: reprints@medknow.com

Received: 27.11.2019, **Revised:** 16.02.2020

Accepted: 23.02.2020, **Published:** 07.04.2020

Financial support and sponsorship: Nil.

Conflicts of interest: There are no conflicts of interest.

function, and complications such as penile nodule, and penile curvature in these patients.

MATERIALS AND METHODS

This is an ambispective observational study extending from July 2002 to August 2019, which included all the patients admitted with the diagnosis of fracture penis. The institute ethics committee approved the study (NK/5021/study/99). Retrospective data were retrieved from the medical records department. The demographic profile, mode of injury, clinical presentation, and the imaging findings were recorded. The intraoperative findings and the method of repair were scrutinized. Patients were contacted telephonically and were asked to visit the outpatient department for clinical evaluation and evaluation of their sexual health. On the follow-up visits, they were clinically evaluated for sexual health and the erectile function was objectively recorded using the Sexual Health Inventory for Men (SHIM) questionnaire, (also known as the International Index of Erectile Function [IIEF]-5). The erectile dysfunction (ED) severity was classified as: none (22–25), mild (17–21), mild-to-moderate (12–16), moderate (8–11), and severe (5–7). Concomitantly, Erection Hardness Score (EHS) was used to stratify the quality of erections after the repair. The patients were also asked about any complications and were examined to identify nodules/plaque or curvature. Statistical analysis was performed using Microsoft excel 2010 and IBM SPSS Statistics for Windows, Version 22.0 (IBM Corp., Armonk, NY, USA). Descriptive statistics were applied and values were presented as mean (standard deviation) and median (range).

RESULTS

During the study, 62 cases of suspected penile fracture received treatment at our institute. The complete details of 45 patients were available for analysis. Two patients did not have fracture at surgical exploration (Pseudo penile fracture) and were excluded. Hence, a total of 43 patients were considered for the final analysis. Each patient underwent a thorough clinical evaluation and received urgent surgical intervention, except the two who refused surgery. The diagnosis was based on clinical grounds after thorough history and physical examination. Ultrasonography (USG) was performed in 26 patients and retrograde urethrogram (RGU) was performed in five cases with suspected urethral injury [Table 1]. In addition, a magnetic resonance imaging (MRI) was performed in two cases who had delayed presentation (100 h and 504 h) after the injury [Figure 1] and the USG was inconclusive. Immediate surgical exploration was carried out in 41/43 cases.

Median age at presentation was 37 (range 23–72) years, and injury during the sexual intercourse (33/43) was the most common etiology (76.7%). Seven (16.3%) patients had the penile fracture from accidental injury, while 3 (7.0%)

Table 1: Relevant details of imaging modality used and data compared to that at surgical exploration

Modality	n (%)	Compared to surgically explored (n=43), n (%)
Ultrasound performed	27/43	
Defect seen	15/27 (55.5)	41/43 (95.3)
Average defect size (mm)	6.5	15
Retrograde urethrogram performed	5/43	
Contrast extravasation/urethral injury seen	4/5	4 (100)
MRI performed	2/43	
Defect size (mm)	7.2 and 6.0	10 and 8

MRI=Magnetic resonance imaging

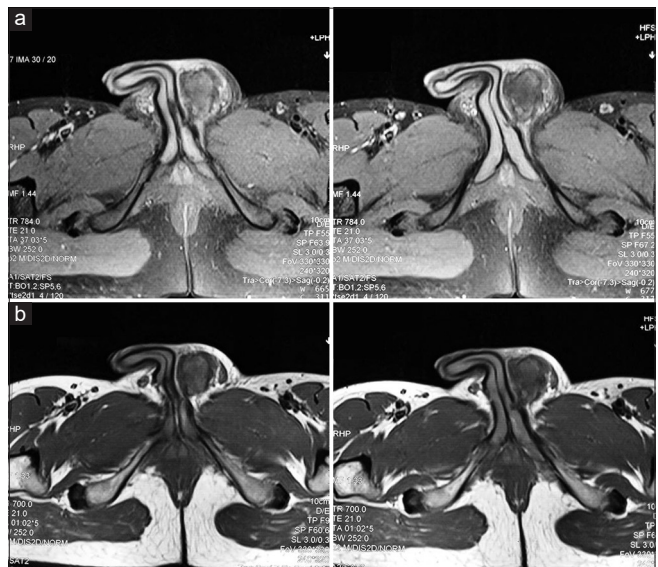

Figure 1: Magnetic resonance imaging images of a patient presenting 3 weeks after fall over an erect penis 1a: Non contrast T2 fat saturated and 1b: T1W image showing heterogeneous hyperintensity suggestive of hematoma. The defect in the left corpora is also seen

sustained the injury during masturbation. Six accidental injuries were due to rolling over the erect penis during morning tumescence. One patient was riding a motorcycle when he met with an accident and the semi-erect penis hit the handle of the motorcycle. The interval from injury to presentation ranged from 12 to 504 h. However, the majority (31/43) of the patients presented within 24 h of injury. Seventy percent (30/43) of the patients presented with an eggplant deformity [Figure 2] with diffuse ecchymosis of the penis, while 30% of the patients presented with a localized hematoma. Thirty-three (76.7%) patients reported a pop sound and a sudden detumescence of the erect penis followed by a localized hematoma or the classical egg-plant deformity. Ultrasound was performed in 27 patients and in 15/27 (55.5%) was able to delineate the tunical defect [Table 1]. The defect size was reported in 13 patients, and the mean size of the defect was 6.5 mm. Patients were explored in an emergency setting under

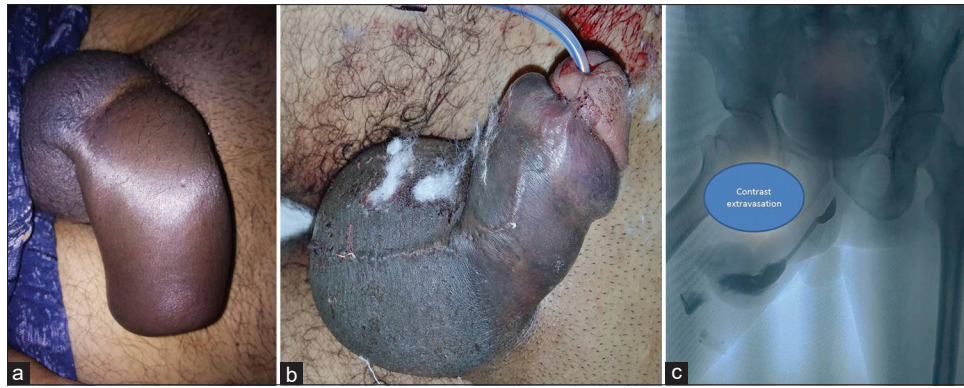

Figure 2: Fracture of penis with swelling and discoloration (aubergine sign/eggplant deformity). (a) Not associated with urethral injury. (b)- Associated with urethral injury. Patient presented with a history of blood at the meatus. Retrograde urethrogram did not show injury and the catheter was placed gently over a guidewire. (c)- Retrograde urethrogram in a patient with fracture penis showing contrast extravasation

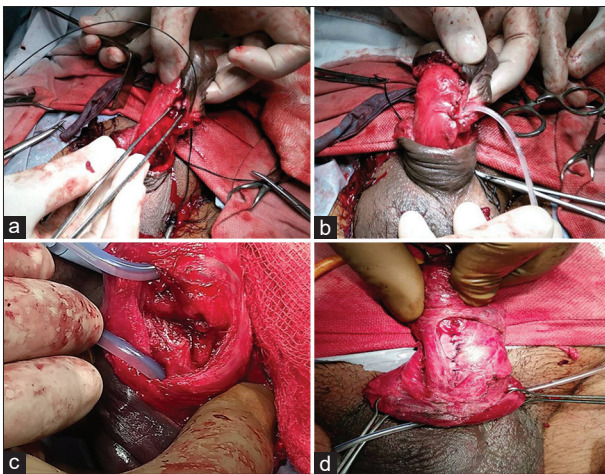


Figure 3: (a) Penile fracture with hypospadias and submeatal narrowing. Note the defect is distally located near the meatus. (b) Repaired fracture penis and guidewire in the urethra. (c) Fracture penis associated with transection of pendular urethra. (d) Exposure of defect through a circumpenile degloving skin incision and repair using 3–0 prolene inverted sutures

either general or regional anesthesia. The median size of the defect was 1.5 cm (interquartile range = 1–1.5). Thirty-seven patients (82.2%) had the injury on the ventrolateral aspect of the cavernosa while 4 patients had a tear on the dorsal aspect. Five patients had presented with blood at the meatus and an associated urethral injury was suspected [Figure 2b]. A RGU was performed in all the 5 patients which confirmed and localized the site of injury in 4 cases [Figure 2c]. One of the patients had distal penile hypospadias and submeatal narrowing, in him the defect was distal to the conventional site of the penile fracture [Figure 3]. All cases were repaired through a subcoronal degloving incision, except one, which was explored through a lateral penile incision. One of the patients had complete transection of the urethra and an end-to-end repair was performed [Figure 3c]. The tunical defects were repaired with 3–0 prolene sutures (90%) or 3–0 vicryl sutures (10%) [Figure 3d]. Prolene was used in inverted fashion so as to bury the knots inside. Urethral injury repair was performed using 4–0 vicryl in 4 cases.

At a median follow-up of 36 months, 20 patients agreed for the clinic visit. Out of 20 patients, 14 patients were sexually active and 6 were inactive. The reasons for sexual inactivity were as follows: Three patients had no active sexual partner, two stated lack of desire (age 59 and 62 years), and one patient complained of ED and cited it as the cause for sexual inactivity. Average time to return to sexual activity was 4.6 months. The mean SHIM score was 21.36 ± 1.33 and the average EHS was 3.21 ± 0.43 . Eight patients had mild ED (SHIM-17-21) and 6 patients had no ED. Eleven patients had the EHS of 3 and 3 patients had the EHS of 4. Two patients complained of penile curvature on erection which was $<20^\circ$ (measured using a clinometer in erect penis after the administration of tadalafil 10 mg along with visual stimuli) and did not affect penetration during sexual intercourse. On examination, 4 out of 20 patients were found to have penile nodules which were small measuring 5–6 mm and felt like suture granulomas. None of the patients had Peyronie's plaque or had difficulty during intercourse due to the nodules.

DISCUSSION

Abu al-Qasim al-Zahrawi, an Arab physician, was the first to document a case of penile fracture more than 1000 years ago.^[1,2] Malis and Zur in 1924 described the first case of fracture penis noted in the modern medical literature.^[3] Penile fracture, once a rare urological emergency, has lately become a frequent presentation in the emergency room and involves the rupture of tunica albuginea and the underlying corpora cavernosa of an erect penis due to an external bending force. In our study, we found 23 cases between 2002 and 2010 and 37 fractures from 2011 to 2019. This differential rise can be attributed to the rise in population, more so a younger population of our country. Tunica albuginea thins out (0.25–0.5 mm, as compared to a resting thickness of 2 mm) during erection and ruptures due to a marked short-term increase in intra-cavernosal pressure which approaches or exceeds the tensile strength of the tunica.^[4] Fracture penis is usually caused by abrupt bending of the erect penis due to trauma. The most commonly encountered

causes include sexual intercourse, masturbation, and rolling over in the bed over the erect penis.^[1,5]

The meta-analysis by Amer *et al.* found sexual intercourse as cause of fracture penis in 46% of the patients followed by forced flexion (21%) and masturbation (18%) in a pooled data of over 3000 patients.^[1] The etiology of trauma has been differently reported from various regions. Trauma sustained during sexual intercourse is reported as the main cause of penile injury in America; manipulating the erect penis (a practice known as “taghaandan”) to achieve detumescence is reported as a major cause in the Middle East,^[5,6] whereas rolling over an erect penis in bed and masturbation are the most common causes in Japan.^[7] In our series also, the most common cause was injury during sexual intercourse (76.7%) with the erect penis hitting the perineum or the pubic bone, while 16.3% of patients had an accidental injury to the erect penis, most commonly due to rolling over in sleep. One interesting presentation in our series was the patient masturbating by rubbing the penis at the edge when the penis hit the bed and sustained the fracture. Another was that of a young man riding a motorcycle and accidentally hitting his penis on the handle of the motorcycle. In our study, most (35/43) of the patients presented at night or in the early morning corresponding to the prevalent timing of sexual intercourse. Mahapatra *et al.* have attributed this timing of fracture to the circadian rhythm of testosterone which may or may not be the case.^[8] The diagnosis is usually made by a thorough clinical history and a good clinical evaluation. Thirty-three (76.7%) patients reported a pop sound and a sudden detumescence. Seventy percent of the patients in our series presented with an eggplant deformity with diffuse ecchymosis of the penis while 30% of the patients presented with a localized hematoma.

USG of the penis is the most commonly performed investigation and it can reveal the defect in tunica albuginea if performed by an experienced radiologist. In our series, the USG had a sensitivity of 55.5%. The mean defect size detected on USG was 6.5 mm which was much smaller than the actual size of the defect on surgical exploration (median 1.5 cm). This might have resulted as the hematoma and subcutaneous edema obscured the defect. In an earlier published series from our center, we have reported that the diagnosis of penile fracture remains predominantly clinical and the reported sensitivity of the USG was 50%. The same holds true till date as the sensitivity of clinical history and examination remains high (100% in our series). Only two patients had negative explorations based on the clinical examination (false positives). We have noticed an increase in the utilization of ultrasound in our setup in the last decade, which has now become a routine, as compared to that prior to 2010. USG is primarily being used as a tool to prevent medicolegal hassles. Another probable reason for obtaining an USG as a routine is to avoid unnecessary surgery and its consequences. However, based on these data, we do not advocate use of USG as a method

of preoperative diagnosis as it may miss almost 45%–50% of the cases. A penile Doppler may be helpful in picking up the diagnosis of thrombosis of dorsal vein and vessel injury, however a normal penile Doppler does not rule out penile fracture. This poor sensitivity can result from various reasons: cursory examination in a busy emergency setup as ours, obscuring of the defect by the hematoma and at times being performed by an ultrasonologist with limited experience. MRI was performed in two cases which showed the defect size closer to the size seen on surgical exploration. MRI was only performed in patients presenting late (100 h and 504 h) and can delineate the defect definitely thus helping in decision-making. The European Association of Urology (EAU) Guidelines state that MRI is superior to USG in determining the defect size and location. However, the cost and availability restricts its use in routine practice.

The defect in tunica is usually transverse and 1–2 cm in length.^[9] Fracture is usually unilateral, although tears in both the corporeal bodies occur in 10% of the injuries.^[10] Bilateral corporeal injuries are more commonly associated with urethral injury.^[11] Most of the penile fractures are located distal to the suspensory ligament, and majority of the coital injuries are located ventrolaterally,^[12] where the tunica albuginea is the thinnest.^[13] In our series, ventrolateral corpora was injured in 37 patients, while in 4, the tear was present on the dorsolateral side. The right corpora was involved in 20 patients while it was the left in 21 patients. None of the patients had simultaneous tears in both the corpora.

In the meta-analysis by Amer *et al.*, it has been reported that an associated urethral injury should be suspected in patients with gross hematuria, microscopic hematuria or who are unable to micturate.^[1] The meta-analysis reported the incidence of urethral injury with penile fracture at 6.1%. In our study, the urethral injury was suspected in 5 patients (11.6%) who presented with blood at the meatus and all underwent RGU. In one patient there was no contrast extravasation and was managed conservatively with catheter. Intraoperatively, also full-thickness urethral injury was not found. The probable reason for the blood at meatus could be a contusion injury to the urethra. In the other four patients, the site of urethral injury was visible on the RGU. Intraoperatively, it was found to be located adjacent to the fracture site concordant with the RGU findings and were repaired using 4–0 vicryl at the time of fracture repair. We placed a per urethral catheter in all these cases. Derouiche *et al.* have reported the use of suprapubic catheter in patients with urethral injury.^[14] However, we found the use of a urethral catheter of benefit in both splinting the urethral repair and simultaneously draining the bladder. None of the patients with urethral injury developed urethral stricture on follow-up.

The treatment of penile fracture has undergone a paradigm shift over the decades with earlier reports recommending conservative management with bed rest, pressure dressings,

use of ice packs and prolonged catheterization along with antibiotics, fibrinolytics, estrogens, and diazepam for suppressing the erections.^[15] Such treatments, though in vogue for a long time, often had disastrous results. Such a conservative treatment may result in erectile dysfunction, penile deformities, and consequential suboptimal coitus in 10%–30% of the patients.^[5] The review by Kalash and Young and Hinev *et al.* recommended immediate surgical repair of all the cases of penile fracture as this provides a chance for complete recovery, even in the presence of a concomitant urethral injury.^[16,17] Emergent repair was undertaken in all but two cases in our series, which is now considered the best method for managing the fracture penis.^[16]

The incision used for repair of the fracture is variable and is surgeon dependent. Distal circumcoronal degloving incision is the most commonly used incision, although occasionally a small lateral incision may be useful for small palpable defects.^[18–22] The degloving incision allows for exposure of both the corporal bodies and the spongiosum for ready diagnosis and management of the concomitant urethral injuries. At the same time, it preserves the cosmesis of the penile skin. We operated 40 patients with a circumcoronal degloving incision and 1 patient with the peripenile lateral incision. Ours is a tertiary care teaching center and the majority of these repairs were performed by the residents under training. Hence, a universal approach of circumcoronal degloving incision with access to all three corpora for all the patients is taught and practiced at our center. One patient from the former group had necrosis of

the penile skin, which was managed conservatively with daily dressings. EAU recommends early repair of penile fracture with the closure of defect in tunica albuginea by either the degloving or the longitudinal incision.

Different authors have reported different follow-up protocols. At a median follow-up of 36 months in our series, 14/20 patients were sexually active. The average time to return to sexual activity was 4.6 months. The mean SHIM score was 21.36 ± 1.33 and the average EHS was 3.21 ± 0.43 . Eight (57.1%) patients had mild ED according to the SHIM score while 6 (42.9%) patients had no ED. 4/20 (20%) patients developed penile nodule, while 2 patients complained of curvature (<20 degrees) although both the problems were not found to be bothersome. Our patient cohort is a heterogeneous group and most of the surgical repair is performed by the trainee residents. On specifically inquiring whether they were counseled about the risk of ED and penile nodule/curvature, 13/20 patients recalled being informed about ED but none recalled being informed about the penile nodule/curvature. A 20% incidence of penile nodule calls for long term follow up of patients with penile fracture repair or at counseling them regarding these long-term problems. Hence, a patient being lost to follow up should not be taken as a sign of successful repair especially in a country like ours where the social construct deters the patients from seeking help regarding sexual dysfunction. A comparison of all the series^[23–28] reporting ED, penile nodule and curvature is given in Table 2. Erectile function after fracture repair

Table 2: Series showing outcomes of sexual dysfunction after penile fracture repair

Study	Patients evaluated	Follow-up (median/mean)	Sexually active	Erectile function	Penile nodule	Penile curvature
Zargooshi ^[23]	170	53 months	NR	Mild ED - 5 Moderate ED - 3	5	7
Acikgoz <i>et al.</i> ^[24]	46/63	63±17.25 months (mean)	NR	Mean IIEF - 23.2±3.1 2 patients with ED	5	2
Nason <i>et al.</i> ^[25]	17/21	46 months (median)	16	IIEF-5 >22 - 14 patients 17-21 - 1 12-16 - 1 EHS 4 - 10 patients 3 - 7 patients BMSFI - 13 (83%) Patients were mostly satisfied or very satisfied with their sex life within the previous month	NR	NR
Reis <i>et al.</i> ^[26]	42	59.3	NR	2 patients with ED	0	4
Mahapatra <i>et al.</i> ^[8]	18/20	3 weeks-3 months	18	IIEF-5 ED - 2 patients No ED - 16 patients	2	0
Rajendra <i>et al.</i> ^[27]	13/21	NR	13	IIEF >22 - 11 17-21 - 1 12-16 - 1	0	0
Bolat <i>et al.</i> ^[28]	64	39.1±32.7 months (mean)	64	EHS - 3.8±0.9 5 patients with ED	1	1
Our study	20/43	36 months (median)	14	EHS- 3.21+/-0.43 SHIM Score- 21.36+/-1.33	4	2

ED=Erectile dysfunction, EHS=Erection hardness score, BMFSI= Brief male sexual function index, IIEF=International index of erectile function, NR=Not reported, SHIM=Sexual Health Inventory for Men

is comparable across the series but the incidence of penile nodule is higher in our series. It may be attributed to predominant use of prolene in our series and at times failure to bury the knots or not taking inverting sutures which can give rise to suture granulomas felt as nodules.

Common causes of ED after fracture penis are cavernosal arterial insufficiency and veno occlusive dysfunction.^[29] In a personal series of 170 patients Zargooshi reported that the early repair of fracture penis results in erectile function comparable to that of the control population.^[23] Acikgoz *et al.* found no statistically significant difference in patients operated within 24 h or after 24 h (Median IIEF-5 score of 22.65 in the 17 patients who were operated more than 24 h after the injury versus 23.78 of the 39 patients who were managed surgically within 24 h of the incident).^[24] Interestingly, they also found that 2 patients who were not operated in their series also did not develop ED, penile curvature or penile nodule. In our study, we were unable to trace patients who were not operated. Other complications in neglected cases may include urethral cavernosal fistulae and stricture urethra.^[30] In our series, none of the patients developed urethral strictures or fistulae. However, follow up protocols need to be standardized to detect these complications at the earliest. The limitations of our study include attrition of patients and cross-sectional follow-up.

CONCLUSION

Penile fracture is truly a urological emergency, and the diagnosis primarily remains clinical. Prompt diagnosis and an emergent surgical exploration provide good outcomes in terms of preservation of the sexual function. Long-term problems of penile nodule/plaque and curvatures should be discussed with the patient and they should be counseled regarding the same.

REFERENCES

1. Amer T, Wilson R, Chlosta P, AlBuheissi S, Qazi H, Fraser M, *et al.* Penile fracture: A meta-analysis. *Urol Int* 2016;96:315-29.
2. Agarwal MM, Singh SK, Sharma DK, Ranjan P, Kumar S, Chandramohan V, *et al.* Fracture of the penis: A radiological or clinical diagnosis? A case series and literature review. *Can J Urol* 2009;16:4568-75.
3. Malis J, Zur K. Der fractura penis. *Arch Klin Chir* 1924;129:651.
4. El-Bahnasawy MS, Gomha MA. Penile fractures: The successful outcome of immediate surgical intervention. *Int J Impot Res* 2000;12:273-7.
5. Özen HA, Erkan I, Alkibay T, Kendi S, Remzi D. Fracture of the penis and long-term results of surgical treatment. *Br J Urol* 1986;58:551-2.
6. El Atar R, Sfaxi M, Benslama MR, Amine D, Ayed M, Mouelli SB, *et al.* Fracture of the penis: Management and long-term results of surgical treatment. Experience in 300 cases. *J Trauma* 2008;64:121-5.
7. Ishikawa T, Fujisawa M, Tamada H, Inoue T, Shimatani N. Fracture of the penis: Nine cases with evaluation of reported cases in Japan. *Int J Urol* 2003;10:257-60.
8. Mahapatra RS, Kundu AK, Pal DK. Penile fracture: Our experience in a tertiary care hospital. *World J Mens Health* 2015;33:95-102.
9. Asgari MA, Hosseini SY, Safarinejad MR, Samadzadeh B, Bardideh AR.

- Penile fractures: Evaluation, therapeutic approaches and long-term results. *J Urol* 1996;155:148-9.
10. El-Taher AM, Aboul-Ella HA, Sayed MA, Gaafar AA. Management of penile fracture. *J Trauma* 2004;56:1138-40.
 11. Koifman L, Barros R, Júnior RA, Cavalcanti AG, Favorito LA. Penile fracture: Diagnosis, treatment and outcomes of 150 patients. *Urology* 2010;76:1488-92.
 12. Lee SH, Bak CW, Choi MH, Lee HS, Lee MS, Yoon SJ. Trauma to male genital organs: A 10-year review of 156 patients, including 118 treated by surgery. *BJU Int* 2008;101:211-5.
 13. Hsu GL, Brock G, Martínez-Piñeiro L, von Heyden B, Lue TF, Tanagho EA. Anatomy and strength of the tunica albuginea: Its relevance to penile prosthesis extrusion. *J Urol* 1994;151:1205-8.
 14. Derouiche A, Belhaj K, Hentati H, Hafsia G, Slama MR, Chebil M. Management of penile fractures complicated by urethral rupture. *Int J Impot Res* 2008;20:111-4.
 15. Farah RN, Stiles R Jr., Cerny JC. Surgical treatment of deformity and coital difficulty in healed traumatic rupture of the corpora cavernosa. *J Urol* 1978;120:118-20.
 16. Kalash SS, Young JD Jr. Fracture of penis: Controversy of surgical versus conservative treatment. *Urology* 1984;24:21-4.
 17. Hinev A. Fracture of the penis: Treatment and complications. *Acta Med Okayama* 2000;54:211-6.
 18. Morey AF, Dugi DD 3rd. Genital and lower urinary tract trauma. In: Wein AJ, Kavoussi LR, Partin AW, Novick AC, editors. *Campbell-Walsh Urology*. 10th ed. Philadelphia: Elsevier-Saunders, Co.; 2012. p. 2507, 2520.
 19. Jack GS, Garraway I, Reznicek R, Rajfer J. Current treatment options for penile fractures. *Rev Urol* 2004;6:114-20.
 20. Zargooshi J. Penile fracture in Kermanshah, Iran: Report of 172 cases. *J Urol* 2000;164:364-6.
 21. Miller S, McAninch JW. Penile fracture and soft tissue injury. In: McAninch JW, editor. *Traumatic and Reconstructive Urology*. Philadelphia: W.B. Saunders; 1996. p. 693-8.
 22. Mydlo JH. Surgeon experience with penile fracture. *J Urol* 2001;166:526-8.
 23. Zargooshi J. Penile fracture in Kermanshah, Iran: The long-term results of surgical treatment. *BJU Int* 2002;89:890-4.
 24. Acikgoz A, Gokce E, Asci R, Buyukalpelli R, Yilmaz AF, Sarikaya S. Relationship between penile fracture and Peyronie's disease: A prospective study. *Int J Impot Res* 2011;23:165-72.
 25. Nason GJ, McGuire BB, Liddy S, Looney A, Lennon GM, Mulvin DW, *et al.* Sexual function outcomes following fracture of the penis. *Can Urol Assoc J* 2013;7:252-7.
 26. Reis LO, Cartapatti M, Marmioli R, de Oliveira Júnior EJ, Saade RD, Fregonesi A. Mechanisms predisposing penile fracture and long-term outcomes on erectile and voiding functions. *Adv Urol* 2014;2014:768158.
 27. Rajendra NB, Vikas S, Amit M, Nitin PD, Wagh AT, Sarnaik SM, *et al.* Long term outcome of patients with penile fracture undergoing delayed repair. *Open J Trauma* 2017;1:32-6.
 28. Bolat MS, Özen M, Önem K, Açıkgoz A, Asci R. Effects of penile fracture and its surgical treatment on psychosocial and sexual function. *Int J Impot Res* 2017;29:244-9.
 29. Penson DF, Seftel AD, Krane RJ, Frohrib D, Goldstein I. The hemodynamic pathophysiology of impotence following blunt trauma to the erect penis. *J Urol* 1992;148:1171-80.
 30. Eke N. Fracture of the penis. *Br J Surg* 2002;89:555-65.

How to cite this article: Sharma AP, Narain TA, Devana SK, Tyagi S, Parmar KM, Bora GS, *et al.* Clinical spectrum, diagnosis, and sexual dysfunction after repair of fracture penis: Is no news good news? *Indian J Urol* 2020;36:117-22.