

Meeting abstract

Open Access

## Laparoscopic treatment of giant solitary hepatic cyst in a geriatric patient

S Ricciardi\*, R Giansini, E Mion, P Mainente, S Faccin and L De Santis

Address: U.O.A. Di Chirurgia Generale, Ospedale "San Lorenzo" Valdagno – VI, Italy

\* Corresponding author

from XXI Annual Meeting of The Italian Society of Geriatric Surgery  
Terni, Italy, 4–6 December 2008

Published: 1 April 2009

BMC Geriatrics 2009, 9(Suppl 1):A45 doi:10.1186/1471-2318-9-S1-A45

This abstract is available from: <http://www.biomedcentral.com/1471-2318/9/S1/A45>

© 2009 Ricciardi et al; licensee BioMed Central Ltd.

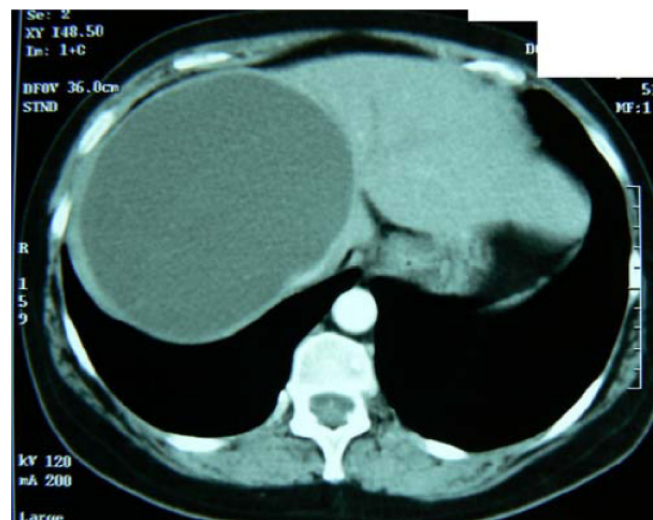
### Objective

Solitary congenital liver cysts are a rare finding and present a challenge in the diagnosis. The role of laparoscopy surgery in the management of benign cysts is now the gold standard for treating selected, giant, accessible, symptomatic or complicated cysts. Our objective was to assess the feasibility, the safety and the efficacy of the minimally invasive technique procedure for treating giant hepatic cyst even in geriatric patient.

### Methods

In support of the laparoscopic approach in the elderly, we here describe our minimally invasive technique in a patient with an isolated cystic mass located in the right lobe of the liver, in the anteroinferior (V–VI) and posterosuperior (VI–VIII) segments (Figure 1). A 65-year-old woman reported progressive upper abdominal distension, and digestive complaints that are unexplained by other findings. Our case was initially diagnosed by ultrasound (solitary cyst, unilocular, spherical shape, smooth-walled, and absence of internal echoes, measuring 15 cm in diameter) and confirmed by CT scan and MRI, which also gave further information regarding the extent of the mass and its proximity to any vital structures within the liver. Serological tests for hydatid liver disease were negative and an upper gastrointestinal endoscopy was normal. Alkaline phosphatase and the total bilirubin level were mildly elevated. Thereafter the patient was scheduled for laparoscopic cyst excision. After trocar placement, similar to that for laparoscopic cholecystectomy, a small opening was made in the cyst and the contents aspirated for cytology and culture. Using a monopolar hooked cautery, the

cyst was resected free from the liver surface, followed by an omentoplasty into the remaining cyst cavity (to prevent closing roof defect and cyst recurrence). The cyst was not in communication with biliary tree and not biliary leak has been reported. The procedure was completed laparoscopically without intraoperative complication and no need for blood transfusion. The operative time was 240 minutes.



**Figure 1**  
CT scan: appearance of a large hepatic cyst.

## Results

The cyst has been resected free from the liver surface without intraoperative complication and no need for blood transfusion. Histopathologic analysis demonstrated a true liver cyst (smooth cyst wall without calcification). Cyst serous fluid sent for CA testing was negative as a tumoral marker. In the early postoperative the patient developed a bilateral pleural effusion, treated successfully conservatively. The postoperative hospital stay was 12 days.

The patient is alive and free of symptoms during a follow-up of 12 months, without any signs of cyst recurrence.

## Discussion

The precise frequency of liver cysts is difficult to estimate, because most do not cause symptoms and require no treatment. When cysts become large and cause symptom treatment is warranted. No medical therapy has proven curative. From technical point of view cyst may be treated by percutaneous aspiration under ultrasound or CT guidance in combination with sclerotherapy with alcohol or other agents. However the cyst fluid is continually secreted by the epithelial lining of the cyst and for this reason, needle aspiration of simple cyst is not curative and it may cause bleeding and the development of hepatic abscess do to contamination of the cavity that should become a problem difficult to resolve. Today, the general agreement is that laparoscopic unroofing of large simple cyst (the so called Lin procedure) offers the best balance between efficacy and safety.

In our experience we preferred remove completely the wall of the cyst, to avoid cyst recurrence, by suppressing further fluid secretion. However, excision of the entire cyst wall is not necessary if is possible ablate the remaining epithelium with elettrocautery or an argon beam coagulator. Surgical cyst fenestration can be done laparoscopically in elderly achieving at least similar results to those offered by an open approach, and is accompanied by the usual postoperative benefits of laparoscopic surgery.

## Conclusion

Hepatic symptomatic giant cysts are suitable for the laparoscopic approach even in elderly patients. In selected patients total excision of the cyst is safe, associated with minimal morbidity and good long-term outcome and offers all the advantages of minimally invasive surgery.

Publish with **BioMed Central** and every scientist can read your work free of charge

*"BioMed Central will be the most significant development for disseminating the results of biomedical research in our lifetime."*

Sir Paul Nurse, Cancer Research UK

Your research papers will be:

- available free of charge to the entire biomedical community
- peer reviewed and published immediately upon acceptance
- cited in PubMed and archived on PubMed Central
- yours — you keep the copyright

Submit your manuscript here:  
[http://www.biomedcentral.com/info/publishing\\_adv.asp](http://www.biomedcentral.com/info/publishing_adv.asp)

