

Clinical Study

Comparison of Two Reconstructive Techniques in the Surgical Management of Four-Level Cervical Spondylotic Myelopathy

FengNing Li,^{1,2} ZhongHai Li,³ Xuan Huang,² Zhi Chen,² Fan Zhang,² HongXing Shen,² YiFan Kang,¹ YinQuan Zhang,¹ Bin Cai,² and TieSheng Hou²

¹Department of Orthopedics, Third Affiliated Hospital of PLA, Second Military Medical University, Shanghai 200433, China

²Department of Orthopedics, Changhai Hospital, Second Military Medical University, Shanghai 200433, China

³Department of Orthopedics, First Affiliated Hospital of PLA General Hospital, Beijing 100048, China

Correspondence should be addressed to HongXing Shen; shenhxspine@gmail.com and YiFan Kang; yfkang19630617@126.com

Received 13 October 2014; Revised 3 January 2015; Accepted 6 January 2015

Academic Editor: Shiro Imagama

Copyright © 2015 FengNing Li et al. This is an open access article distributed under the Creative Commons Attribution License, which permits unrestricted use, distribution, and reproduction in any medium, provided the original work is properly cited.

To compare the clinical efficacy and radiological outcome of treating 4-level cervical spondylotic myelopathy (CSM) with either anterior cervical discectomy and fusion (ACDF) or “skip” corpectomy and fusion, 48 patients with 4-level CSM who had undergone ACDF or SCF at our hospital were analyzed retrospectively between January 2008 and June 2011. Twenty-seven patients received ACDF (Group A) and 21 patients received SCF. Japanese Orthopaedic Association (JOA) score, Neck Disability Index (NDI) score, and Cobb's angles of the fused segments and C2-7 segments were compared in the two groups. The minimum patient follow-up was 2 years. No significant differences between the groups were found in demographic and baseline disease characteristics, duration of surgery, or follow-up time. Our study demonstrates that there was no significant difference in the clinical efficacy of ACDF and SCF, but ACDF involves less intraoperative blood loss, better cervical spine alignment, and fewer postoperative complications than SCF.

1. Introduction

There is currently no consensus on the best surgical treatment method for multilevel cervical spondylosis myelopathy (CSM). Surgery through an anterior approach was firstly described by Robinson and Smith [1] in 1955 as a successful treatment for cervical disease. Several decades later following the development of surgical techniques and advances in internal fixation materials, anterior approach surgery has become widely accepted; however, controversy remains regarding the selection of surgical procedures for the treatment of multilevel CSM.

Surgeries using both anterior and posterior approaches have been developed with the goal of decompressing the spinal cord and restoring the stability of the cervical spine. The posterior approach involves laminectomy with or without fusion, or laminoplasty. Laminectomy and laminoplasty have been found to be effective treatment for multilevel CSM but are hindered by the complications of progressive cervical kyphosis, C5 nerve root palsy, axial neck pain, segmental

instability, and associated postoperative neurological deterioration [2–5]. While the anterior approach surgery directly decompresses the spinal cord and nerve root, improves cervical alignment, and reduces the incidence of complications. Several studies have confirmed the safety and efficacy of treating multisegmental CSM using an anterior approach [6–9]. Different methods of anterior approach surgery include contiguous corpectomy and fusion (CCF), 4-level anterior cervical discectomy and fusion (ACDF) [10], “skip” corpectomy and fusion (SCF) [11], and hybrid decompression and fusion (HDF) [12]. During CCF it is necessary to remove three continuous vertebral bodies. The procedure requires long anterior strut grafts and postoperative complications include pseudarthrosis, graft subsidence, and loss of cervical lordosis [13–15]. For this reason only ACDF, SCF, and HDF continue to be widely used.

Based on these factors, the decision to treat multilevel CSM especially 4-level CSM with multilevel ACDF rather than SCF remains controversial, and few studies have investigated the treatment of 4-level CSM. In the present study,

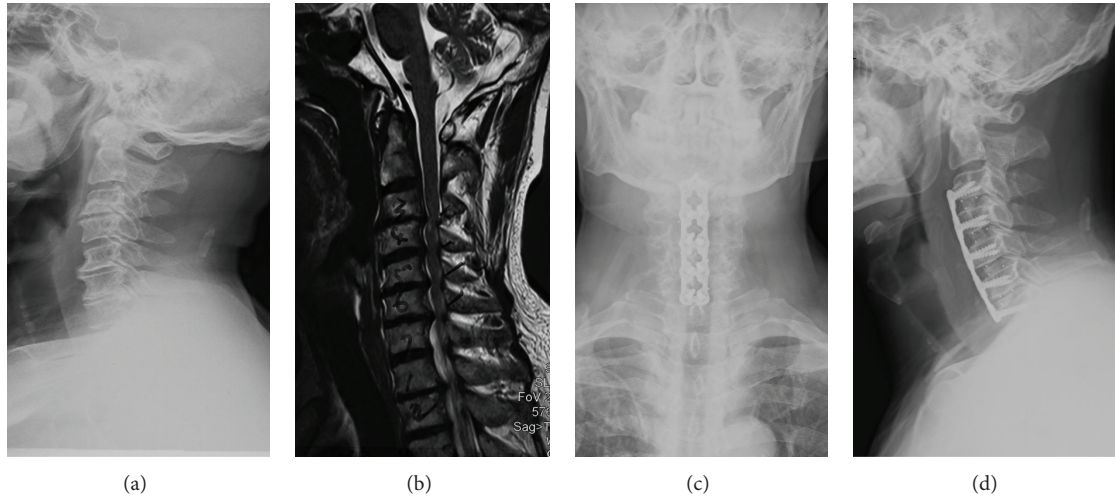


FIGURE 1: A 62-year-old male patient presented with a 6-month history of numbness in both hands which had become aggravated in the last month ago. This was accompanied by a month history of unsteadiness. Preoperative X-ray and MRI images ((a) and (b)) show loss of the cervical curvature with proliferation of osteophytes, and protrusions of C3/4 and C6/7 intervertebral discs. The compression of the spine was mainly restricted to the intervertebral space. No obvious compression was found on the posterior surface of the vertebral bodies. (c) and (d) show the anteroposterior and lateral images on neutral position of the cervical spine after ACDF surgery.

data from patients with 4-level CSM who underwent ACDF and SCF were retrospectively analyzed to compare the clinical efficacy, radiological outcomes, and complications associated with these two reconstructive techniques.

2. Subjects and Methods

2.1. Subject. Between January 2008 and June 2011, 48 consecutive patients who underwent surgery for 4-level CSM by a single surgeon (Shen HX) in our spine surgery center took part in the study. Inclusion criteria were (1) symptoms of cervical myelopathy and/or radiculopathy; (2) cervical spine X-ray, CT, and MRI showing intervertebral disc degeneration and herniation; and (3) cervical pathology at four consecutive levels. Exclusion criteria included ossification of the posterior longitudinal ligament (OPLL), rheumatoid arthritis, cerebral palsy, tumor, injury, destructive spondyloarthritis caused by hemodialysis, previous cervical surgery, thoracic spondylotic myelopathy, and lumbar spinal canal stenosis. Twenty seven (18 male and 9 female) between 47 and 76 years of age with compression restricted in the intervertebral spaces received ACDF (Group A). An additional 21 patients (13 male and 8 female) aged between 46 and 68 years, who had ventral spinal cord compression caused by pathology posterior to the vertebral body received SCF (Group B). The characteristics of the patients in the two groups are shown in Table 1.

2.2. Surgical Procedures. The surgical procedures performed on C3–7 have been described previously [10, 11]. For the patients in the ACDF group, the protrusive intervertebral discs and osteophytes were resected. An interbody fusion cage was implanted, and an anterior plate was used to improve the cervical spine alignment by providing multiple points of fixation. For the patients in the SCF group, C4 and C6 corpectomy was followed by resection of the osteophytes

TABLE 1: Characteristics of the patients.

	ACDF group (<i>N</i> = 27)	SCF group (<i>N</i> = 21)	<i>P</i> value
Age (year)	57.3 ± 8.0	56.7 ± 6.3	0.259
Gender (male/female)	18/9	13/8	0.518
Disease course (month)	11.2 ± 13.7	10.7 ± 8.1	0.121
Duration of follow-up (month)	34.7 ± 6.9	33.1 ± 8.4	0.156
Operated segments	C3–7	C3–7	
Operation time (minute)	152.6 ± 24.2	148.3 ± 25.9	0.733
Blood loss (mL)	161.1 ± 42.4	292.9 ± 67.6	0.027*

Values shown are means ± SD. ACDF: anterior cervical discectomy and fusion; SCF: “skip” corpectomy and fusion. **P* < 0.05.

posterior to the C5 vertebral body. This was performed using extended decompression. An allograft bone graft or autogenous iliac bone graft was then implanted and fixed using an anterior plate.

Slim-loc or Skyline anterior dynamic cervical plates (Johnson and Johnson Co., Depuy Spine Ltd., Ryhamn, MA) were used for fixation in both groups. X-rays were used to identify the affected segments during surgery. All patients were asked to wear cervical collar for 6 weeks. The patients were followed up at 6 weeks, 3, 12, 18, and 24 months postoperatively. Typical surgical outcomes are shown in Figures 1 and 2.

2.3. Postoperative Evaluation. Perioperative data including patient characteristics, disease course, operation time, and blood loss volume were collected. Clinical efficacy was evaluated by preoperative and postoperative measurement of Japanese Orthopaedic Association (JOA) scores, neck disability index (NDI) score, and recovery rate of the JOA

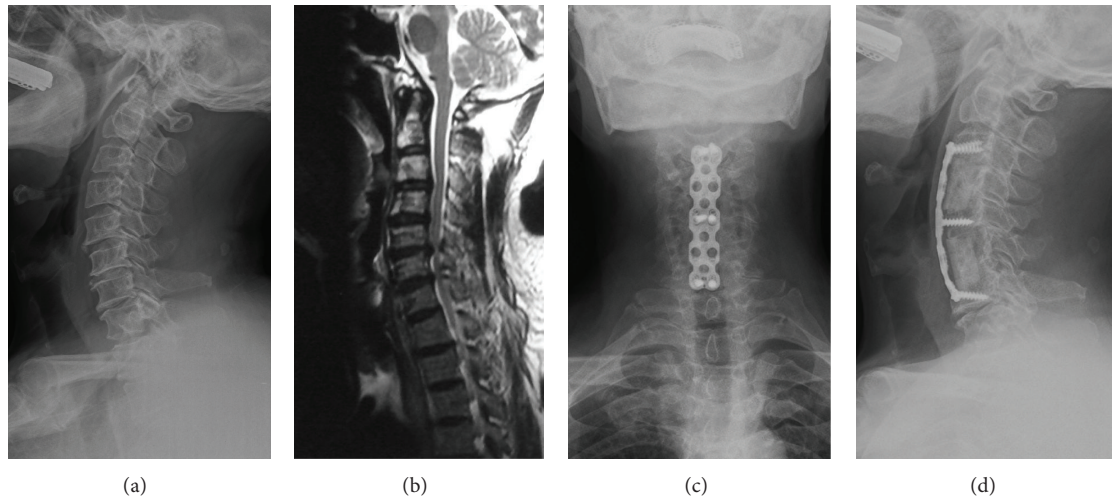


FIGURE 2: A 65-year-old male patient presented with a 2-year history of pain in the neck and shoulders accompanied by numbness in both hands. Preoperative X-ray and MRI images show proliferation of osteophytes, protrusions of C3/4 and C6/7, and spinal compression caused by hypertrophy of ligamentum flavum. (c) and (d) show the anteroposterior and lateral images on neutral position of the cervical spine after SCF surgery.

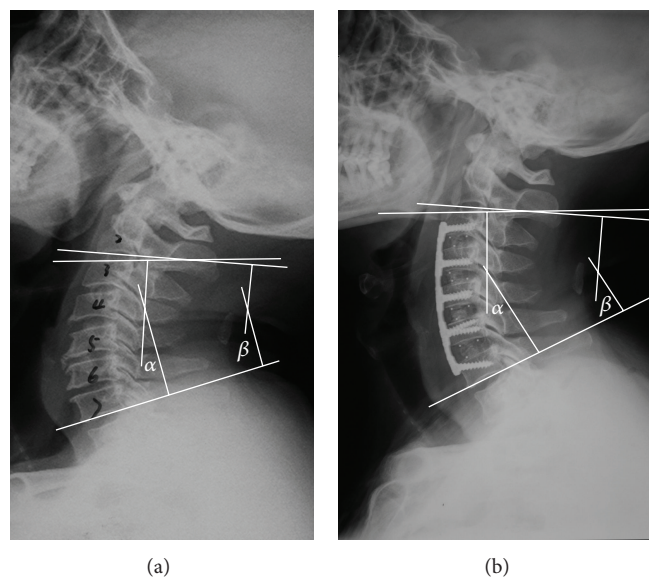


FIGURE 3: Measurement of Cobb's angle of C3–7 and C2–7 segments before (a) and after (b) surgery.

scores. Radiological outcomes included measurement of Cobb's angles for the operated segments (viz., C3–7 segments) and C2–7 segments. As shown in Figure 3, this was calculated as the angle between the superior border of the C3 vertebral body and the inferior border of the C7 or the angle between the inferior border of the C2 and the C7 vertebral body on neutral position. The criteria for osseous fusion were based on flexion and extension X-ray images showing that the spinous process distance was no more than 2 mm. Other criteria included absence of a radiolucent gap between the graft and the endplate; and/or demonstration of continuous bridging bony trabeculae at the graft-endplate interface [16–18]. Graft subsidence was defined as a >3 mm decrease in total vertical height of the two fused vertebral bodies measured on lateral

cervical radiographs taken immediately postoperatively and at 1 day postoperatively [19].

The presence of the following postoperative complications was recorded: temporary hoarseness, dysphagia, C5 nerve root palsy, cerebrospinal fluid leakage, pseudarthrosis, incision infection, graft subsidence, and graft dislocation. The incidence of dysphagia was defined as that solid or dry food gets stuck in the process of swallowing [20].

2.4. Statistical Analysis. Statistical analysis was undertaken using SPSS version 19.0 software (SPSS Inc., Chicago, IL, USA). Independent-sample *t*-tests were used to compare quantitative data including in the two groups. Paired-sample *t*-tests were used to compare the parameters before and after

TABLE 2: Clinical parameters and radiological outcomes.

	ACDF group (N = 27)	SCF group (N = 21)	P value
JOA score			
Preoperative	8.5 ± 1.3	8.4 ± 1.2	0.697
End of the follow-up	12.7 ± 1.4**	13.9 ± 1.6**	0.965
Increase (%)	49.9 ± 15.3	64.1 ± 16.5	0.690
NDI score			
Preoperative	35.2 ± 3.3	34.0 ± 3.7	0.652
End of the follow-up	14.8 ± 4.0**	13.3 ± 3.6**	0.524
Cobb's angle of C3-7 (°)			
Preoperative	8.5 ± 4.9	8.1 ± 5.5	0.510
End of the follow-up	21.7 ± 6.5**	15.8 ± 4.4**	0.025*
Cobb's angle of C2-7 (°)			
Preoperative	10.7 ± 5.9	9.1 ± 5.9	0.988
End of the follow-up	24.7 ± 6.3**	18.1 ± 4.2**	0.027*

Values shown are means ± SD. ACDF: anterior cervical discectomy and fusion; SCF: "skip" corpectomy and fusion. JOA: Japanese Orthopaedic Association; NDI: neck disability index. *P < 0.05; **relative to values before surgery.

surgery. Pearson Chi-square tests were used to compare the incidence of postoperative complications. Values of P < 0.05 were considered statistical significant.

3. Results

3.1. Perioperative Conditions. As shown in Table 1, blood loss was significantly lower in ACDF group than in SCF group. However, no significant between group differences were found in sex, age, course of disease, follow-up, and operation time.

3.2. Clinical Parameters and Radiological Outcomes. As shown in Table 2, the JOA scores increased sharply postoperatively in patients in the ACDF and SCF groups. There were corresponding decreases in postoperative NDI scores in the two groups. There were no significant differences in JOA scores, NDI scores, and recovery rate of the JOA scores before and after the operation between the two groups.

Cobb's angle of the operated segments increased postoperatively in both groups. The Cobb's angle of the C2-7 segments increased from 10.7 ± 5.9 to 24.7 ± 6.3 in the ACDF group, and from 9.1 ± 5.9 to 18.1 ± 4.2 in the SCF group. No significant difference was found in Cobb's angles of the operated segments and C2-7 segments before the operation between the two groups. However, Cobb's angles of the operated segments and C2-7 segments after the operation were found significantly higher in the ACDF group than in the SCF group.

3.3. Postoperative Complications. Postoperative complications including temporary hoarseness (two patients), temporary dysphagia (six patients), and C5 nerve root palsy (three patients) were found in 11 patients in the ACDF group. In

TABLE 3: Complications.

Complication	Number (%) of patients		P value
	ACDF group (N = 27)	SCF group (N = 21)	
Temporary hoarseness	2 (7.4%)	1 (4.76%)	0.707
Temporary dysphagia	6 (22.2%)	4 (19.1%)	0.788
C5 nerve root palsy	3 (11.1%)	2 (9.5%)	0.858
Cerebrospinal fluid leakage	0	1 (4.8%)	0.252
Pseudarthrosis	0	2 (9.5%)	0.101
Incision infection	0	1 (4.8%)	0.252
Graft subsidence	0	3 (14.3%)	0.043*
Graft dislocation	0	1 (4.8%)	0.252
Total	11 (40.7%)	15 (71.4%)	0.034*

ACDF: anterior cervical discectomy and fusion; SCF: "skip" corpectomy and fusion. *P < 0.05.

the SCF group, 15 patients developed postoperative complications (including one patient with temporary hoarseness, four with temporary dysphagia, two with C5 nerve root palsy, one with cerebrospinal fluid leakage, two with pseudarthrosis, one with incision infection, three with graft subsidence, and one with graft dislocation).

As shown in Table 3, postoperative complications were more common and more severe in the SCF group than in the ACDF group. In all patients, hoarseness, dysphagia, and C5 nerve root palsy improved after 2-weeks conservative treatments and had resolved completely at the 6-week follow-up. In the SCF group, one patient with cerebrospinal fluid leakage recovered after 2 weeks by keeping the supine position, drainage and dressing change. Besides, complications associated with graft were found in six patients, including two with pseudarthrosis, three with graft subsidence, and one with graft dislocation. Because these patients did not have significant clinical symptoms, none of them received revision surgery, and they still have been followed.

4. Discussion

Cervical spondylotic myelopathy is a degenerative disease which mostly occurs in the elderly people. MRI images show that spinal cord compressions are mainly the result of protrusive intervertebral discs and osteophytes. The pathophysiological features of CSM make anterior decompression the most effective surgical option.

Surgical treatment of multilevel CSM includes surgery through posterior, anterior and combined anterior and posterior surgical approaches. Both anterior and posterior approaches have been developed with the goal of decompressing the spinal cord and restoring the stability of the cervical spine. For some patients, with thickening of ligamentum flavum, in whom the compressions are mainly located at the dorsal spine, posterior laminectomy or laminoplasty is used to reduce the pressure. However, surgery through the posterior approach can result in progressive cervical kyphosis, C5 nerve root palsy, axial neck pain, segmental instability, and associated postoperative neurological deterioration, and may

not completely reduce the pressure in patients with anterior compression (such as those with patients with intervertebral disc protrusion or osteophytosis), especially if there is co-existing kyphosis deformation.

Contiguous corpectomy and fusion was initially used for the treatment of 4-level CSM [21]. However, a study comparing three reconstructive techniques [22] demonstrated that ACCF was associated with high blood-loss, low fusion rate, a high incidence of postoperative complications, and relatively poor cervical lordosis restoration. On the basis of these findings ACCF is no longer considered the correct choice for treating multilevel CSM. A biomechanical study [23] demonstrated that long bone strut grafts and cervical plate which required a longer fixed force arm were needed for multilevel corpectomy. This resulted in a relatively high pressure being exerted on the rear end screw which increased the incidence of graft dislocation, dislodgement, and internal fixation failure [23]. Another biomechanical study which comparing SCF and CCF, reported that SCF provided better stability than CCF in terms of lateral bending, and found that fixation with six screws reduced peak screw pull-out force during axial rotation by 19% [24]. However, as the biomechanical stability of CCF is relatively poor, and as the technique is associated with severe postoperative complications such as nonunion, strut graft subsidence, and loss of lordosis, the procedure has been gradually replaced by other techniques.

Other researchers have suggested that the primary goal of treating 4-level CSM with ACDF should be decompression of the spinal cord, followed by realignment of the cervical spine, stabilization of the cervical spine, and correction of a cervical spinal deformity [10]. The same authors also noted that extended decompression with ACDF could not achieve complete reversal of compression in the posterior half of the vertebral bodies and they suggest that corpectomy should be performed in these cases. Other research [11] suggests that SCF requires less fusion interface than ACDF and shorter strut grafts, and for these reasons it may provide better stability without the need for fixation through a posterior approach. Therefore, SCF has the potential to achieve effective decompression with a lower risk of fusion failure.

The most common indication was cervical myelopathy, followed by a loss of cervical lordosis, cervical spinal cord compression, segmental instability, axial neck pain, radiculopathy, segmental instability, radiculomyelopathy, post-laminectomy deformity, failure of previous fusion, and central cord syndrome. For most cases, ACDF can achieve the purpose of thorough decompression. SCF is reserved for patients with ventral spinal cord compression caused by pathology posterior to the vertebral body and inaccessible via an extended discectomy [25].

4.1. Clinical Efficacy. ACDF and SCF both use an anterior approach to achieve direct decompression. Our analysis demonstrates that both techniques are associated with a similar level of efficacy, however, the blood loss volume was significantly lower in ACDF group as the procedure does not require the resection of vertebral body. As SCF may theoretically, could provide better decompression than

ACDF, our own preference is to treat patients with ventral spinal cord compression caused by pathology posterior to the vertebral body with SCF, and to manage those with compression limited to the intervertebral spaces with ACDF. We believe that this management protocol may explain differences in the degree of compression between the two groups.

4.2. Cervical Spine Alignment. Previous workers have demonstrated that there is no significant difference in the postoperative realignment of the cervical spine between ACDF and HDF in the management of 3-level CSM [22]. However, the surgical failure rate increases significantly with the number of corpectomies that are required. Previous studies have also demonstrated that the failure rate caused by graft dislocation may be in the region of 50% to 71% when three contiguous corpectomies are performed [26, 27]. Our own findings demonstrate that ACDF results in better cervical spine alignment than SCF, suggesting that ACDF is better able to restore lordosis by providing fixation at multiple points, whereas graft subsidence, which could affect alignment of the cervical spine, is a general feature of SCF.

4.3. Postoperative Complications. A previous study [28] compared the incidence of complications (including graft subsidence, graft dislocation, hoarseness, dysphagia, C5 nerve root palsy, cerebrospinal fluid leakage, and incision infection) following the repair of 3-level CSM with three different reconstructive techniques using an anterior approach. The results suggested that ACDF was associated with the lowest incidence of pseudarthrosis and the highest incidence of laryngeal nerve-related complications. However, the highest overall incidence of complications was been found in CCF group, although no surgical treatment was required for most of the complications. Our analysis also showed that the incidence of complications in patients with 4-level CSM was significantly higher than that reported for 3-level CSM. In our series of cases complications in the ACDF group mainly included temporary hoarseness, dysphagia, and C5 nerve root palsy. Moreover, the incidence of severe complications such as incision infection, graft dislocation, and graft subsidence were significantly lower than in the SCF group. With corpectomies in the SCF group, long strut grafts and plate fixations create long lever arms that stress the caudal screws, making patients vulnerable to graft migration, displacement, and subsidence and instrumentation failure. These findings suggest that ACDF may be associated with a better safety profile than SCF.

4.4. Adjacent Segment Degeneration. For patients with multilevel CSM, the incidence of postoperative adjacent segment degeneration (ASD) is the most important concern for researchers. The incidence rate of ASD after anterior cervical fusion has been estimated at about 2.9% [29]. Previous studies suggest that the biomechanical changes of the cervical spine involved in the fusion of multiple segments may increase the mobility of adjacent segments, which in turn, increases compression on the intervertebral discs and accelerates disc degeneration. Thus, the incidence of ASD has been shown

to increase with the number of fused segments [30–32]. However, other research suggests that ASD is caused by the dual action of natural and accelerated degeneration of adjacent segments [29, 33]. In accordance with this hypothesis, a systematic review identified pre-existent adjacent segment degeneration as the main determinant of ASD [34]. Other studies have shown that the incidence of ASD is significantly lower after anterior cervical fusion undertaken for multilevel disease than for single-level disease. This may be explained by the incorporation of the high-risk (C5–C6, C6–C7) and intermediate-risk (C3–C4, C4–C5) levels into the fusion construct that occur adjacent to levels at low risk for new disease (C2–C3, C7–T1) [29]. In our series of patients there was no evidence of ASD after a follow-up of 2 years or more.

Limitations to the present study include the retrospective design, relatively short follow-up time, small sample size, and compression differences between the two groups which could theoretically bias the results. However, to date no study has investigated differences between ACDF and SCF. This is, therefore, the first study to demonstrate that ACDF involves less intraoperative blood loss, better cervical spine alignment, and fewer postoperative complications than SCF. Randomized controlled trials with larger sample sizes and longer follow-up times are needed to further investigate the differences between these two reconstructive techniques.

Conflict of Interests

The authors declare no conflict of interests.

Authors' Contribution

FengNing Li, ZhongHai Li, and Xuan Huang contributed equally to the work.

Acknowledgment

This study was supported by the 1255 Project of Changhai Hospital of Shanghai (no. CHI125520900).

References

- [1] R. A. Robinson and G. W. Smith, "Anterolateral cervical disc removal and interbody fusion for the cervical disc syndrome," *Bulletin of the Johns Hopkins Hospital*, vol. 96, pp. 223–224, 1955.
- [2] H. N. Herkowitz, "A comparison of anterior cervical fusion, cervical laminectomy, and cervical laminoplasty for the surgical management of multiple level spondylotic radiculopathy," *Spine*, vol. 13, no. 7, pp. 774–780, 1988.
- [3] K. Yonenobu, N. Hosono, M. Iwasaki, M. Asano, and K. Ono, "Laminoplasty versus subtotal corpectomy: a comparative study of results in multisegmental cervical spondylotic myelopathy," *Spine*, vol. 17, no. 11, pp. 1281–1284, 1992.
- [4] H. Sakaura, N. Hosono, Y. Mukai et al., "C5 palsy after decompression surgery for cervical myelopathy: review of the literature," *Spine*, vol. 28, no. 21, pp. 2447–2451, 2003.
- [5] G. J. Kaptain, N. E. Simmons, R. E. Replogle, and L. Pobere-skin, "Incidence and outcome of kyphotic deformity following laminectomy for cervical spondylotic myelopathy," *Journal of Neurosurgery*, vol. 93, no. 2, supplement, pp. 199–204, 2000.
- [6] S.-L. Hwang, K.-S. Lee, Y.-F. Su et al., "Anterior corpectomy with iliac bone fusion or discectomy with interbody titanium cage fusion for multilevel cervical degenerated disc disease," *Journal of Spinal Disorders & Techniques*, vol. 20, no. 8, pp. 565–570, 2007.
- [7] M. Ikenaga, J. Shikata, and C. Tanaka, "Anterior corpectomy and fusion with fibular strut grafts for multilevel cervical myelopathy," *Journal of Neurosurgery. Spine*, vol. 3, no. 2, pp. 79–85, 2005.
- [8] M. Ikenaga, J. Shikata, and C. Tanaka, "Long-term results over 10 years of anterior corpectomy and fusion for multilevel cervical myelopathy," *Spine*, vol. 31, no. 14, pp. 1568–1574, 2006.
- [9] A. P. Nirala, M. Husain, and D. K. Vatsal, "A retrospective study of multiple interbody grafting and long segment strut grafting following multilevel anterior cervical decompression," *British Journal of Neurosurgery*, vol. 18, no. 3, pp. 227–232, 2004.
- [10] S. W. Chang, U. K. Kakarla, P. H. Maughan et al., "Four-level anterior cervical discectomy and fusion with plate fixation: radiographic and clinical results," *Neurosurgery*, vol. 66, no. 4, pp. 639–646, 2010.
- [11] S. Dalbayrak, M. Yilmaz, and S. Naderi, "Skip corpectomy in the treatment of multilevel cervical spondylotic myelopathy and ossified posterior longitudinal ligament," *Journal of Neurosurgery: Spine*, vol. 12, no. 1, pp. 33–38, 2010.
- [12] S. Odate, J. Shikata, H. Kimura, and T. Soeda, "Hybrid decompression and fixation technique versus plated three-vertebra corpectomy for four-segment cervical myelopathy: analysis of 81 cases with a minimum 2-year follow-up," *Journal of Spinal Disorders and Techniques*, 2013.
- [13] H. T. Hee, M. E. Majd, R. T. Holt, T. S. Whitecloud III, and D. Pienkowski, "Complications of multilevel cervical corpectomies and reconstruction with titanium cages and anterior plating," *Journal of Spinal Disorders and Techniques*, vol. 16, no. 1, pp. 1–8, 2003.
- [14] H. Nakase, Y.-S. Park, H. Kimura, T. Sakaki, and T. Morimoto, "Complications and long-term follow-up results in titanium mesh cage reconstruction after cervical corpectomy," *Journal of Spinal Disorders & Techniques*, vol. 19, no. 5, pp. 353–357, 2006.
- [15] J. C. Wang, R. A. Hart, S. E. Emery, and H. H. Bohlman, "Graft migration or displacement after multilevel cervical corpectomy and strut grafting," *Spine*, vol. 28, no. 10, pp. 1016–1021, 2003.
- [16] L. K. Cannada, S. C. Scherping, J. U. Yoo, P. K. Jones, and S. E. Emery, "Pseudoarthrosis of the cervical spine: a comparison of radiographic diagnostic measures," *Spine*, vol. 28, no. 1, pp. 46–51, 2003.
- [17] A. Ploumis, A. Mehbod, T. Garvey, T. Gilbert, E. Transfeldt, and K. Wood, "Prospective assessment of cervical fusion status: plain radiographs versus CT-scan," *Acta Orthopaedica Belgica*, vol. 72, no. 3, pp. 342–346, 2006.
- [18] E. C. Papadopoulos, R. C. Huang, F. P. Girardi, K. Synnott, and F. P. Cammisia Jr., "Three-level anterior cervical discectomy and fusion with plate fixation: radiographic and clinical results," *Spine*, vol. 31, no. 8, pp. 897–902, 2006.
- [19] H.-P. W. van Jonbergen, M. Spruit, P. G. Anderson, and P. W. Pavlov, "Anterior cervical interbody fusion with a titanium box cage: early radiological assessment of fusion and subsidence," *Spine Journal*, vol. 5, no. 6, pp. 645–649, 2005.
- [20] Q. Lin, X. Zhou, X. Wang, P. Cao, N. Tsai, and W. Yuan, "A comparison of anterior cervical discectomy and corpectomy

- in patients with multilevel cervical spondylotic myelopathy," *European Spine Journal*, vol. 21, no. 3, pp. 474–481, 2012.
- [21] R. L. Saunders, H. J. Pikus, and P. Ball, "Four-level cervical corpectomy," *Spine*, vol. 23, no. 22, pp. 2455–2461, 1998.
- [22] Y. Liu, Y. Hou, L. Yang et al., "Comparison of 3 reconstructive techniques in the surgical management of multilevel cervical spondylotic myelopathy," *Spine*, vol. 37, no. 23, pp. E1450–E1458, 2012.
- [23] K. Singh, A. R. Vaccaro, J. Kim, E. P. Lorenz, T.-H. Lim, and H. S. An, "Enhancement of stability following anterior cervical corpectomy: a biomechanical study," *Spine*, vol. 29, no. 8, pp. 845–849, 2004.
- [24] M. Yilmaz, K. Zafer Yüksel, S. Baek et al., "Biomechanics of cervical 'Skip' corpectomy versus standard multilevel corpectomy," *Journal of Spinal Disorders and Techniques*, 2012.
- [25] M. A. Eleraky, C. Llanos, and V. K. H. Sonntag, "Cervical corpectomy: report of 185 cases and review of the literature," *Journal of Neurosurgery*, vol. 90, no. 1, pp. 35–41, 1999.
- [26] A. R. Vaccaro, S. P. Falatyn, G. J. Scuderi et al., "Early failure of long segment anterior cervical plate fixation," *Journal of Spinal Disorders*, vol. 11, no. 5, pp. 410–415, 1998.
- [27] R. C. Sasso, R. A. Ruggiero Jr., T. M. Reilly, and P. V. Hall, "Early reconstruction failures after multilevel cervical corpectomy," *Spine*, vol. 28, no. 2, pp. 140–142, 2003.
- [28] Y. Liu, M. Qi, H. Chen et al., "Comparative analysis of complications of different reconstructive techniques following anterior decompression for multilevel cervical spondylotic myelopathy," *European Spine Journal*, vol. 21, no. 12, pp. 2428–2435, 2012.
- [29] A. S. Hilibrand, G. D. Carlson, M. A. Palumbo, P. K. Jones, and H. H. Bohlman, "Radiculopathy and myelopathy at segments adjacent to the site of a previous anterior cervical arthrodesis," *The Journal of Bone & Joint Surgery A*, vol. 81, no. 4, pp. 519–528, 1999.
- [30] J. C. Eck, S. C. Humphreys, T.-H. Lim et al., "Biomechanical study on the effect of cervical spine fusion on adjacent-level intradiscal pressure and segmental motion," *Spine*, vol. 27, no. 22, pp. 2431–2434, 2002.
- [31] A. Elsawaf, L. Mastronardi, R. Roperto, A. Bozzao, M. Caroli, and L. Ferrante, "Effect of cervical dynamics on adjacent segment degeneration after anterior cervical fusion with cages," *Neurosurgical Review*, vol. 32, no. 2, pp. 215–224, 2009.
- [32] C.-S. Wang, J.-H. Chang, T.-S. Chang, H.-Y. Chen, and C.-W. Cheng, "Loading effects of anterior cervical spine fusion on adjacent segments," *Kaohsiung Journal of Medical Sciences*, vol. 28, no. 11, pp. 586–594, 2012.
- [33] D. R. Gore, S. B. Sepic, and G. M. Gardner, "Roentgenographic findings of the cervical spine in asymptomatic people," *Spine*, vol. 11, no. 6, pp. 521–524, 1986.
- [34] M. J. Lee, J. R. Dettori, C. J. Standaert, C. G. Ely, and J. R. Chapman, "Indication for spinal fusion and the risk of adjacent segment pathology: does reason for fusion affect risk? A systematic review," *Spine*, vol. 37, no. 22, pp. S40–S51, 2012.