

## REFERENCES

1. Arezzo A, Verra M, Morino M. Transanal endoscopic microsurgery after neoadjuvant therapy for rectal GIST. *Digestive and Liver Disease* 43 (2011) 921–924.
2. Blay JY, Bonvalot S, Casali P, et al. GIST consensus meeting panellists: Consensus meeting for the management of gastrointestinal stromal tumours. Report of the GIST Consensus Conference of 20–21 March 2004, under the auspices of ESMO. *Ann Oncol* 2005;16:566–78.
3. Fiore M, Palassini E, Fumagalli E, Pilotti S, Tamborini E, Stacchiotti S, Pennacchioli E, Casali PG, Gronchi A. Preoperative imatinib mesylate for unresectable or locally advanced primary gastrointestinal stromal tumors (GIST). *Eur J Surg Oncol*. 2009 Jul;35(7):739-45. Epub 2008 Dec 24.
4. Hamada M, Ozaki K, Horimi T, Tsuji A, Nasu Y, Iwata J, Nagata Y. Recurrent rectal GIST resected successfully after preoperative chemotherapy with imatinib mesylate *Int J Clin Oncol* (2008) 13:355–360.
5. Lo SS, Papachristou GI, Finkelstein SD, Conroy WP, Schraut WH, Ramanathan RK. Neoadjuvant imatinib in gastrointestinal stromal tumor of the rectum: report of a case. *Dis Colon Rectum* 2005;48:1316-1319.
6. Machlenkin S, Pinski I, Tulchinsky H et al (2011) The effective of neoadjuvant imatinib therapy on outcome and survival after rectal gastrointestinal stromal tumour. *Colon Dis* 13:1110–1115.
7. Mandalà M, Pezzica E, Tamborini E, Guerra U, Lagonigro SM, Forloni B, Barni S. Neoadjuvant imatinib in a locally advanced gastrointestinal stromal tumour (GIST) of the rectum: a rare case of two GISTs within a family without a familial GIST syndrome. *Eur J Gastroenterol Hepatol*. 2007 Aug;19(8):711-3.
8. Nahas, SC, Nahas, CS, Marques CF, Dias AR, Pollara WM, Cecconello I. Transanal endoscopic microsurgery (TEM): a minimally invasive procedure for treatment of selected rectal neoplasms. *ABCD, arq. bras. cir. dig.* 2010, vol.23, n.1, pp. 35-39.
9. Salazar M, Barata A, André S, Venâncio J, Francisco I, Cravo M, Nobre-Leitão C. First report of a complete pathological response of a pelvic GIST treated with imatinib as neoadjuvant therapy. *Gut*. 2006 Apr;55(4):585-6.
10. Wang JP, Wang T, Huang MJ, Wang L, Kang L, Wu XJ. The role of neoadjuvant imatinib mesylate therapy in sphincter-preserving procedures for anorectal gastrointestinal stromal tumor. *Am J Clin Oncol*. 2011 Jun;34(3):314-6.

ABCDDV/1092

ABCD Arq Bras Cir Dig Letter to the Editor  
2015;28(1):89-90  
DOI:<http://dx.doi.org/10.1590/S0102-67202015000100023>

## ENDOSCOPIC HEMOSTASIS OF A BLEEDING GASTRIC GASTROINTESTINAL STROMAL TUMOR (GIST) WITH ENDOLOOP PLACEMENT

*Hemostasia endoscópica de tumor estromal gastrointestinal (GIST) gástrico com colocação de "endoloop"*

Felipe Alves **RETES**, Bruno da Costa **MARTINS**,  
Mauricio Paulin **SORBELLO**, Cezar Fabiano Manabu **SATO**,  
Fabio Shiguehissa **KAWAGUTI**, Fauze **MALUF-FILHO**,  
Ulysses **RIBEIRO-JUNIOR**

From the Instituto do Câncer do Estado de São Paulo, Faculdade de Medicina, Universidade de São Paulo (Cancer Institute of São Paulo State, Faculty of Medicine, University of São Paulo), São Paulo, SP, Brazil

Financial source: none

### Correspondence:

Mauricio Paulin Sorbello  
E-mail: [sorbello.mauricio@gmail.com](mailto:sorbello.mauricio@gmail.com)

Received for publication: 21/01/2014  
Accepted for publication: 09/12/2014

ABCD Arq Bras Cir Dig 2015;28(1):86-92



This is an Open Access article distributed under the terms of the Creative Commons Attribution Non-Commercial License, which permits unrestricted non-commercial use, distribution, and reproduction in any medium, provided the original work is properly cited.

## INTRODUCTION

Gastrointestinal bleeding due to gastric neoplasia is difficult to manage and may provoke dramatic situations. For the most part, therapeutic endoscopic methods provide only temporary success in controlling bleeding. Often, a poor clinical condition and an advanced stage of the neoplastic disease mean these patients will receive exclusively palliative clinical care. Hence, surgical procedures are often contraindicated, either due to lack of clinical conditions or the increased mortality resulting from surgical trauma. In such cases, alternative endoscopic techniques have been described as minimally invasive means of controlling tumor-induced bleeding.

## CASE REPORT

A 79 year-old man with gastric GIST, receiving Imatinib for the presence of multiple hepatic (Figure 1), pulmonary and bone metastases, was admitted to the Cancer Institute of the University of São Paulo Medical School, São Paulo, SP, Brazil after presenting massive hematemesis, followed by syncope.

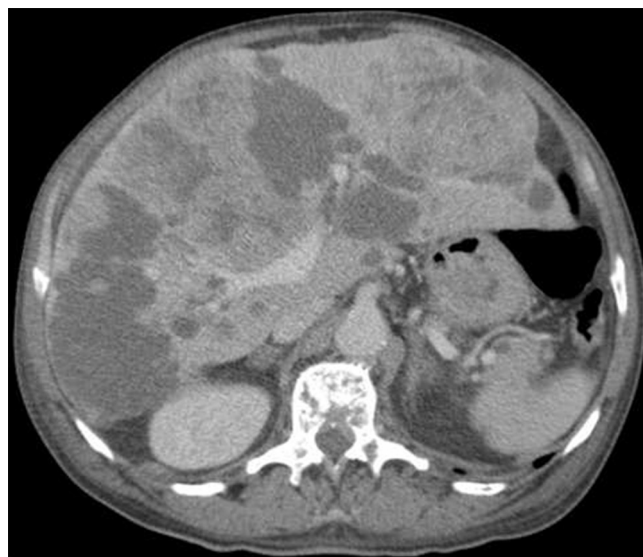

FIGURE 1 - Multiple hepatic metastases

An upper gastrointestinal endoscopy was indicated. The exam revealed fresh blood in the gastric chamber and a 4 cm submucosal ulcerated lesion, partially covered with adherent clots in the cardia region. Since there was no ongoing bleeding, endoscopic therapy was not performed at that time. However, after multidisciplinary discussion, it was decided to attempt endoscopic hemostasis due to the high risk involved in using anesthesia to perform surgical resection. An endoloop was placed at the base of the lesion in a retroflexed position (Figure 2).

One week later, an endoscopic review exam was performed, demonstrating the successful hemostatic procedure (Figure 3).

The patient was then referred to and followed by the palliative care group and died two months later, without further bleeding.

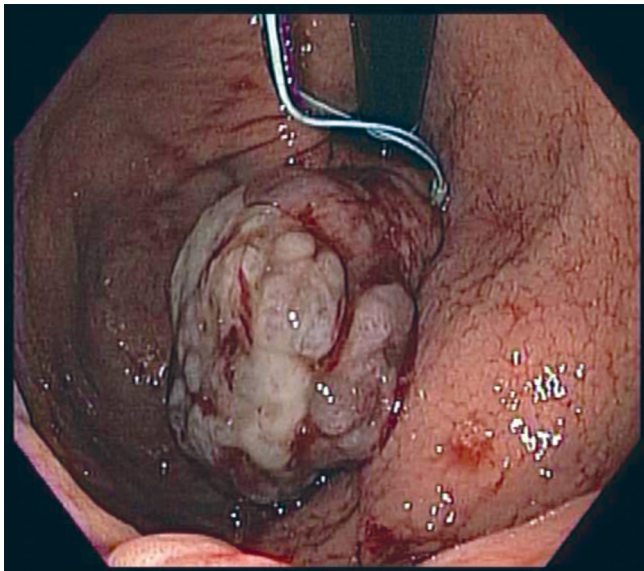


FIGURE 2 - Endoscopic retroflexion: bleeding GIST and endoloop placement

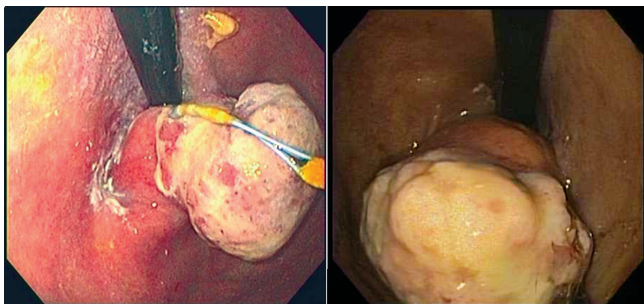


FIGURE 3 - Endoscopic follow-up: GIST looped, with ischaemic appearance and necrosis

## DISCUSSION

Endoscopic hemostasis of tumoral lesions is a challenging situation, since no endoscopic therapy has been proved to be superior<sup>3</sup>. Choice of therapy will be dictated by the tumor's appearance and the personal experience of the endoscopist. Reports show that hemoclips have been applied in both successful<sup>2</sup> and failed<sup>4</sup> attempts to achieve hemostasis. In the present case, the tumor appeared to be friable and an attempt to apply hemoclips could have led to mucosal tearing and recurrent bleeding. Endoloop ligation of such lesions has been described to treat bleeding tumors and also to resect lesions in patients deemed non-surgical candidates, through ischemic necrosis (loop-and-let-go)<sup>1</sup>. Although the surgical approach is considered the treatment of choice for such lesions, the endoloop technique is a useful, feasible, cheap and safe alternative for patients considered unsuitable for surgery or as a temporary measure to stabilize patients before the surgical treatment.

## REFERENCES

1. Arezzo A, Verra M, Miegge A, Morino M. Loop-and-let-go technique for a bleeding, large sessile gastric gastrointestinal stromal tumor (GIST). *Endoscopy*. 2011;43 Suppl 2 UCTN:E18-9.
2. Cheng AW, Chiu PW, Chan PC, Lam SH. Endoscopic hemostasis for bleeding gastric stromal tumors by application of hemoclip. *J Laparoendosc Adv Surg Tech A*. 2004;14:169-71;

3. Savides TJ, Jensen DM, Cohen J, Randall GM, Kovacs TO, Pelayo E, Cheng S, Jensen ME, Hsieh HY. Severe upper gastrointestinal tumor bleeding: endoscopic findings, treatment, and outcome. *Endoscopy*. 1996;28:244-8;
4. Seya T, Tanaka N, Yokoi K, Shinji S, Oaki Y, Tajiri T. Life-threatening bleeding from gastrointestinal stromal tumor of the stomach. *J Nihon Med Sch*. 2008;75:306-11;

ABCDDV/1093

ABCD Arq Bras Cir Dig Letter to the Editor  
2015;28(1):90-92

DOI:http://dx.doi.org/10.1590/S0102-67202015000100024

## LAPAROSCOPIC REPAIR IN SIMULTANEOUS OCCURRENCE OF RECURRENT CHRONIC TRAUMATIC DIAPHRAGMATIC HERNIA AND TRANSDIAPHRAGMATIC INTERCOSTAL HERNIA

*Reparação laparoscópica na ocorrência simultânea de  
hérnia diafragmática traumática crônica recorrente e hérnia  
transdiafragmática intercostal*

Murat **YILDAR**<sup>1</sup>, Ismail **YAMAN**<sup>2</sup>, Hayrullah **DERICI**<sup>3</sup>

From the Department of General Surgery, Balıkesir University Faculty of Medicine, Balıkesir, Turkey

Financial source: none

Conflicts of interest: none

### Correspondence:

Murat Yıldar

Email: muratyildar@hotmail.com

Received for publication: 04/02/2014

Accepted for publication: 11/12/2014

## INTRODUCTION

Traumatic diaphragmatic hernia (TIH) develops in association with blunt or penetrating thoracoabdominal injuries. Incidence levels between 0.8% and 42% have been reported, depending on the injury site<sup>1,9,12,13</sup>. TIH is a rare entity. It occurs either due to trauma-related diaphragmatic injuries which cause tears in the intercostal muscles between the fractured ribs, or due to recurrence of diaphragmatic hernia in which previous repair was performed using the transthoracic approach<sup>1</sup>.

Traumatic diaphragmatic injuries are generally asymptomatic when isolated, and frequently cannot be detected radiologically under acute conditions<sup>13</sup>. When accompanied by other organ injuries requiring surgical exploration, diagnosis is made during operation, and these can be treated concurrently. Laparoscopic repair is usually preferred in acute isolated diaphragmatic injuries, while chronic and recurrent cases are traditionally repaired using thoracotomy because of dense adhesions. With increasing experience of minimally invasive surgery in recent years, it has been reported that chronic and recurring cases can also be laparoscopically treated.

No cases of laparoscopic repair in simultaneous recurrent chronic traumatic diaphragmatic hernia (RCDH) and TIH have been reported to date. Here, is described the laparoscopic repair of this association.