

A novel technique using endoscopic band ligation for removal of long-stalked (> 10 mm) pedunculated colon polyps: A prospective pilot study

Hyun Ho Choi[#], Chang Whan Kim^{1,#}, Hyung-Keun Kim, Sang Woo Kim, Sok Won Han¹, Kyung Jin Seo², Hiun-Suk Chae

Department of Internal Medicine, Uijeongbu St. Mary's Hospital, College of Medicine, The Catholic University of Korea, ¹Department of Internal Medicine, Bucheon St. Mary's Hospital, College of Medicine, The Catholic University of Korea, ²Department of Hospital Pathology, Uijeongbu St. Mary's Hospital, College of Medicine, The Catholic University of Korea, Seoul, Korea

[#]Author HHC and author CWK equally contributed to this work.

Abstract

Background: Endoscopic removal of large and thick-stalked pedunculated colonic polyps, often leads to massive hemorrhage. Several techniques to minimize this complication have not been widely adopted due to some caveats. In order to prevent postpolypectomy bleeding, we invented a novel technique to dissect long-stalked pedunculated colonic polyps using endoscopic band ligation (EBL) by laterally approaching the stalk.

Methods: In this prospective single-center study, 17 pedunculated polyps in 15 patients were removed between April 2012 and January 2016. We targeted pedunculated polyps with a long stalk length (>10 mm) and a large head (>10 mm) located in the distal colon. After identifying lesions with a colonoscope, we reapproached the middle part of the stalk of the targeted polyp with an EBL-equipped gastroscope to ligate it. Snare polypectomy was performed just above the ligation site of the stalk.

Results: EBL-assisted polypectomy removed all of the lesions successfully, which were confirmed pathologically. There was little technical difficulty associated with the endoscopic procedures, regardless of polyp size and stalk thickness, except for one case with a very large polyp that impeded the visualization of the ligation site. We observed a positive correlation between procedure time and the diameter of the head (spearman $\rho = 0.52$, $P = 0.034$). After dissection of the polyp, the EBL bands remained fastened to the dissected stalks in all cases. There was no complication associated with polypectomy for 1 month.

Conclusion: EBL-assisted polypectomy is an easy, safe, and effective technique to remove long-stalked pedunculated colonic polyps without postpolypectomy bleeding.

Keywords: Bleeding, colonic polyp, colonoscopy, endoscopic mucosal resection, ligation

Address for correspondence: Prof. Hiun-Suk Chae, Department of Internal Medicine, Uijeongbu St. Mary's Hospital, College of Medicine, The Catholic University of Korea, 271, Cheonbo-Ro, Uijeongbu-si, Gyeonggi-do - 11765, Republic of Korea.

E-mail: chs@catholic.ac.kr

Submitted: 17-Nov-2020 **Revised:** 24-Dec-2020 **Accepted:** 24-Dec-2020 **Published:** 22-Feb-2021

Access this article online	
Quick Response Code:	Website: www.saudijgastro.com
	DOI: 10.4103/sjg.sjg_625_20

This is an open access journal, and articles are distributed under the terms of the Creative Commons Attribution-NonCommercial-ShareAlike 4.0 License, which allows others to remix, tweak, and build upon the work non-commercially, as long as appropriate credit is given and the new creations are licensed under the identical terms.

For reprints contact: WKHLRPMedknow_reprints@wolterskluwer.com

How to cite this article: Choi HH, Kim CW, Kim HK, Kim SW, Han SW, Seo KJ, *et al.* A novel technique using endoscopic band ligation for removal of long-stalked (>10 mm) pedunculated colon polyps: A prospective pilot study. Saudi J Gastroenterol 2021;27:296-301.

INTRODUCTION

Colonoscopic polypectomy including standard snare polypectomy, endoscopic mucosal resection (EMR), and endoscopic submucosal dissection (ESD) is a standard therapy for colon polyps that has replaced surgical polypectomy throughout the colon.^[1] One of the most common and serious complications associated with endoscopic polypectomy is hemorrhage, with an incidence ranging from 0.3% to 6%.^[2] Postpolypectomy bleeding (PPB) occurs frequently in cases of large polyps, with thick stalks (>5 mm), in the presence of malignancy and location in the right colon.^[3] In particular, large pedunculated colonic polyps with thick stalk often cause immediate and profuse PPB by incomplete hemostasis of feeding arteries immediately after removal.^[4] A few endoscopic techniques have been reported to reduce the risk of bleeding, including injection therapy and mechanical hemostatic methods using endoloops and the application of clips.^[4-10] For example, polypectomy using an endoloop may require sophisticated endoscopic techniques and PPB may occur in relation to the procedure because of loop slippage or inadvertent dissection in thin-stalk polyps. Another method of clipping the base of the stalk of targeted polyps before polypectomy, remains controversial^[6,8] because risk of coagulation syndrome might occur by contacting clips with a polypectomy snare.

Endoscopic band ligation (EBL) has been shown to be an effective method of controlling bleeding from esophageal varices, gastric lesions with visible vessels, and rectal varices.^[11] Since the techniques are simple and familiar to the endoscopists, the band ligation apparatus has been widely used to control other types of hemostasis for colonic PPB, colonic diverticular hemorrhage, and endoscopic submucosal resection in cases of small rectal carcinoids.^[12] EBL can provide a clear view of lesions under direct pressure by a transparent cap to the targeted lesions. However, with the above method, the EBL approaches directly and head-on to the target lesions, which is not suitable to remove the polyp because of little space to reserve the polyp. To overcome the problem, the authors intended lateral access to the stalk of targeting polyps and then ligate it by releasing the band of EBL in order to compress and block the feeding arteries of pedunculated polyps, thereby preventing PPB. In this study, we evaluated the feasibility, safety, and efficacy of this hemostatic technique to remove long-stalked pedunculated colon polyps.

METHODS

Patients

Between April 2012 and January 2016, 15 patients with 17

pedunculated colonic polyps were enrolled in this study. Eligible criteria were as follows: (1) polyps with head >10 mm and stalk length >10 mm; (2) location at the distal segments of the colon; and (3) benign features under endoscopic inspection (absence of ulceration and induration or friability). In patients taking anticoagulants such as aspirin, coumadin, or nonsteroidal anti-inflammatory drugs (NSAIDs), this medication was discontinued 7 days before the polypectomy and resumed a week later.

Patients underwent colonoscopy before performing endoscopic band ligation assisted polypectomy (EAP). Colonoscopic examinations were performed using a standard colonoscope (CF-H260 series; Olympus, Tokyo, Japan). During colonoscopy, we found targeted polyps and identified their sizes and locations. The size of the polyp head and the diameter of the stalk were estimated using the complete opening width of the biopsy forceps. We then changed the colonoscope to an upper endoscope for EBL (Sumitomo Bakelite Co., Akita, Japan) because of the absence of colonoscopy-fitted EBL. After EAP, the patients stayed in the hospital for 1 day. Hemoglobin, hematocrit, and plain abdomen X-rays were checked 1 day after the treatment. Physical examinations were performed to assess for abdominal pain and hematochezia. The patients were followed up in the outpatient clinic for 1 month. This study protocol was approved by our Institutional Research Ethics Board and adhered to the Helsinki Declaration. All study subjects provided written informed consent before the procedure.

Endoscopic procedure

The EAP procedure is illustrated in Figures 1 and 2. A conventional upper endoscope loaded with a band ligator was inserted to the site of the targeted pedunculated polyp [Figure 2a]. After approaching the lateral side of the stalk [Figures 1a and 2b] and grasping the mid-portion of the stalk using a tripod grasper (FG-45L-1, Olympus), we drew it into the cap, feeling some resistance [Figures 1b and 2c]. When the endoscopic view was blurred, the rubber band was released from the cap to ligate the stalk [Figures 1c and 2d]. We were able to confirm the proper ligation band by identifying endoscopically and presume the compression of feeding arteries to the polyp by congestion of the polyp head. Thereafter, we resected the remaining free margin of the stalk just above the ligation with an electro-surgical snare (SD-9U-1 or SD-11U-1, Olympus) [Figure 1d]. The polyps were removed by electrocoagulation with Endocut Q current (effect 3, cut duration 2 ms, cut interval 1200 ms) generated by a VIO300D electro-surgical unit (Erbe, Tübingen, Germany) [Figure 2e]. All procedures were performed by three experienced endoscopists who had

an experience of more than 1,000 colorectal endoscopic mucosal resections. The resected polyps were collected for histopathological evaluation and reviewed by pathologists specializing in gastrointestinal pathology; a cutting site with coagulation is shown in Figure 3. Hematoxylin and eosin-stained slides were reviewed for each case.

Clinical outcomes

We evaluated several parameters, including completeness of resection, procedure time, and complications including immediate PPB, delayed PPB, and perforation. Complete resection was defined as a lesion-free margin with both the lateral and basal tissues microscopically. Immediate PPB was defined as pulsating bleeding or oozing of blood lasting more than 60 s immediately after the procedure. Delayed PPB was defined as gross rectal bleeding, bleeding requiring endoscopic or radiological hemostasis, or transfusions requiring surgery up to 1 month after the procedure. Perforation was detected with either endoscopic penetration of the wall or radiological examinations. In addition, spearman's correlation test was used to analyze the correlation between the procedure time and diameter of the head or stalk of the polyp.

RESULTS

Fifteen patients were enrolled in the study; 17 pedunculated colonic polyps were removed by EAP. The mean age of

the patients was 64 years (range 52–81 years). The mean size of resected polyps was 15.6 mm (range 10–40 mm): size ≥ 20 mm (3/17, 17.6%) and 10–19 mm (14/17, 82.4%). The width of the stalks was 14.4 mm (range 10–25 mm): stalk width ≤ 9 mm (8/17, 47.1%) and ≥ 10 mm (9/17, 52.9%) [Table 1]. The average duration of the endoscopic procedure was 365 s (range 151–890 s). We observed positive correlation between procedure time and the diameter of the head (spearman $\rho = 0.52$, $P = 0.034$) [Figure 4]. However, the procedure time was not related to other polyp-related factors including width and length of the stalk and pathologic types. All lesions were resected without difficulty except one case of a 40 × 40 mm polyp with a stalk 15 mm thick (patient 15 in Table 1). The procedural time of that case was about 15 mins because of the difficulty in finding the exact ligation, due to the visual hindrance by the huge mass itself. Nevertheless, R0 resection was obtained in of the cases. Histological examination of the 17 polyps revealed 10 tubular adenomas with low-grade dysplasia, three tubular adenomas with high-grade dysplasia, one tubulovillous adenoma with low-grade dysplasia, and three tubulovillous adenomas with high-grade dysplasia. There were no procedure-related complications for 1 month, such as PPB and perforations.

DISCUSSION

The incidence of early and late PPB as the most common complication is 10.0%–15.1%, especially in pedunculated polyps without any preventive intervention.^[4,13,14] The relevant factors for PPB are related to characteristics of polyp itself (size, morphology, and location) as well as other underlying conditions of patients (age, cardiovascular or chronic renal disease, and anticoagulant use).^[15] Usually, PPB occurs in settings with large polyp size, or pedunculated polyp with a thick stalk. Although several preventive measures for PPB including injection therapy, endoloop ligation, and application of hemoclips have been developed, PPB remains a major complication of polypectomy until now.^[5,7,9,10,16-20] EBL was first introduced for the treatment of bleeding esophageal varices in 1988.^[11] The simplicity and high efficiency of this technique have prompted widespread use in the management of nonvariceal bleeding, including PPB, arteriovenous malformations, and colonic diverticular hemorrhage.^[12,21,22]

Herein, for the first time, we applied EBL in polypectomy of pedunculated colonic polyps for the prevention of PPB. In this study, the features of all resected polyps were as follows: localization in the distal colon, mean size of a polyp 15.6 mm, mean stalk width of 10.1 mm, and pathologic type (13 tubular adenomas and 4 tubulovillous adenomas).

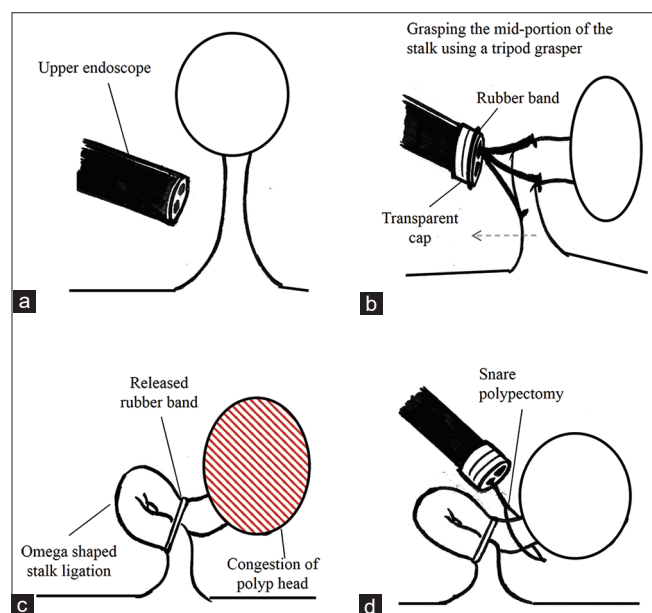


Figure 1: Schematic showing the endoscopic band ligation–associated colonic polypectomy technique. (a) Endoscope-equipped with a rubber band to be deployed at the target polyp. (b) Tripod forceps grasping the middle part of the stalk with suction and application of the ligation band. (c) The ligation band is located in the middle of the stalk, which was inverted and ligated to create an omega shape. (d) Endoscopic snare polypectomy is performed just above the ligation band

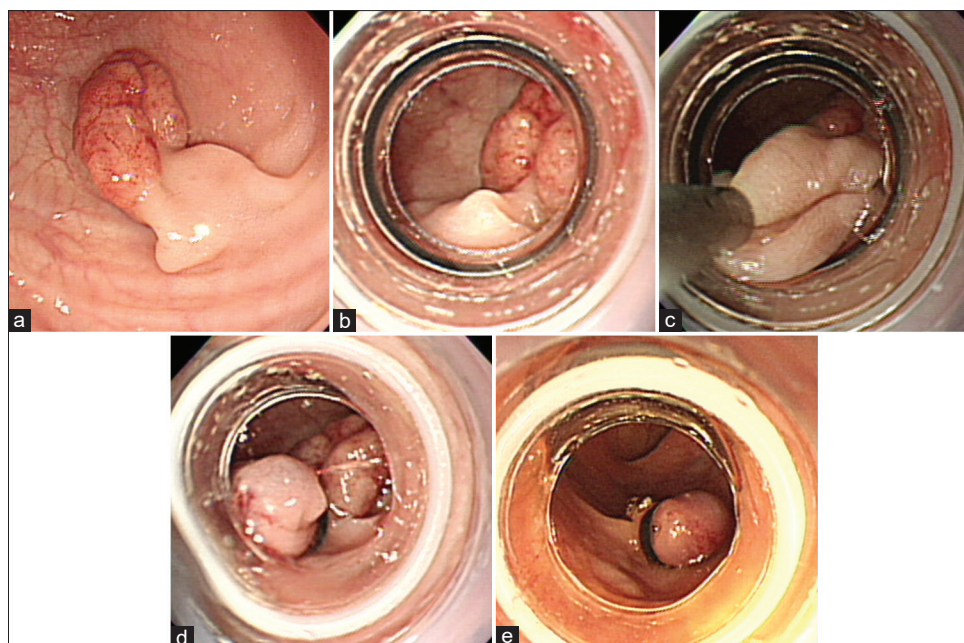


Figure 2: Endoscopic view of the endoscopic band ligation–associated colonic polypectomy. (a) A large pedunculated polyp with a long stalk. (b) Endoscopic view of the lateral side of the pedunculated polyp approach. (c) Tripod forceps are used to grasp the middle of the pedunculated polyp stalk, which is then pulled into the ligation device. (d) Endoscopic view of the ligated polyp stalk. (e) Endoscopic view after removal of the pedunculated polyp, with no hemorrhage visible at the polypectomy site

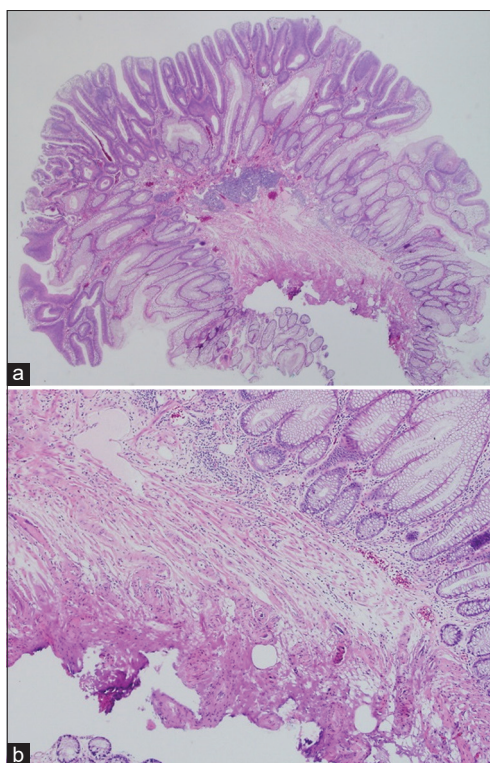


Figure 3: Histological view of a resected pedunculated polyp. The stalk was resected completely with clean margins by coagulation (hematoxylin and eosin stain, $\times 12$ (a), $\times 40$ (b))

The average total procedure duration for polyp removal was less than 10 min, except for one case. The larger the size of the head, the longer the procedure time was noted in this

study, which resulted from a voluminous head making it difficult to visualize the lesion endoscopically. Nevertheless, all the targeted colonic polyps were easily and successfully removed with EAP. There were no complications such as bleeding or perforation in any case. From our experience, this technique has many advantages including safety, ease of use, and high success rates for the treatment of large pedunculated polyps, regardless of stalk thickness, unlike endoloop procedure that has the limitation in the thickness of stalk of polyps.^[7]

As shown in Figures 1 and 2, the steps of the procedure in EAP are as follows: (1) turning from the front view of the polyp to the side, approaching the stalk of the pedunculated polyp of interest; (2) suction and traction of the stalk into the transparent cap with a tripod grasper until there is the blurring of endoscopic vision; (3) release of the band from the cap; (4) identifying the congested stalk by tight engagement of the rubber band; and (5) cutting the remaining exposed stalk above the ligation using a hot snare. The second step of the procedure, aspiration of the lesion into the cap, is an essential part like the EBL technique,^[12] because it is difficult to predict if the volume of captured stalk is enough to compress the feeding vessel. It is necessary that endoscopists feel some resistance on the passage of the stalk at the outer end of the cap during withdrawal of stalk, by continuously pulling the stalk until endoscopic vision is blurred. Insufficient suction would

Table 1: Characteristics of 17 large pedunculated polyps in 15 patients who underwent endoscopic band ligation-assisted polypectomy

Patient number	Polyp number	Location	Diameter of head (mm)	Diameter of stalk (mm)	Procedure time (s)	Histology	Resection margin	Complications
1	1	S-colon	15	12	329	TA c LGD	Negative	None
2	2	SDJ	10	10	453	TVA c LGD	Negative	None
3	3	S-colon	10	9	292	TA c LGD	Negative	None
3	4	S-colon	14	8	375	TA c LGD	Negative	None
4	5	S-colon	20	15	365	TA c HGD	Negative	None
5	6	S-colon	10	9	213	TA c LGD	Negative	None
5	7	S-colon	18	8	347	TA c LGD	Negative	None
6	8	S-colon	15	9	539	TA c LGD	Negative	None
7	9	S-colon	10	7	188	TA c HGD	Negative	None
8	10	S-colon	18	10	253	TVA c HGD	Negative	None
9	11	S-colon	23	8	609	TVA c HGD	Negative	None
10	12	S-colon	17	15	402	TA c LGD	Negative	None
11	13	S-colon	10	10	327	TA c LGD	Negative	None
12	14	S-colon	15	8	231	TA c LGD	Negative	None
13	15	S-colon	11	9	151	TA c LGD	Negative	None
14	16	S-colon	15	10	256	TA c HGD	Negative	None
15	17	S-colon	40	15	908	TVA c HGD	Negative	None

S-colon: Sigmoid colon; SDJ: Sigmoid-descending junction; TA c LGD: Tubular adenoma with low-grade dysplasia; TVA c LGD: Tubulovillous adenoma with low-grade dysplasia; TA c HGD: Tubular adenoma with high-grade dysplasia; TVA c HGD: Tubulovillous adenoma with high-grade dysplasia

make the rubber band slip off. The second important point is the positioning of the cap: correct positioning of the cap can avoid the unwanted chances of trapping the normal colon wall and head portion of the polyp to misinterpret the resected specimen, microscopically.

In our method, we used a tripod grasper to draw the targeted site of the stalk appropriately into the space within the cap, before EBL. We could confirm endoscopically choked stalks in addition to slippage of ligated bands until the end of the procedure. Other capture devices such as biopsy forceps are also available to grasp the stalk. Interestingly, we observed the change of stalk shape from originally linear to inverted, acutely angled, omega by EBL. This morphologic alteration may display more effective blocking of blood flow into the polyp with compression of the dual sites, than other

traditional methods blocking one site of blood flow into the polyp. EAP has another strength. From the point of the operating endoscopists, they can select the available hemostatic tools depending on the features of colon polyps including their location, size of the head, and thickness of the stalk as well as characteristics of subjects. Furthermore, this method has another advantage over the endoloop in the removal of thin-stalked polyp less than 8 mm, which is unwillingly dissected by mechanical force.^[8] In other words, EAP has the advantage in removing all polyps irrespective of the width of the stalk.

For executing this procedure, it is important for the endoscopist to use his own experience to be able to perform the various hemostasis methods. If an endoscopist is generally familiar with the EBL procedure for the treatment of variceal bleeding, it seems likely that the endoscopist may perform this procedure without difficulty. However, the learning curve of endoscopists is also necessary to master the technique and achieve satisfactory results.

This procedure has several limitations in clinical application. It cannot be applied in cases of pedunculated polyps with short length stalk (<10 mm) because of little space to grasp the stalk and in cases of insufficient visualization of the stalk due to large heads. Another drawback is the endoscope change from colonoscopy to upper endoscopy because of the absence of colonoscope-fitted EBL to shorten total procedure time. As the proximal colon is unreachable by upper endoscopes, we performed EAP only in patients with left-sided polyps. Besides, the development of a new device of a larger cap allowing to adapt to very thick stalks is also required.

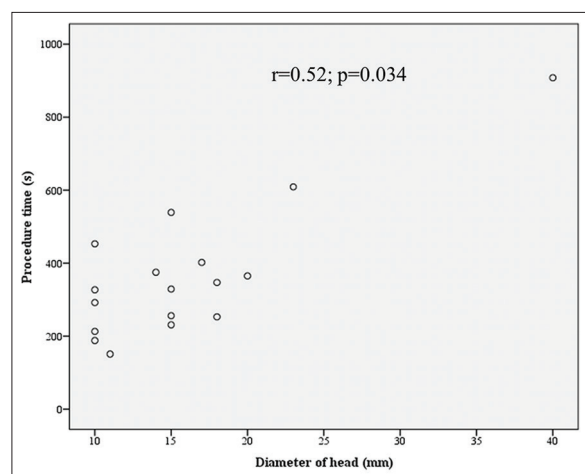


Figure 4: A positive Spearman correlation between procedure time and the diameter of the head ($\rho = 0.52$, $P = 0.034$)

In conclusion, we have described the use of band ligation for polypectomy of pedunculated colonic polyps. EAP appears to be an easy, safe, and effective technique for the prevention of PPB of pedunculated colonic polyps. These results should be confirmed in large-scale, prospective, controlled studies.

Financial support and sponsorship

Nil.

Conflicts of interest

There are no conflicts of interest.

REFERENCES

1. Fyock CJ. Colonoscopic polypectomy and associated techniques. *World J Gastroenterol* 2010;16:3630-7.
2. Dobrowolski S, Dobosz M, Babicki A, Glowacki J, Nalecz A. Blood supply of colorectal polyps correlates with risk of bleeding after colonoscopic polypectomy. *Gastrointest Endosc* 2006;63:1004-9.
3. Ferlitsch M, Moss A, Hassan C, Bhandari P, Dumonceau J-M, Paspatis G, *et al.* Colorectal polypectomy and Endoscopic mucosal resection (EMR): European society of gastrointestinal endoscopy (ESGE) clinical guideline. *Endoscopy* 2017;49:270-97.
4. Di Giorgio P, De Luca L, Calcagno G, Rivellini G, Mandato M, De Luca B. Detachable snare versus epinephrine injection in the prevention of postpolypectomy bleeding: A randomized and controlled study. *Endoscopy* 2004;36:860-3.
5. Kouklakis G, Mpoumpouraris A, Gatopoulou A, Efraimidou E, Manolas K, Lirantzopoulos N. Endoscopic resection of large pedunculated colonic polyps and risk of postpolypectomy bleeding with adrenaline injection versus endoloop and hemoclip: A prospective, randomized study. *Surg Endosc* 2009;23:2732-7.
6. Boo S-J, Byeon J-S, Park SY, Rew JS, Lee DM, Shin SJ, *et al.* Clipping for the prevention of immediate bleeding after polypectomy of pedunculated polyps: A pilot study. *Clin Endosc* 2012;45:84-8.
7. Katsinelos P, Kountouras J, Paroutoglou G, Beltsis A, Chatzimavroudis G, Zavos C, *et al.* Endoloop-assisted polypectomy for large pedunculated colorectal polyps. *Surg Endosc* 2006;20:1257-61.
8. Ji J-S, Lee S-W, Kim TH, Cho Y-S, Kim H-K, Lee K-M, *et al.* Comparison of prophylactic clip and endoloop application for the prevention of postpolypectomy bleeding in pedunculated colonic polyps: A prospective, randomized, multicenter study. *Endoscopy* 2014;46:598-604.
9. Matsushita M, Hajiro K, Takakuwa H, Kusumi F, Maruo T, Ohana M, *et al.* Ineffective use of a detachable snare for colonoscopic polypectomy of large polyps. *Gastrointest Endosc* 1998;47:496-9.
10. Moss A, Nalankilli K. Standardisation of polypectomy technique. *Best Pract Res Clin Gastroenterol* 2017;31:447-53.
11. Baron TH, Wong Kee Song LM. Endoscopic variceal band ligation. *Am J Gastroenterol* 2009;104:1083-5.
12. Ji JS, Cho YS. Endoscopic band ligation: Beyond prevention and management of gastroesophageal varices. *World J Gastroenterol* 2013;19:4271-6.
13. Iishi H, Tatsuta M, Narahara H, Iseki K, Sakai N. Endoscopic resection of large pedunculated colorectal polyps using a detachable snare. *Gastrointest Endosc* 1996;44:594-7.
14. Dobrowolski S, Dobosz M, Babicki A, Dymecki D, Hac S. Prophylactic submucosal saline-adrenaline injection in colonoscopic polypectomy: Prospective randomized study. *Surg Endosc* 2004;18:990-3.
15. Rutter MD, Nickerson C, Rees CJ, Patrick J, Blanks RG. Risk factors for adverse events related to polypectomy in the English bowel cancer screening programme. *Endoscopy* 2014;46:90-7.
16. Akahoshi K, Kubokawa M, Gibo J, Osada S, Tokumaru K, Shiratsuchi Y, *et al.* Endoscopic resection using the clutch cutter and a detachable snare for large pedunculated colonic polyps. *Endoscopy* 2017;49:54-8.
17. Brandimarte G, Tursi A. Endoscopic snare excision of large pedunculated colorectal polyps: A new, safe, and effective technique. *Endoscopy* 2001;33:854-7.
18. Akahoshi K, Kojima H, Fujimaru T, Kondo A, Kubo S, Furuno T, *et al.* Grasping forceps assisted endoscopic resection of large pedunculated GI polypoid lesions. *Gastrointest Endosc* 1999;50:95-8.
19. Averbach M, Hashiba K, Corrêa P, Cutait R, Rossini G, Paccos JL, *et al.* Use of a homemade nylon loop for the prevention of postpolypectomy bleeding of large pedunculated polyps. *Surg Laparosc Endosc Percutan Tech* 2005;15:275-8.
20. Mizukami T, Hiroyuki I, Hibi T. Anchor clip technique helps in easy prevention of post-polypectomy hemorrhage of large colonic polyps. *Dig Endosc* 2010;22:366-9.
21. Akahoshi K, Yoshinaga S, Fujimaru T, Kondoh A, Higuchi N, Furuno T, *et al.* Endoscopic resection with hypertonic saline-solution-epinephrine injection plus band ligation for large pedunculated or semipedunculated gastric polyp. *Gastrointest Endosc* 2006;63:312-6.
22. Carmo J, Marques S, Chapim I, Barreiro P, Bispo M, Chagas C. Elastic band ligation for the removal of a colonic tubular adenoma in a diverticulum. *Endoscopy* 2015;47(Suppl 1 UCTN):E490-1.