

Case report

Primary bladder angiosarcoma synchronous with prostatic acinar adenocarcinoma in an 82-year-old male

Cătălina Paranici^{*1}, Sanda Achim¹, Valentin Enache^{1,2}, Marina Bara²

¹Department of Pathology, Floreasca Emergency Hospital, Bucharest, Romania; ²Department of Pathology, Victor Babes Institute, Bucharest, Romania

Abstract

Primary bladder angiosarcoma is a rarely encountered and poorly described malignancy. Only 34 cases have been described in the English literature according to PubMed, accounting for only 2% of the genitourinary soft tissue sarcomas and 0.6% of all bladder tumors. We report a case of a primary angiosarcoma of the urinary bladder in an 82-year-old patient and present the clinical history, histopathological and immunohistochemical features of this tumor, in order to provide better understanding of the diagnosis, possible therapies and clinical outcome.

Keywords: *bladder angiosarcoma; acinar adenocarcinoma; prostate*

Introduction

Angiosarcomas primarily involving the bladder are exceedingly rare and poorly characterized malignancies, with only 34 cases being described in the English literature according to PubMed [1, 2], accounting for only 2% of the genitourinary soft tissue sarcomas [3] and 0.6% of all bladder tumors [4].

First case of primary angiosarcoma of the bladder was described by Jungano F. in 1907 [5], most of these tumors occurring in male patients, with an average of 55 years [6]. Some of them had a history of radiotherapy for previous pelvic cancer, cigarette smoking, or exposure to vinyl chlorides [3].

This is a highly aggressive tumor that carries a very poor prognosis, the five-year survival rates reported to be 10% to 35% [3].

We report a case of primary angiosarcoma of urinary bladder in an 82-year-old man, with synchronous prostatic acinar adenocarcinoma, describing the clinical presentation and follow-

up, the histopathological and immunohistochemical features, as well as providing a brief discussion on the potential pit-falls and main differential diagnosis of this rare entity.

Case report

We present the case of an 82-year-old male who was admitted to hospital with diffuse abdominal pain, abnormal colonic transit, dysuria/nycturia and weight loss.

An abdominal and pelvic ultrasound was performed that revealed a hyperechoic image measuring 31 mm on the right lateral wall of the bladder that protruded into the bladder lumen. No invasion into the adjacent tissues was described. An enlarged prostate having a maximum diameter of 47 mm, with a diffusely heterogenous aspect and a hypoechoic image of 23 mm on the right lateral side was also described.

Cystoscopy examination revealed a bladder tumor, measuring 4/4 cm with long papillary surface and a narrow base, located on the right lateral wall. Transurethral resection of bladder tumor (TURBT) was performed and samples of tumor fragments were sent for histopathological examination.

Received: October 2020; Accepted after review: January 2021; Published: January 2021.

*Corresponding author: Cătălina Paranici, Department of Pathology, Floreasca Emergency Hospital, Calea Floreasca 8, București 014461, Romania
Email: catalina.panciu@yahoo.com



Microscopically, the neoplastic proliferation presented as fused stratified papillae with marked cellular disorder, cells with pleomorphic nuclei, prominent nucleoli and numerous mitoses. The findings were consistent with the diagnosis of high-grade non-invasive papillary urothelial carcinoma. Post-surgical evolution was favorable. The following treatment included bladder lavage (24h after surgery), Epirubicin injections (3rd day after surgery) and removal of the bladder catheter (4th day after surgery).

Three months following the transurethral curettage, the patient was again admitted with abdominal pain with radiation to the lumbar region, pain and swelling of the right testicle. Ultrasound examination reported a 53 mm diameter of the prostate with heterogenous density and epididimitis. Transurethral resection of the prostate (TURP) and bilateral orchidectomy was performed.

Histological examination of the fragments from *veru montanum* region revealed a malignant process with a pseudosarcomatous aspect, composed of markedly pleomorphic, discohesive cells, a high mitotic activity, and tumor necrosis. The diagnosis was favorable for sarcomatoid urothelial carcinoma. The fragments of prostate biopsy presented benign nodular hyperplastic lesions, but no invasive

tumor. Orchiepididymitis and vascular thrombi were found in the testis.

Another three months later the patient presented with complete urine retention. Cystoscopy revealed tumor recurrence and the ultrasonography found a 74/64 mm bladder tumor, with a wall thickness of 12 mm on the right and posterior wall of the bladder, and an increased sized prostate with a diameter of 51 mm. Radical cystoprostatectomy was performed.

At gross examination a 7/4/3 cm bladder tumor was found that extended through the right and posterior bladder wall invading the perivesical tissue, the prostatic lobes and the urethral resection margin. For histology the bladder was thoroughly sampled, including prostate and seminal vesicles.

Microscopic examination showed an extensively invasive, high-grade neoplasm involving the bladder wall (Figures 1A and 1B), invading the full thickness of muscularis propria and perivesical adipose tissue but also the stroma of both prostatic lobes. Distal urethral resection margin of the prostate and of the bladder wall were involved by invasive tumor. Numerous lympho-vascular tumoral emboli extensive tumor necrosis and hemorrhage were observed.

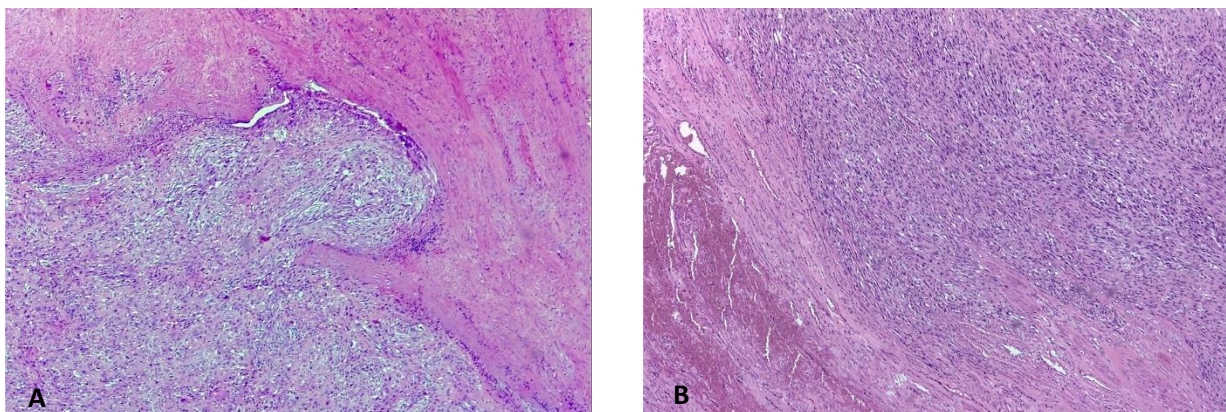


Fig. 1. Histological features of angiosarcoma of the bladder. **A, B.** Low-power view of an invasive, high-grade spindle-cell neoplasm infiltrating through the bladder wall (HE, 50X),

The tumor presented a wide spectrum of morphological features, with some solid areas resembling poorly differentiated urothelial carcinoma with malignant cells forming sheets or nests without evidence of lumen formation, a mixture of spindle and epithelioid cells were

found in other areas (Figures 2A and 2B), also with squamous components, and large areas showed more pronounced vascular differentiation with anastomosing, angular, blood-filled spaces lined by hyper-chromatic malignant cells (Figures 2C and 2D).

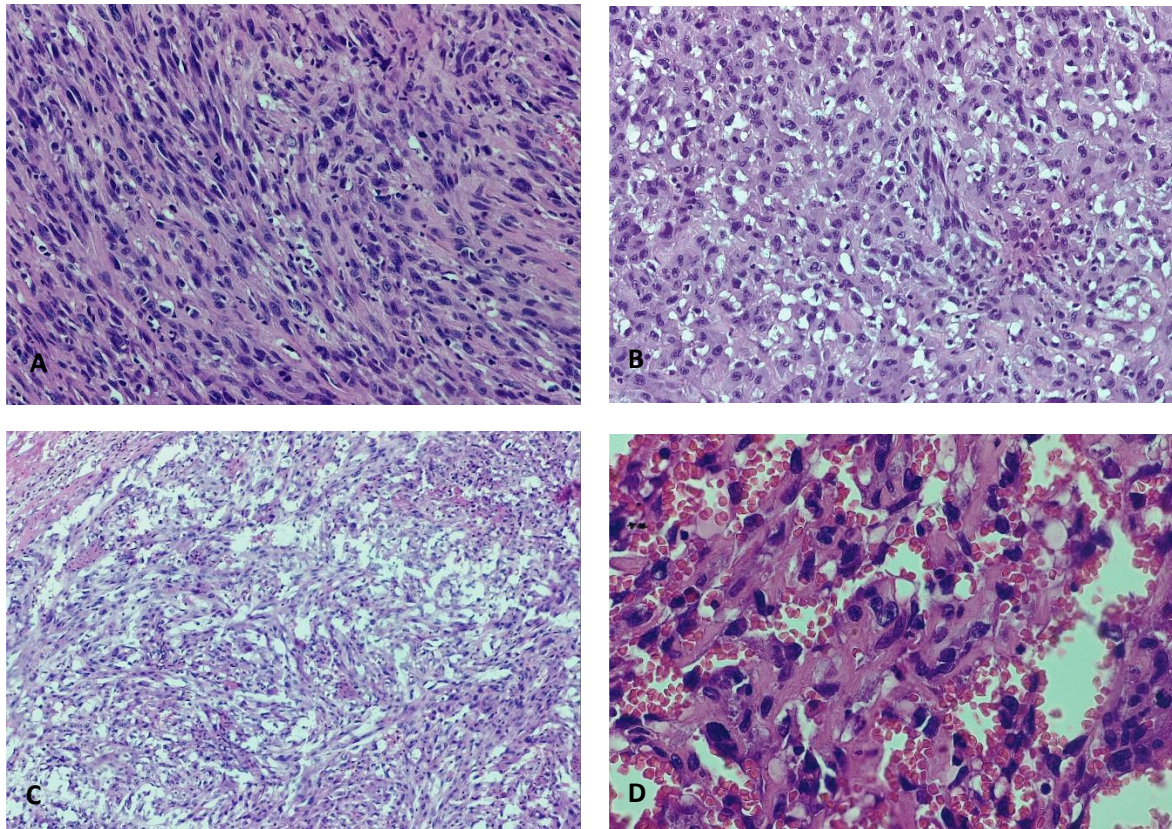


Fig. 2. Histological features of angiosarcoma of the bladder: **A, B.** Morphological features including spindle and epithelioid pleomorphic cells (HE, 200X). **C, D.** High-power view of anastomosing blood-filled channels lined by atypical, hyperchromatic, endothelial cells (HE, 100X and 400X),

An associated prostatic acinar adenocarcinoma (Gleason score 3+4=7, Grade group 2) was diagnosed invading the left seminal vesicles and presenting perineurial infiltration (Figure 3).

Immunohistochemical stains showed expression of vascular markers CD31, CD34 (Figures 4A and 3B) in the tumor cells, patchy positivity for cytokeratin AE1/AE3 (Figure 4C) and negativity for p63 (Figure 4D). These findings were consistent with the diagnosis of angiosarcoma.

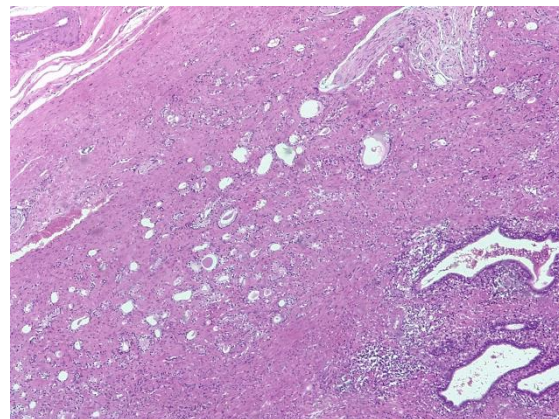


Fig. 3. Prostatic acinar adenocarcinoma (HE, 50X)

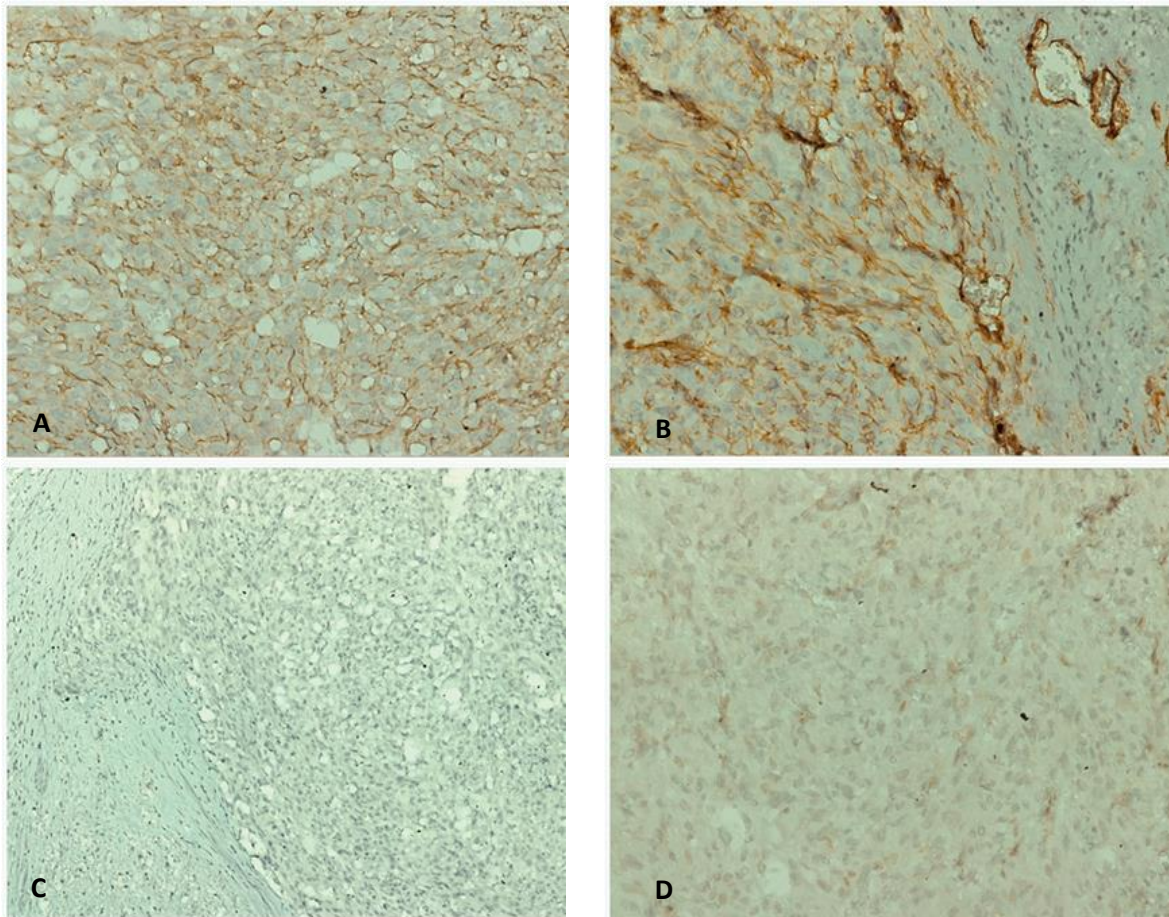


Fig. 4. Immunohistochemical stains: Diffuse expression of CD31 (**A**) and CD34 (**B**) in tumor cells (IHC, anti-CD31 and anti-CD34 Abs, 200X). Weak expression of CK AE1/AE3 (**C**) and negative p63 (**D**) in neoplastic cells (IHC, anti-cytokeratin AE1/AE3 and anti-p63 Abs, 100x and 200X, respectively).

Discussions

The rarity of the angiosarcoma primarily involving the urinary bladder makes the diagnosis of this malignancy easy to be overlooked, but this entity must be considered especially in older patients with remote history of abdominopelvic radiation therapy presenting with hematuria and dysuria [7, 8].

Awareness in the variability of the morphological aspects in a bladder angiosarcoma is very important, as features can be misleading, especially in small biopsy specimens, a situation that initially occurred in our current case. The most important feature of this tumor is blood-filled vascular channels lined by malignant endothelial cells as seen in "classical angiosarcomas", but solid architecture with spindle cells or even a predominant epithelioid morphology may be encountered [1-3, 9].

Therefore, one must keep in mind the main differential diagnosis of angiosarcomas, (hemangioma, Kaposi's sarcoma, poorly differentiated or sarcomatoid urothelial carcinoma and metastatic melanoma) and use appropriate immunohistochemical panel of stains to make the correct diagnosis. This is an extremely important issue, as angiosarcomas display a more aggressive behavior, with early hematogenous spread and a propensity for local spread and distant metastases and consequently therapeutic approaches are substantially different [3].

The treatment for angiosarcomas of the bladder doesn't have an accepted gold-standard because of its rarity. Yet, an aggressive therapeutical approach similar to that used for soft tissue sarcomas with other locations (i.e., head and neck and extremities) that include radical surgery, with achievement

of optimal surgical margins, chemotherapy, and radiotherapy is required [3, 10].

The current case was also difficult to assess because of the extensive involvement of both the prostate gland and inferior bladder wall with infiltration of the urethral surgical margin, making it difficult to determine the exact primary site of origin.

Because of large tumor size, increased stage or metastatic disease at presentation (most of the angiosarcomas are at least muscle invasive when diagnosed) [10] and also high-grade features and increased likelihood of lympho-vascular tumoral emboli, long-term survival in patients with genitourinary sarcomas tend to be very poor [3, 4], as in the case of this patient who passed away one month after the cysto-prostatectomy was performed.

Conclusions

Angiosarcoma of the bladder, which arises from blood vessel endothelium, is an exceedingly rare and poorly characterized entity which carries a very poor prognosis.

References

1. Wang G, Black PC, Skinnider BF, Hayes MM, Jones EC. Post-radiation epithelioid angiosarcoma of the urinary bladder and prostate. *Can Urol Assoc J* 2016; 10(5-6):E197-E200.
2. Matoso A, Epstein JI. Epithelioid Angiosarcoma of the Bladder: A Series of 9 Cases. *Am J Surg Pathol* 2015; 39(10):1377-82. PMID: 25929352.
3. Nizam A, Paquette EL, Wang BG, Aragon-Ching JB. Epithelioid angiosarcoma of the bladder: A case report and review of the literature. *Clin Genitourin Cancer* 2018; 16(6):e1091-e1095 doi: 10.1016/j.clgc.2018.07.010.
4. Moch H, Cubilla AL, Humphrey PA, Reuter VE, Ulbright TM. The 2016 WHO Classification of Tumors of the Urinary System and Male Genital Organs, World Health Organization; 4th Edition, Lyon, IARC, 2016.
5. Jungano F. Sur un cas d'angiosarcome de la vessie. *Ann Mal Organes Genitourinaires* 1907; 25:1451-64.
6. Lott S, Lopez-Beltran A, Montironi R, MacLennan GT, Cheng L. Soft tissue tumors of the urinary bladder Part II: malignant neoplasms. *Hum Pathol* 2007; 38(7):963-977. doi: 10.1016/j.humpath.2007.03.016. PMID: 17574946.
7. Warne RR, Ong JS, Snowball B, Vivian JB. Primary angiosarcoma of the bladder in a young female. *BMJ Case Reports* 2011; 2011. DOI: 10.1136/bcr.11.2010.3484.
8. Tavora F, Kryvenko ON, Epstein JI. Mesenchymal tumors of the bladder and prostate: an update. *Pathology* 2013; 45(2):104-15. doi: 10.1097/PAT.0b013e32835c768b. PMID: 23250042.
9. Abbasov B, Munguia G, Mazal PR, et al. Epithelioid angiosarcoma of the bladder: report of a new case with immunohistochemical profile and review of the literature. *Pathology* 2011; 43(3):290-3. PMID: 21436648.
10. Bahouth Z, Masarwa I, Halachmi S, Nativ O. Primary angiosarcoma of urinary bladder: 13th reported patient. *Case Rep Oncol Med* 2015; 2015:652870. doi: 10.1155/2015/652870. PMID: 25688314.

The present case describes a primary angiosarcoma of the bladder with synchronous prostatic acinar adenocarcinoma in a patient without known risk factors. Despite aggressive treatment including radical cysto-prostatectomy and adjuvant therapy, the tumor presented a rapid progression and the patient succumb to disease shortly after the diagnosis, an evolution that mirrors that of angiosarcomas originating in other sites.

Recognizing this malignancy earlier as a different entity, even on small biopsy fragments, could improve the outcome of these patients to a very great extent.

Consent

Written informed consent was obtained from the patient for publication of this case report and accompanying images. A copy of the written consent is available for review by the Editor-in-Chief of this journal.

Competing interests

The authors declare that they have no competing interests.

