



ELSEVIER

Contents lists available at ScienceDirect

JSES International

journal homepage: www.jsesinternational.org

Higher failure rate of suture anchors in partial distal biceps tendon ruptures in comparison with Endobutton fixation

Elisabeth Wörner, MD^{a,b,*}, Iris van Oost, MSc^a, Denise Eygendaal, Prof. Dr.^{a,b}, Bertram The, Dr.^a

^aDepartment of Orthopaedic Surgery, Amphia Hospital, Breda, The Netherlands

^bDepartment of Orthopaedic Surgery, Amsterdam UMC, Amsterdam, The Netherlands

ARTICLE INFO

Keywords:

Complications
Cortical button
Endobutton
Distal biceps tendon
Elbow
Heterotopic ossifications
Rupture
Partial tear
Rerupture

Level of evidence: Level III; Retrospective Cohort Comparison; Treatment; Study

Background: Little is known about the preferred repair technique of partial tears of the distal biceps tendon. In this study, suture anchors were compared with the Endobutton technique for repair of partial distal biceps tendon ruptures, especially regarding failure rate.

Methods: A total of 59 patients with 62 partial distal biceps ruptures underwent surgical treatment between 2008 and 2019. Repair of the partially ruptured distal biceps tendon was performed using suture anchors ($n = 21$) or an Endobutton ($n = 41$). Postoperative evaluation consisted of integrity and physical examination of the distal biceps tendon, range of motion, stability, neurologic status, and radiographs in AP view and lateral direction of the elbow.

Results: At a median follow-up of 14 (1–82) months in all patients, a total of 5 patients had a rerupture of the reconstructed distal biceps tendon (8.1%). A significant higher rerupture rate was seen in the suture anchor group ($n = 4$) than in the Endobutton group ($n = 1$) ($P = .04$). The other outcome measures were similar between groups. Other than rerupture rate, there were complications in 21 patients (34%). The major symptomatic complication was attributed to lateral antebrachial cutaneous nerve neuropraxia ($n = 8$, 15%). Heterotopic ossifications were seen in 12 patients (34%), and ossifications were symptomatic in 4 of these patients (33%).

Conclusion: A significantly higher failure rate was seen after repair of a partial distal biceps rupture using suture anchors than by using an Endobutton technique. Overall, both techniques were accompanied with complications, in particular, lateral antebrachial cutaneous nerve neuropraxia and the formation of heterotopic ossifications, though clinically less relevant than a rerupture.

© 2021 The Author(s). Published by Elsevier Inc. on behalf of American Shoulder and Elbow Surgeons.

This is an open access article under the CC BY-NC-ND license

(<http://creativecommons.org/licenses/by-nc-nd/4.0/>).

A rupture of the distal biceps tendon is a relatively uncommon injury. It represents only 3% of all tendon lesions with an incidence of 1.2–5.4 per 100,000 patients per year.²⁹ Partial tears are even more uncommon and have not been intensively studied before. The natural history of partial tears is poorly understood, and optimal treatment is not yet well defined. Ruptures of the distal biceps tendon are commonly seen in the dominant elbow of middle-aged, active men.^{3,37} The injury mechanism is typically an eccentric muscle contraction against a heavy load in a semiflexed position.³⁶ The same injury mechanism can cause partial tears, but a chronic degenerative tendinosis can also develop into a partial tear – either with or without an acute onset.²² Partial tears mimic the same

symptoms of a complete rupture, but are in most cases less painful and less loss of supination strength. Generally, the biceps tendon remains palpable in the antecubital fossa, which can result in a negative “Hook test”.^{10,35}

The initial treatment approach of partial tears of the distal biceps tendon is different from complete tears. Nonoperative treatment of a complete tear generally leads to functional loss of supination and flexion strength of the elbow.³³ Therefore, surgery is indicated unless the patient is low-demanding or not medically fit for surgery.⁶ In partial tears, the initial treatment consists of a period of rest and avoidance of aggravating activity. In many cases, this approach is combined with braces, a peritendinous intrabursal steroid injection and physical therapy. However, conservative treatment has a high failure rate, and surgery is indicated if conservative therapy is ineffective, if there is persistent pain, and loss of supination power.⁷ Surgical debridement and reattachment of the tendon should be performed, especially when the partial rupture is >50% of the tendon.^{4,17}

Institutional review board approval was not required for this study.

* Corresponding author: Elisabeth Wörner, MD, Orthopaedic Department, Amphia Hospital Breda, Molengracht 21, 4818 CK, Breda, The Netherlands.

E-mail address: lworner@amphia.nl (E. Wörner).

<https://doi.org/10.1016/j.jseint.2021.02.012>

2666-6383/© 2021 The Author(s). Published by Elsevier Inc. on behalf of American Shoulder and Elbow Surgeons. This is an open access article under the CC BY-NC-ND

Surgical fixation of distal biceps rupture is primarily aimed to restore functional supination strength. It would seem desirable to restore the native anatomic insertion of the biceps tendon to the radial tuberosity. However, a recent study could not elucidate the clinical relevance of exact anatomic restoration of the distal end of the biceps.⁹ Repair with the Endobutton (EB) has shown to have good mechanical properties in complete ruptures. The failure rate ranged from 1.2% to 5.6%.^{5,23,32,38,39} Prior studies could not find a statistical difference between different techniques but do show a trend toward a lower failure rate of the EB technique compared with suture anchors in complete ruptures.^{1,13} To date, there is no consensus about the preferred operative technique for the repair of partial distal biceps tendon ruptures.⁸

Complications after repair of complete ruptures can be the formation of heterotopic ossifications (9.5%–23%), neurapraxia of the lateral antebrachial cutaneous nerve (LACN) (6.9%), and posterior interosseous nerve (PIN) palsy (1.1%).^{2,14,21,25} The rerupture rate is around 1.5% after primary repair of distal biceps tendon ruptures.²¹ In partial ruptures, the complications and rerupture rate has not been extensively studied. A systematic review reported the following complications: neuropraxia of the LACN (17%), PIN palsy (6%), elbow discomfort (2%), surgical revision (2%), and asymptomatic heterotopic ossification (1%).⁸

The purpose of this study is to compare the EB technique with suture anchors (SA) for primary repair of partial distal biceps tendon ruptures. This study is the first study that compares different surgical techniques for the repair of partially ruptured distal biceps tendons. Our hypothesis is that fixation with an EB through a bone tunnel (ToggleLoc; Biomet, Warsaw, IN, USA) has fewer reruptures compared with suture anchors (Superquick DS Anchors) in partial ruptures.^{16,30}

Methods

Patients and study design

A search of the medical surgical database was performed to identify all patients who underwent primary repair of a partial distal biceps tendon rupture with either suture anchors or an EB, between January 1, 2008 and September 1, 2019. A total of 64 surgical reports were reviewed along with follow-up clinic notes. Exclusion criteria were a different surgical technique, patients younger than 18 years, revision surgery, or no follow-up visits after surgery. Demographic information included sex, age at surgery, date of surgery, technique of repair, clinical evaluation before and after surgery, and documented complications (symptomatic and asymptomatic).

The indication for surgery consisted of physical examination, loss of supination strength, loss of supination range, and pain. Preoperative physical examination of the elbow consisted of range of motion (ROM), assessment of stability, performing the “Hook test,” Popeye sign, pain on palpation of the insertion of the biceps, pain with resisted supination, and pain with resisted pronation.^{28,34,42} The ROM was measured with a goniometer by an orthopedic surgeon. Additional imaging for diagnosis was used in 90% (n = 56) of the patients to examine the partially ruptured distal biceps tendon, consisting of either magnetic resonance imaging (MRI) (n = 53, 95%) and/or ultrasound (n = 14, 25%). A tear of more than 50% was thought to be an indication for surgery and persisting pain and loss of supination power after a trial of conservative therapy.⁴ In all patients, radiographs (anterior-posterior and lateral) of the affected elbow were obtained before surgery to rule out other pathology that could be causing the pain or restrictions in range of motion and to assess the osseous anatomy of the proximal

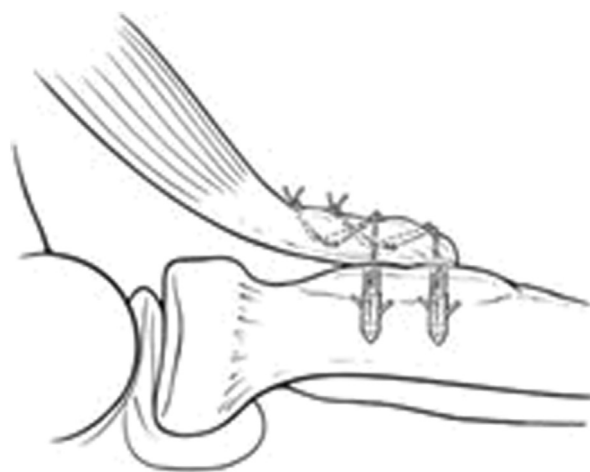


Figure 1 Suture anchor technique

radius. The decision whether patients would undergo repair with SA or an EB was surgeon-based.

Surgical techniques

All patients underwent surgery to restore the partial ruptured distal biceps tendon. The surgical treatment patients received was either with a suture anchor (SA) (Superquick DS Anchor; DePuy Mitek, Raynham, MA, USA) or an EB (ToggleLoc; Biomet, Warsaw, IN, USA).¹⁶ One surgeon (DE) only performed repairs with the EB (n = 37), whereas the other surgeon (BT) did repairs with both EB (n = 3) and SA (n = 21). One patient was operated by a third surgeon (CB) with an EB (n = 1).

The techniques are both an anterior single-incision technique. The patient was placed in supine position with the forearm in full supination on a surgical hand table. The arm was routinely prepared and draped from shoulder to hand, and a sterile tourniquet was applied. A longitudinal incision was made 1 cm distal of the elbow skin crease to distal. The LACN was identified and protected. Blunt dissection onto the proximal radius was performed with protection of the radial nerve. Visualization of the radial tuberosity was performed by releasing the tissue from ulnar to radial, without the usage of a levered retractor, a Hohman, but with direct-pull retractors. The PIN was protected by supinating the forearm and directing the guide pin in an ulnar/proximal direction, never in a distal or radial direction. The quality of the distal biceps tendon was identified to assess if a graft would be necessary. The initial steps were similar for both techniques, but the repair of the partial tear is significantly different between techniques.

In the SA technique (Fig. 1), the torn part of the tendon was freed from adhesions to be preserved for repair. Its end was sutured with a nonabsorbable thread, OrthoCord (DePuy Orthopaedics Inc., Warsaw, IN, USA). The suture anchors were inserted onto the footprint (tuberositas radii), and the orthocord was braided into the tendon for re-fixation. Only one cortex was drilled, and thus, injury to the PIN could be avoided which runs in the vicinity of the overlying cortex. This construction was then gradually pulled into position on the tuberosity with the elbow flexed to 90°. The forearm was maintained in a forcibly supinated position when the sutures were tightened. The anchoring pins were always inserted in the most posterior part of the tuberosity to gain maximum leverage.⁹

In the EB technique (Fig. 2), after the initial steps as described previously, the partial tear was completed to allow adequate

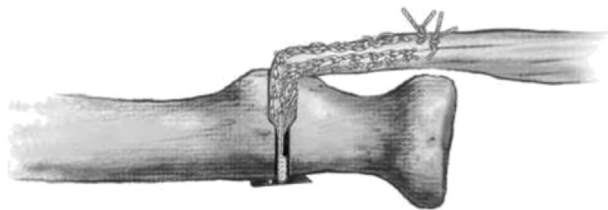


Figure 2 Endobutton technique.

fixation of the tendon with the EB – different from the suture anchor technique where the original tendon was preserved. A guide wire was drilled into the anatomic insertion location of the biceps tendon (tuberositas radii) from ventral to dorsal, but aiming just slightly proximal and ulnar to angle away from the PIN with the arm in full supination. A 4.5-mm cannulated drill was advanced over the guide wire, through the posterior cortex. The drill tunnel was created in a nonanatomic position shifting the insertion toward the anterior side to prevent injury to the PIN when drilling the second cortex. The anterior cortex was drilled based on the size of the tendon. Fixation of the button on the distal biceps tendon was performed with an OrthoCord suture. The button was pulled through the radius with a Beath pin to pass the sutures. The button was engaged to the posterior cortex and locked into place. The fixation was tested, and intraoperative fluoroscopy was used to confirm the correct position of the button. The passing sutures were removed.

Rehabilitation protocol

The rehabilitation protocol did not differ between surgical techniques. Postoperatively, a long arm cast was applied for 1 week. An oral nonsteroidal anti-inflammatory drug – meloxicam or indomethacin – was routinely prescribed for 1 week or 3 weeks, respectively. In total, 21 patients received a prescription for indomethacin for 3 weeks, and 35 patients received meloxicam for 1 week. This is owing to a change in protocol in 2016 for preventive measurements on heterotopic ossifications (of which consensus is lacking to date in the current literature).^{20,24} Physical therapy was started after 1 week. Both passive and active ROM exercises were allowed. Patients were advised to prevent flexion against resistance for the first 3 months. After 3 months, patients could resume normal activities, as before the biceps tendon injury.

Postoperative protocol

Standard postoperative protocol, similar between groups, was evaluation 6–8 weeks after surgical repair. Evaluation consisted of ROM, strength, and neurologic status of the elbow, and all patients had intraoperative radiographs (anterior-posterior and lateral direction) to assess button or anchor position. Postoperative radiographs (> 6 weeks) were not taken routinely. The physical examination was performed by a board-certified orthopedic surgeon. Pronation and supination strength were tested manually. Radiographs were performed in most patients – this was not standard protocol – to identify heterotopic ossifications or other osseous complications.

Medical ethics committee approval

After review of the protocol, the Medical Ethics Committee of Amphia Hospital (Breda, The Netherlands) gave approval (N2019-0253) to start the study.

Statistical analysis

Statistical analysis (SPSS 20.0; IBM Corp., Armonk, NY, USA) was performed using the Fisher exact test to compare categorical data. The independent T-test and the Mann-Whitney U test were used to compare numerical data between groups. Nonparametric tests were used when the data were not normally distributed. A *P* value less than .05 was considered to denote significance. For description of the patient population, only the first examination of a biceps tendon tear was used in patients with bilateral biceps tendon tears.

Results

In total, 64 patients had a surgical repair of the distal biceps tendon after a partial tear, either with SAs or EB; of them, 5 patients were lost to follow-up and excluded from further analysis. The remaining 59 patients had 62 distal biceps ruptures. Three patients had a partial rupture of the biceps tendon in both elbows.

The patients were predominantly men (85%). The mean age was 49.9 (\pm 1.2) years at the time of surgery, and the dominant arm was involved in 61% of the patients. The majority of the patients (63%) had physical intensive job (ie, painter, carpenter, heavy truck transport). During physical examination, the hook test was considered positive in 39% of the patients. In 46 patients (74%), palpation at the insertion of the distal biceps tendon at the tuberosity radii was painful. No statistical differences in preoperative physical examination (ROM, stability, pain on palpation of the insertion distal biceps, Hook test, Popeye sign) were seen between groups. Patients, in both groups, mainly complained of loss of flexion and supination strength or pain in the antecubital fossa.

The median follow-up of all patients was 14 (1–82) months after surgery. The range of follow-up was rather wide but not significantly different between groups (*P* = .07). In total, 36 patients had a postoperative follow-up of more than 12 months. The median follow-up for this group was 20 (12–82) months, similar between groups (*P* = .2).

The mean ROM of the elbow was postoperative 130.4 (\pm 3.0) degrees and was not different between groups (*P* = .2). Grafts were used in 4 patients, when the biceps tendon showed too much degeneration intraoperatively. All 4 of these patients had a repair with an EB.

The intraoperative radiograph of all patients identified a good position of the anchors or EB. In 34 (55%) patients, postoperative radiographs of the elbow were obtained after 6–8 weeks. HOs were seen on 12 of the 32 radiographs (38%). An EB was used in twelve of the thirteen patients with heterotopic ossifications seen on postoperative radiographs. In total, 4 patients had symptomatic HO (33%); all had a DBT repair with an EB. Two of those patients had pain and restrictions in postoperative ROM, whereas the other 2 only had persistent pain. Postoperative radiographs after 6–8 weeks were not routinely taken, and significantly more postoperative radiographs were taken in the EB group (*P* = .01).

In 22 patients (35%), symptomatic complications were seen postoperatively as shown in [Table 1](#); this was similar between groups (*P* = .78). Complications included neuropraxia LACN, rerupture, pain, symptomatic HO, and PIN palsy.

In total, 9 patients (15%) had an LACN neuropraxia palsy, which resolved in all patients within 2–8 months. One patient (1.6%) had a transient PIN palsy that resolved 2 months after surgery. All nerve injuries resolved with an expectant approach. In total, 4 patients had persisting pain postoperatively that all resolved with physical therapy and an expectant approach.

A major complication was the rerupture rate of 5 of 62 patients (8.1%), diagnosed through physical examination combined with MRI. A significant higher rerupture rate (*n* = 4) was seen in the SA group

Table 1
Characteristics of the Endobutton group versus the suture anchor group.

	Endobutton N = 41 (SD)	Suture anchor N = 21 (SD)	P value
Characteristics			
Mean age at surgery (yr)	48.3 (1.4)	53.1 (2.2)	.06
Gender (% male)	36 (88)	17 (81)	.47
Follow-up (mo)	14 (1-82)	6 (1-42)	.07
Follow-up >12 mo	20 (12-82)	20 (12-42)	.2
Affected side			
Dominant arm (%)	25 (61)	16 (76)	.5
Cause of injury			
Acute trauma (%)	20 (49)	8 (38)	.4
Outcome measurements			
ROM: flexion arc in degrees	127.37 (3.57)	135.00 (3.16)	.2
Radiographs (%) >4 week after operation	28 (68)	6 (29)	<.01*
HO (%)	11 (29)	1 (5)	.6
Rerupture	1	4	.04*
Rerupture rate follow-up > 12 mo	0	4	.02*

HO, heterotopic ossifications; LACN, lateral antebrachial cutaneous nerve; ROM, range of motion; SD, standard deviation; %, percentage.

Values are numbers (percentages) for categorical variables and mean (SD) for continuous variables unless stated otherwise.

*significance ($P < .05$).

than in the EB group ($n = 1$) ($P = .04$). The patient group with a follow-up of more than 12 months had a similar rerupture rate: 3 of 36 (8.3%). In this group, all 3 reruptures were seen in the SA group, resulting in a statistically significant difference to Endobutton group ($P = .02$). The rerupture of the Endobutton procedure occurred 5 months after surgery by a sudden catch of a falling object. The patient underwent revision with an EB. The reruptures of patients treated with suture anchors were not preceded by a trauma. In one patient, suture anchors failed and were detached from the bone after 10 months. The other patient had persisting elbow pain and loss of 30 degrees of supination after 2 months because of a high-grade rerupture. The other 2 patients complained of persisting pain 3 months after surgery, and the MRI showed a minor partial rupture of the distal biceps tendon. The treatment of the reruptures was different between patients. Three of 4 patients with a primary repair with suture anchors underwent revision with an EB. One patient was successfully treated conservatively with intrabursal infiltration with kenacort and lidocaine (4:1) and physical therapy.

Discussion

The present study focused on the optimal repair technique for partial distal biceps tendon ruptures. The most important finding of this study is the high rerupture rate of the SA procedure (19%). A rerupture can be the effect of a failure of the surgical technique (lack of adequate tendon tissue, inadequate initial attachment, very tight repair) or a poorly compliant patient who forcibly flexes or supinates against resistance in the early postoperative period. In this study, the one rerupture primarily reconstructed with an EB was caused by patient compliance. The patient tried to catch a heavy falling object (a child). The reruptures after the repair with suture anchors were not caused by a trauma (or patient compliance) but failure of the repair technique and insufficient bone ingrowth of the tendon. In prior research, the failure rate in partial tears has not been studied intensively. Studies showed rather satisfactory results after repair of partial distal biceps ruptures.^{8,12,15,40} Frazier et al¹⁷ described 1 failure of 17 patients (5.9%) 4 years after primary repair, the initial repair of this patient consisted of a suturing technique only (no anchors or screws). Another study showed good results with repair of partial distal biceps tendon ruptures with suture anchors; all patients returned to pre-morbid duties within 6 months of surgery.⁴⁰ Mainly the failure rate of complete distal biceps tendon ruptures has been studied. EBs have shown to provide a good biomechanical construction and biology for restoration of complete distal biceps tendon ruptures.¹²

Hinchey et al²¹ describes a rerupture rate of 1.5% in complete tears, all patients had a rerupture within 3 weeks, and the rerupture appeared to be a result from patient compliance issues and the exposure of the repairs to excessive force. A biomechanical comparison between EBs and SAs showed a 16% higher failure load in favor of the EB. However, this difference did not reach significant difference, and the study was performed in complete tears.

The surgical techniques differ in many ways. In the SA procedure, the original (partially ruptured) tendon is maintained, and it is used for attachment to the tuberosity. Partial tears are often chronic tears and the quality of the distal part of the tendon is thereby often altered.³¹ In the EB technique of partial tears, the partially torn tendon was a completed and the whole tendon was taken down. The button rests on the cortical bone on the dorsal aspect of the radius, which results in a strong biomechanical construction with the tendon. This may be beneficial for the healing process that is not solely dependent on the hypovascular and degenerated distal end of the tendon, such as in repair with a suture anchor.³⁷ Thus, an EB repair may provide a more optimal tendon refixation in partial tears with good strength and little change on rerupturing, compared with SAs. There are to date no biomechanical studies that evaluate the strength of the repair in partial tears to compare these results. Future studies should be conducted in a prospective manner to assess the difference in both techniques.

In this study, we have seen a total symptomatic complication rate of 35%. The most frequent symptomatic complication that was seen was paresthesia of the LACN. An anterior approach has been associated with a number of the nerve injuries that were caused by prolonged retraction against the brachioradialis muscle placing concentrated pressure on the PIN and LACN palsies.^{2,20} In our study, the neuropraxia was transient in all cases. The PIN is a nerve at risk during the operation because of the bone tunnel that is created bicortically. In a prior study, PIN palsy occurred in 3.2% of the patients after primary distal biceps repair of complete ruptures.³³ One study even showed a higher incidence of PIN palsy and LACN paresthesia in repairs of partial distal biceps tendons ruptures when matched to complete tears.³⁶ In our study, we did observe only one injury to the PIN. This may be owing to precautionary measures taken by the highly specialized (elbow) orthopedic surgeons during the operation, as described previously in the procedure section.

Heterotopic ossifications were seen on 12 of the 34 (35%) postoperative radiographs, 4 of these patients had symptomatic HO (ROM restriction). In our postoperative findings, 12 of 13 cases with

HO have been reconstructed with an EB. This is a relatively high incidence compared with prior research.¹ However, postoperative radiographs in the present study were not taken routinely, and significantly more postoperative radiographs were taken in the EB group. Thus, we cannot conclude in this study that the EB procedure has a correlation with the formation of HO. Kodde et al^{26,27} described the occurrence of 23% of HO on postoperative radiographs after using the EB technique. A prior study in complete ruptures showed no difference in HO formation between SA or EB refixation.¹¹ A single-incision is thought to lead to fewer heterotopic ossifications, but a conclusive answer to this question is pending.¹⁹ Further research is necessary to correlate the occurrence of heterotopic ossification after distal biceps tendon refixation to a specific technique or incision in (partial) distal biceps tendon repair.

Physical examination was not always conclusive for a partial tears and imaging of the distal biceps tendon was necessary, similar to prior studies.⁴⁰ MRI was the primary method for the diagnosis and to differentiate among bursitis, tendinitis, and normal anatomy. Many patients had a physical intensive job (ie, painter, carpenter, heavy truck transport). This may be important for the development of tendinosis into a (partial) rupture of the distal biceps tendon. It is known that bicipitoradial bursitis occurs frequently in association with partial tearing and that chronic inflammation of the adjacent bicipitoradial bursa may be contributory to distal biceps tendon ruptures.^{18,41}

The strength of the present study is the relatively large number of patients with a repair after partial distal biceps tendon (it is a relatively rare phenomenon). We describe one of the major concerns when repairing a tendon: a rerupture. The present study also has its limitations in addition to its retrospective nature. The mean follow-up was relatively short but not significantly different between groups. All patients were seen at the outpatient clinic after 6–8 weeks. Correcting for follow-up time of more than 12 months did not affect the outcomes of our study. Our clinic is a major referral centre for elbow injuries in the Netherlands. We think that if patients would have had problems with their elbows, they would have come back to us or referred back to us by other physicians. Second, not all patients had postoperative radiographs, and thus, asymptomatic heterotopic ossifications may be missed, especially in the SA group. Third, the repair with suture anchors was performed by only 1 surgeon and the EB technique was performed by all surgeons. All surgeons in the study are board-certified orthopedic and highly experienced elbow surgeons, thus we do not think there is a surgeon-based bias. Finally, our study lacks subjective results such as the Mayo Elbow Performance Index and the Disabilities of the Arm, Shoulder and Hand scores because it was a retrospective study and not all scores could be collected.

We recommend the use of the EB technique in partial distal biceps ruptures because of the high failure rate of SAs in our study. A prospective randomized clinical trial or biomechanical study should be performed to compare both techniques with little bias and to collect postoperative outcome data such as (objective) strength measurements and postoperative radiographs in all patients.

Conclusion

The failure rate of repair of the partial distal biceps rupture was 8% in all patients in both techniques. This study reveals a significantly higher failure rate in SAs than in EB. Complications other than failure rate were not different between techniques. Therefore, the EB repair with complete take down of the distal biceps tendon is the technique of choice in partial distal biceps tendon ruptures.

Disclaimers:

Funding: No funding was disclosed by the author(s).

Conflicts of interest: The authors, their immediate families, and any research foundations with which they are affiliated have not received any financial payments or other benefits from any commercial entity related to the subject of this article.

References

1. Amarasooriya M, Bain GI, Roper T, Bryant K, Iqbal K, Phadnis J. Complications after distal biceps tendon repair: A systematic review. *Am J Sports Med* 2020;48:3103–11. <https://doi.org/10.1177/0363546519899933>.
2. Amin NH, Volpi A, Lynch TS, Patel RM, Cerynik DL, Schickendantz MS, et al. Complications of distal biceps tendon repair: A meta-analysis of single-incision versus double-incision surgical technique. *Orthop J Sport Med* 2016;4:1–5. <https://doi.org/10.1177/2325967116668137>.
3. Anakwenze OA, Baldwin K, Abboud JA. Distal biceps tendon repair: An analysis of timing of surgery on outcomes. *J Athl Train* 2013;48:9–11. <https://doi.org/10.4085/1062-6050-48.1.10>.
4. Bain GI, Johnson LJ, Turner PC. Treatment of partial distal biceps tendon tears. *Sports Med Arthrosc* 2008;16:154–61. <https://doi.org/10.1097/JSA.0b013e318183eb60>.
5. Bain GI, Prem H, Heptinstall RJ, Verhellen R, Paix D. Repair of distal biceps tendon rupture: A new technique using the Endobutton. *J Shoulder Elbow Surg* 2000;9:120–6.
6. Baker BE, Bierwaghen D. Rupture of the distal tendon of the biceps brachii. Operative versus non-operative treatment. *J Bone Joint Surg - Ser A* 1985;67:414–7.
7. Bauer TM, Wong JC, Lazarus MD. Is nonoperative management of partial distal biceps tears really successful? *J Shoulder Elbow Surg* 2018;27:720–5. <https://doi.org/10.1016/j.jse.2017.12.010>.
8. Behun MA, Geeslin AG, O'Hagan EC, King JC. Partial Tears of the Distal Biceps Brachii Tendon: A Systematic Review of Surgical Outcomes. *J Hand Surg Am* 2016;41:e175–89. <https://doi.org/10.1016/j.jhsa.2016.04.019>.
9. Bellringer SF, Phadnis J, Human T, Redmond CL, Bain GI. Biomechanical comparison of transosseous cortical button and Footprint repair techniques for acute distal biceps tendon ruptures. *Shoulder Elbow* 2020;12:54–62. <https://doi.org/10.1177/1758573218815312>.
10. Bourne MH, Morrey BF. Partial rupture of the distal biceps tendon. *Clin Orthop Relat Res* 1991;143–8.
11. Cain RA, Nydick JA, Stein MI, Williams BD, Polikandriotis JA, Hess AV. Complications following distal biceps repair. *J Hand Surg Am* 2012;37:2112–7. <https://doi.org/10.1016/j.jhsa.2012.06.022>.
12. Chavan PR, Duquin TR, Bisson LJ. Repair of the ruptured distal biceps tendon: A systematic review. *Am J Sports Med* 2008;36:1618–24. <https://doi.org/10.1177/0363546508321482>.
13. Citak M, Backhaus M, Seybold D, Suero EM, Schildhauer TA, Roetman B. Surgical repair of the distal biceps brachii tendon: A comparative study of three surgical fixation techniques. *Knee Surgery. Sport Traumatol Arthrosc* 2011;19:1936–41. <https://doi.org/10.1007/s00167-011-1591-0>.
14. Cusick MC, Cottrell BJ, Cain RA, Mighell MA. Low incidence of tendon rerupture after distal biceps repair by cortical button and interference screw. *J Shoulder Elbow Surg* 2014;23:1532–6. <https://doi.org/10.1016/j.jse.2014.04.013>.
15. Dellaero DT, Mallon WJ. Surgical treatment of partial biceps tendon ruptures at the elbow. *J Shoulder Elbow Surg* 2006;15:215–7. <https://doi.org/10.1016/j.jse.2005.08.020>.
16. DiRaimo MJ, Maney MD, Deitch JR. Distal biceps tendon repair using the Toggle Loc with Zip Loop. *Orthopedics* 2008;31:1201. <https://doi.org/10.3928/01477447-20081201-05>.
17. Frazier MS, Boardman MJ, Westland M, Imbriglia JE. Surgical Treatment of Partial Distal Biceps Tendon Ruptures. *J Hand Surg Am* 2010;35:1111–4. <https://doi.org/10.1016/j.jhsa.2010.04.024>.
18. Fritz RC, Steinbach LS, Tirman PFJ, Martinez S. MR imaging of the elbow: An update. *Radiol Clin North Am* 1997;35:117–44.
19. Garon MT, Greenberg JA. Complications of Distal Biceps Repair. *Orthop Clin North Am* 2016;47:435–44. <https://doi.org/10.1016/j.oct.2015.10.003>.
20. Grewal R, Athwal GS, MacDermid JC, Faber KJ, Drosdowech DS, El-Hawary R, et al. Single versus double-incision technique for the repair of acute distal biceps tendon ruptures: A randomized clinical trial. *J Bone Joint Surg* 2012;94:1166–74. <https://doi.org/10.2106/JBJS.K.00436>.
21. Hinchey JW, Aronowitz JG, Sanchez-Sotelo J, Morrey BF. Re-rupture rate of primarily repaired distal biceps tendon injuries. *J Shoulder Elbow Surg* 2014;23:850–4. <https://doi.org/10.1016/j.jse.2014.02.006>.
22. Hobbs MC, Koch J, Bamberger HB. Distal Biceps Tendinosis: Evidence-Based Review. *J Hand Surg Am* 2009;34:1124–6. <https://doi.org/10.1016/j.jhsa.2009.01.001>.
23. Idler CS, Montgomery WH, Lindsey DP, Badua PA, Wynne GF, Yerby SA. Distal biceps tendon repair: A biomechanical comparison of intact tendon and 2 repair techniques. *Am J Sports Med* 2006;34:968–74. <https://doi.org/10.1177/0363546505284185>.

24. Joice M, Vasileiadis GI, Amanatullah DF. Non-steroidal anti-inflammatory drugs for heterotopic ossification prophylaxis after total hip arthroplasty. *Bone Joint J* 2018;100B:915-22. <https://doi.org/10.1302/0301-620X.100B7.BJ-2017-1467.R1>.
25. Kodde IF, Baerveldt RC, Mulder PGH, Eygendaal D, van den Bekerom MPJ. Refixation techniques and approaches for distal biceps tendon ruptures: A systematic review of clinical studies. *J Shoulder Elbow Surg* 2016;25:29-37. <https://doi.org/10.1016/j.jse.2015.09.004>.
26. Kodde IF, van den Bekerom MPJ, Eygendaal D. Best approach for the repair of distal biceps tendon ruptures. *World J Orthop* 2013;4:98-9. <https://doi.org/10.5312/wjo.v4.i2.98>.
27. Kodde IF, van den Bekerom MPJ, Eygendaal D. Reconstruction of distal biceps tendon ruptures with a cortical button. *Knee Surg Sport Traumatol Arthrosc* 2015;23:919-25. <https://doi.org/10.1007/s00167-013-2571-3>.
28. Koo JB, Shin DJ. Do You Know Popeye or Popeye Sign? *Ultrasound Med Biol* 2013;39:553-4. <https://doi.org/10.1016/j.ultrasmedbio.2013.02.259>.
29. Leighton M, Bush-Joseph C, Bach B. Distal biceps brachii repair: Results in dominant and nondominant extremities. *Clin Orthop Relat Res* 1995;317:114-21.
30. Lintner S, Fischer T. Repair of the distal biceps tendon using suture anchors and an anterior approach. *Clin Orthop Relat Res* 1996;116-9.
31. Luokkala T, Siddharthan SK, Karjalainen TV, Watts AC. Distal biceps hook test – Sensitivity in acute and chronic tears and ability to predict the need for graft reconstruction. *Shoulder Elbow* 2020;12:294-8. <https://doi.org/10.1177/1758573219847146>.
32. Mazzocca AD, Burton KJ, Romeo AA, Santangelo S, Adams DA, Arciero RA. Biomechanical evaluation of 4 techniques of distal biceps brachii tendon repair. *Am J Sports Med* 2007;35:252-8. <https://doi.org/10.1177/0363546506294854>.
33. Nigro PT, Cain R, Mighell MA. Prognosis for recovery of posterior interosseous nerve palsy after distal biceps repair. *J Shoulder Elbow Surg* 2013;22:70-3. <https://doi.org/10.1016/j.jse.2012.08.001>.
34. O'Driscoll SW, Goncalves LBJ, Dietz P. The hook test for distal biceps tendon avulsion. *Am J Sports Med* 2007;35:1865-9. <https://doi.org/10.1177/0363546507305016>.
35. Rantanen J, Orava S. Rupture of the distal biceps tendon. A report of 19 patients treated with anatomic reinsertion, and a meta-analysis of 147 cases found in the literature. *Am J Sports Med* 1999;27:128-32.
36. Ruch DS, Watters TS, Wartinbee DA, Richard MJ, Leversedge FJ, Mithani SK. Anatomic findings and complications after surgical treatment of chronic, partial distal biceps tendon tears: A case cohort comparison study. *J Hand Surg Am* 2014;39:1572-7. <https://doi.org/10.1016/j.jhsa.2014.04.023>.
37. Seiler JG, Parker LM, Chamberland PDC, Sherbourne GM, Carpenter WA. The distal biceps tendon. Two potential mechanisms involved in its rupture: Arterial supply and mechanical impingement. *J Shoulder Elbow Surg* 1995;4:149-56.
38. Sethi P, Obopilwe E, Rincon L, Miller S, Mazzocca A. Biomechanical evaluation of distal biceps reconstruction with cortical button and interference screw fixation. *J Shoulder Elbow Surg* 2010;19:53-7. <https://doi.org/10.1016/j.jse.2009.05.007>.
39. Spang JT, Weinhold PS, Karas SG. A biomechanical comparison of EndoButton versus suture anchor repair of distal biceps tendon injuries. *J Shoulder Elbow Surg* 2006;15:509-14. <https://doi.org/10.1016/j.jse.2005.09.020>.
40. Vardakas DG, Musgrave DS, Varitimidis SE, Goebel F, Sotereanos DG. Partial rupture of the distal biceps tendon. *J Shoulder Elbow Surg* 2001;10:377-9.
41. Williams BD, Schweitzer ME, Weishaupt D, Lerman J, Rubenstein DL, Miller LS, et al. Partial tears of the distal biceps tendon: MR appearance and associated clinical findings. *Skeletal Radiol* 2001;30:560-4.
42. Zwerus EL, Somford MP, Maissan F, Heisen J, Eygendaal D, Van Den Bekerom MP. Physical examination of the elbow, what is the evidence? A systematic literature review. *Br J Sports Med* 2018;52:1253-60. <https://doi.org/10.1136/bjsports-2016-096712>.