

Case Report

A Complex Renal Cyst: It Is Time to Call the Oncologist?

Antonio Granata,¹ Antonio Basile,¹ Giuseppe Alessandro Bruno,¹ Alberto Saita,¹ Mario Falsaperla,¹ Michele Figuera,¹ Maurizio Gallieni,² and Fulvio Floccari³

¹ Departments of Nephrology, Dialysis, Urology, and Radiology, AOU "Policlinico-Vittorio Emanuele", Catania, Italy

² Department of Nephrology and Dialysis, San Paolo Hospital and DMCO, University of Milano, Italy

³ Department of Nephrology and Dialysis, San Paolo Hospital, Civitavecchia, Italy

Correspondence should be addressed to Antonio Granata, antonio.granata4@tin.it

Received 21 January 2011; Accepted 15 March 2011

Academic Editor: James E. Springate

Copyright © 2011 Antonio Granata et al. This is an open access article distributed under the Creative Commons Attribution License, which permits unrestricted use, distribution, and reproduction in any medium, provided the original work is properly cited.

Introduction. Hydatid disease is a cyclozoontic parasitic infestation caused by the cestode *Echinococcus granulosus*. The cysts mainly arise in the liver (50 to 70%) or lung (20 to 30%), but any other organ can be involved, in abdominal and pelvic locations, as well as in other less common sites, which may make both diagnosis and treatment more complex. Isolated renal involvement is extremely rare. **Case Presentation.** We report a rare case of isolated renal hydatid disease in a 71-year-old man with a history of vague abdominal pain, anemia, fever, and microhematuria. Ultrasonographic examination revealed a complex cyst in the right kidney, including multiple smaller cysts with internal echoes. A magnetic resonance scan of the abdomen confirmed the findings, and hydatid cyst disease was diagnosed. Right nephrectomy was performed, and microscopic examination confirmed the diagnosis of hydatid cyst. Albendazole, 10 mg/kg per day, was given for 4 weeks (2 weeks preoperatively and 2 weeks postoperatively). **Conclusion.** Isolated primary hydatidosis of the kidney should always be considered in the differential diagnosis of any cystic renal mass, even in the absence of accompanying involvement of liver or other visceral organs.

1. Case Report

A 71-year-old man was admitted to our department for a prolonged history of asthenia, vague abdominal pain, fever, microhematuria, reduced renal function, and complex cystic mass on right native kidney at ultrasonography. He had a history of surgery for appendectomy (and physical examination revealed an incisional hernia), diabetes mellitus type 2, arterial hypertension (treated with ramipril 5 mg/day and atenolol 100 mg/day for three years), and recurrent urinary infections. Peripheral white blood cells count was of 11,400 cells/mL. 80% were neutrophils, while 18% were lymphocytes. Eosinophils were 0.5%. Patient showed normocytic anaemia: haemoglobin 9.8 gr/dL, MCV 80 fl.

A diagnosis of chronic renal failure in stage IIIB NKF was made: creatinine 1.8 mg/dL (0.7–1.5 mg/dL), eGFR 37 mL/min, sodium 136 mmol/L (136–145 mmol/L), potassium 4.4 mmol/L (3.4–4.5 mmol/L), Cl 96 mmol/L (96–108 mmol/L), and urea 81 mg/dL (20–50 mg/dL). Fasting

glucose was of 392 mg/dL (70–110 mg/dL). C-reactive protein appeared extremely high: 54 mg/L (0–5 mg/L).

Abdominal ultrasonography of the patient confirmed a large mass in the upper pole of right kidney (150 × 130 × 130 mm), with a wheels or honeycomb shape. A magnetic resonance revealed a heterogeneous, complex cystic mass on right native kidney (Figure 1). A right nephrectomy was indicated and performed. The surgical specimen weighted 415 g and measured 163 × 142 × 138 mm (Figure 2). The cut surface of the kidney revealed semisolid cystic lesions containing white-gray membranous structures. Histological examination revealed the lamellar membrane of the hydatid cyst. The serological tests for hydatid disease were negative.

Albendazole, 10 mg/kg per day, was given for 4 weeks (2 weeks preoperatively and 2 weeks postoperatively). The postoperative recovery was uneventful. The patient was discharged in good condition after nephrectomy (creatinine 1.8 mg/dL, eGFR 38 mL/min).

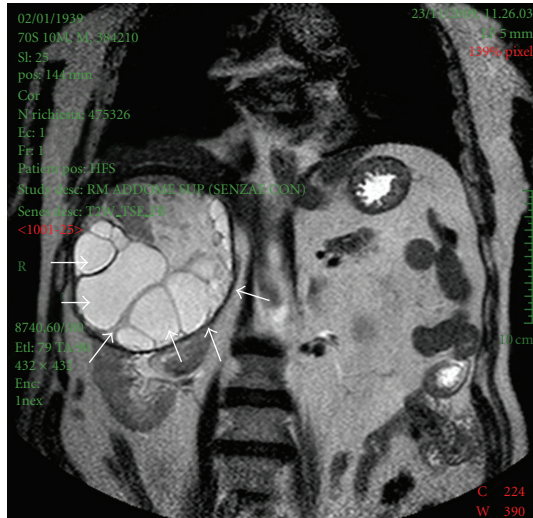


FIGURE 1: Magnetic resonance image showing the characteristic appearance of a hydatid cyst. Coronal T2 WI MRI shows marked hyperintensity with a hypointense rim (pericyst) of several daughter cysts that have less signal intensity than mother cyst.

2. Discussion

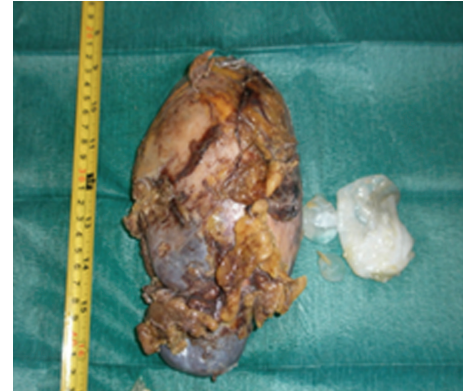
Echinococcosis or hydatid disease is a cyclozoonotic parasitic infestation caused by the cestode *Echinococcus granulosus* belonging to the order Cestoda and the family Taenia.

Human infestation is caused by larval form (about 5 mm long) and not by the adult form. This is found in the small intestine of dog and other canine species. Man is the intermediate host and gets the disease by ingesting contaminated vegetables and water.

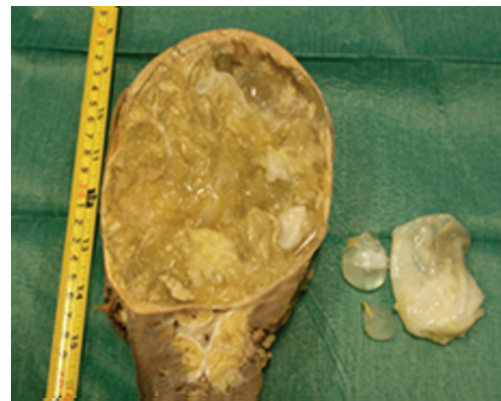Classical clinical presentation of the hydatid disease involves the liver in 50 to 70% cases and lung in 20 to 30%, but any other organ can potentially be involved. Secondary involvement due to the hematogenous dissemination may be seen in almost any anatomical location.

Although hydatid cysts can occur in any location, echinococcosis is usually found in the liver and the lung [1, 2]. Extrahepatic hydatidosis has been described in the peritoneal cavity, retroperitoneum, spleen, kidney, and adrenal glands and even in the spine, myocardium, and abdominal wall [1, 2]. Kidney involvement in echinococcosis is extremely rare. It is involved only in 2–3% of all cases, even in areas where hydatid disease is endemic [10], usually as a part of disseminated disease. Thus, isolated renal echinococcosis is rare and only few cases were reported in the literature [3].

Laboratory tests may suggest the diagnosis, which is confirmed by radiologic examination such as ultrasonography, computed tomography, and/or MRI [4]. Primary involvement of the kidney without the involvement of the liver and the lungs is a rare event [3]. Generally the renal hydatid cyst remains asymptomatic for years, and it is discovered incidentally. The most common symptoms, including flank pain, lumbar-abdominal mass, digestive symptoms, subcostal pain, abdominal distension, are nonspecific.



(a)



(b)

FIGURE 2: The excised organ (a) and the isolated hydatid renal cyst (b).

Cyst rupture with involvement of calyces and pelvis (also called communicating cyst) may cause microscopic hydatiduria, a pathognomonic but rare sign of hydatidosis. Hydatiduria can be found only in 10–20% of all cases of renal hydatidosis, and it is usually microscopic [3]. Eosinophilia also occurs only in 10–20% of all cases and is not specific. Hematuria is sometimes the presenting sign [5]. Radiologic examination is key for the diagnosis [4–6].

Plain abdominal radiography revealing curvilinear or speckled calcifications is nonspecific, but sometimes it shows a suggestive thin rim of calcification delineating the cyst. The diagnosis of the hydatid cyst of the kidney is based mainly on ultrasonography, CT, and/or MRI scan [7]. Ultrasonography is the most appropriate method for the differential diagnosis of renal cystic cancer, with a sensitivity of 95%. The most common classification of hydatid cysts, based on US features, includes five types [4–7]. In *type 1*, the hydatid cyst appears as a well-defined, anechoic lesion with posterior acoustic enhancement that may be undistinguishable from simple renal cysts. However, a double-contour thick wall or a history of living in endemic regions strongly suggests a diagnosis of hydatid cyst [4–8]. *Type 2* refers to a cyst with detached membrane or a floating membrane (the “water lily” sign is formed by the undulating membrane). *Type 3* is

characterized by septa and intraluminal daughter cysts. This US pattern can be misinterpreted as congenital polycystic disease of the kidney [9], but the diffuse and bilateral involvement of both kidneys in the latter may aid in the differentiation [9]. *Type 4* is a nonspecific solid mass, and the heterogeneous appearance of *type 4* should be differentiated from infected renal cysts, abscesses, and neoplasms [2–8, 10, 11]. Calcification, with a ringlike pattern, occurs in the pericystic layer of the wall of the hydatid cyst in *type 3, 4*, and *5* lesions [8]. However, the accuracy of ultrasound evaluation remains operator dependent.

CT scan usually demonstrates an expansible, hypoattenuating mass with a well-defined wall and daughter cysts within the parent cyst. The central part of the cyst has an attenuation of 30–35 HU, in contrast to the much lower attenuation of the fluid in the surrounding cysts (5–15 HU), giving the mass a wheel-like or rosette appearance [4–8].

MRI is considered an acceptable alternative to the CT scan in the diagnosis: hydatid fluid is hypointense on T1-weighted and hyperintense on T2-weighted images, although an heterogeneous signal intensity may also be detected on T1-weighted images. MRI reveals a multiple or solitary, high-signal intensity mass consisting of multiple thin-walled lesions and outlined by a thick, hypointense rim (Figure 1). The high fluid content of the mass gives a characteristic high-signal intensity in the central part of the cyst, whereas the peripheral zone is usually hypointense, compared to the centre of the lesion [7–9].

IV pyelography can show distortions of the upper urinary tract, with sign of compression or a nonfunctioning kidney, but this imaging technique is reserved only for selected cases [9, 12, 13].

Patient age, kidney function, and typology of cysts should be evaluated thoroughly to choose between medical and surgical treatments of renal hydatidosis. One month of albendazole treatment should be considered to sterilize the cyst, even when surgery is chosen as treatment strategy [14]. *Type 1* and *2* and some of *type 3* cysts are potential candidates for percutaneous US-guided treatment, and some of *type 3* and *type 4* cysts respond to albendazole treatment, at least becoming inactive and dormant.

Surgical options for renal hydatid cyst include total excision, partial nephrectomy, partial cystectomy, kidney-sparing surgery (cyst removal and pericystectomy), or nephrectomy for a completely damaged kidney. Laparoscopic removal of renal hydatid cyst can have some clinical advantages over traditional surgery, but risks of cyst rupture and dissemination during dissection, entrapment, and removal of the hydatid cyst during laparoscopy have been reported [4–9, 12–14].

3. Conclusion

In endemic areas nephrologists discovering complex cyst in a kidney should consider potential diagnosis of hydatid cyst. In fact clinical intuition can be crucial for correct and timely diagnosis, allowing prompt treatment and potentially saving a kidney.

References

- [1] K. Tepetes, G. Christodoulidis, M. Spryridakis, and K. Hatzitheofilou, "Large solitary retroperitoneal echinococcal cyst: a rare case report," *World Journal of Gastroenterology*, vol. 13, no. 45, pp. 6101–6103, 2007.
- [2] A. K. Tsaroucha, A. C. Polychronidis, N. Lyrantzopoulos et al., "Hydatid disease of the abdomen and other locations," *World Journal of Surgery*, vol. 29, no. 9, pp. 1161–1165, 2005.
- [3] M. O. Tan, L. Emir, C. Germiyanoglu, C. Uygur, U. Altug, and D. Erol, "Isolated renal and retroperitoneal hydatid cysts," *International Urology and Nephrology*, vol. 32, no. 1, pp. 41–46, 2000.
- [4] A. T. Turgut, K. Odev, A. Kabaalioglu, S. Bhatt, and V. S. Dogra, "Multitechnique evaluation of renal hydatid disease," *American Journal of Roentgenology*, vol. 192, no. 2, pp. 462–467, 2009.
- [5] C. Gögüş, M. Safak, S. Baltaci, and K. Türkölmez, "Isolated renal hydatidosis: experience with 20 cases," *Journal of Urology*, vol. 169, no. 1, pp. 186–189, 2003.
- [6] K. J. Shah, A. P. Ganpule, and M. R. Desai, "Isolated renal hydatid cyst managed by laparoscopic transperitoneal nephrectomy," *Indian Journal of Urology*, vol. 25, no. 4, pp. 531–533, 2009.
- [7] H. A. Gharbi, W. Hassine, M. W. Brauner, and K. Dupuch, "Ultrasound examination of the hydatid liver," *Radiology*, vol. 139, no. 2, pp. 459–463, 1981.
- [8] P. Polat, M. Kantarci, F. Alper, S. Suma, M. B. Koruyucu, and A. Okur, "Hydatid disease from head to toe," *RadioGraphics*, vol. 23, no. 2, pp. 475–494, 2003.
- [9] I. Sayek, M. B. Tirnaksiz, and R. Dogan, "Cystic hydatid disease: current trends in diagnosis and management," *Surgery Today*, vol. 34, no. 12, pp. 987–996, 2004.
- [10] J. M. Sarah, W. J. Christopher, and D. J. Waren Jr., "Parasitic diseases of the genitourinary system," in *Campbell-Walsh Urology*, A. J. Wein, L. R. Kavoussi, A. C. Novick, A. W. Partin, and C. A. Peters, Eds., pp. 458–459, Saunders, 9th edition, 2007.
- [11] P. Perimenis, A. Athanasopoulos, K. Gyftopoulos, and G. Barbalias, "Primary echinococcal disease of the kidney: the case for a more conservative approach," *International Urology and Nephrology*, vol. 32, no. 4, pp. 609–613, 2001.
- [12] P. Sountoulides, I. Zachos, S. Efremidis, A. Pantazakos, and T. Podimatas, "Nephrectomy for benign disease? A case of isolated renal echinococcosis," *International Journal of Urology*, vol. 13, no. 2, pp. 174–176, 2006.
- [13] I. Pedrosa, A. Saiz, J. Arrazola, J. Ferreirós, and C. S. Pedrosa, "Hydatid disease: radiologic and pathologic features and complications," *RadioGraphics*, vol. 20, no. 3, pp. 795–817, 2000.
- [14] S. Zmerli, M. Ayed, A. Horchani, I. Chami, M. El Ouakdi, and M. Riadh Ben Slama, "Hydatid cyst of the kidney: diagnosis and treatment," *World Journal of Surgery*, vol. 25, no. 1, pp. 68–74, 2001.