


Suppurative Meningitis Complicated with Arthritis Caused by Streptococcus Suis Infection: A Case Report

Bin Shen , Luyuan Tong, Jia Qiu, Jianfeng Zhong, Zhaowei Tong, Xiaofeng Li

Department of Infectious Diseases, Huzhou Central Hospital, Huzhou Key Laboratory of Precision Medicine Research and Translation for Infectious Diseases, Huzhou, Zhejiang Province, 313000, People's Republic of China

Correspondence: Xiaofeng Li, Department of Infectious Diseases, Huzhou Central Hospital, Huzhou Key Laboratory of Precision Medicine Research and Translation for Infectious Diseases, No. 1558, Sanhuan North Road Wuxing District, Huzhou, Zhejiang Province, 313000, People's Republic of China, Email xf_li0728@163.com

Background: *Streptococcus suis* (*S. suis*) is a common gram-positive bacterium in pigs. Its natural infection sites are the upper respiratory tract (especially tonsils and nasal cavity), reproductive tract and digestive tract of pigs. It is a new emerging human and animal disease. A co-morbid pathogen that can cause serious infections in humans, including meningitis, sepsis, septic arthritis, and sometimes deafness. No cases have been reported in Huzhou City, Zhejiang Province, China.

Case Presentation: A 50-year-old male patient who had worked as a butcher in a slaughterhouse for 20 years. Admitted to the hospital due to abdominal pain, joint pain, fever, and headache. His condition rapidly worsened causing altered consciousness, drowsiness and developed hearing loss. *S. suis* induced pyogenic meningitis complicated by arthritis was suspected based on the results of biochemical and culture analysis of the cerebrospinal fluid, and metagenomic next-generation sequencing. The patient's symptoms significantly improved after treatment with antibiotics such as ceftriaxone, meropenem, and linezolid, as well as supportive therapies including steroids and hyperbaric oxygen therapy, and his hearing improved significantly. After about 2 years of follow-up, the hearing was significantly better than before, but hearing impairment still remained.

Conclusion: *Streptococcus suis* is endemic in pork-consuming and pig-raising countries, but can occur throughout the world, especially among individuals with occupational exposure to pigs and/or pork, such as slaughterhouse workers, butchers, farmers, etc. Strengthen science education among key groups. This case was diagnosed as *Streptococcus suis* meningitis combined with arthritis. However, abdominal pain in the early stage of the disease is very rare and is easy to be misdiagnosed. It is necessary to identify whether it is complicated by peritonitis. For hearing loss caused by *Streptococcus suis* infection, the use of hyperbaric oxygen chamber treatment has obvious therapeutic effects.

Keywords: arthritis, hearing loss, hyperbaric oxygen therapy, meningitis, streptococcus suis

Introduction

Streptococcus suis is an emerging zoonotic pathogen, with the majority of cases reported globally originating from Thailand, followed by Vietnam. This bacterium can cause meningitis, sepsis, arthritis, endocarditis, endophthalmitis, etc. Hearing loss is the most common sequelae after recovery from purulent meningitis. The incidence range in China is wide, mostly sporadic, with complex causes and diverse forms, and is rarely seen in clinical work. Pyogenic meningitis complicated by arthritis caused by *Streptococcus suis* infection is a rare condition. This study reported the diagnosis and treatment process of one such patient admitted to the Huzhou Central Hospital. Further, we summarized and analyzed similar cases reported in previous studies to deepen our understanding of this disease.

Case Presentation

A 50-year-old male patient was admitted to the Infectious Disease Department of the Huzhou Central Hospital on February 26, 2021, due to “abdominal pain with joint pain for 1 day and fever with a headache for 11 h”. The patient’s abdominal pain is located under the xiphoid process in the upper abdomen, which is dull and intermittent and can be relieved by itself. The patient also complained of discomfort and pain in both knee and wrist joints, which were significantly aggravated during activity. The patient’s joint movement was restricted, and the lower limb muscle strength decreased. The patient developed a fever with a maximum temperature of 40.0°C 11 h before admission. The patient experienced chills prior to the fever but no shivering. The patient also had continuous headaches and discomfort characterized as throbbing, nausea, and vomiting with projectile water-like gastric contents. The patient went to the local health center for treatment, but the specific treatment details were unclear. No obvious improvement in symptoms was observed.

On February 26, 2021, the patient was transferred to our emergency department for further treatment. The blood routine from the emergency department revealed the following: white blood cell (WBC) count $4.9 \times 10^9/L$, neutrophil percentage 91.5%, hemoglobin level 140.0 g/L, platelet count $177.0 \times 10^9/L$, highly sensitive C-reactive protein level 176.4 mg/L, B-type natriuretic peptide level 162 pg/mL, D-dimer level 1570 ng/mL, blood potassium level 2.74 mmol/L, alanine aminotransferase level 52.9 U/L, aspartate aminotransferase level 47.0 U/L, and total bilirubin level 11.6 $\mu\text{mol/L}$. The cardiac ultrasound showed mild regurgitation of the mitral, tricuspid, and aortic valves. The head and chest computed tomography revealed no obvious abnormalities except for a small nodule in the right middle lobe of the lung and bilateral lower lobe exudation. The patient was admitted with a preliminary diagnosis of a “fever of unknown origin”. The patient denies any history of hereditary or infectious diseases in the family, and the family relationship is harmonious. The patient’s vital signs upon admission were as follows: body temperature 35.7°C, blood pressure 87/56 mm Hg, pulse rate 112 beats/min, and respiratory rate 20 breaths/min. The patient was conscious, partially responsive, somnolent, and mentally soft. The muscle tone was normal, and the tendon reflexes were present. The patient had positive neck resistance and positive bilateral Kernig’s and Brudzinski’s signs. Both wrists and knees were tender with restricted movement, but no local redness or swelling was observed. The lower limb muscle strength was of grade 4. No abnormalities were detected in cardiac and lung auscultation.

The patient was previously healthy and had been working as a butcher in a slaughterhouse for 20 years. The patient had a left index finger cut by a knife but did not receive proper disinfection or bandaging 2 days before the onset of the illness. The patient had long-term contact with sick and dead pigs. The diagnosis upon admission was infective fever, with intracranial infection as the primary consideration. On admission, the patient had low blood pressure, cold and clammy limbs, and profuse sweating. The antibiotic 2.0g ceftriaxone (February 26, 2021–February 27, 2021) was administered every 12 h intravenously for anti-infection treatment, and fluid supplementation was intensified. Meanwhile, liver protection and other treatments were given.

A lumbar puncture was performed on the second day of admission, and the cerebrospinal fluid (CSF) pressure was measured to be 300 mmH₂O (1 mmH₂O = 0.0098 kPa). The CSF was turbid and appeared like ground glass. The routine CSF cell count was $2.080 \times 10^9/L$, with multiple nuclei accounting for 80%, positive for the India ink test, and negative for *Cryptococcus*. The CSF biochemical analysis results were as follows: chloride level 122.5 mmol/L, glucose level 1.26 mmol/L, adenosine deaminase level 1.8 U/L, and protein level 4042.9 mg/L. The blood routine test showed a WBC count of $10.510 \times 10^9/L$, with neutrophils accounting for 90.6% and a high-sensitivity C-reactive protein level of 210.2 mg/L. The liver and kidney function electrolyte results were as follows: potassium level 4.16 mmol/L, alanine aminotransferase level 61.9 U/L, aspartate aminotransferase level 96.5 U/L, total bilirubin level 26.3 $\mu\text{mol/L}$, and procalcitonin level 63.84 ng/mL. The blood gas analysis results were as follows: oxygen partial pressure 58 mm Hg, blood pH 4.90, carbon dioxide partial pressure 26 mm Hg, and lactate level 1.6 mmol/L. The patient had significant headache and neck stiffness, with bilateral knee joint soreness and discomfort (Figure 1), decreased muscle strength in both lower extremities, and inability to lift them.

The initial diagnosis was purulent meningitis and bilateral knee arthritis. The patient’s condition was severe, and ceftriaxone was discontinued and replaced with meropenem 2.0g q8h (February 27, 2021–March 1, 2021) for stronger anti-infection treatment. Mannitol 20g q8h was administered to reduce intracranial pre

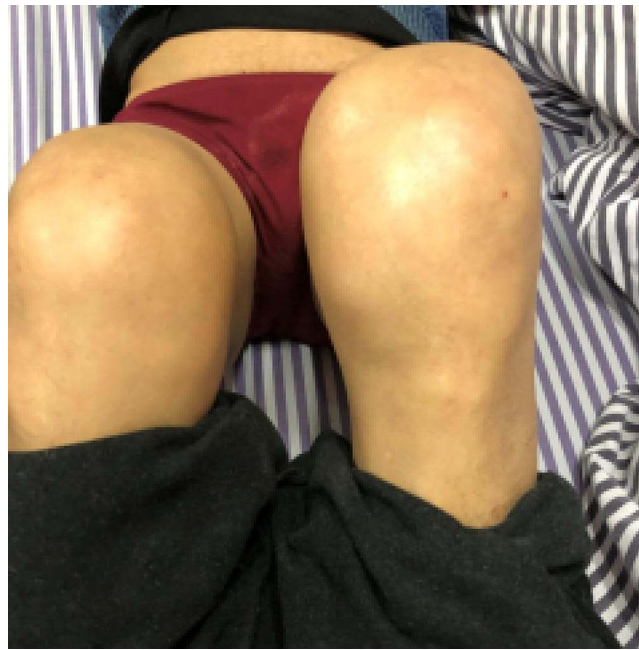

Figure 1 Swelling of both knee joints in the patient diagnosed with *S. suis* meningitis.

On the fourth day of admission, the patient's head still was swollen but had improved, and the knee joint soreness and limited mobility had also improved. The patient had a normal body temperature, clear consciousness, correct responses, dizziness, visual rotation, and unstable gait. Significant pain was felt upon flexing the knees, and swelling was observed in both knees. The muscle strength in both lower extremities was of grade 4, and the patient's mental state was still good. The neck resistance was positive, and Kernig's and Brudzinski's signs on both sides were negative.

On March 1, 2021, the patient's blood test results showed a red blood cell count as $3.51 \times 10^{12}/L$ and an ultra-sensitive C-reactive protein level as 40.6 mg/L. The electrolyte, liver and kidney function, lipid, and cardiac enzyme tests showed a WBC ratio of 1.15, alanine aminotransferase level 71.1 U/L, aspartate aminotransferase level 92.1 U/L, glutamyl transpeptidase level 174.1 U/L, lactate dehydrogenase level 269.7 U/L, total protein level 56.0 g/L, and albumin level 29.9 g/L. The patient's calcitonin level was 24.62 ng/mL, and the neutrophil alkaline phosphatase score was 144, with a positive rate of 75%.

A general bacterial and fungal culture and a routine drug sensitivity test were performed on the CSF after the fifth day of admission (March 2, 2021). The results indicated no fungal growth but showed the presence of *S. suis* (Figure 2). *S. suis* was found to be sensitive to clindamycin, penicillin, ceftriaxone, levofloxacin, ceftazidime, and vancomycin. However, it was resistant to tetracycline and erythromycin. On the same day, the next-generation sequencing results of the CSF showed that the number of sequences detected for *S. suis* was 57,722, and the number of sequences detected for the genus *Streptococcus* was 64,304. Additionally, it was discovered that the strain of *S. suis* was type II. The results of routine stool examination, occult blood test, self-antibody panel, and hepatitis A, B, and C were all normal, and the blood culture was negative. A color Doppler ultrasound of the lower extremities on March 1, 2021, showed unobstructed blood flow in the arteries and deep veins of both legs.

The patient was diagnosed with *S. suis* meningitis, a central nervous system infection. The inflammatory markers and symptoms significantly improved with treatment using 2.0 g ceftriaxone q12h (March 1, 2021-March 23, 2021) instead of meropenem for anti-infective therapy. Dizziness was treated symptomatically by adding dimenhydrinate.

Other CSF and relevant laboratory test results upon admission are depicted in Tables 1 and 2. On the seventh day of hospitalization, the patient's dizziness and headache improved, and the second lumbar puncture CSF culture turned negative. However, the patient developed hearing loss, tinnitus, and continued pain in both knees. Pure-tone audiometry showed moderate-to-severe hearing loss in the right and left ears, and distortion-product otoacoustic emission was not

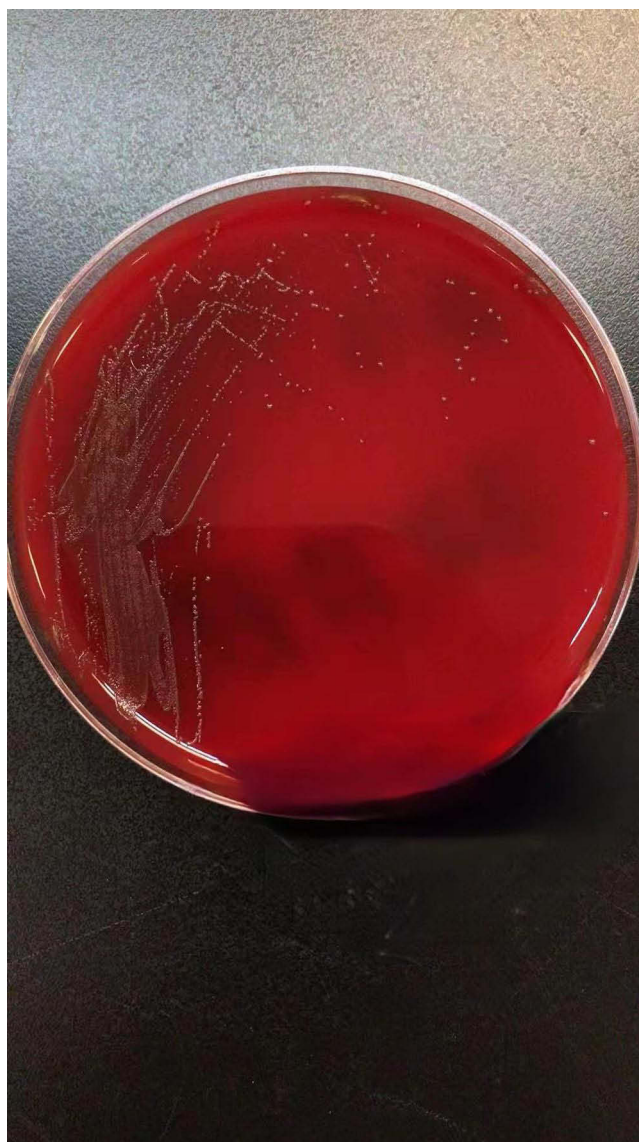

Figure 2 The colonies were medium in size, off-white in color, smooth, and rounded in shape on Columbia blood medium.

present in either ear. Methylprednisolone 80 mg qd was added for 5 days, and emicizumab 500 µg was administered intravenously once daily for symptomatic treatment. Joint ultrasound showed fluid accumulation in the left patellar bursa and a small amount of fluid in the right patellar bursa, with slightly thickened synovium in both knees. Joint effusion and

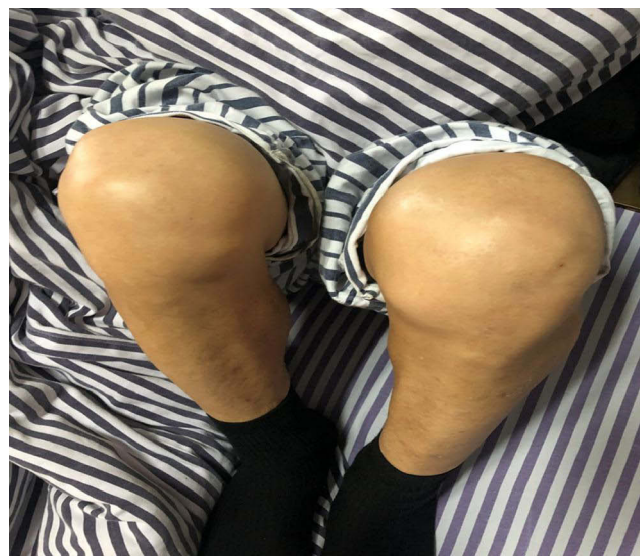Table 1 Changes in CSF Indicators in Patients

Date	Blood Pressure (mmH ₂ O)	Nucleated cell Count (×10 ⁹ /L)	Appearance	Pan's test	Polynuclear cells (%)	Adenosine Deaminase (U/L)	Protein (mg/L)	Glucose (mmol/L)	Chlorine (mmol/L)
2-27-2021	300	2.080	Hairy glass-like	Positive	80	1.8	4042.9	1.26	122.5
3-4-2021	175	0.020	Colorless and clear	Positive	50	3.7	1055.1	2.81	120.2
3-10-2021	150	0.060	Colorless and clear	Positive	22.0	0.9	563.9	2.83	122.8
3-16-2021	165	0.024	Colorless and clear	Positive	30	0.7	593.2	2.66	123.2
3-23-2021	225	0.100	Colorless and clear	Positive	25	2.6	821.6	2.7	130.2
3-31-2021	175	0.006	Colorless and clear	Weak Positive	/	0.6	456.5	2.77	124.9
4-12-2021	188	0.040	Colorless and clear	Positive	15	1.9	763.5	2.9	125.8
5-5-2021	220	0.00	Colorless and clear	Negative	/	2.0	530.0	3.76	128.0
9-8-2021	125	0.008	Colorless and clear	Weak Negative	/	0.5	394.0	3.4	126.7

Table 2 Changes in Laboratory Parameters of the Patient

Date	White Blood Cell Count ($10^9/L$)	Neutrophil (%)	Platelets ($10^9/L$)	High-Sensitivity C-Reactive Protein (mg/L)	Procalcitonin (ng/mL)
2-27-2021	10.5	90.6	193	210.2	63.84
3-1-2021	7.5	74.9	281	40.6	24.62
3-4-2021	7.2	67.8	593	1.2	2.13
3-10-2021	9.7	69.9	687	<0.5	0.12
3-18-2021	8.1	71.6	370	0.4	/
3-29-2021	10.6	70.1	373	<0.5	/
4-6-2021	10.0	60.3	353	<0.5	/
4-12-2021	9.2	67.9	273	<0.5	/
5-6-2021	8.8	76.1	387	0.9	/
9-9-2021	6.2	54.9	364	<0.5	/

mild joint pain were observed during walking, possibly related to *S. suis*-induced reactive arthritis. Etoricoxib (1 tablet/day) was added for treatment. The patient had a significant hearing loss on the 12th day after admission. The otolaryngology department recommended treatment with a hyperbaric oxygen (HBO) chamber. The swelling and pain of the knee joint improved, the movement was free, and the patient could walk on his own, and a re-examination of the knee joint ultrasound showed reduced joint effusion, as shown in [Figure 3](#). On March 18, 2021, a cranial computed tomography scan showed no obvious abnormalities. On March 23, the patient's condition worsened with elevated intracranial pressure, which measured 225 mmH₂O, and increased cell count and protein levels in the CSF. Therefore, the cephalosporin therapy was discontinued, and linezolid was initiated with a dose of 0.6 g intravenously every 12h (March 23, 2021-April 13, 2021) for enhanced anti-infective treatment. Despite the mild improvement in bilateral hearing, a cranial MRI on March 29 showed a small infarct in the left frontal lobe, as depicted in [Figure 4](#). The auditory brainstem response test on the same day revealed that only the right ear produced a wave V with a threshold of 80 dBnHL, while the other waves were unrecognizable at a maximum of 95 dBnHL click stimulation. After receiving treatment with linezolid, minocycline, Ginkgo biloba extract, phosphatidylcholine, and cilostazol, as well as 10 sessions of HBO therapy, the patient's headache improved but dizziness persisted. Bilateral hearing loss and knee pain significantly improved, while the range of motion in the left knee was slightly limited.

**Figure 3** Minor ischemic lesion in the left frontal lobe.

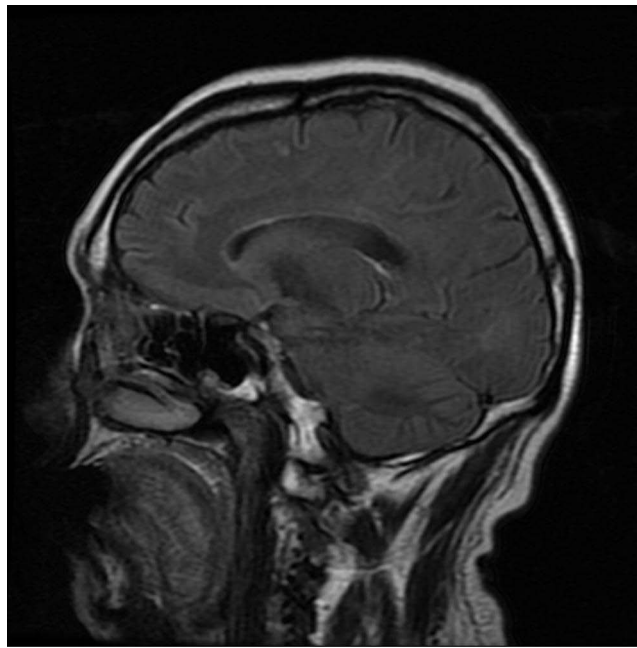


Figure 4 Improved swelling of both knee joints.

After stopping the medication for more than 4 months, the patient reported occasional dizziness and some residual hearing loss, but some improvement was observed. Mild knee pain was felt at times, but it significantly improved with no headaches, fever, or other discomforts. On September 8, 2021, the patient's CSF pressure was 125 mmH₂O. Also, the cerebrospinal fluid routine *Cryptococcus neoformans* antigen test was weakly positive, with a red blood cell count of $0.230 \times 10^9/L$. The biochemical and adenosine deaminase tests for CSF were normal. On September 9, 2021, the blood tests showed a hemoglobin level of 157.0 g/L, neutrophil count of $3.4 \times 10^9/L$, platelet count of $364.0 \times 10^9/L$, and a WBC count of $6.2 \times 10^9/L$. The patient's liver and kidney function tests were within normal range. A head MRI revealed a small ischemic lesion in the left frontal lobe. During a follow-up call on May 27, 2022, the patient reported occasional dizziness, mild knee pain, and mild hearing loss, which improved significantly. During a call on February 20, 2023, the patient reported occasional dizziness, no knee pain, and some residual hearing loss, but no significant impact on daily life was found.

Discussion

S. suis infection was first reported in humans in Denmark in 1968.¹ Since then, the pathogen has spread worldwide and has a high prevalence in Southeast Asia, with more than 1600 reported cases globally,² mostly in Thailand and Vietnam. In China, 2 *S. suis* outbreaks in humans affected more than 100 people and caused 38 deaths.³ Previous studies identified 35 serotypes of *S. suis* using agglutination assays. Among these, *S. suis* serotype 2 (SS2) is the most common serotype causing human infections, while SS1, SS4, SS5, SS14, and SS16 are rare serotypes. Further genetic analysis has revealed at least 16 sequence types of SS2,⁴ with sequence types 1 and 7 being the most pathogenic.⁵ The virulence of *S. suis* is determined by both serotype and genotype, and its virulence factors can be classified as highly pathogenic, weakly pathogenic, or nonpathogenic based on the bacterial virulence factor spectrum. Gene series analysis was not performed in this case due to testing limitations.

S. suis infection is the most common in countries where pigs are widely raised, and professions related to pig contact are the main risk factors for infection. In our case, the patient had long worked as a butcher in a slaughterhouse and had long-term contact with sick and dead pigs. He had a cut on the left index finger from a knife 2 days before the onset of symptoms. Besides occupational exposure, consuming undercooked or partially cooked pork products is also a risk factor

for infection.^{6–9} Patients are usually healthy before being infected with *S. suis*, but predisposing factors such as diabetes, alcoholism, and malignant tumors have been reported.

S. suis is an emerging zoonotic pathogen that mainly causes meningitis, sepsis, arthritis, endocarditis, and endophthalmitis in humans. In our case, a male patient of middle to elderly age range presented with abdominal and joint pain. He developed headaches, nausea, and projectile vomiting 11 h before admission, followed by hearing impairment after admission. The initial diagnosis was unclear, but the biochemical examination of the CSF suggested the possibility of purulent meningitis. The final diagnosis was purulent meningitis with concomitant arthritis. This was determined based on the results of a CSF culture and high-throughput gene detection. Several factors were taken into consideration while making this diagnosis, including the patient's long-term occupation as a butcher in a slaughterhouse and his prolonged exposure to sick and dead pigs. Additionally, the fact that he had a knife cut on his left index finger 2 days before the onset of symptoms, which was not adequately disinfected or bandaged, was also considered relevant. The cause of the condition was identified as *S. suis*. Compared with meningitis and sepsis, the clinical presentations of enteritis, arthritis, endocarditis, pneumonia, spondylodiscitis, endophthalmitis, and peritonitis caused by *S. suis* are relatively rare.¹⁰ However, a few studies report clinical presentations such as abdominal pain and diarrhea.¹¹ Therefore, we need to consider the possibility of rare pathogens such as *S. suis* in patients who present with abdominal pain in the future.

The most common manifestation of *S. suis* infection is meningitis. Hearing loss is the most common sequela after recovery from purulent meningitis, with a prevalence of 53% as shown in a recent meta-analysis.¹² Up to half of the patients may report this symptom at the time of or several days after the consultation. This type of hearing loss is usually bilateral, severe, and permanent.^{13,14} Deafness with or without vestibular dysfunction is considered to be caused by direct infection of the cochlea. *S. suis* is thought to enter the inner ear through the aqueduct of the cochlea via the lytic action of its exotoxin, causing suppurative labyrinthitis.¹³ Patients with vestibular dysfunction due to *S. suis* meningitis may also suffer from permanent disability due to dizziness and gait instability. Such patients should receive immediate vestibular rehabilitation treatment to improve their independence in daily activities.^{13,15} Dexamethasone has been shown to reduce a hearing loss.¹² HBO therapy is also a treatment method in which patients are exposed to high environmental pressure and breathe 100% oxygen in a hyperbaric chamber. This hyperoxia has various beneficial effects as adjuvant therapy for many otolaryngological diseases and conditions. These effects can be summarized as anti-ischemic (delivering oxygen to other ischemic tissues, reducing ischemia–reperfusion injury), anti-infective (bacteriostatic, enhancing the phagocytic activity of WBCs and optimizing antibiotic therapy), and wound-healing effects (stimulating granulation tissue formation and stabilization). HBO therapy has strong scientific evidence and can improve the pure-tone audiometry threshold in patients with sudden sensorineural hearing loss who are unresponsive to drug therapy. Further research may identify the group of patients with sudden sensorineural hearing loss who would benefit the most from HBO therapy. For these patients, HBO therapy is expected to be the most cost-effective.¹⁶ In this case study, the patient experienced hearing loss on the seventh day of hospitalization and was initially treated with intravenous methylprednisolone. The tinnitus improved, but the hearing loss persisted. The patient began HBO chamber therapy on the 12th day of hospitalization, which was performed 10 times, and the patient's hearing improved significantly. No cases of HBO chamber treatment for hearing loss in patients with *S. suis* meningitis were found in previous studies or recent meta-analyses.^{12,17} The therapeutic effect observed in this study can provide a reference for treating patients with hearing loss in the future. However, the timing of treatment selection requires further exploration. Unfortunately, the patient's hearing improved after treatment, but the hearing test was not repeated.

The symptoms of the infection caused by *S. suis* are typically similar to those of bacterial meningitis. Therefore, the treatment strategy usually involves the use of antibiotics. The most commonly used antibiotics are beta-lactams (penicillin G, ceftriaxone, or amoxicillin), aminoglycosides (gentamicin), phenylpyrazoles (fluphenazine), and fluoroquinolones. Most strains of *S. suis* are sensitive to penicillin or cephalosporins, and high-dose intravenous penicillin G is effective in most patients.^{18–20} *S. suis* is susceptible to many antibiotics, but resistance to tetracyclines and macrolides is common.^{8,18–20} Therefore, antibiotic treatment is highly effective in *S. suis* infection. The use of dexamethasone as an adjunct therapy to reduce mortality and improve the outcomes of bacterial meningitis remains controversial. Early diagnosis and treatment are the most important factors in reducing the damage caused by *S. suis* infection. *S. suis* is a positive coccus. Ceftriaxone treatment was effective initially, but the condition relapsed midway. Choose antibiotics

with strong blood-brain barrier penetration and high joint cavity bone concentration. Consider that the patient has symptoms such as hearing loss and dizziness. Vancomycin was not suitable, so linezolid anti-infective treatment was chosen.

Therefore, patients with risk factors for susceptibility should immediately consider the possibility of streptococcal infection if they exhibit clinical symptoms such as fever, headache, joint pain, and hearing loss. Early treatment with pathogen-sensitive penicillin or antibiotics is essential to prevent long-term mortality and morbidity. In the present case, HBO therapy combined with corticosteroids had some positive effects on early hearing loss. This can be further validated with more clinical cases in the future. Currently, the most effective prevention and control measure in the absence of vaccination is strengthening food hygiene supervision.

Abbreviations

WBC, white blood cell count; CSF, Cerebrospinal fluid; MRI, Magnetic Resonance Imaging; HBO, a hyperbaric oxygen; SS2, *S. suis* serotype 2.

Data Sharing Statement

The datasets generated during and/or analyzed during the current study are available from the corresponding author on reasonable request.

Ethics and Concern

This research complies with the guidelines for human studies and is in accordance with the Declaration of Helsinki. This report was approved by the Medical Ethics Committee of Huzhou Central Hospital. Written informed consent for the disclosure of their detailed information was obtained from the patients.

Acknowledgments

The authors are grateful to their colleagues for the management of the patient and to the subject for participating in this study.

Author Contributions

All authors made a significant contribution to the work reported, whether that is in the conception, study design, execution, acquisition of data, analysis and interpretation, or in all these areas; took part in drafting, revising or critically reviewing the article; gave final approval of the version to be published; have agreed on the journal to which the article has been submitted; and agree to be accountable for all aspects of the work.

Funding

There is no funding to report.

Disclosure

The authors report no conflicts of interest in this work.

References

1. Perch B, Kristjansen P, Skadhauge K. Group R streptococci pathogenic for man. Two cases of meningitis and one fatal case of sepsis. *Acta Pathol Microbiol Immunol Scand.* 1968;74(1):69. doi:10.1111/j.1699-0463.1968.tb03456.x
2. Feng Y, Zhang H, Wu Z, et al. Streptococcus suis infection: an emerging/reemerging challenge of bacterial infectious diseases? *Virulence.* 2014;5(4):477. doi:10.4161/viru.28595
3. Yu H, Jing H, Chen Z, et al. Human Streptococcus suis outbreak, Sichuan, China. *Emerg Infect Dis.* 2006;12(6):914. doi:10.3201/eid1206.051194
4. Hlebowicz M, Jakubowski P, Smiatacz T. Streptococcus suis meningitis: epidemiology, clinical presentation and treatment. *Vector Bor Zoonot Dis.* 2019;19(8):557. doi:10.1089/vbz.2018.2399
5. Jiang F, Guo J, Cheng C, et al. Human infection caused by Streptococcus suis serotype 2 in China: report of two cases and epidemic distribution based on sequence type. *BMC Infect Dis.* 2020;20(1):223. doi:10.1186/s12879-020-4943-x

6. Huong VT, Ha N, Huy NT, et al. Epidemiology, clinical manifestations, and outcomes of *Streptococcus suis* infection in humans. *Emerg Infect Dis.* 2014;20(7):1105. doi:10.3201/eid2007.131594
7. Wertheim HF, Nghia HD, Taylor W, et al. *Streptococcus suis*: an Emerging Human Pathogen. *Clin Infect Dis.* 2009;48(5):617. doi:10.1086/596763
8. Ma E, Chung PH, So T, et al. *Streptococcus suis* infection in Hong Kong: an emerging infectious disease? *Epidemiol Infect.* 2008;136(12):1691. doi:10.1017/S0950268808000332
9. Goyette-Desjardins G, Auger JP, Xu J, et al. *Streptococcus suis*, an important pig pathogen and emerging zoonotic agent—an update on the worldwide distribution based on serotyping and sequence typing. *Emerging Microbes Infect.* 2014;3: 6.
10. Huang YT, Teng LJ, Ho SW, et al. *Streptococcus suis* infection. *J Microbiol Immunol Inf.* 2005;38(5):306.
11. Feng P, Tan MZ, Chen ZH, et al. [Clinical features and outcome of infection of type 2 *Streptococcus suis* in human]. *Sichuan da Xue Bao Yi Xue Ban.* 2007;38(5):874. Chinese.
12. van Samkar A, Brouwer MC, Schultz C, et al. *Streptococcus suis* meningitis: a systematic review and meta-analysis. *PLoS Negl Trop Dis.* 2015;9(10):e0004191. doi:10.1371/journal.pntd.0004191
13. Tan JH, Yeh BI, Seet CS. Deafness due to haemorrhagic labyrinthitis and a review of relapses in *Streptococcus suis* meningitis. *Singapore Med J.* 2010;51(2):e30.
14. Kay R, Cheng AF, Tse CY. *Streptococcus suis* infection in Hong Kong. *QJM.* 1995;88(1):39.
15. Strupp M, Arbusow V, Maag KP, et al. Vestibular exercises improve central vestibulospinal compensation after vestibular neuritis. *Neurology.* 1998;51(3):838. doi:10.1212/WNL.51.3.838
16. Muzzi E, Zennaro B, Visentin R, et al. Hyperbaric oxygen therapy as salvage treatment for sudden sensorineural hearing loss: review of rationale and preliminary report. *J Laryngology Otol.* 2010;124(2):e2. doi:10.1017/S0022215109992052
17. Rayanakorn A, Goh BH, Lee LH, et al. Risk factors for *Streptococcus suis* infection: a systematic review and meta-analysis. *Sci Rep.* 2018;8(1):13358. doi:10.1038/s41598-018-31598-w
18. Mai NT, Hoa NT, Nga TV, et al. *Streptococcus suis* meningitis in adults in Vietnam. *Clin Infect Dis.* 2008;46(5):659. doi:10.1086/527385
19. Chang B, Wada A, Ikebe T, et al. Characteristics of *Streptococcus suis* isolated from patients in Japan. *Jpn J Infect Dis.* 2006;59(6):397. doi:10.7883/yoken.JJID.2006.397
20. Tall H, Njanpop-Lafourcade BM, Mounkoro D, et al. Identification of *streptococcus suis* meningitis through population-based surveillance, togo, 2010–2014. *Emerging Infectious Diseases.* 2016;22(7):1262. doi:10.3201/eid2207.151511

Infection and Drug Resistance

Dovepress

Publish your work in this journal

Infection and Drug Resistance is an international, peer-reviewed open-access journal that focuses on the optimal treatment of infection (bacterial, fungal and viral) and the development and institution of preventive strategies to minimize the development and spread of resistance. The journal is specifically concerned with the epidemiology of antibiotic resistance and the mechanisms of resistance development and diffusion in both hospitals and the community. The manuscript management system is completely online and includes a very quick and fair peer-review system, which is all easy to use. Visit <http://www.dovepress.com/testimonials.php> to read real quotes from published authors.

Submit your manuscript here: <https://www.dovepress.com/infection-and-drug-resistance-journal>