

Interdigitating dendritic cell sarcoma located in the adrenal gland: a case report and literature review

Journal of International Medical Research

49(11) 1–5

© The Author(s) 2021

Article reuse guidelines:

sagepub.com/journals-permissions

DOI: 10.1177/03000605211055410

journals.sagepub.com/home/imr

Peng Hao¹, Liang Cao¹, Yangming Li¹,
Dong Lin² , Tinghui Hu³ and Tao Wu¹ 

Abstract

We report a case of interdigitating dendritic cell sarcoma (IDCS) originating from the adrenal gland. A 57-year-old middle-aged woman with no previous history of malignancy came to our hospital after color Doppler ultrasound revealed a right adrenal mass. An abdominal computed tomography scan also showed an adrenal mass. Postoperative pathology confirmed the diagnosis of IDCS. After complete surgical removal of the adrenal tumor, the patient has been disease-free for 1 year. IDCS may have a good prognosis after surgical resection. To our knowledge, this is only the second reported case of IDCS in the adrenal region.

Keywords

Interdigitating dendritic cell, interdigitating dendritic cell sarcoma, adrenal gland, case report, adrenalectomy, extralymphatic lesion

Date received: 27 July 2021; accepted: 5 October 2021

Introduction

Interdigitating dendritic cell sarcoma (IDCS) is an extremely rare malignancy that originates from a dendritic cell (DC) tumor and usually presents as lymphadenopathy with local enlargement, rarely accompanied by systemic symptoms such as fever and weight loss. The most common primary site of IDCS is the

¹Department of Urology, Affiliated Hospital of North Sichuan Medical College, Nanchong, Sichuan, China

²Department of Urology, Pengzhou People's Hospital, Pengzhou, Sichuan, China

³Department of Urology, Emei City People's Hospital, Emeishan, Sichuan, China

Corresponding author:

Tao Wu, The Affiliated Hospital of North Sichuan Medical College, 1 Maoyuan South Road, Shunqing, Nanchong, Sichuan 637000, China.

Email: alhawking@163.com



Creative Commons Non Commercial CC BY-NC: This article is distributed under the terms of the Creative

Commons Attribution-NonCommercial 4.0 License (<https://creativecommons.org/licenses/by-nc/4.0/>) which permits non-commercial use, reproduction and distribution of the work without further permission provided the original work is attributed as specified on the SAGE and Open Access pages (<https://us.sagepub.com/en-us/nam/open-access-at-sage>).

lymph nodes, which are mainly located in the cervical, mediastinum, and axillary regions. Extralymphatic IDCS lesions mainly occur in the liver, lungs, spleen, digestive system, head and neck, and testes.¹ In 1981, Feltkamp et al. reported the first case of IDCS occurring in the mediastinal region.² Subsequently, IDCS cases from the liver, lungs, spleen, digestive system, head and neck, and testicles have been reported. However, IDCS cases originating from the adrenal region are extremely rare, with only one previously reported case.³ Herein, we report the second case of IDCS originating from the adrenal gland and review relevant knowledge about the pathological features and clinical treatment of IDCS.

Case report

The reporting of this study conforms to the CARE guidelines.⁴ The patient gave verbal informed consent for the publication of this case report. A 57-year-old woman was admitted to our hospital with a 1-month history of right adrenal hyperplasia, which was found by color Doppler ultrasound. The patient had no systemic symptoms such as cough or blood-stained sputum, dizziness, chest tightness, fever, night sweats, weight loss, or fatigue.

Contrast-enhanced computed tomography showed a 3.4×2.1 -cm, solitary, heterogeneous density mass with a clear boundary (Figure 1). Other radiological and ultrasound examinations did not reveal significant nodal disease or distant metastasis. The patient underwent a right adrenalectomy, and the pathological findings of the surgical specimen confirmed the diagnosis of IDCS.

Histopathology of the surgically removed specimen showed that the tumor cell nuclei were partially round/oval. The chromatin was lightly stained, mostly vacuolated, and the nucleoli were medium-sized. The cytoplasm was abundant, slightly eosinophilic, and the cells were ill-defined. Mitoses were low ($<5/10$ high-power field). Small lymphocytes were mixed between tumor cells (Figure 2a). Immunohistochemical analysis showed that the tumor cells consistently expressed s100 and weakly expressed CD68, CD163, and SOX10. The Ki67 proliferation index was 15%. Other examined tumor markers including CD1a, Desmin, EMA, CK, CD21, CD23, CD35, HMB, and SMA, were negative (Figure 2b). The patient has been recurrence-free for 1 year since treatment.

Discussion

DCs are a heterogeneous group of non-lymphoid and non-phagocytic immune

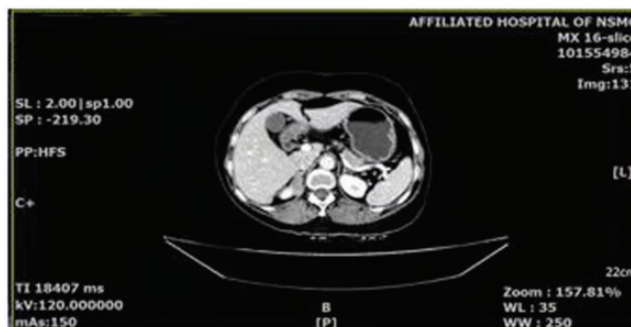


Figure 1. Contrast-enhanced computed tomography image: a solitary, heterogeneous-enhanced density mass with a clear boundary.

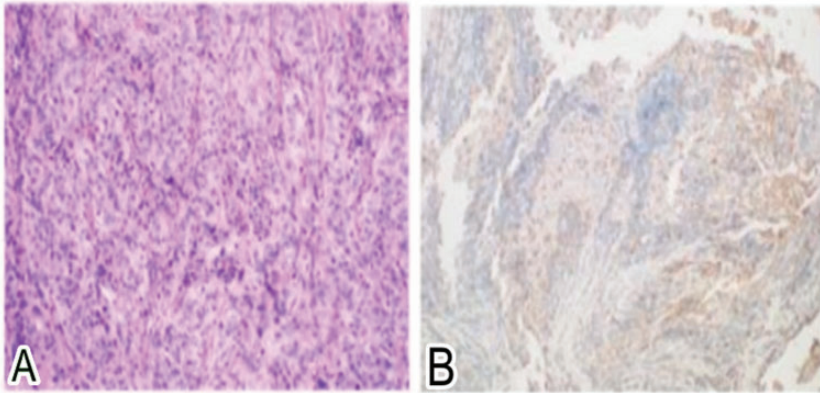


Figure 2. (a) Hematoxylin–eosin staining: tumor cell nuclei were partially round/oval. (b) Immunohistochemical staining: tumor cells consistently expressed S100, and weakly expressed CD68, CD163, and SOX10.

helper cells present in lymphoid and non-lymphatic organs. DCs are key antigen presenting cells and initiators of immune responses and include several subtypes such as Langerhans' cells, interdigitating DCs, follicular DCs, dermal dendrocytes, indeterminate cells, and veiled cells.^{5–7} DC tumors are very rare, accounting for less than 1% of all lymph node tumors, and IDCs are extremely rare malignancies that originate from DCs. Owing to the overlapping morphology of the various types of DCs, ancillary studies are needed for definitive diagnosis. Other tumor types that need to be excluded are melanoma, spindle cell carcinoma, and various mesenchymal tumors.⁸ Approximately 11% of IDCs cases are misdiagnosed as lymphoma, melanoma, peripheral schwannoma, or malignant fibrous histiocytoma. Histomorphology and immunophenotyping can help distinguish IDCs from other spindle cell tumors and metastatic melanomas.⁵

IDCS has a distinctive histological pattern, with abundant, slightly eosinophilic cytoplasm, and there is often an indistinct border. The cytoplasm is rich in mitochondria and endoplasmic reticulum, and the nuclei are unevenly shaped and can be

serrated, and the nucleolus is obviously larger. Melanin, desmosome junction, and Birbeck granules are not seen. The most commonly described histological pattern of IDCs is the proliferation of spindle-shaped or histiocytic cells, which is similar to other tumor-like conditions including DC tumors, histiocytic lesions, and granulomatous inflammation.^{1,2,9,10} Currently, there are no specific markers for IDCs, the tumor cells of which often show different immunophenotypes that can be confirmed by multiple immunohistochemical methods. The most commonly expressed molecules are S100, CD68, vimentin, and CD1a, accounting for 95.8%, 58%, 38.7%, and 4.5% of cases, respectively. The diagnosis of IDCs should be established if tumor cells express S100, CD68, and vimentin, but are negative for CK, LCA, CD15, CD30, CD21, and CD35.¹ IDCs can be distinguished from metastatic melanoma by similar immunohistochemical features (S-100⁺, CD68^{+/-}). However the absence of other melanocyte markers may determine the diagnosis.⁸ As a marker associated with cell proliferation, Ki-67 expression ranges from 10% to 40% in IDCs, with a median of 20%.^{10,11} The Ki-67

results in this case were 15%, which could roughly predict the low disease severity of this patient.

Currently, there is no definitive standard treatment for IDCS. The clinical progression course of IDCS is unpredictable, ranging from indolent to invasive, with a high tendency for distant metastasis (in approximately 33% of patients). Localized IDCS can be surgically treated. The 1-year mortality rate of IDCS patients with resectable diseases is 18%, while that of patients with unresectable diseases is 63%. The results of this study indicated that surgical resection was associated with better disease prognosis and survival.¹ Surgical resection is still the primary treatment for local and resectable IDCS. Adjuvant radiotherapy does not significantly improve the overall survival time or reduce recurrence rates, and systemic chemotherapy is the main treatment for patients with distant metastasis.¹² The chemotherapy regimens for patients with metastatic IDCs include CHOP (cyclophosphamide, adriamycin, vincristine, prednisone), ABVD (adriamycin, bleomycin, vincristine, dacarbazine), and ICE (ifosfamide, carboplatin, etoposide). However, the anticancer efficacy of these regimens is very limited.^{7,8,13} No significant difference in disease-free survival was reported between patients who underwent surgical resection alone compared with those who received adjuvant therapy.² Although the patient we reported refused postoperative adjuvant therapy after surgery, owing to the particularity of the location of this case, the patient has been disease-free for more than 1 year after undergoing surgical treatment.

Conclusions

IDCS is a very rare, aggressive, malignant tumor with similar pathological features to DCs and melanoma, which makes diagnosis difficult. Currently, there is no agreed upon

standard therapy to treat IDCS. On the basis of this case, we confirm that IDCS can localize to the adrenal region, and that early and timely detection and diagnosis, as well as complete surgical resection of the lesion, are necessary. To date, surgical resection is the only treatment for IDCS that can ensure long-term disease-free survival. We still need more multicenter cases and long-term follow-up data to guide better clinical decision-making when diagnosing and treating IDCS.


Declaration of conflicting interest


The authors declare that there is no conflict of interest.

Funding

This research received no specific grant from any funding agency in the public, commercial, or not-for-profit sectors.

ORCID iDs

Dong Lin  <https://orcid.org/0000-0002-4836-4351>

Tao Wu  <https://orcid.org/0000-0003-0068-4273>

References

1. Muhammed A, Ahmed ARH, Maysa H, et al. New insights inside the interdigitating dendritic cell sarcoma-pooled analysis and review of literature. *Ann Hematol.* 2019; 98: 2641–2651.
2. Xue T, Jiang X-N, Wang W-G, et al. Interdigitating dendritic cell sarcoma: Clinicopathologic study of 8 cases with review of the literature. *Ann Diagn Pathol* 2018; 34: 155–160.
3. Zhu YL, Qiu T, Zhang HF, et al. [Clinicopathological characteristics and differential diagnosis of interdigitating dendritic cell sarcoma]. *Zhonghua Zhong Liu Za Zhi.* 2019; 41: 449–453. doi: 10.3760/cma.j.issn.0253-3766.2019.06.010.
4. Gagnier JJ, Kienle G, Altman DG, et al.; CARE Group. The CARE guidelines: Consensus-based clinical case reporting

- guideline development. *Headache*. 2013; 53: 1541–1547.
5. Saygin C, Uzunaslan D, Ozguroglu M, et al. Dendritic cell sarcoma: A pooled analysis including 462 cases with presentation of our case series. *Crit Rev Oncol Hematol*. 2013; 88: 253–271. doi: 10.1016/j.critrevonc.2013.05.006. Epub 2013 Jun 5.
 6. Kawachi K, Nakatani Y, Inayama Y, et al. Interdigitating dendritic cell sarcoma of the spleen: Report of a case with a review of the literature. *Am J Surg Pathol*. 2002; 26: 530–537.
 7. Efun G, Sumer BD, Sarode VR, et al. Interdigitating dendritic cell sarcoma of the parotid gland: Case report and literature review. *Am J Otolaryngol* 2009; 30: 264–268.
 8. Pokuri VK, Merzianu M, Gandhi S, et al. Interdigitating dendritic cell sarcoma. *J Natl Compr Canc Netw*. 2015; 13: 128–132.
 9. Lupato V, Romeo S, Franchi A, et al. Head and neck extranodal interdigitating dendritic cell sarcoma: Case report and review of the literature. *Head Neck Pathol* 2016; 10: 145–151.
 10. Shan S-J, Meng L-H, Lu R, et al. Primary cutaneous interdigitating dendritic cell sarcoma: A case report and review of the literature. *Am J Dermatopathol*. 2015; 37: 639–642.
 11. Gaertner EM, Tsokos M, Derringer GA, et al. Interdigitating dendritic cell sarcoma. A report of four cases and review of the literature. *Am J Clin Pathol*. 2001; 115: 589–597.
 12. Zhu J, Su S, Zhou J, et al. Interdigitating dendritic cell sarcoma presenting in the sigmoid colon mesentery: A case report and literature review. *Medicine (Baltimore)*. 2017; 96: e6210.
 13. Kim SY, Kang J-H, Chun SH, et al. Interdigitating dendritic cell sarcoma of the tonsil. *Asia Pac J Clin Oncol*. 2010; 6: 144–148.