

Pyoderma gangrenosum associated with Takayasu's arteritis in a young Caucasian woman and response to biologic therapy with tocilizumab



Dean J. Choong, MD,^a Jeremy L. Ng, MBBS, FACD,^b and Carl Vinciullo, MBBS, FACD^b
Perth, Western Australia

Key words: biologic agent; biologics; biologic therapy; Caucasian; dermatology; IL-6; monoclonal antibody; monoclonal antibodies; pyoderma gangrenosum; Takayasu's arteritis; tocilizumab; vasculitis.

INTRODUCTION

Pyoderma gangrenosum (PG) associated with Takayasu's arteritis has been well-described in the Asian population.¹ However, the association is extremely rare in Caucasian populations, with only 2 previously reported cases.^{2,3} This case describes this rare association in a young Caucasian woman and highlights the importance of considering the possibility of Takayasu's arteritis in these patients. The patient was commenced on tocilizumab to treat her Takayasu's arteritis, which was associated with a marked improvement of her extremely refractory PG. To our knowledge, this case also represents the second-ever reported clinical response of PG to tocilizumab.⁴

CASE REPORT

We describe the case of a 25-year-old Caucasian woman with Takayasu's arteritis preceded by years of PG. She had a five-year history of lesions involving the arms, torso, and perineum (Fig 1). Notably, skin and colonic biopsies at the time of initial diagnosis did not show any evidence of vasculitis. Her medical comorbidities included hypothyroidism and obesity. The patient had trialed numerous therapies (with weaning success) in the past including prednisolone, methotrexate, mycophenolate, cyclosporin A, infliximab, and adalimumab. She was then trialed on 8-weekly ustekinumab and demonstrated a partial response with end-of-dose flaring.

Abbreviations used:

IL-6: interleukin 6
PG: pyoderma gangrenosum

Three months into ustekinumab treatment (3 doses given in total), the patient suffered a left middle cerebral artery territory stroke and was found to have significant carotid artery stenosis. She underwent a mechanical thrombectomy with left common carotid artery stenting.

There was suspicion of a large-vessel vasculitis causing the carotid stenosis, based on the patient's age and elevated inflammatory markers (c-reactive protein, 97 mg/L; erythrocyte sedimentation rate, 105 mm/hr). A positron emission tomography scan revealed areas of uptake in both common carotid arteries, with left greater than right at the site of stent insertion after thrombectomy.

Follow-up imaging at 6 months revealed progressive stenosis of both common carotid arteries (Fig 2). A diagnosis of Takayasu's arteritis was made after repeated positron emission tomography scanning demonstrated increased uptake in these areas of stenosis (Fig 3).

Following the diagnosis, she commenced intravenous tocilizumab 680 mg monthly, in an attempt to control both the vasculitis and the PG. The patient developed transient transaminitis and a flare of her vasculitis associated with the first dose of

From the Dermatology Department, Fiona Stanley Hospital^a; and Dermatology Department, Royal Perth Hospital.^b

Funding sources: None.

Accepted for poster presentation at The Australasian College of Dermatologists' 53rd Annual Scientific Meeting, April 9-11, 2021 (virtual conference).

Correspondence to: Dean J. Choong, MD, Dermatology Department, Fiona Stanley Hospital, 11 Robin Warren Drive, Murdoch, WA 6150, Australia. E-mail: dean.choong@gmail.com.

JAAD Case Reports 2021;9:4-6.
2352-5126

© 2021 by the American Academy of Dermatology, Inc. Published by Elsevier, Inc. This is an open access article under the CC BY-NC-ND license (<http://creativecommons.org/licenses/by-nc-nd/4.0/>).

<https://doi.org/10.1016/j.jidcr.2020.12.034>

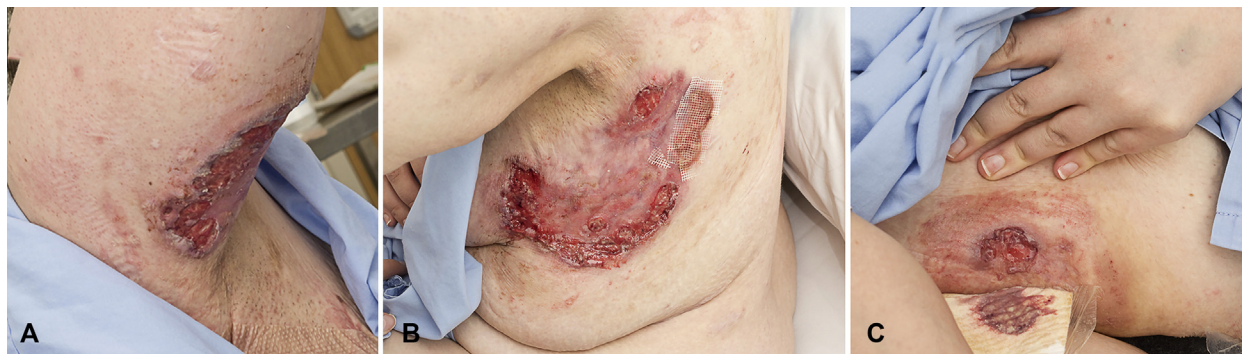

Fig 1. The patient's pyoderma gangrenosum lesions at the time of commencement of tocilizumab, involving the (A) right upper arm, (B) left lateral chest wall, and (C) right anterior abdomen.

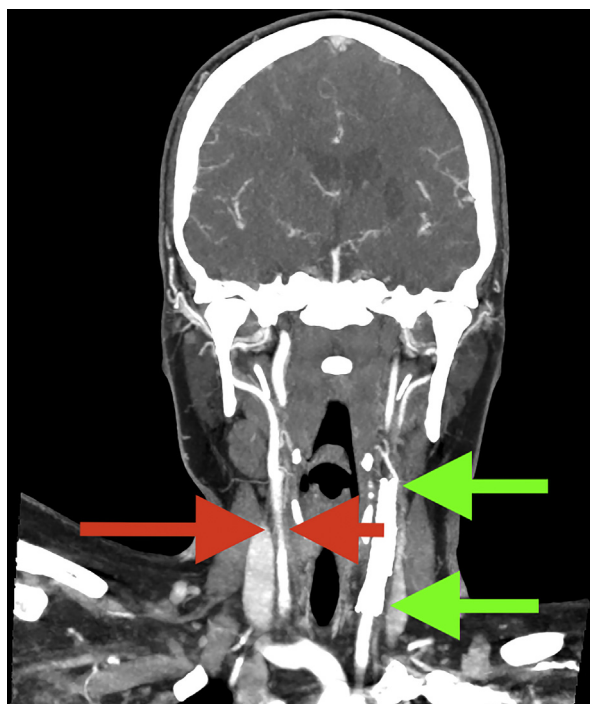


Fig 2. Stenosis of the right common carotid artery (red arrows) demonstrated on computed tomography angiogram, 6 months following the patient's stroke. Also shown is the left common carotid artery stent (green arrows).

tocilizumab, which required hospitalization for treatment with intravenous steroids, and she was discharged on oral cyclosporin A 100 mg daily. The patient subsequently tolerated a half-dose of tocilizumab 360 mg and then had her monthly dose escalated to 520 mg for 6 months, followed by 600 mg for 7 months, and then to a full-dose of 680 mg monthly without further hepatic impairment or adverse events.

The patient's inflammatory markers normalized within 2 weeks of the first tocilizumab dose

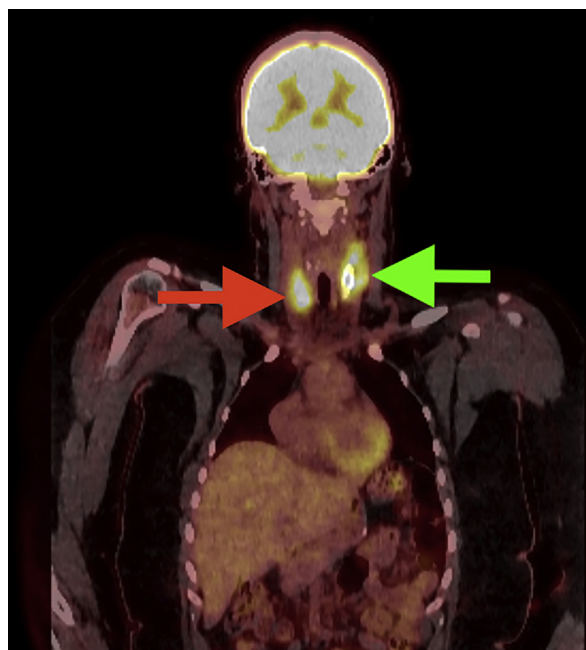

Fig 3. Positron emission tomography imaging showing increased uptake in the right common carotid artery (red arrow) corresponding to the area of stenosis and increased uptake at the site of the left common carotid artery stent (green arrow).

(c-reactive protein, <1 mg/L; erythrocyte sedimentation rate, 16 mm/hr). The PG lesions healed completely after 10 months of tocilizumab, and cyclosporin A was discontinued after 12 months. Now, 18 months into treatment, there is ongoing control of both the PG and Takayasu's arteritis.

DISCUSSION

Takayasu's arteritis is a chronic large-vessel vasculitis that can present as non-specific constitutional signs and symptoms related to vessel occlusions

including stroke, claudication, and cardiac failure. Takayasu's arteritis is associated with cutaneous manifestations such as erythema nodosum, PG, and erythema induratum, among others. The association of Takayasu's arteritis and PG is rare in Caucasian patients, with only 2 reported cases.^{2,3}

Fearfield et al. described a case of a 33-year-old Caucasian woman with PG occurring 3 years prior to the diagnosis of Takayasu's arteritis.² Like in our patient, PG lesions preceded the diagnosis of Takayasu's arteritis. PG lesions can occur at any time in relation to Takayasu's arteritis, possibly occurring more often when the vasculitis becomes occlusive.²

This case highlights the importance of considering the association with Takayasu's arteritis in both Asian and Caucasian PG patients. Earlier recognition of associated vasculitis (especially in younger patients) through simple measures, such as bilateral blood pressure measurement, may help reduce the excess morbidity and mortality associated with Takayasu's arteritis.⁵

To date, we found only 1 case report describing a clinical response of PG to tocilizumab.^{4,6} Lee et al. reported complete healing of lesions within 3 months of commencing subcutaneous tocilizumab 162 mg fortnightly in a patient with PG with associated rheumatoid arthritis.⁴ A retrospective study from 2018 of biologics and immunoglobulin treatments of PG, involving 52 patients and 83 treatment regimens, had only 1 patient that received tocilizumab without any clinical response.⁷

Two previously reported cases of PG associated with Takayasu's arteritis in Caucasian patients both responded to a combination of steroids and steroid-sparing agents.^{2,3} Our patient had PG refractory to multiple lines of treatment, including 3 lines of biologic agents.

In summary, we present a rare case of PG occurring together with Takayasu's arteritis in a Caucasian patient. We believe this case is the second-ever reported clinical response of PG to tocilizumab, a humanized anti interleukin 6 (IL-6) receptor monoclonal antibody. IL-6 contributes to the differentiation of T regulatory cells into T helper 17 cells, which play an important role in the activation and accumulation of neutrophils. Inhibiting the IL-6 signaling pathway with targeted agents such as tocilizumab provides a potential therapeutic option in the management of neutrophilic dermatoses such as PG.

Conflicts of interest

None disclosed.

REFERENCES

1. Ujiiie H, Sawamura D, Yokota K, Nishie W, Shichinohe R, Shimizu H. Pyoderma gangrenosum associated with Takayasu's arteritis. *Clin Exp Dermatol*. 2004;29:357-359.
2. Fearfield LA, Ross JR, Farrell AM, Costello C, Bunker CB, Staughton RC. Pyoderma gangrenosum associated with Takayasu's arteritis responding to cyclosporin. *Br J Dermatol*. 1999; 141:339-343.
3. Loetscher J, Fistarol S, Walker UA. Pyoderma gangrenosum and erythema nodosum revealing Takayasu's arteritis. *Case Rep Dermatol*. 2016;8:354-357.
4. Lee WS, Choi YJ, Yoo WH. Use of tocilizumab in a patient with pyoderma gangrenosum and rheumatoid arthritis. *J Eur Acad Dermatol Venereol*. 2017;31:e75-e77.
5. Mirouse A, Biard L, Comarmond C, et al. Overall survival and mortality risk factors in Takayasu's arteritis: a multicenter study of 318 patients. *J Autoimmun*. 2019;96:35-39.
6. McKenzie F, Cash D, Gupta A, Cummings LW, Ortega-Loayza AG. Biologic and small-molecule medications in the management of pyoderma gangrenosum. *J Dermatolog Treat*. 2019;30:264-276.
7. Herberger K, Dissemond J, Brüggelstrat S, Sorbe C, Augustin M. Biologics and immunoglobulins in the treatment of pyoderma gangrenosum—analysis of 52 patients. *J Dtsch Dermatol Ges*. 2019;17:32-41.