



# A Case Report of Intravascular Hemolysis and Heme Pigment–Induced Nephropathy Following AngioJet Thrombectomy for Thrombosed DIPS Shunt

Canadian Journal of Kidney Health and Disease  
Volume 7: 1–7  
© The Author(s) 2020  
Article reuse guidelines:  
sagepub.com/journals-permissions  
DOI: 10.1177/2054358120979233  
journals.sagepub.com/home/cjk

Si Tian<sup>1</sup>, Nicolette Sinclair<sup>2</sup>, and Sachin Shah<sup>1,3</sup>

## Abstract

**Rationale:** The AngioJet system is a combined mechanical and pharmacological device used for thrombectomy. As a result of the mechanical disruption of clot, intravascular hemolysis is noted to occur. Rarely, intravascular hemolysis can be severe enough to cause heme pigment–induced acute kidney injury (AKI).

**Presenting concerns of the patient:** We describe a case of a 45-year-old man with Child-Pugh class B cirrhosis, Budd-Chiari syndrome, and antiphospholipid antibody syndrome who required thrombectomy following a thrombosed direct intrahepatic portosystemic shunt (DIPS). He developed evidence of worsening anemia, dark urine, direct antiglobulin test–negative intravascular hemolysis, and severe AKI within 24 hours of the procedure.

**Diagnosis:** Based on his severe AKI in association with elevated hemolytic markers, and the temporal association with the AngioJet procedure, the patient was diagnosed with heme pigment–induced AKI secondary to intravascular hemolysis.

**Interventions:** The patient remained anuric and became volume–overloaded after fluid resuscitation. He was started on dialysis 72 hours after the procedure. Five days after thrombectomy, hemolytic markers returned to normal.

**Outcome:** The patient received hemodialysis for approximately 3 weeks, followed by renal recovery and cessation of dialysis treatments. Five weeks after the AngioJet procedure, his renal function returned to normal.

**Teaching points:** We present a case of heme pigment–induced AKI following an AngioJet procedure that required initiation of dialysis. Although this rare complication has been reported in the literature, it typically occurs when the procedure is used for larger clot burden (ie, venous thromboembolism). To our knowledge, this is the first case of severe hemolysis with associated AKI following the use of the AngioJet for a thrombosed DIPS. Due to the patient’s comorbid conditions, overlapping clinical features, and lack of appreciation of the hemolysis associated with the AngioJet system, the differential diagnosis of the patient’s AKI was quite broad. Nephrologists should be aware of this complication when managing patients with AKI to direct therapy early and avoid unnecessary diagnostic and therapeutic interventions.

## Abrégé

**Justification:** Le système AngioJet<sup>MC</sup> est un dispositif combinant la mécanique et la pharmacologie utilisé pour la thrombectomie. À la suite de la rupture mécanique du caillot, on constate une hémolyse intravasculaire qui, dans de rares cas, peut être suffisamment grave pour provoquer une insuffisance rénale aiguë (IRA) induite par les pigments de l’hème.

**Présentation du cas:** Nous présentons le cas d’un homme de 45 ans atteint d’une cirrhose de catégorie B selon le score Child Pugh, du syndrome de Budd-Chiari et du syndrome des antiphospholipides, et qui nécessitait une thrombectomie à la suite d’une dérivation porto-systémique intrahépatique (DIPS) directe thrombosée. Dans les 24 heures suivant la procédure, le patient a présenté des signes d’aggravation de l’anémie, des urines foncées, une hémolyse intravasculaire négative au test de Coombs direct et une grave IRA.

**Diagnostic:** L’association d’une grave IRA à des taux élevés de marqueurs hémolytiques et le lien temporel avec la procédure AngioJet<sup>MC</sup> ont mené au diagnostic d’IRA induite par les pigments de l’hème et secondaire à une hémolyse intravasculaire.

**Interventions:** Le patient est demeuré anurique et s’est retrouvé en surcharge volumique après la réanimation liquidienne. Un traitement de dialyse a été initié 72 heures après la procédure. Les taux de marqueurs hémolytiques sont revenus à la normale cinq jours après la thrombectomie.

**Résultats:** Le patient a été hémodialysé environ trois semaines, après quoi la récupération rénale a été constatée et la dialyse a été cessée. Cinq semaines après la procédure AngioJet<sup>MC</sup>, la fonction rénale du patient était revenue à la normale.



**Conclusions:** Nous présentons un cas d'IRA induite par les pigments de l'hème à la suite d'une procédure AngioJet<sup>MC</sup> pour laquelle un traitement de dialyse a été nécessaire. Bien que cette rare complication soit rapportée dans la littérature, elle survient généralement lorsque la procédure est employée pour des embolies plus importantes (une thromboembolie veineuse, par exemple). À notre connaissance, il s'agit du premier cas d'hémolyse grave associée à une IRA survenue à la suite de l'utilisation du système AngioJet<sup>MC</sup> pour traiter une DIPS thrombosée. En raison des maladies concomitantes du patient, du chevauchement des manifestations cliniques et du manque de compréhension de l'hémolyse associée au système AngioJet<sup>MC</sup>, le diagnostic différentiel de l'IRA était plutôt large. Les néphrologues devraient garder cette complication à l'esprit lorsqu'ils prennent en charge un patient atteint d'IRA afin d'orienter rapidement le traitement et d'éviter les diagnostics et interventions inutiles.

### Keywords

AKI, hemolysis, AngioJet, thrombectomy, dialysis

Received July 28, 2020. Accepted for publication October 18, 2020.

### Introduction

Percutaneous pharmacomechanical thrombectomy systems (PMT) have been used in both venous<sup>1</sup> and arterial<sup>2</sup> thrombotic syndromes and also for the management of vascular access thrombosis.<sup>3</sup> The AngioJet thrombectomy system (Boston Scientific, Natick, MA, USA) is one such device. It employs high-pressure saline pulses combined with thrombolytic pharmacotherapy to disrupt clot. Potential benefits over mechanical thrombectomy or pharmacotherapy alone include a lower incidence of post-thrombotic syndrome, lower volume of thrombolytic, shorter treatment time, and less bleeding.<sup>4</sup>

Complications of PMT include bleeding, vascular trauma, arterial emboli, arrhythmias, and rarely pancreatitis and hepatitis.<sup>2,3,5</sup> In addition, intravascular hemolysis is a frequent complication of the AngioJet system, mediated by destruction of red blood cells by high-pressure saline pulses.<sup>6,7</sup> The degree of hemolysis can be severe enough to cause acute kidney injury (AKI) secondary to heme pigment-induced nephropathy.<sup>8-10</sup> We report a case of intravascular hemolysis associated with severe AKI following the use of the AngioJet system for a thrombosed direct intrahepatic portosystemic shunt (DIPS).

### Case Report

#### Presenting Concerns

A 45-year-old man with a history of Child-Pugh class B cirrhosis from Budd-Chiari syndrome required thrombectomy

for a thrombosed DIPS using the AngioJet system. He developed hemolysis and AKI within 24 hours of the procedure.

#### Clinical Findings

The patient was diagnosed with Child-Pugh class B cirrhosis and Budd-Chiari syndrome approximately before 3 months. A workup for Budd-Chiari syndrome revealed a persistently positive anticardiolipin IgG titer of >40 U. The patient was diagnosed with primary antiphospholipid antibody syndrome (APS) and was commenced on warfarin. Other causes of Budd-Chiari syndrome were excluded based on lab tests or clinical presentation.

The patient was otherwise healthy and worked as a researcher. Family and social history were noncontributory. He denied any over-the-counter remedies. After his Budd-Chiari diagnosis, medications included warfarin (international normalized ratio [INR] target 2-3), furosemide, and spironolactone.

Shortly after his diagnosis of Budd-Chiari, due to worsening hepatic synthetic function, he underwent a DIPS procedure (portal vein to inferior vena cava [IVC]). A traditional transjugular intrahepatic portosystemic shunt (TIPS) was not feasible as hepatic veins were occluded. Four weeks after successful placement of DIPS, the patient had worsening ascites. Outpatient diuretics were increased with improvement (furosemide 40 mg daily, spironolactone 100 mg daily). A Doppler ultrasound and computed tomography of the abdomen with intravenous contrast were performed shortly after (Figure 1). Despite a therapeutic INR, both modalities

<sup>1</sup>Department of Medicine, University of Saskatchewan, Saskatoon, Canada

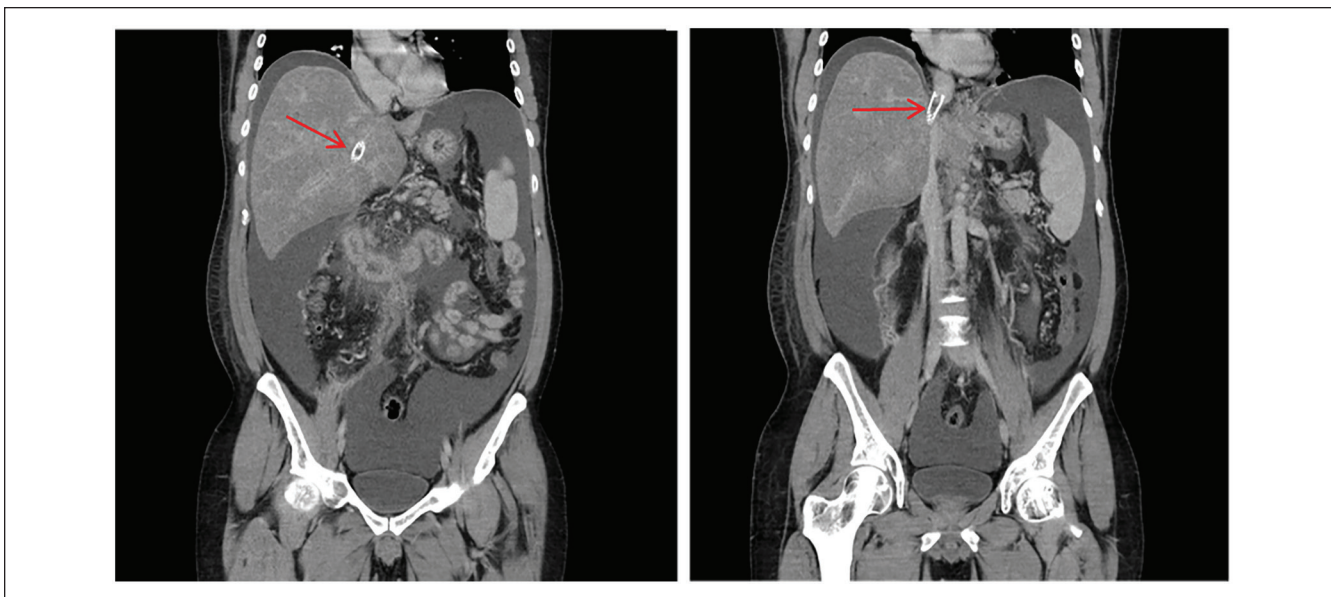
<sup>2</sup>Department of Medical Imaging, University of Saskatchewan, Saskatoon, Canada

<sup>3</sup>Division of Nephrology, Department of Medicine, University of Saskatchewan, Saskatoon, Canada

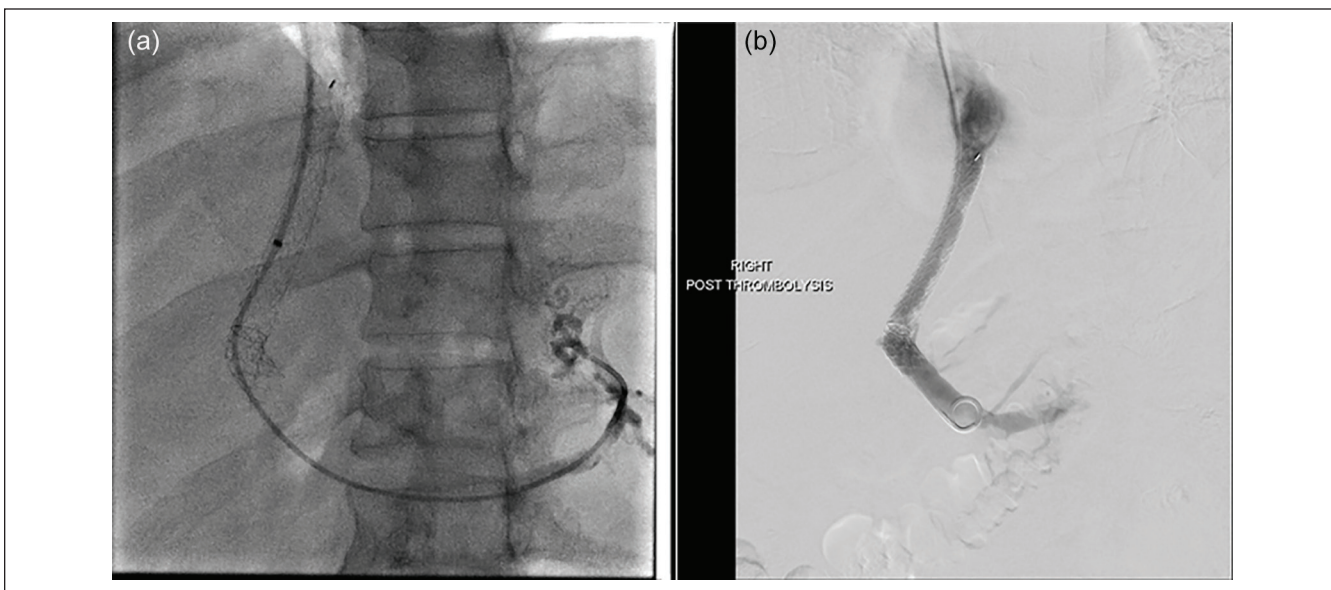
#### Corresponding Author:

Sachin Shah, Division of Nephrology, Department of Medicine, University of Saskatchewan, St. Paul's Hospital, 434-230 Avenue R South, Saskatoon, SK, Canada S7M 2Z1.

Email: Sjs479@mail.usask.ca



**Figure 1.** Coronal contrast-enhanced computed tomographic images in portal venous phase demonstrate hypodense thrombus (red arrows) within the direct intrahepatic portosystemic shunt stent. Note the density of contrast within the inferior vena cava and heart for comparison. There is also marked ascites and patchy enhancement of the liver parenchyma.



**Figure 2.** (a) A pre-AngioJet fluoroscopic image with a catheter through the DIPS stent from a right internal jugular approach. Contrast has been injected into the splenic vein, demonstrating some filling of small splenic collaterals but no flow through the DIPS. (b) A digital subtraction angiogram demonstrating flow through the portal vein, DIPS shunt, and into the right atrium after treatment. DIPS = direct intrahepatic portosystemic shunt.

were confirmed in stent thrombosis. He was admitted to hospital 1 week later for PMT with the AngioJet system (Figure 2). The AngioJet activation time was 124 seconds, with 10 mg of tissue plasminogen activator being infused directly into clot. Twenty milliliters of Isovue 300 contrast was used intravenously. Before thrombectomy, he was given a single dose of naproxen 500 mg. After the procedure, there was significant oozing from the access site (right internal

jugular vein) for 48 hours, which required pressure to control. There was no other source of bleeding and no symptoms of any infectious foci.

On initial examination, vital signs were stable with a blood pressure of 106/68 mm Hg. There was no documented hypotension, tachycardia, or fevers leading up to or during his admission. Cardiac and respiratory examination was normal. He had no ascites or edema on examination.

## Diagnostic Focus and Assessment

Table 1 reveals his laboratory investigations over time. On the day of admission, his creatinine was 112  $\mu\text{mol/L}$ . On postoperative day (POD) 1, he developed transient gross hematuria, followed by dark brown urine, and his creatinine increased to 306  $\mu\text{mol/L}$ . He became progressively oliguric. Potassium and bicarbonate remained normal throughout his admission.

Due to near oligo-anuria and reluctance for a Foley catheter, only 1 urinalysis was collected. The urine dipped positive for blood and protein. Microscopy was not performed. Urine sodium was 29 mmol/L, and his fractional excretion of sodium (FeNa) was 0.98%. His glomerulonephritis workup, including antinuclear antibody, double-stranded DNA, anti-neutrophil cytoplasmic antibodies, hepatitis B and C serology, and HIV serology, was negative. C3 was 0.89 g/L (normal range, 0.9-2 g/L) and C4 was normal. Blood cultures were negative. Of note, anti-glomerular basement membrane (GBM) testing using the ELISA technique was positive, but negative via immunofluorescence testing. On POD 8, a second sample was sent for anti-GBM testing and was confirmed negative via both testing methods. Renal ultrasound with Doppler revealed normal kidney size and patent renal arteries and veins.

The patient's hemoglobin dropped acutely following the procedure, requiring 1 unit of packed red blood cells. The prolonged bleeding from his puncture site was initially thought to be the cause of his anemia. With this in mind, along with the contrast exposure needed for thrombectomy and the recent increase in diuretic doses, initial explanations for the patient's AKI included acute tubular necrosis (ATN). However, the lack of hypotension, small contrast load, low FeNa, and findings on urinalysis pointed away from this diagnosis. Hepatorenal syndrome (HRS) was also considered; however, his stable liver function, rapidity of his worsening renal function, and findings on urinalysis made this less likely.

On POD 2, evidence of active hemolysis was noted on review of previous bloodwork. Direct antiglobulin test was negative. Peripheral blood smear on POD 3 showed minimal (<1%) schistocytes. Pink plasma was noted by the pathologist. ADAMTS13 and genetic screen for complement abnormalities were negative.

## Therapeutic Focus and Assessment

The patient was initially admitted to internal medicine to expedite his thrombectomy. Diuretics were withdrawn, and he was hydrated with crystalloid and intravenous albumin for presumption of mild pre-renal AKI (see Table 1). Warfarin was discontinued on admission given his clot burden despite anticoagulation and bleeding from his procedural puncture site. Five milligrams of oral vitamin K was given on POD 1 due to ongoing oozing from the puncture site. Once

bleeding was controlled, he was placed on unfractionated heparin while awaiting definitive therapeutic options. Nephrology was consulted on POD1 and fluid resuscitation was continued.

Once intravascular hemolysis was identified, concerns of a thrombotic microangiopathy (TMA) secondary to antiphospholipid antibody syndrome were raised. The patient received a 3-day pulse of methylprednisone 1 g/day (POD 2-4), and we attempted plasmapheresis (POD 4). Unfortunately, the patient developed anaphylaxis within the first hour of treatment. On further reflection, the lack of significant schistocytes, rapid improvement in hemolytic markers, and relative stability in platelets without meaningful treatment made TMA an unlikely diagnosis. Plasmapheresis and steroids were stopped.

After a review of the literature, the patient's dark urine, hemolysis, and recent thrombolysis were more consistent with isolated intravascular hemolysis and heme pigment-induced nephropathy. The patient was treated supportively with hemodialysis beginning on POD 3 for persistent anuria and worsening volume overload. He was discharged home 18 days after the initial AngioJet procedure to continue outpatient dialysis.

## Follow-up and Outcomes

The patient's hemolysis resolved by POD 5. He continued to receive dialysis for a total of 3 weeks, after which dialysis was stopped. His renal function normalized 35 days after the procedure.

## Discussion

We present a case of AKI where the diagnostic and therapeutic considerations changed as the case unfolded. The initial diagnostic consideration for our patient's AKI was ATN secondary to outpatient diuresis, pre-procedural nonsteroidal anti-inflammatory drug, access site bleeding, and venous contrast load. As bilirubin increased on POD 1 and renal function continued to decline despite aggressive hydration, we also explored the possibility of HRS. However, both etiologies were excluded based on urinalysis. Furthermore, the degree of pre-renal insult and lack of significant risk factors for contrast-induced nephropathy made ATN unlikely. The rate of rise in creatinine seemed too explosive for even type 1 HRS, and the stability in liver function also made this diagnosis unlikely. Considerations shifted to APS-related TMA when indirect bilirubin was identified as the primary source of bilirubin. Ultimately, given the spontaneous resolution of our patient's hemolysis and AKI, the lack of common clinical findings associated with APS-related renal disease (ie, hypertension),<sup>11,12</sup> and the temporal association with the thrombectomy procedure, a self-limiting mechanical hemolysis better explained the presentation. Notably, the patient's positive anti-GBM on ELISA testing was felt to be false

**Table 1.** Timeline of Events.

Time	Event	Hemoglobin, g/L (hematocrit, L/L)	Platelets, ×10 <sup>9</sup> /L	Creatinine, μmol/L	Lactate dehydrogenase, μ/L	Haptoglobin, g/L	Total bilirubin (direct)	INR	Miscellaneous
Day 30	Inpatient labs (on warfarin)	143 (0.437)	199		300	0.41	87 (30)	2.3	
Day 2	Routine outpatient bloodwork	162 (0.492)	228	77	N/A	N/A	55 (27)	3.3	
Day 1	Admission to hospital, warfarin held	166 (0.501)	193	112	N/A	N/A	54 (31)	3.5	
Day 0	Pre-thrombectomy	148 (0.441)	149	N/A	N/A	N/A	N/A	N/A	
Day 0	4 hours after thrombectomy	133 (0.386)	137	121	N/A	N/A	N/A	3.9	
Day 1	Worsening anemia and oliguric AKI.	124 (0.363)	152	306	1738	<0.1	133 (27)	2.5	U/A: Blood and protein (dark urine)
Day 2	Nephrology consulted Transfused 1 unit of PRBCs	66 (0.189)	134	569	N/A	N/A	103	2.2	
Day 3	Initiated dialysis	79 (0.226)	135	702			114	1.9	Schistocytes < 1%
Day 4	Plasmapheresis treatment	72 (0.212)	105		804	<0.1	83 (42)		Schistocytes < 1%
Day 5	Ongoing dialysis with normalization of hemolytic markers	70 (0.203)	96		508	0.4	54 (32)	1.3	
Day 22	Last outpatient dialysis	N/A	N/A	450	N/A	N/A	N/A		2L urine output
Day 35	Outpatient labs	105 (0.311)	170	96	N/A	N/A	31 (14)		

AKI = acute kidney injury; PRBC = packed red blood cell.

positive; hemolysis is known to cause interference with this form of testing.<sup>13</sup> Indeed, when the hemolysis had resolved, our patient's repeat anti-GBM antibody testing using ELISA was negative.

Pigment nephropathy is a form of AKI secondary to heme pigments, which are released from myoglobin (rhabdomyolysis) or hemoglobin (intravascular hemolysis). When hemolysis occurs, plasma proteins, such as haptoglobin, bind to free hemoglobin to mitigate its deleterious effects. Massive hemoglobin release can occur in the context of intravascular hemolysis. In these circumstances, the release of free hemoglobin overwhelms binding proteins, and free hemoglobin is filtered into the glomerulus where it causes renal injury via vasoconstriction, oxidative stress, direct tubular injury, and tubular obstruction.<sup>14</sup> This can result in oliguric AKI.

Laboratory features of heme pigment-induced nephropathy include anemia, thrombocytopenia, elevated lactate dehydrogenase, low haptoglobin, high total bilirubin, high reticulocyte, and elevated transaminases. Urinalysis is significant for hemoglobinuria and variable proteinuria. Gross hematuria may be present.<sup>14</sup> Following centrifugation, urine may be pink/red without any discoloration of the centrifuged pellet. Microscopy may reveal ATN casts. Importantly, an absence of red blood cells is noted. Other markers of hemolysis such as hyperkalemia, hyperphosphatemia, and pink plasma may also be present. Pigment nephropathy may have an FeNa <1% despite established ATN.<sup>15</sup> This may be reflective of concurrent hypovolemia and vasoconstriction and was consistent with our patient's labs. Prevention of AKI with intravenous crystalloid fluids remains the mainstay of treatment. However, there is a paucity of data on the best choice of fluids (ie, alkalization vs normal saline). Once AKI has been established, treatment is largely supportive.

AngioJet is a type of PMT device that creates a hydrodynamic recirculation vortex that fragments and traps the adjacent thrombus. It has the ability to infiltrate the thrombus with a thrombolytic before mechanical fragmentation. While generally well tolerated, some degree of intravascular hemolysis occurs in the majority of patients.<sup>6</sup> A study by Vesely et al showed an average 4-fold increase in free hemoglobin immediately after AngioJet, whereas the surgical thrombectomy group did not have a meaningful change in free hemoglobin.<sup>6</sup> AKI following PMT is also a well-described complication with an incidence as high as 30% in some reports.<sup>8,9</sup> Notably, patients treated with AngioJet are at higher risk of AKI if there is a greater than 10% drop in hematocrit.<sup>8</sup> Our patient's hematocrit dropped by 20%.

Although AKI is not uncommon after AngioJet, dialysis-dependent AKI is quite rare. A retrospective study by Escobar et al, showed 2 out of 52 patients required dialysis after using AngioJet.<sup>8</sup> The Peripheral Use of AngioJet Rheolytic Thrombectomy with a Variety of Catheter Lengths (PEARL) registry, which followed 283 patients with acute limb ischemia, found that 4 patients developed dialysis-dependent renal failure. Dialysis dependence was permanent in 3 of these patients.<sup>2</sup> In contrast, other studies

have shown dialysis-dependent AKI typically resolves by 25 days, approximately.<sup>9,10</sup>

Portosystemic shunts are a known cause of intravascular hemolysis. In a study by Sanyal et al, 7 of 60 patients developed TIPS-associated hemolysis within 4 weeks of the procedure.<sup>16</sup> Six of the 7 patients achieved spontaneous resolution of the hemolysis within 12 weeks, and there were no reported cases of AKI in this series. In our case, the hemolysis occurred on POD 1 of PMT, was associated with severe AKI, and the hemolysis resolved within 5 days. This clinical course makes DIPS an unlikely source of our patient's hemolysis and AKI.

Our case is unique for several reasons. First, it proved to be a diagnostic challenge given the patient's comorbidities and overlapping clinical findings. Second, to our knowledge, this is the first reported case of heme pigment-induced nephropathy following an AngioJet procedure for a thrombosed portosystemic shunt. This bears mentioning, as the clot burden in our case was quite small. Most published case reports of the AngioJet procedure leading to hemolysis and AKI are in the setting of venous thromboembolism, where clot burden would be considered to be greater and AngioJet treatment time longer than in our case. Furthermore, the degree of hemolysis is thought to be proportional to the treatment time with the AngioJet system,<sup>17</sup> but our patient's run time was only 124 seconds. Indeed, the product monograph for the AngioJet system suggests maximum treatment times of 480 seconds for the AngioJet Zelante catheter, which was used in this case.<sup>18</sup> Although there is a relationship between total run time and degree of hemolysis, this is clearly not the only variable, given the outcome in our patient after a short AngioJet run time. It is possible that the proximity of our patient's thrombus to the IVC allowed for more widespread distribution of the heme pigment. In addition, prompt recognition of the patient's hemolysis and more aggressive fluid resuscitation earlier in the clinical course may have been beneficial. Combining this with the patient's comorbidities, we postulate that our patient was at high risk of heme pigment-induced nephropathy even with the short treatment time and relatively small clot burden.

We acknowledge several limitations to our report. First, there is a paucity of relevant lab data. Specifically, our patient was admitted with a creatinine above his baseline. Although we suspected a pre-renal etiology, no creatinine was drawn the morning of the procedure (after a trial of intravenous fluids), only 4 hours after. As such, we cannot definitively exclude a second, co-existing cause of the patient's AKI. However, the elevated hematocrit on admission is suggestive of a hypovolemic state. Hemolytic markers were not repeated until POD 4 due to a delay in diagnosis until POD 2 and lab error on POD 3, which makes interpreting the severe anemia spanning from POD 1 to 5 difficult. We contend there were additional factors contributing to the anemia after the initial hemolytic insult, including hemodilution from fluids and oozing from surgical site. In addition, due to the patient's near anuria, urine microscopy was not done. Evidence of hemoglobinuria and granular casts without red blood cells would have strengthened our diagnosis. Finally, we observed

a smaller number of schistocytes and lower phosphate level than expected. This was likely due to delay in obtaining both labs until after hemolytic markers had already improved.

A renal biopsy would have strengthened our diagnosis. However, in light of the spontaneous improvement in hemolytic markers and the high risk of bleeding in a cirrhotic patient with thrombocytopenia and need for anticoagulation, we felt the risks of a biopsy outweighed the benefits. Typical biopsy findings of heme pigment nephropathy include tubular injury with pigmented tubular casts that stain positive for hemoglobin. Electron microscopy may have shown podocyte injury mediated through oxidative stress and apoptosis.<sup>19</sup>

In conclusion, severe intravascular hemolysis causing heme pigment nephropathy can occur after PMT. Although this complication is well documented in surgical and interventional radiology literature, nephrologists should also be familiar with this complication when evaluating patients with AKI after PMT. Consideration should be given to pre-hydration for patients undergoing an AngioJet procedure, particularly when additional risk factors for AKI are present.

### Ethics Approval and Consent to Participate

We would like to thank our patient for his consent to publish this case.

### Consent for Publication

All authors reviewed the final manuscript and consented to publication.

### Availability of Data and Materials

All data and materials can be made available on request.

### Acknowledgments

We thank our patient for his trust and his consent to publish this case.

### Declaration of Conflicting Interests

The author(s) declared no potential conflicts of interest with respect to the research, authorship, and/or publication of this article.

### Funding

The author(s) received no financial support for the research, authorship, and/or publication of this article.

### ORCID iD

Sachin Shah  <https://orcid.org/0000-0003-2809-1023>

### References

1. Kasirajan K, Gray B, Ouriel K. Percutaneous AngioJet thrombectomy in the management of extensive deep venous thrombosis. *J Vasc Interv Radiol*. 2001;12(2):179-185.
2. Leung DA, Blitz LR, Nelson T, et al. Rheolytic pharmacomechanical thrombectomy for the management of acute limb ischemia: results from the PEARL registry. *J Endovasc Ther*. 2015;22(4):546-557.
3. Chan PG, Goh GS. Safety and efficacy of the AngioJet device in the treatment of thrombosed arteriovenous fistula and grafts: a systematic review. *J Vasc Access*. 2018;19(3):243-251.
4. Wong P, Chan Y, Law Y, Cheng SWK. Percutaneous mechanical thrombectomy in the treatment of acute iliofemoral deep vein thrombosis: a systematic review. *Hong Kong Med J*. 2019;25(1):48-57.
5. Urdaneta J, Arroyo D, Mon C, et al. Acute haemolytic pancreatitis and hepatitis secondary to percutaneous pharmacomechanical thrombectomy of prosthetic vascular access for haemodialysis. *Nefrologia*. 2019;39:104-105.
6. Vesely TM, Williams D, Weiss M, et al. Comparison of the AngioJet rheolytic catheter to surgical thrombectomy for the treatment of thrombosed hemodialysis grafts. *J Vasc Interv Radiol*. 1999;10:1195-1205.
7. Zhu J, Ni C-F, Dai Z-Y, Yao LZ, Li WH. A case-controlled study on AngioJet rheolytic thrombectomy and catheter-directed thrombolysis in the treatment of acute lower extremity deep venous thrombosis. *Vascular*. 2020;28(2):177-182.
8. Escobar GA, Burks D, Abate MR, et al. Risk of acute kidney injury after percutaneous Pharmacomechanical Thrombectomy using AngioJet in venous and arterial thrombosis. *Ann Vasc Surg*. 2017;42:238-245.
9. Morrow KL, Kim AH, Plato SA, et al. Increased risk of renal dysfunction with percutaneous mechanical thrombectomy compared with catheter-directed thrombolysis. *J Vasc Surg*. 2017;65(5):1460-1466.
10. Dukkipati R, Yang EH, Adler S, Vintch J. Acute kidney injury caused by intravascular hemolysis after mechanical thrombectomy. *Nat Clin Pract Nephrol*. 2009;5(2):112-116.
11. Fakhouri F, Noël LH, Zuber J, et al. The expanding spectrum of renal diseases associated with antiphospholipid syndrome. *Am J Kidney Dis*. 2003;41(6):1205-1211.
12. Nochy D, Daugas E, Droz D, et al. The intrarenal vascular lesions associated with primary antiphospholipid syndrome. *J Am Soc Nephrol*. 1999;10(3):507-518.
13. Saracevic A, Dukic L, Simundic A-M. Haemolysis and lipemia interfere with resistin and myeloperoxidase BioVendor ELISA assays. *Biochem Med*. 2019;29:315-321.
14. Dvanajscak Z, Walker PD, Cossey LN, et al. Hemolysis-associated hemoglobin cast nephropathy results from a range of clinicopathologic disorders. *Kidney Int*. 2019;96(6):1400-1407.
15. Corwin HL, Schreiber MJ, Fang LS. Low fractional excretion of sodium. Occurrence with hemoglobinuric- and myoglobinuric-induced acute renal failure. *Arch Intern Med*. 1984;144:981-982.
16. Sanyal AJ, Freedman AM, Purdum PP, Shiffman ML, Luketic VA. The hematologic consequences of transjugular intrahepatic portosystemic shunts. *Hepatology*. 1996;23(1):32-39.
17. Nazarian GK, Qian Z, Coleman CC, et al. Hemolytic effect of the Amplatz thrombectomy device. *J Vasc Interv Radiol*. 1994;5(1):155-160.
18. Boston Scientific. ANGIOJET catheter reference guide. [https://www.bostonscientific.com/content/dam/bostonscientific/pi/portfolio-group/Catheter%20Thrombectomy/AngioJet/Resources/AngioJet-Reference-Guide\\_PI-282523-AA.pdf](https://www.bostonscientific.com/content/dam/bostonscientific/pi/portfolio-group/Catheter%20Thrombectomy/AngioJet/Resources/AngioJet-Reference-Guide_PI-282523-AA.pdf)
19. Esteras R, Cannata-Ortiz P, del Palacio-Tamarit M, et al. Podocyte and tubular involvement in AngioJet-induced kidney injury. *Clinical Kidney Journal*. 2019. <https://doi.org/10.1093/ckj/sfz104>