

Multicentric Castleman disease of hyaline-vascular variant with paraneoplastic pemphigus results in abnormal lung function: Report of 3 cases

JIEMEI CEN^{1,2}, WEN ZENG³, MIANLUAN PAN¹, YE QIU¹ and JIANQUAN ZHANG¹

¹Department of Respiratory Medicine, The Eighth Affiliated Hospital, Sun Yat-Sen University, Shenzhen, Guangdong 518033; ²Department of Respiratory Medicine, The Third Affiliated Hospital, Sun Yat-sen University, Guangzhou, Guangdong 510630; ³Department of Respiratory Medicine, The First Affiliated Hospital of Guangxi Medical University, Nanning, Guangxi 530000, P.R. China

Received November 30, 2022; Accepted March 22, 2023

DOI: 10.3892/etm.2023.11968

Abstract. Castleman disease (CD) is clinically divided into unicentric CD (UCD) and multicentric CD (MCD). Hyaline-vascular variant (HV) is the most common pathological type of UCD, while the plasma cell type (PC) is the most common type of MCD and thus, hyaline-vascular variant multicentric CD (HV-MCD) is a rare type of CD. In addition, its etiology has remained elusive. The present study retrospectively analyzed the medical records of 3 patients diagnosed as HV-MCD admitted to The First Affiliated Hospital of Guangxi Medical University (Guangxi, China) between January 2007 and September 2020. A total of 2 males and 1 female were admitted. The areas involved varied considerably. Respiratory symptoms were seen in 3 cases, along with fever, weight loss and splenomegaly. Damage to the skin and mucous membranes resulted in oral ulcers when accompanied by paraneoplastic pemphigus (PNP). Dry and wet rales were found in all patients. All 3 cases were complicated with PNP and had hypoxemia and obstructive ventilation dysfunction. In accordance with PC-MCD, it manifested as lymph node enlargement and may involve several lymph nodes. Computed tomography mainly indicated bronchiectasis and mediastinal lymph node enlargement. In 1 case, chemotherapy failed after local mass excision, 1 case remitted after chemotherapy but

the lung lesion was irreversible and 1 case was untreated and soon died of respiratory failure. The cases of HV-MCD with pulmonary involvement were induced by small airway lesions and associated with poor prognosis. Respiratory symptoms along with systemic symptoms were common.

Introduction

Castleman disease (CD) was previously known as giant lymphadenopathy, angiolymphatic hamartoma or angiofollicular lymph node hyperplasia. The etiology remains elusive and shares certain clinical and pathological features with viral infection, tumors and autoimmune disease (1). The hyaline-vascular variant was mostly seen in unicentric CD and UCD has no obvious symptoms or produces corresponding compression symptoms due to enlarged lymph nodes pressing on adjacent tissues. When accompanied by paraneoplastic pemphigus (PNP), the skin and mucosa of the mouth may be damaged, and oral ulcers and rashes may appear along with lung involvement. However, the clinical manifestations of multicentric CD (MCD) are heterogeneous but not specific, which may include multiple regional lymph node enlargement, recurrent systemic symptoms (weight loss, fever, fatigue), anemia, edema, hypoproteinemia, and involvement of multiple important organs, such as lung, liver, spleen and kidney, and the prognosis is worse than that of UCD. Hyaline-vascular variant MCD (HV-MCD) is a relatively rare clinical type and particularly those cases with pulmonary involvement are rarely described in this subcategory (2). However, previous case reports were lacking details of pulmonary involvement. Thus, to improve the understanding of the clinical characteristics of this rare type, the clinical data of 3 patients admitted to the hospital were systematically and retrospectively analyzed.

Case presentations

Case 1. A 16-year-old male patient was admitted to the local hospital due to 'abdominal mass accompanied by fever, oral ulcer and shortness of breath for one and a half years, which had worsened for three months'. In January 2008, the patient

Correspondence to: Dr Jianquan Zhang, Department of Respiratory Medicine, The Eighth Affiliated Hospital, Sun Yat-Sen University, 3025 Shennan Middle Road, Futian, Shenzhen, Guangdong 518033, P.R. China
E-mail: jqzhang2002@126.com

Abbreviations: UCD, unicentric Castleman disease; HV, hyaline-vascular variant; MCD, multicentric Castleman disease; PC, plasma cell type; CT, computed tomography; PNP, paraneoplastic pemphigus; BO, bronchiolitis obliterans

Key words: HV-MCD, clinical features, prognosis

noticed an abdominal mass without obvious inducement, accompanied by oral ulcer, fever, shortness of breath, cough, expectoration, abdominal pain and abdominal distension. In late March 2009, the patient developed shortness of breath, obvious during activities, but no chest tightness or chest pain. The patient was then admitted to the First Affiliated Hospital of Guangxi Medical University (Nanning, China) in June 2009. Physical examination on admission indicated splenomegaly, a mass could be palpated in the abdomen, lymph nodes of the size of soybeans could be palpated in the bilateral groins, and rales of dry and wet could be heard in both lungs. Laboratory tests indicated elevated white blood cells, IgM and reduced albumin, while the globulin, C-reactive protein (CRP), IgG and IgA levels were normal. Analysis of autoantibodies determined the following: Histone (+/-), keratin antibody (+), anti-nuclear antibody (+), anti-DS-DNA (+/-), anti-cardiolipin antibody (+) and desmoglein 3 (+). T-lymphocyte subsets were as follows: Total T cells, 78.2%; CD4+ cells, 39.4%; CD8+ cells, 33.4%; CD4/CD8 ratio, 1.18 (normal). IL-6 levels were 0.204 ng/l (normal range, 0.373-0.463 ng/l). Blood gas analysis was normal. Plain CT scan of the chest and abdomen revealed the following: i) Huge space-occupying lesion in the right posterior abdominal cavity; ii) splenomegaly; iii) emphysema, infectious lesions in the anterior segment of the right upper lobe, peripheral bronchiectasis, hyperinflation, uneven lung density, high-ventilation and low-ventilation areas mixed; iv) endogenous gas in the mediastinum and posterior chest wall (Fig. 1). Pulmonary function examination suggested the following: i) Severe obstructive ventilation dysfunction; ii) peripheral resistance, total airway resistance, peripheral elastic resistance all increased. The bronchial dilation test indicated that the absolute value of first second forced expiratory volume was increased by 70 ml. Right posterior abdominal mass resection was performed during hospitalization. Postoperative pathology indicated CD of lymph node HV. Oral mucosal biopsy revealed slight epithelial hyperplasia, basal cell liquefaction, spinous layer release and vascular hyperplasia in lamina propria, as well as lymphocyte infiltration. The diagnosis was as follows: i) Multicentric transparent vascular CD (left neck, right supraclavicular, bilateral axilla, inguinal lymph nodes); ii) paraneoplastic pemphigus; and iii) bronchiolitis obliterans (BO). No significant improvement was observed after treatment with methylprednisolone, aminophylline and bronchodilator. The symptoms were not improved after the treatment with the Cyclophosphamide, Vincristine and Prednisone regimen combined with interferon and the Cyclophosphamide, Doxorubicin, Vinblastine and Prednisone (CHOP) regimen. The patient was subsequently lost to follow-up.

Case 2. A 51-year-old male patient was admitted to the First Affiliated Hospital of Guangxi Medical University (Nanning, China) in November 2011 with 'cervical lymph node enlargement and exertive shortness of breath for 1 month'. In October 2011, the patient went to a local hospital due to 'inguinal hernia'. After physical examination, cervical lymph node enlargement was found. Positron emission tomography/CT examination revealed multiple nodules under the left neck, bilateral clavicle region and mediastinum, with an uneven increase in metabolism (Fig. 2A). Pathological examination of the left cervical lymph node revealed HV of giant lymph node hyperplasia

(CD). The patient gradually developed weight loss, shortness of breath, blood sputum, right chest pain and oral ulcer in late October. The patient then came to the First Affiliated Hospital for further diagnosis and treatment in November 2011. Physical examination revealed several lymph nodes of soybean size in the left neck and supraclavicular fossa. Dry and wet rales were found in both lungs. All results of blood routine examination, including albumin, globulin, IgG and IgA, and liver function and urine routine examination, were normal. IgM and creatinine were elevated and the endogenous creatinine clearance rate was reduced. T-cell subsets were as follows: CD4+T cells, 28.10%; CD8+T cells, 41.20%; CD4/CD8, 0.68; total T cells, 75.50% (normal). IL-6 levels were 0.501 ng/l (normal). Blood gas analysis revealed a high PCO₂. Chest CT revealed multiple mediastinal lymphadenopathies (Fig. 2C). The diagnosis was multicentric clear vascular CD (left lower neck, bilateral clavicular region, mediastinal lymph node). After four cycles of chemotherapy on the CHOP regimen, no significant reduction of mediastinal lymph nodes was observed. The fifth and sixth cycles of chemotherapy were changed to the Fluorouracil, Cisplatin and Docetaxel (FCD) regimen. In December 2011, chest CT indicated that the mediastinal multiple lymph node enlargement was slightly smaller than previously (Fig. 2A and C). In January 2013, the patient began to develop oral ulcer, which was diagnosed as 'pemphigus' at the Affiliated Stomatological Hospital of Guangxi Medical University (Nanning, China). The patient was treated with hydrocortisone, but there was no obvious improvement of oral ulcer. The patient stopped taking hormones in November 2013 and gradually developed discomfort, such as shortness of breath after activity. The patient returned to the hospital for treatment due to cough, sputum and shortness of breath after activity. During hospitalization, lung function examination was performed and the result was as follows: i) Severe obstructive ventilate dysfunction; ii) severe peripheral airway obstruction; and iii) severe diffuse dysfunction. The bronchial dilation test indicated that 20 min after inhalation of Ventolin, the FEV1 increased by 16.9%, and the absolute value of the FEV1 only increased by 90 ml. Antibody against desmoglein 3 (+) was detected. Chest CT indicated patchy, cable-like high-density and ground-glass shadows in both lungs, and multiple enlarged lymph node shadows were seen in the mediastinum. The diagnosis was as follows: i) CD; ii) paraneoplastic pemphigus; iii) interstitial pneumonia. The patient was given piperacillin sodium tazobactam, levofloxacin and fluconazole for anti-infective treatment. After discharge, the patient voluntarily switched to itraconazole but still had mild symptoms. In November 2013, the patient was admitted to the hospital, as cough, sputum and shortness of breath gradually worsened. Reexamination by chest CT indicated that the mediastinal lymph nodes had disappeared (Fig. 2B and D), but the lung lesion was irreversible with cavitation and was susceptible to respiratory infection.

Case 3. A 63-year-old female was admitted with left chest and left lower abdominal pain for >1 month. The patient complained of paroxysmal dull pain in the left chest and the left lower abdomen with no obvious cause in early January 2012, with oral ulcer, fever, nausea, vomiting, diarrhea and pain gradually aggravated, which affected the patient's sleep. At the local hospital, abdominal ultrasound was conducted

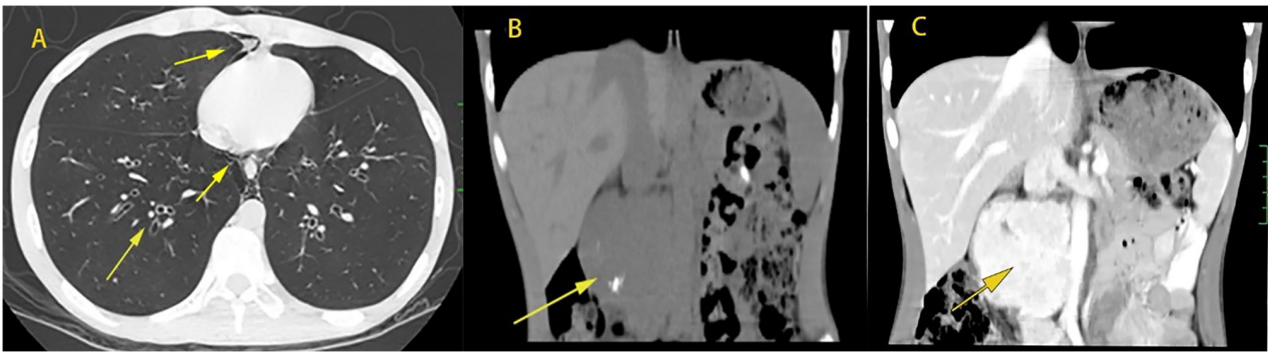


Figure 1. Case 1. 64-slice spiral CT, June 2009. (A) On a plain scan of the lung window, a patchy shadow of increased density is visible in the anterior segment of the right upper lobe (upper right arrow). Endogenous gas was present in the mediastinum and posterior chest wall (lower right arrow) and bronchiectasis (lower left arrow) was seen in both lungs. (B) On a plain scan, the density of the right posterior abdominal mass was uniform. (C) On enhanced CT, the right posterior abdominal mass was significantly enhanced.

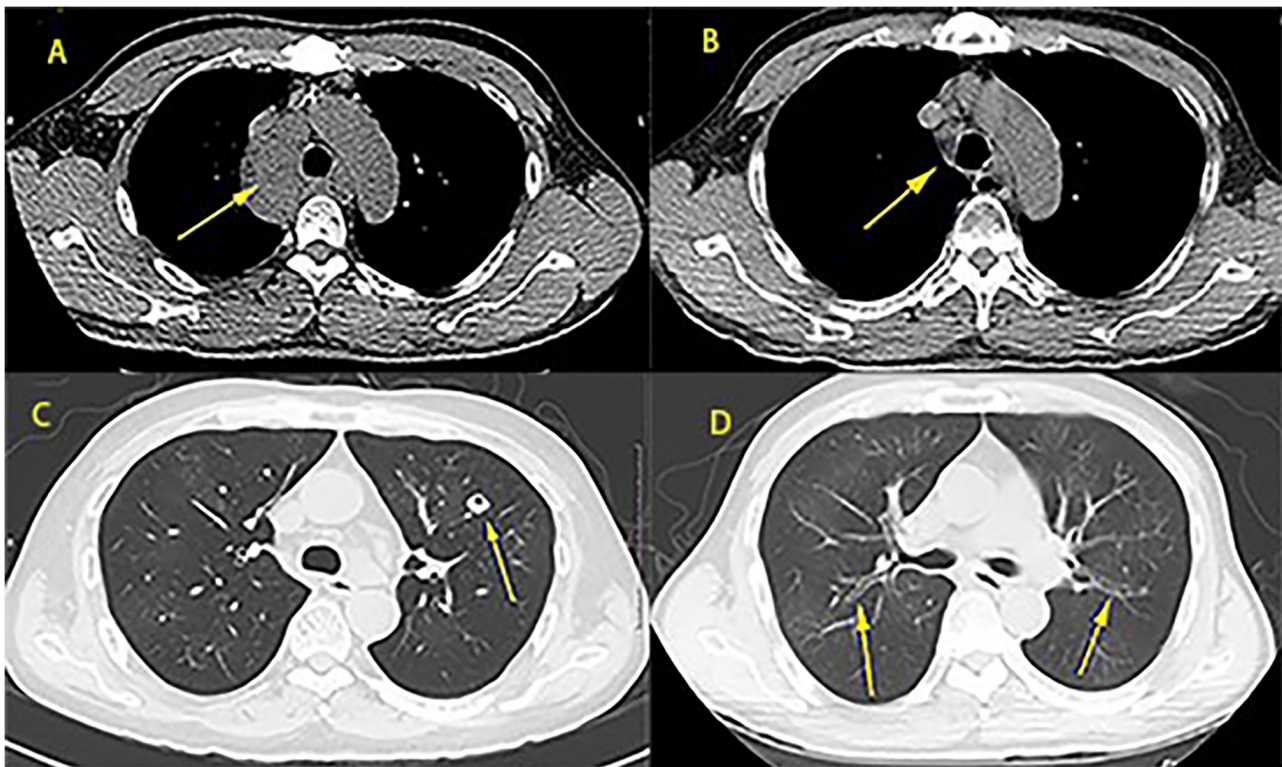


Figure 2. Case 2. (A) In October 2011, prior to treatment, mediastinal lymph node enlargement was observed (the arrow points at the enlarged mediastinal lymph node). (B) In April 2018, at the post-treatment review, the mediastinal enlarged lymph nodes had disappeared. (C) In October 2011, prior to treatment, a void was visible in the left lung. (D) In October 2018, bronchiectasis was observed in both lungs.

but no obvious abnormality was seen. Chest and abdominal CT indicated the following: Patchy high-density shadow in both lungs, peripheral bronchiole wall thickened, bronchiole dilatation with secretion retention, soft tissue mass shadow protruding into the left thoracic cavity near the spine of the left lower lung, irregular thickening and envelopment of the left pleura, as well as lymph node shadow of the mediastinal tracheal bulge (Fig. 3). Subsequently, a series of symptoms, including cough with a small amount of white foam-like sputum, decreased appetite and fatigue occurred. For further diagnosis and treatment, the patient was admitted to the First Affiliated Hospital of Guangxi Medical University (Nanning, China) in February 2012. Physical examination

indicated right supraclavicular lymph node enlargement. Complete blood routine examination revealed reduced hemoglobin and a high platelet count; CRP, globulin and IgG were elevated, while albumin was reduced, and IgM and IgA were normal. Autoantibodies were as follows: Anti-RO-52 antibody (+), desmoglein 3 (+) and the remaining indices were negative. IL-6 levels were 0.354 ng/l. No abnormality of renal function, routine urine and complement was observed. Pulmonary function examination was as follows: i) Mixed ventilatory dysfunction with mild limitation; ii) mild peripheral airway obstruction. Chest CT revealed a patchy high-density shadow in both lungs, irregular thickening of the left pleura with envelopment and lymph node shadow in the

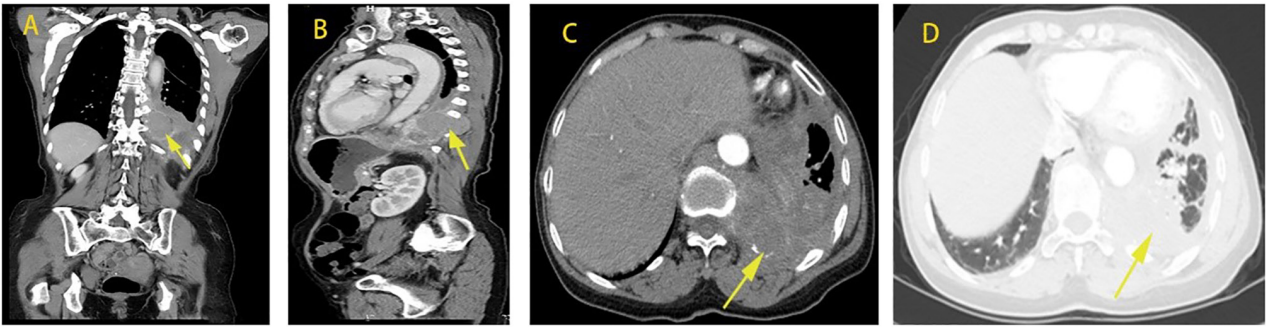


Figure 3. Case 3. Chest and abdominal CT in early January 2012. (A) Coronal view: A mass (the yellow arrow) is visible near the spine in the left lower thoracic cavity. The capsule is clear, but the diaphragm is not penetrated, accompanied by a small amount of pleural effusion in the left thoracic cavity. (B) Sagittal view: A mass may be observed in the left thoracic cavity, breaking through the posterior pleural cavity with a small amount of pleural effusion. (C) A mass is present near the spine of the left thoracic cavity, which breaks through the posterior pleural cavity, accompanied by left pleural effusion, and a patchy and cable-like exudative shadow of the left lung is present. (D) The enhancement of the left thoracic mass was not obvious.

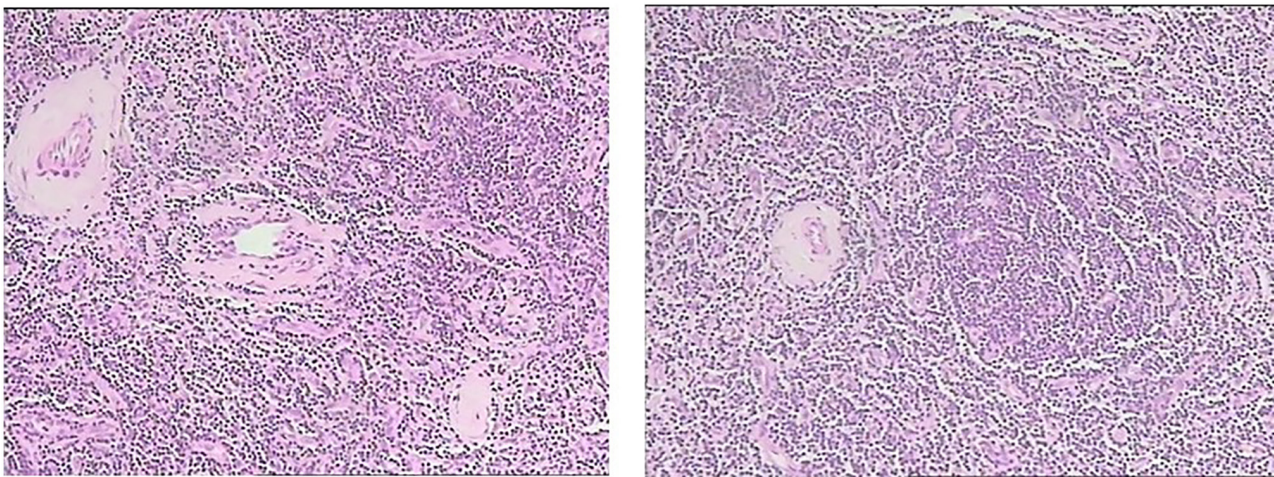


Figure 4. Histological features. Left panel: Postoperative pathology characteristics of case 1; right posterior abdominal mass resection of hyaline-vascular variant multicentric Castleman disease. Right panel: Pathological examination of the left cervical lymph node revealed a hyaline-vascular variant of giant lymph node hyperplasia of case 2 (magnification, 10x10).

mediastinal trachea. Fiber bronchoscopy indicated chronic bronchitis, a small amount of lung tissue, clear alveoli and no tumor. B-mode ultrasound indicated multiple enlarged lymph nodes in the left neck and right supraclavicular region and multiple hypoechoic masses in the bilateral axilla and inguinal region (lymph node sonography). Percutaneous lung penetration of the lower left lung mass: Microscopic observation revealed fibrous connective tissue, hyalinosis and small focal-like chronic inflammatory cell infiltration, with no histological evidence of granuloma or carcinoma. Microscopic examination of lymph nodes in the left neck indicated structural destruction of lymph nodes, atrophy of lymphatic follicles, hyperplasia of interstitial fibrous tissue with hyalinosis and hyalinosis in the vascular wall, which was consistent with giant lymph node hyperplasia (clear vascular type). The diagnosis was as follows: i) HV-MCD (left neck, right supraclavicular, bilateral axilla, inguinal lymph nodes); ii) paraneoplastic pemphigus; and iii) BO. After receiving anti-inflammatory, analgesic and other symptomatic supportive treatment, it was suggested that the patient consults the thoracic surgery department to evaluate whether surgical treatment may be performed, but the patient

refused and asked to be discharged when the condition did not improve and soon died of respiratory failure.

Summary of the three cases. All of the three cases were pathologically diagnosed with HV (Fig. 4) and were HIV-negative with no smoking history. In two of the three patients, the condition included mediastinum involvement and their clinical manifestations comprised common symptoms of respiratory diseases, such as cough, expectoration, shortness of breath and chest pain. Furthermore, all of the three patients had refractory oral ulcer, systemic symptoms such as emaciation and fever, splenomegaly and local compression symptoms, such as local lymph node enlargement or abdominal pain. With regard to laboratory results, anemia was more common (2/3 patients). Furthermore, elevated erythrocyte sedimentation rate (ESR), C-reactive protein (CRP) and immunoglobulin, as well as declined albumin may be seen in certain cases. Chest CT mainly indicated bronchiectasis and mediastinal lymph node enlargement, with flocculent, patchy and stripey high-density shadow. Blood gas analysis revealed hypoxemia and pulmonary function examination showed obstructive ventilation dysfunction; 1 case had mixed ventilation dysfunction with mild restrictive ventilation dysfunction.

Table I. General information and clinical manifestations of the 3 cases of hyaline-vascular variant multicentric Castleman disease.

Case no.	Age, years	Sex	Occupation	Clinical features	Involved regions
1	16	Male	Student	Fever, weight loss, shortness of breath, cough, sputum, abdominal pain, abdominal distention, oral ulcer, splenomegaly	Oral mucosa, abdominal cavity, bilateral inguinal lymph nodes
2	51	Male	Teacher	Neck lymph node enlargement, weight loss, shortness of breath, bloody sputum, chest pain, oral ulcer	Bilateral neck, supraclavicular fossa, mediastinum, abdomen
3	63	Female	Worker	Chest pain, abdominal pain, oral ulcer	Left neck, left supraclavicular fossa, mediastinum

Table II. Laboratory test results of the 3 cases of hyaline-vascular variant multicentric Castleman disease.

Parameter (normal range)	Case 1	Case 2	Case 3
WBC (3.5-9.5), x10 ⁹ /l	10.31	7.6	9.1
HGB (130-150), g/l	119	146	103
PLT (125-350), x10 ⁹ /l	329	286	523
N% (0.4-0.75)	0.67	0.548	0.696
L% (0.2-0.5)	0.251	0.208	0.145
ESR (0-15), mm/h	NA	NA	84
CRP (0-5), mg/l	1.8	N/A	31.13
ALB (40-55), g/l	27.5	44.5	29.2
GLB (20-40), g/l	26.5	27.5	41.5
A/G (1.2-2.4)	1.02	1.8	0.7
C3 (0.79-1.52), g/l	1.15	NA	1.35
C4 (0.16-0.38), g/l	0.34	NA	0.37
IgM (0.840-1.32), g/l	2.52	1.693	1.16
IgG (8-18), g/l	11.69	Normal	20.27
IgA (0.9-4.5), g/l	1.73	Normal	4.03
Creatinine (59-104), μmol/l	Normal	Normal	Normal
RF (0-12.5), IU/ml	2.6	NA	5.3
Autoantibodies	Histone (+/-), AKA (+) ANA (+), anti-ds-DNA (+/-), ACA (+)	NA	Ro-52 (+)
Tumor markers	Normal	NA	Normal
T-cell subsets			
Total T, % (62.6-76.8)	78.2	75.50	NA
CD4+T, % (30-46)	39.4	28.10	NA
CD8+T, % (19.2-33.6)	33.4	41.20	NA
CD4/CD8 (0.95-2.13)	1.18	0.68	NA

NA, not available.

The bronchial dilation test was normal. Physical examination and other auxiliary examinations confirmed the polycentric diagnosis of CD (Tables I-IV).

Discussion

The main pathological type of UCD is HV. Except for local tumor compression symptoms, there are generally no systemic symptoms. Chest CT typically displays isolated, well-bordered,

enlarged lymph nodes or localized nodular masses, with no other pulmonary involvement except for the masses (3-8). Abnormalities of Laboratory parameters are uncommon in HV-UCD and lung function is generally normal (9,10). Blood gas analysis indicated hypoxemia. Most of the pulmonary functions were obstructive ventilation dysfunction, and mosaic sign and other signs of BO could be seen on chest CT. In a study of 14 patients diagnosed with PNP, Mimouni *et al* (11) found 12 patients with HV-UCD, suggesting that PNP may be

Table III. Instrumental examination results of the 3 cases of hyaline-vascular variant multicentric Castleman disease.

Examination	Case 1	Case 2	Case 3
ECG	Sinus arrhythmia	Sinus rhythm, T wave changes	Normal
Abdominal ultrasound	Right abdominal mass of substance	Liver inner gallbladder wall thickened, echo enhancement, gallbladder stone	Normal
Urinary ultrasound	UE	Left kidney cyst	Normal
Others	Abdominal CT plain and enhanced: i) Huge space-occupying lesion in the right posterior abdominal cavity; ii) splenomegaly	Positron emission tomography/CT: Multiple nodules under the left neck, bilateral clavicle area and mediastinum, with uneven and increased metabolism masses (lymph nodes ranging from 3 to 7 mm), gallbladder stones and small left renal cyst considered	Uterorectal ultrasound: Depression and liquid dark area, 20x13 cm. Conclusion: Pelvic effusion

UE, unexamined.

Table IV. Results of blood gas analysis, respiratory function and bronchodilation test of the 3 cases of hyaline-vascular variant multicentric Castleman disease.

Parameter	Case 1	Case 2	Case 3
FEV1, %	23.3	18.8	69.4
FVC, %	67.2	48.6	77.6
FEV1/FVC, %	28.96	31.5	73.32
VC, %	67.1	46.9	77.1
Bronchial dilation test	Absolute value of FEV1 was increased by 70 ml	Absolute value of FEV1 was increased by 90 ml	Negative
Diffusing capacity	UE	0.49	1.62
Dispersion rate	UE	0.33	1.46
RV/TLC, %	UE	78.01	46.18
PH	7.434	7.352	UE
PO ₂ , mmHg	78.4	120 ^a	UE
PCO ₂ , mmHg	42.7	46.5	UE
HCO ₃ ⁻	28	24.1	UE

^aThe concentration of oxygen inhaled was 3 l/min. There was no normal range for the lung function test, as it varies from person to person. FEV1, forced expiratory volume in the first second; FVC, forced vital capacity; VC, vital capacity; RV/TLC, residual volume/total lung capacity; PH, potential of hydrogen; PO₂, pressure of oxygen; PCO₂, partial pressure of carbon dioxide; HCO₃⁻, hydrocarbonate; UE, unexamined.

a sign of the presence of HV-UCD. In that study, 10 patients progressed to BO and eventually died. In certain patients, PNP may be partially improved after resection of the primary tumor. Therefore, for HV-UCD, surgical resection of the local mass is advocated at present and may improve most symptoms and abnormalities of test results. If surgery is not possible, irradiation, embolization or neoadjuvant therapy with rituximab or siltuximab/tocilizumab (if evidence of acute inflammatory state is present) should be considered (12-14).

The most common pathological type of MCD is the plasma cell type (PC). PC-MCD is frequently accompanied by systemic symptoms, such as fever, night sweats, fatigue, loss of appetite, weight loss, organ enlargement, diffuse polyadenosis and edema. Furthermore, the disease is associated with a

number of abnormalities of laboratory parameters, including thrombocytopenia, anemia, leukocytosis, hypoproteinemia, hyperglobulinemia, positive autoantibodies, abnormal renal function and increases in acute-phase proteins, such as CRP, ESR, fibrinogen and IL-6. Lung involvement is more common than in HV-UCD, with respiratory symptoms including cough, sputum and shortness of breath. Hypoxemia is commonly found in the blood gas analysis and pulmonary function analysis indicates mixed ventilation disorder (15-18), suggesting interstitial lung damage and small airway lesions, and the pathological features of BO and lymphocytic interstitial pneumonia have also been confirmed in the literature (19). CT findings include lymphadenopathy, often with diffuse hilar and mediastinal lymphadenopathy, and pulmonary parenchyma changes,

including centrilobular nodules, bronchovesicular bundle and septal thickening, cysts and pleural effusion. Since MCD involves multiple sites and is a diffuse lesion, the feasibility of surgical resection is low. Two small studies reported that ~50% of MCD patients achieved complete remission after receiving four drugs combined with chemotherapy (20,21). Steroids are used primarily to induce remission in acute situations, but lasting remission is rare and therefore not recommended for maintenance therapy. Currently, rituximab has been used in certain CD20-positive patients with MCD, either alone or after failure of other treatments, and >50% of patients have achieved remission with mild side effects (22-26). Rituximab-based therapy markedly improved 5-year OS for Human herpes virus type 8 (HHV8)-MCD from 33 to 90% (27). Siltuximab, an anti-IL-6 antibody, is the only Food and Drug Administration-approved treatment for idiopathic MCD.

The present study reported on 3 rare cases of HV-MCD. Although not all of the patients had masses in the lungs, they all had respiratory symptoms, such as shortness of breath, cough and sputum, chest pain and other symptoms of concomitant PNP, as well as discomfort at the location of the masses, fever, emaciation, splenomegaly and further systemic symptoms. Laboratory tests revealed elevated IgM or IgG and positive autoimmune antibodies. These changes are common laboratory abnormalities in PC-MCD. Blood gas analysis indicated hypoxemia, 2 patients with varying degrees of obstructed ventilation dysfunction and 1 patient with restricted mixed ventilation dysfunction. These lung functions suggested small airway lesions and possible interstitial damage. The most common characteristic of CD accompanied by PNP is stomatitis (28,29). Stomatitis is manifested as mucosal erosion and ulceration, which is the most common in HV-UCD. As a result, the 3 cases of HV-MCD in the present study had characteristics of obstructive or mixed ventilation dysfunction, hypoxemia and carbon dioxide increases, as well as fever, emaciation, increases in immunoglobulin, autoimmune antibody abnormalities and likeliness of concurrent PNP. Therefore, it is evident that HV-MCD has the clinical features of HV-UCD and PC-MCD. From the treatment effect aspect, regardless of the type of CD, BO is one of the main causes of death, while surgical resection or chemotherapy has no obvious effect, leading to the death of patients due to respiratory failure, resulting in poor prognosis.

In the three cases of the present study, abnormal lung function was due to PNP. Wang *et al* (30) found that a specific B-cell clone exists in HV-CD, which may produce antibodies to identify antigen expressed in epithelium, and patients were prone to having concurrent PNP and oral ulcer. Antibodies against bronchial epithelial proliferation caused airway occlusion and thus led to the formation of occlusive bronchiolitis. After the removal of diseased tissue, the antibody concentration declined. Thus, tumor removal brought about a good prognosis. In certain studies, lung lesions of PC-MCD other than mass were confirmed by pathological biopsy as interstitial fibrous thickening, plasma-cell infiltration and alveolar collapse. Reichard *et al* (31) found a karyotype change of chromosome 7p15 double-allele containing IL-6 locus in PC-CD, which may be related to the imbalance of IL-6 cytokines. Mihara *et al* (32) found that IL-6 promoted the migration of inflammatory cells and the production of antibodies by B cells. Therefore, lung lesions of PC-MCD may be caused

by interstitial destruction and fibrosis may be caused by excessive infiltration of neutrophils and plasma cells due to increased IL-6 secretion. It has been suggested that anti-IL-6 therapy has an important role in the treatment strategy of PC-MCD. In these three cases, IL-6 was not elevated.

A total of four cases of HV-MCD involving the lungs were reported previously (2,33), but chest CT, blood gas analysis and lung function results were not described in detail. HV-MCD is a rare type of CD. All of the 3 cases in the present study had abnormal lung function, suggesting that abnormal lung function due to pemphigus paraneoplasia of HV-MCD is an important clinical feature. Attention should be paid when hypoxemia, obstructive ventilation dysfunction and lung shadow, accompanied by fever, emaciation, splenomegaly and other systemic symptoms, e.g., anemia, hypoalbuminemia, increased immunoglobulin, CRP and other laboratory abnormalities, or refractory oral mucosa and skin lesions are observed in a patient to rule out whether it is caused by CD. Timely examination of lymph nodes, chest and abdomen should be performed. If a mass or enlarged lymph node is present, early biopsy should be performed.

HV-MCD not only presents similarly to HV-UCD, which is easily complicated with PNP and BO, but also manifests as a lung shadow and is accompanied by systemic symptoms such as fever, emaciation and splenomegaly, as well as abnormalities of laboratory parameters, such as anemia, hypoalbuminemia, elevated immunoglobulin and elevated CRP, which are also common in PC-MCD. While the primary focus disappears after treatment, the small airway lesion is irreversible and affects the quality of life, and more severe cases can lead to death. Thus, the prognosis of HV-MCD is poor. Since HV-MCD is a rare disease and is easily misdiagnosed by respiratory physicians, if a patient presents with respiratory symptoms, lymphadenectasis, elevated immunoglobulin, hypoxemia, obstructive ventilation function disturbance and small airway lesion, and no improvement is seen after conventional therapy, general check-up and lymph node biopsy are required to clarify the diagnosis.

Acknowledgements

Not applicable.

Funding

This work was supported by grants from the Natural Science Foundation of China (grants no. NSFC81760010 and 82060364) and the Science and Technology Department of Guangxi Zhuang Autonomous Foundation of Guangxi Key Research and Development Program (grant no. GuikeAB20238025).

Availability of data and materials

All data generated or analyzed during this study are included in this published article.

Authors' contributions

JC, YQ and JZ performed the research. JC, WZ and JZ designed the study. JC, YQ, WZ, MP and JZ contributed

essential reagents or tools. MP analysed the data. JC analyzed the data and wrote the manuscript. All authors have read and approved the final manuscript. JZ and JC confirm the authenticity of all the raw data.

Ethics approval and consent to participate

This study was approved by the Ethics Committee associated with the Faculty of Medicine at The First Affiliated Hospital of Guangxi Medical University (Guangxi, China; no. 2023-E065-01). Written informed consent was provided by the patients.

Patient consent for publication

Written informed consent was obtained from the adult patients for publication of identifying images or other personal or clinical details of participants. When referring to individuals younger than the age of 18, consent for publication was obtained from the parents.

Competing interests

The authors declare that they have no competing interests.

References

- Oksenhendler E, Boutboul D, Fajgenbaum D, Mirouse A, Fieschi C, Malphettes M, Vercellino L, Meignin V, Gérard L and Galicier L: The full spectrum of Castleman disease: 273 patients studied over 20 years. *Br J Haematol* 180: 206-216, 2018.
- Biçakçioğlu P, Gülhan SS, Acar LN, Ağaçkiran Y, Özkar Ş, Kaya S and Karaoğluoğlu N: Intrathoracic Castleman disease. *Turk J Med Sci* 44: 197-202, 2014.
- Dispenzieri A and Fajgenbaum DC: Overview of Castleman disease. *Blood* 135: 1353-1364, 2020.
- Haap M, Wiefels J, Horger M, Hoyer A and Müssig K: Clinical, laboratory and imaging findings in Castleman's disease-The subtype decides. *Blood Rev* 32: 225-234, 2018.
- van Rhee F, Oksenhendler E, Srkalovic G, Voorhees P, Lim M, Dispenzieri A, Ide M, Parente S, Schey S, Streetly M, *et al*: International evidence-based consensus diagnostic and treatment guidelines for unicentric Castleman disease. *Blood Adv* 4: 6039-6050, 2020.
- Kligerman SJ, Auerbach A, Franks TJ, Franks TJ and Galvin JR: Castleman disease of the thorax: Clinical, radiologic, and pathologic correlation: From the radiologic pathology archives. *Radiographics* 36: 1309-1332, 2016.
- Zhang X, Rao H, Xu X, Li Z, Liao B, Wu H, Li M, Tong X, Li J and Cai Q: Clinical characteristics and outcomes of Castleman disease: A multicenter study of 185 Chinese patients. *Cancer Sci* 109: 199-206, 2018.
- Hill AJ, Tirumani SH, Rosenthal MH, Shinagare AB, Carrasco RD, Munshi NC, Ramaiya NH and Howard SA: Multimodality imaging and clinical features in Castleman disease: Single institute experience in 30 patients. *Br J Radiol* 88: 20140670, 2015.
- Ota H, Kawai H and Matsuo T: Unicentric castleman's disease arising from an intrapulmonary lymph node. *Case Rep Surg* 2013: 289089, 2013.
- Sarana B, Jaal J, Tamm H and Laisaar T: Resection of unicentric interlobar Castleman disease with following adjuvant radiotherapy. *SAGE Open Med Case Rep* 5: 2050313x17744481, 2017.
- Mimouni D, Anhalt GJ, Lazarova Z, Aho S, Kazerounian S, Kouba DJ, Mascaro JM Jr and Nousari HC: Paraneoplastic pemphigus in children and adolescents. *Br J Dermatol* 147: 725-732, 2002.
- van Rhee F and Munshi NC: Castleman disease. *Hematol Oncol Clin North Am* 32: xiii-xiv, 2018.
- Boutboul D, Fadlallah J, Chawki S, Fieschi C, Malphettes M, Dossier A, Gérard L, Mordant P, Meignin V, Oksenhendler E and Galicier L: Treatment and outcome of unicentric castleman disease: A retrospective analysis of 71 cases. *Br J Haematol* 186: 269-273, 2019.
- Larroche C, Cacoub P, Soulier J, Oksenhendler E, Clauvel JP, Piette JC and Raphael M: Castleman's disease and lymphoma: Report of eight cases in HIV-negative patients and literature review. *Am J Hematol* 69: 119-126, 2002.
- Wang ST, Wang QP, Li J, Zhang T, Zhang L and Mao YY: Amyloidosis secondary to intrapulmonary Castleman disease mimicking pulmonary hyalinizing granuloma-like clinical features: A rare case report. *Medicine (Baltimore)* 98: e15039, 2019.
- Zhang H, Zhang JQ, Zhong XN, Liu GN, Li MH, Bai J, He ZY and Deng JM: Two case reports of Castleman disease with pulmonary involvement. *Int J Tuberc Lung Dis* 19: 362-365, 2015.
- Hwangbo Y, Cha SI, Lee YH, Lee SY, Seo H, Oh S, Kim M, Choi SH, Park TI and Shin KM: A case of multicentric castleman's disease presenting with follicular bronchiolitis. *Tuberc Respir Dis (Seoul)* 74: 23-27, 2013.
- Nabeya D, Yoshimatsu Y and Fujiwara H: A case of acute progressive diffuse interstitial lung disease preceding idiopathic multicentric Castleman disease. *Respir Med Case Rep* 31: 101216, 2020.
- Johkoh T, Müller NL, Ichikado K, Nishimoto N, Yoshizaki K, Honda O, Tomiyama N, Naitoh H, Nakamura H and Yamamoto S: Intrathoracic multicentric Castleman disease: CT findings in 12 patients. *Radiology* 209: 477-481, 1998.
- Herrada J, Cabanillas F, Rice L, Manning J and Pugh W: The clinical behavior of localized and multicentric Castleman disease. *Ann Intern Med* 128: 657-662, 1998.
- Chronowski GM, Ha CS, Wilder RB, Cabanillas F, Manning J and Cox JD: Treatment of unicentric and multicentric Castleman disease and the role of radiotherapy. *Cancer* 92: 670-676, 2001.
- Marcelin AG, Aaron L, Mateus C, Gyan E, Gorin I, Viard JP, Calvez V and Dupin N: Rituximab therapy for HIV-associated Castleman disease. *Blood* 102: 2786-2788, 2003.
- Ide M, Kawachi Y, Izumi Y, Kasagi K and Ogino T: Long-term remission in HIV-negative patients with multicentric Castleman's disease using rituximab. *Eur J Haematol* 76: 119-123, 2006.
- Ocio EM, Sanchez-Guijo FM, Diez-Campelo M, Castilla C, Blanco OJ, Caballero D and San Miguel JF: Efficacy of rituximab in an aggressive form of multicentric Castleman disease associated with immune phenomena. *Am J Hematol* 78: 302-325, 2005.
- Corbellino M, Bestetti G, Scalapogna C, Calattini S, Galazzi M, Meroni L, Manganaro D, Fasan M, Moroni M, Galli M and Parravicini C: Long-term remission of Kaposi sarcoma-associated herpesvirus-related multicentric Castleman disease with anti-CD20 monoclonal antibody therapy. *Blood* 98: 3473-3475, 2001.
- Kofteridis DP, Tzagarakis N, Mixaki I, Maganas E, Xilouri E, Stathopoulos EN, Eliopoulos GD and Gikas A: Multicentric Castleman's disease: Prolonged remission with anti CD-20 monoclonal antibody in an HIV-infected patient. *AIDS* 18: 585-586, 2004.
- Bower M, Newsom-Davis T, Naresh K, Merchant S, Lee B, Gazzard B, Stebbing J and Nelson M: Clinical features and outcome in HIV-Associated multicentric castleman's disease. *J Clin Oncol* 29: 2481-2486, 2011.
- Anhalt GJ: Paraneoplastic pemphigus. *J Investig Dermatol Symp Proc* 9: 29-33, 2004.
- Lim JM, Lee SE, Seo J, Kim DY, Hashimoto T and Kim SC: Paraneoplastic pemphigus associated with a malignant thymoma: A case of persistent and refractory oral ulcerations following thymectomy. *Ann Dermatol* 29: 219-222, 2017.
- Wang L, Bu D, Yang Y, Chen X and Zhu X: Castleman's tumours and production of autoantibody in paraneoplastic pemphigus. *Lancet* 363: 525-531, 2004.
- Reichard KK, Robinett S and Foucar MK: Clonal cytogenetic abnormalities in the plasma cell variant of Castleman disease. *Cancer Genet* 204: 323-327, 2011.
- Mihara M, Hashizume M, Yoshida H, Suzuki M and Shiina M: IL-6/IL-6 receptor system and its role in physiological and pathological conditions. *Clin Sci (Lond)* 122: 143-159, 2012.
- Luo JM, Li S, Huang H, Cao J, Xu K, Bi YL, Feng RE, Huang C, Qin YZ, Xu ZJ and Xiao Y: Clinical spectrum of intrathoracic Castleman disease: A retrospective analysis of 48 cases in a single Chinese hospital. *BMC Pulm Med* 15: 34, 2015.

