

Journal club

Pregnancy-adapted YEARS algorithm: can YEARS do more for pregnant women?

Commentary on:

Van der Pol LM, *et al.* Pregnancy-adapted YEARS algorithm for diagnosis of suspected pulmonary embolism. *N Engl J Med* 2019; 380: 1139–1149.

Context

Venous thromboembolism (VTE), as a term that encompasses pulmonary embolism (PE) and deep vein thrombosis (DVT), is one of the leading causes of maternal morbidity and mortality [1], especially in developed countries, where PE takes second place after complications of hypertensive disorders [2]. When compared to non-pregnant women of similar age, pregnant women have an approximately four to five times higher risk of VTE [3], with an incidence of 1 in 1000 pregnancies [4]. Approximately 20–25% of VTE cases are caused by PE and 75–80% of cases are caused by DVT [5]. About 60% of DVT occurs antepartum, with the highest risk of antepartum pregnancy-associated VTE being in the third trimester. However, about 60% of PE occurs postpartum [3].

As a consequence of physiological changes all three elements of the Virchow's triad are present during pregnancy and the postpartum period [6].

Changes occurring in bio-humoral status (elevated D-dimer level) [7], as well as altered morpho-physiology of pregnant women (swelling and dyspnoea) [6], may delay clinical suspicion for PE. Moreover, the sensitive state of the female body and fetus during pregnancy, as well as the lack of clear and explicit recommendations, makes the diagnostic process more difficult. There are various diagnostic algorithms for exclusion of PE in pregnancy [8]. The most frequently used modalities include computerised tomography pulmonary angiogram (CTPA) and perfusion or ventilation/perfusion (V/Q') lung scan, but also compression ultrasonography (CUS) of the lower extremity and chest radiography [9]. The order of the four listed imaging methods is different depending on the recommendations. Additionally, some studies in the diagnostic algorithm include D-dimer values [10]. CTPA and V/Q' scan provide a similar diagnostic yield for diagnosing PE during pregnancy, but V/Q' scan involves a lower radiation dose to the mother (effective dose and breast dose) and fetus [11].

A few years ago the YEARS algorithm was developed. It includes three clinical criteria (clinical signs of DVT, haemoptysis, and whether PE is the most likely diagnosis) and one laboratory criteria (D-dimer value) to determine the need for CTPA (figure 1) [12]. With the creation and validation of this algorithm, a step forward was taken and with the algorithms adaptation to pregnant women [13].

Cite as: Bokan A, Matijasevic J, Vucicevic Trobok J. Pregnancy-adapted YEARS algorithm: can YEARS do more for pregnant women? *Breathe* 2020; 16: 190307.

 @ERSpublications

Pregnancy-adapted YEARS algorithm provides high certainty in ruling out pulmonary embolism and high efficiency in reducing the need for CTPA <http://bit.ly/2GgH4sv>



CrossMark



© ERS 2020

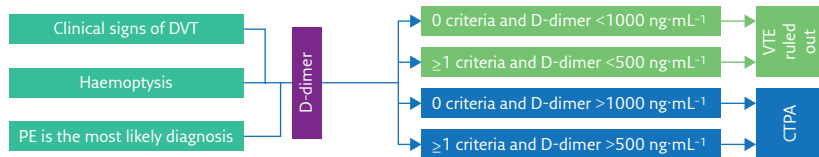


Figure 1 YEARS algorithm for the general population.

Methods

A study by VAN DER POL *et al.* [13] entitled “Pregnancy-adapted YEARS algorithm for diagnosis of suspected pulmonary embolism” has been published in the *New England Journal of Medicine* [13]. The study was a multi-center, international study conducted at 18 hospitals. During the period from October 2013 to May 2018 the study included pregnant women aged ≥ 18 years who had been referred to a hospital because of a suspected PE. All pregnant women were grouped based on the pregnancy-adapted YEARS algorithm (figure 2). Pregnant women who had clinical signs of DVT underwent CUS of the symptomatic leg. Patients in whom DVT was diagnosed were treated with anticoagulant therapy and no other tests were performed. In the case of a normal CUS or absence of clinical signs of DVT, the rest of the algorithm was continued. Patients in whom a diagnosis of PE was ruled out were followed for 3 months [13].

The primary end-point analysed safety of the algorithm. It was based on cumulative incidence of proven PE during a 3-month follow-up period of the subgroup of patients in whom a diagnosis of PE was ruled out using the algorithm. The secondary end-point analysed efficiency of the algorithm, which was based on the proportion of patients for whom CTPA was not indicated using the algorithm [13].

Main results

The study included 510 women, with 12 being initially excluded. After a total of 498 patients were analysed using the YEARS algorithm, 252 (51%) did not meet any of the YEARS criteria and 246 (49%) met at least one of the criteria. In patients with clinical signs of DVT CUS was performed, and DVT was confirmed in three out

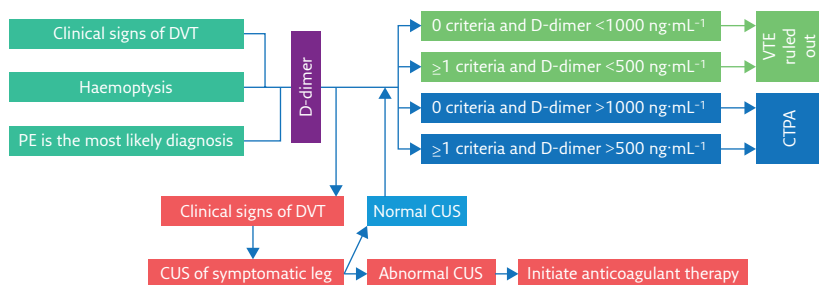


Figure 2 Pregnancy-adapted YEARS algorithm.

of 43 patients. PE was confirmed in 16 patients, with CTPA being used in 15 cases and V/Q scan in one case. None of them had DVT and only one did not meet any YEARS criteria, but had an elevated D-dimer value.

During a 3-month follow-up period, VTE, *i.e.* DVT, was diagnosed in one out of 477 patients (0.21%; 95% CI 0.04–1.2) who did not initially fulfil any YEARS criteria and had D-dimer levels in the reference range. CTPA was not indicated in 195 (39%) out of 494 patients (95% CI 35–44). Considering the efficiency of the algorithm in relation to stage of pregnancy, its value has a downward trend: 65% in the first, 46% in the second and 32% in the third trimester.

Commentary

A universally accepted algorithm for the diagnosis of PE in pregnant women is not yet available. This is in part because types of imaging techniques, as well as bio-humoral markers, do not yet have a clear and universally accepted order and place in available guidelines [8, 14]. The aim of each study addressing this issue is to create an algorithm that concurrently reduces the need for imaging techniques, while increasing the sensitivity and specificity of PE exclusion. The pregnancy-adapted YEARS algorithm is on the right track to accomplish the tasks mentioned above.

Results of the aforementioned study show an impressive decrease in the need for CTPA with high certainty in ruling out PE. Based on the algorithm in a study by RIGHINI *et al.* [10], CTPA was only not performed in 28 (8%) out of 349 patients, compared to the results of the study in question, in which CTPA was not indicated in 195 (39%) out of 494 patients [13]. In line with this, a study by LANGLOIS *et al.* [15] published in May this year used a standard YEARS algorithm. Based on this algorithm CTPA was not performed in 77 (20%) out of 371 patients [15], a higher proportion compared to the algorithm from RIGHINI *et al.* [10] but lower compared to the new YEARS algorithm. Taking into consideration the adverse effects of radiation on both the mother and newborn, as well as the cost of PE imaging, less frequent use of CTPA is of great importance [1], and so far this has been achieved in the highest percentage with pregnancy-adapted YEARS algorithm.

In addition, knowing when it is justified to suspect PE and indicate further examination in this group of patients is questionable. In the general population, pre-test probability is determined using questionnaires, such as the Wells score, Geneva score or their revised versions [16]. The current study clearly emphasises that the algorithm is not determining pre-test probability, but evaluating the need for CTPA. The question is “how does the physician cast suspicion on PE?” At the same time, it is not clear whether it is justified to suspect PE

in the case of symptoms such as sudden onset of dyspnoea or chest pain. Some authors have examined the Wells score in pregnant women, but the studies are insufficient because complete follow-up is missing [9]. Also, some studies found that clinical features associated with PE in pregnancy include age, previous thrombosis, family history of thrombosis, temperature, systolic blood pressure, oxygen saturation and PE-related chest radiograph abnormality [17]. This might be useful to define pre-test probability in pregnancy.

One of the elements that pregnancy-adapted YEARS algorithm does not include is chest radiograph. However, other guidelines, such as the guidelines for the diagnosis and management of acute pulmonary embolism, advise its inclusion [8, 18]. Chest radiography has the lowest estimated fetal radiation exposure (<0.01 mGy) compared to CTPA (0.05–0.5 mGy) and low-dose perfusion lung scan (0.02–0.20 mGy) [18]. Moreover, it is of great importance in the diagnosis of lung diseases. Abnormalities on chest radiography can be relatively specific to PE and can prevent further imaging tests. Also it can be helpful in identifying or excluding other lung diseases or diseases of other organs systems [19].

CUS of the lower extremity is the main difference between YEARS algorithm and pregnancy-adapted YEARS algorithm. CUS has several advantages

including no ionising radiation exposure and being readily available, but also several disadvantages including limited detection of pelvic vein thrombosis and being operator dependent [20]. Despite limitations, CUS is a satisfactory initial diagnostic test that can rule out the need for CTPA [21]. More recent studies indicate that ultrasound of lower extremity, lung and heart as point-of-care ultrasound, can replace the use of methods with ionising radiation [22].

Implications for practice

Diagnosing PE in pregnancy is still a challenge. The choice of diagnostic method that would achieve the greatest benefit and do least harm in pregnancy is still under consideration. CUS is certainly the safest method for pregnant women. Results of the study by VAN DER POL *et al.* [13] indicate high certainty in ruling out PE and high efficiency in reducing the need for CTPA. Application of this algorithm, with possible additional modifications according to local protocols, would improve the current diagnostic procedure in pregnant women. Additional studies have the potential to confirm the results of this study, which would allow the algorithm to be implemented in the guidelines on the diagnosis of PE in pregnancy.

Affiliations

Aleksandar Bokan^{1,2}, Jovan Matijasevic^{1,2}, Jadranka Vucicevic Trobok^{1,2}

¹Institute for Pulmonary Diseases of Vojvodina, Dept for Emergency Pulmonology, Sremska Kamenica, Serbia.

²University of Novi Sad, Faculty of Medicine Novi Sad, Novi Sad, Serbia.

Conflict of interest

A. Bokan has nothing to disclose. J. Matijasevic has nothing to disclose. Jr. Vucicevic Trobok has nothing to disclose.

References

- Bates SM, Rajasekhar A, Middeldorp S, *et al.* American Society of Hematology 2018 guidelines for management of venous thromboembolism: venous thromboembolism in the context of pregnancy. *Blood Adv* 2018; 2: 3317–3359.
- Frölich MA, Banks C, Brooks A, *et al.* Why do pregnant women die? A review of maternal deaths from 1990 to 2010 at the University of Alabama at Birmingham. *Anesth Analg* 2014; 119: 1135–1139.
- Bennett A, Chunilal S. Diagnosis and management of deep vein thrombosis and pulmonary embolism in pregnancy. *Semin Thromb Hemost* 2016; 42: 760–773.
- Simcox LE, Ormsher L, Tower C, *et al.* Pulmonary thromboembolism in pregnancy: diagnosis and management. *Breast* 2015; 11: 282–289.
- ACOG Practice Bulletin No. 196 Summary: thromboembolism in pregnancy. *Obstet Gynecol* 2018; 132: 243–248.
- Greer IA. Thrombosis in pregnancy: maternal and fetal issues. *Lancet* 1999; 353: 1258–1265.
- Khalafallah AA, Morse M, Al-Barzan A-M, *et al.* D-Dimer levels at different stages of pregnancy in Australian women: a single centre study using two different immunoturbidimetric assays. *Thromb Res* 2012; 130: e171–e177.
- Wan T, Skeith L, Karovitch A, *et al.* Guidance for the diagnosis of pulmonary embolism during pregnancy: consensus and controversies. *Thromb Res* 2017; 157: 23–28.
- Cutts BA, Dasgupta D, Hunt BJ. New directions in the diagnosis and treatment of pulmonary embolism in pregnancy. *Am J Obstet Gynecol* 2013; 208: 102–108.
- Righini M, Robert-Ebadi H, Elias A, *et al.* Diagnosis of pulmonary embolism during pregnancy: a multicenter prospective management outcome study. *Ann Intern Med* 2018; 169: 766–773.
- Grüning T, Mingo RE, Gosling MG, *et al.* Diagnosing venous thromboembolism in pregnancy. *Br J Radiol* 2016; 89: 20160021.
- van der Hulle T, Cheung WY, Kooij S, *et al.* Simplified diagnostic management of suspected pulmonary embolism (the YEARS study): a prospective, multicentre, cohort study. *Lancet* 2017; 390: 289–297.
- van der Pol LM, Tromeur C, Bistervels IM, *et al.* Pregnancy-adapted YEARS algorithm for diagnosis of suspected pulmonary embolism. *N Engl J Med* 2019; 380: 1139–1149.
- Conti E, Zezza L, Ralli E, *et al.* Pulmonary embolism in pregnancy. *J Thromb Thrombolysis* 2014; 37: 251–270.

15. Langlois E, Cusson-Dufour C, Moumneh T, *et al.* Could the YEARS algorithm be used to exclude pulmonary embolism during pregnancy? Data from the CT-PE-pregnancy study. *J Thromb Haemost* 2019; 17: 1–6.
16. Tritschler T, Kraaijpoel N, Le Gal G, *et al.* Venous thromboembolism: advances in diagnosis and treatment. *JAMA* 2018; 320: 1583–1594.
17. Goodacre S, Horspool K, Nelson-Piercy C, *et al.* The DiPEP study: an observational study of the diagnostic accuracy of clinical assessment, D-dimer and chest X-ray for suspected pulmonary embolism in pregnancy and postpartum. *BJOG* 2019; 126: 383–392.
18. Konstantinides SV, Meyer G, Becattini C, *et al.* 2019 ESC Guidelines for the diagnosis and management of acute pulmonary embolism developed in collaboration with the European Respiratory Society (ERS). *Eur Heart J* 2020; 41: 543–603.
19. Shawn TH, Yan L, Lateef F. The chest X ray in pulmonary embolism: Westermark sign, Hampton's Hump and Palla's sign. What's the difference? *J Acute Dis* 2018; 7: 99.
20. Durán-Mendicuti A, Sodickson A. Imaging evaluation of the pregnant patient with suspected pulmonary embolism. *Int J Obstet Anesth* 2011; 20: 51–59.
21. Righini M, Le Gal G, Aujesky D, *et al.* Diagnosis of pulmonary embolism by multidetector CT alone or combined with venous ultrasonography of the leg: a randomised non-inferiority trial. *Lancet* 2008; 371: 1343–1352.
22. Squizzato A, Galli L, Gerdes VEA. Point-of-care ultrasound in the diagnosis of pulmonary embolism. *Crit Ultrasound J* 2015; 7: 7.