

Available online at [www.sciencedirect.com](http://www.sciencedirect.com)

ScienceDirect

journal homepage: [www.elsevier.com/locate/radcr](http://www.elsevier.com/locate/radcr)

## Case Report

# Case report: Clinical and magnetic resonance spectroscopy presentation of a female severely affected with X-linked creatine transporter deficiency<sup>☆</sup>

Katherine Morey<sup>a,b</sup>, Barbara Hallinan, MD, PhD<sup>c</sup>, Kim M. Cecil, PhD<sup>b,\*</sup>

<sup>a</sup> Summer Undergraduate Research Fellowship Program, Cincinnati Children's Hospital Medical Center, Cincinnati, OH, USA

<sup>b</sup> Department of Radiology, Cincinnati Children's Hospital Medical Center, University of Cincinnati College of Medicine, 3333 Burnet Avenue, MLC 5033, Cincinnati, OH 45229, USA

<sup>c</sup> Department of Pediatrics, Division of Neurology, Cincinnati Children's Hospital Medical Center, University of Cincinnati College of Medicine, Cincinnati, OH, USA

## ARTICLE INFO

## Article history:

Received 8 November 2021

Revised 18 January 2022

Accepted 19 January 2022

## Keywords:

Creatine transporter deficiency

Female

Magnetic resonance spectroscopy

Exome sequencing

Intellectual disability

Autism spectrum disorder

## ABSTRACT

Creatine transporter deficiency is an X-linked genetic disorder caused by a variant in the SLC6A8 gene located on the X chromosome (Xq28). This condition varies in severity with features often including intellectual disabilities, speech delay, autistic features, attention deficit hyperactivity and gastrointestinal issues. While creatine transporter deficiency primarily affects males, females may also demonstrate severe phenotypes. However, screening of creatine transporter deficiency in females can be especially difficult as urine creatine/creatinine screenings often have values falling within normative ranges. Also, females may not demonstrate the characteristic reduction of creatine concentrations in the brain visualized with in vivo proton magnetic resonance spectroscopy. Identification typically results from exome sequencing. In this report, we present the clinical, imaging, and spectroscopy features of a heterozygous female with a severe presentation of creatine transporter deficiency.

© 2022 The Authors. Published by Elsevier Inc. on behalf of University of Washington.

This is an open access article under the CC BY-NC-ND license

(<http://creativecommons.org/licenses/by-nc-nd/4.0/>)

## Introduction

The first male patient with creatine transporter deficiency (CTD) was identified from a dramatic reduction of the cre-

atine observed throughout his brain upon acquiring proton magnetic resonance spectroscopy (MRS) [7]. Subsequent DNA sequencing led to the discovery of CTD arising from variants in the SLC6A8 gene located on the X chromosome (Xq28) [19]. The creatine transporter protein is responsible for

<sup>☆</sup> Competing Interest: The authors declare that the research was conducted in the absence of any commercial or financial relationships that could be construed as a potential conflict of interest.

\* Corresponding author.

E-mail address: [kim.cecil@cchmc.org](mailto:kim.cecil@cchmc.org) (K.M. Cecil).

<https://doi.org/10.1016/j.radcr.2022.01.053>

1930-0433/© 2022 The Authors. Published by Elsevier Inc. on behalf of University of Washington. This is an open access article under the CC BY-NC-ND license (<http://creativecommons.org/licenses/by-nc-nd/4.0/>)

transporting creatine from the blood to the brain. This syndrome often produces seizures, intellectual disabilities, autistic features, speech and language disorders manifesting early in life for homozygous males. As an X-linked intellectual disability, heterozygous females may present with a broad phenotype spanning from asymptomatic carrier to severely affected with features resembling the male presentation. Females with severe presentations of CTD often have a difficult path to diagnosis as noninvasive urine screening and MRS are not as distinct compared with males. We present the features of a heterozygous female without a familial history of neurodevelopmental disorders who was ultimately identified upon exome sequencing with a *de novo* pathogenic variant of the *SLC6A8* gene consistent with CTD.

## Case description

A female patient first presented at 22 months with new onset of febrile seizure and a history of global developmental delay. There was no known family history of seizures or other central nervous system disorders. She was born via Caesarean section at 38 weeks, sat independently at 9 months, walked at 16 months, and used single words at 18 months. By age 3 years, she demonstrated significant impairment in verbal and nonverbal communication, difficulty initiating and sustaining social interactions. At age 4, she formally received the diagnosis of autism spectrum disorder after assessment with the Autism Diagnostic Observation, Second edition. Using the Wechsler Preschool and Primary Scale of Intelligence, her Full-Scale IQ was assessed in the extremely low range with a score of 59. Testing with the Clinical Evaluation of Language Fundamentals Preschool (CELF Preschool 2) indicated auditory comprehension and total language skills in the lowest first percentile rank (age equivalence at 1.1 and 2.1 years, respectively) with expressive communication at the lowest third percentile rank (age equivalence 2.6 years). At 7 years, she was administered the Early Years – Upper Level version of the Differential Ability Scales, Second Edition assessment, since she was unable to complete any tasks on the School-Age version. Her overall cognitive abilities were measured in the very low range. Her General Conceptual Ability T-score of 40 ranked as <0.1 percentile, with similar rankings for the majority of verbal, nonverbal and spatial subtests. Her Naming Vocabulary subtest T-score was 31, which ranked third percentile at an age level of 4 years, 10 months.

At age 8, she continued to exhibit severely disordered receptive, expressive, supralinguistic and pragmatic language skills with moderately disordered receptive and expressive vocabulary skills.

The patient exhibits self-injurious behaviors and is emotionally labile. She has repetitive behaviors, complex mannerisms or stereotyped behavior including scratching herself, hand flapping, echolalia, and twirling her hair. By age 7 years, she persisted with outbursts of screaming and crying when told “no”. The patient’s mother completed the Vineland Adaptive Behavior Scales, Third edition, assessment. The patient’s adaptive behavior composite, communication, daily living scale and socialization scores were in the lowest <1

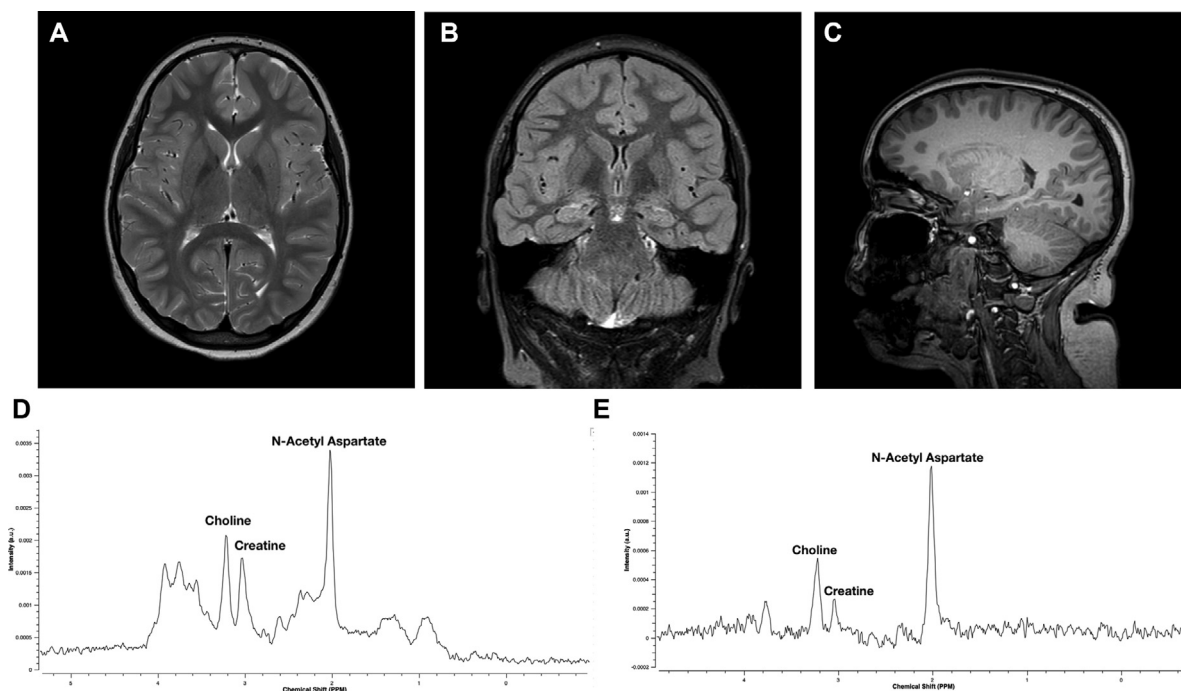
percentile. The patient’s mother also completed the Behavior Rating Inventory of Executive Function, 2nd edition, to yield significantly elevated behavioral and emotional regulation indices for the patient exceeding the 96th percentile with Metacognitive Index at the 87th percentile and the Global Executive Composite at the 93rd percentile.

At the age of 3 years, she began having unprovoked seizures described as seconds-long episodes of unresponsiveness with dystonic movements of the extremities. Multiple seizures were captured on a 24-hour electroencephalography (EEG), described as a change in facial expression with choreoathetoid movements of the extremities. On EEG, these were accompanied by bifrontal fast waves followed by rhythmic delta activity. The interictal EEG showed intermittent 1-4 second bursts of generalized fast activity intermixed with polyspikes during sleep. She was started on Trileptal with no effect, then transitioned to Depakote for a presumed generalized epilepsy. By 4 years of age, parents reported that seizures were occurring up to 40 times a day. Subsequent EEG monitoring revealed that many of the events described (breath-holding, head shaking, staring) were not seizures, however, seconds-long tonic seizures (leg stiffening) persisted. Depakote was thought to cause developmental regression and eventually discontinued. Seizures became infrequent and very brief. Ultimately, her parents elected to discontinue all anticonvulsants at 5 years and seizures stopped by age 7 years.

She was toilet trained by the age of 5 years. She began attending public school in first grade with an individualized educational plan in a classroom for children with complex medical needs and was receiving speech and occupational therapy. At 7 years of age, she exhibited premature pubarche and thelarche. She was not able to dress herself, brush her teeth or care for herself independently.

From 5 years of age, the patient exceeded the 97th percentile for weight and body mass index. The patient was also diagnosed severe obstructive sleep apnea, adenotonsillar hypertrophy, which prompted tonsillectomy and adenoidectomy at 10 years of age. These procedures significantly improved her sleep quality which previously characterized as restless and included snoring and somniloquy.

The unknown causes of developmental delay and seizures in the patient prompted a microarray panel at the age of 4 years, and a Fragile X panel at 5 years, both of which were found to be normal. With persistent developmental delays at age 8 years, further testing of the patient and her parents was conducted with a GeneDx Autism/ID Xpanded panel. The patient was found to have an X-linked heterozygous *de novo* pathogenic p.R514X variant (c.1540 C>T) in the *SLC6A8* gene. A previous magnetic resonance imaging (MRI) examination of the brain at age 6 years was interpreted as normal. However, upon recognition of the *SLC6A8* variant, a repeat MRI of the brain was performed which included MRS within the basal ganglia. Both MRI examinations showed a normal appearance of the brain. The MRI and MRS protocols were acquired on a Philips 3 Tesla MRI scanner with sequential short (34 milliseconds) and long (288 milliseconds) echo acquisitions using a repetition time of 2000 milliseconds, 8 cubic centimeter (2 centimeters per side) single-voxel, point resolved spectroscopy (PRESS) localization, and positioned within the basal ganglia (Figs. 1A-E). Using MRI scanner vendor supplied soft-



**Fig. 1 – A) Axial T2-weighted, B) oblique coronal T2 FLAIR and C) sagittal T1-weighted magnetic resonance imaging obtained in an 8-year-old female heterozygote for creatine transporter deficiency syndrome with N-acetyl aspartate, creatine and choline resonances noted on the D) short echo (34 millisecond) spectrum and the E) long echo (288 millisecond) spectrum acquired from the left hemisphere basal ganglia. The linewidth of the creatine resonance at 3 parts per million (ppm) on the long echo spectrum is much narrower than the adjacent resonances and combined with reduced height indicate a reduction of the creatine concentration.**

ware, semi-quantitative metabolite ratios to creatine signal were determined for each spectrum. The initial qualitative appearance of the short echo MRS acquisition is relatively normal. However, the linewidth of the creatine resonance at 3 parts per million (ppm) on the long echo spectrum was visibly narrower than the adjacent resonances and combined with reduced height indicated a reduction of the creatine concentration. The ratios of N-acetylaspartate and cholines relative to creatine signal levels for the patient were compared to MRI scanner vendor, MRS protocol and age-specific normative data within our institution. Metabolite ratios acquired at both echo times revealed elevated N-acetylaspartate/creatine and choline/creatine values, which suggested reduced creatine levels. We also quantitatively analyzed the spectra with LCModel software [18], adjusting for metabolite and water relaxation rate constants and voxel tissue components (53% gray matter, 46% white matter and 1% cerebrospinal fluid), confirming reduced total creatine concentrations for the spectra upon comparison with normative data. The adjusted short echo basal ganglia creatine concentration was 4.8 mM, which was approximately 40% lower than the normative institutional mean concentration data.

At 10 years of age, creatine supplementation of 300 mg/kg/day was attempted with a regimen of 4 doses distributed throughout the day. The patient did not like taking creatine. The patient's mother and teachers reported an exacerbation of behavioral changes within the first week. Supplementation was discontinued within 1 month due to

an increase in self-injurious and violent behaviors. No post-supplementation laboratory testing or further MRS were acquired due to the short duration of usage.

## Discussion

Historically, the diagnostic algorithm for confirming X-linked CTD in males typically began with the noninvasive measurement of creatine and creatinine in urine [1,3,10,13,17,20,22]. The low expense and non-invasive nature made this a suitable first-tier screening evaluation for patients with global developmental delay [3,17]. High creatine/creatinine ratio in the urine would subsequently prompt additional testing including molecular genetic testing of *SLC6A8* to search for a pathogenic variant and/or proton MRS of the brain to show that the variant is disease causing and not a polymorphism [8]. Phenotypic confirmation of CTD by demonstrating the absence of creatine transport from fibroblast was also beneficial, however, it historically had been costly, labor intensive and time-consuming.

Urine creatine/creatinine screening for a female with intellectual disability is likely not to be very productive as normative data obtained for a French population illustrated that for females, the ratio of creatine/creatinine is higher compared with males [12]. Bahl et al. found that urine creatine levels were significantly different between females and males for the age range of 0-60 months, with no sex difference for other

ages up to 18 years [3]. As the urine creatine to creatinine ratio is influenced by age [1], dietary factors, as well as the composition of the local reference dataset for various laboratory settings, this screening typically fails to identify appropriate candidates for CTD diagnosis [1,3,16]. The six genetically confirmed CTD heterozygous females in DeGrauw et al., demonstrated urine creatine to creatinine ratio all within the institutional normal range [9]. Van de Kamp et al., found an elevated urine creatine/creatinine ratio in only 3 of 8 heterozygous mothers aged 32–77 (mean age 47 years) [23]. Mercimek-Mahmutoglu and Salomons also reported that females with a heterozygous likely pathogenic variant in *SLC6A8* could report normal urine creatine concentrations [15]. Valayannopoulos et al., described normal urine creatine in two severely affected females confirmed with *SLC6A8* variants with clinical features including intellectual disabilities, autistic features, epilepsy and psychosis [21].

Many case reports and case series that employ proton MRS of the brain for evaluation of maternal carriers and affected females report observing normal or slight decreases in creatine concentrations [2–4,11,12,14]. However, technical features detailing the MRS acquisition parameters and quantification approach are often absent in these reports. This may be due in part to the absence of a stable reference metabolite in the quantification approach and/or normative control data. The dramatic decrease or complete absence of creatine upon proton MRS obtained in males does not require rigorous quantification. Many imaging centers employ proton MRS clinically for lesion evaluation that rely on significant concentration deviations from the typical appearing brain. In these instances, sampling normal appearing brain with MRS in an unaffected brain region serves as an internal control while accounting for the effects of technical parameters, age, voxel composition, etc. Diffuse disorders pose a problem for MRS diagnosis in the clinical setting. Most clinical imaging centers struggle to acquire appropriate control data from healthy, age-matched persons unless they have a research team actively acquiring normative data while matching the clinical MRS acquisition protocol. Van de Kamp et al., reported that comparison of quantitated metabolite concentrations from short echo proton MRS sampling of the cortex, white matter and cerebellum in heterozygous females found significant decreases in creatine concentrations with healthy control data averaging between 13% and 35% [23]. Mercimek-Mahmutoglu report the partial reduction of creatine concentration for a female with intractable epilepsy confirmed with CTD [5,14]. Proton MRS acquired within the basal ganglia of a heterozygous female, incidentally with the same pathogenic variant as our patient, at 9 days of age revealed a 63% decline of creatine concentration [6]. Valayannopoulos et al., reported reductions of 50 to 60% for two severely affected females with CTD, respectively [21]. Without rigorous quantification, it is difficult to qualitatively recognize a creatine decrement unless the neuroradiologist interpreting the spectra has significant experience and sensitivity toward perturbation of standard metabolite ratios compared to creatine. This also requires standardization of the MRS voxel location and protocol including short and long echo acquisitions. For our patient, the MRS was performed as a confirmatory test following notification of the results from the GeneDx Autism/ID Expanded panel. The semiquantitative

ratios for metabolite to creatine signals were dramatically elevated for the long echo spectrum and modestly elevated for the short echo spectrum. Had the MRS been performed at the time of the initial MRI at age 6, these metabolite ratio perturbations may have suggested genetic testing focused on a creatine disorder, but could have also been easily overlooked. For this evaluation performed post-exome sequencing, rigorous quantification of the short echo spectrum revealed the creatine decrement upon accounting for the T2 relaxation rate. The T2 relaxation rate for creatine is the shortest relative to the other typically observed MRS brain metabolites of N-acetylaspartate, choline and myo-inositol. Lower creatine levels on long echo MRS with a reduction in linewidth and height on the spectral plot made the ratio to creatine levels qualitatively distinct. Short echo spectra were more difficult to qualitatively recognize the creatine decrement. The signal at 3.0 parts per million (ppm) is the location where the primary creatine methylene resonance appears. It is confounded by macromolecule,  $\gamma$ -aminobutyric acid (GABA) and glutathione signals co-resonating at that location.

The key to diagnosing CTD in our female patient was the performance of the exome sequencing. While historically this was an expensive exploration, it has now become cost effective. Epilepsy panels, as well as autism and intellectual disability panels include the *SLC6A8* gene. Proton MRS can be employed for evaluating pathogenicity of a variant of uncertain significance, though the determination of creatine concentration is more difficult in females than in males with CTD as described in our patient.

Our experience confirms that sequence analysis is the best diagnostic tool for symptomatic females with quantitative MRS employed as a confirmatory assessment [21]. Clinicians evaluating females presenting with unexplained intellectual delay, seizures, and language impairment should consider exome sequencing screening for conditions such as creatine transporter deficiency.

---

## Patient consent

This study protocol was approved by and carried out in accordance with the Cincinnati Children's Hospital Medical Center Institutional Review Board. The patient's parent provided consent for publication.

---

## REFERENCES

- [1] Almeida LS, Verhoeven NM, Roos B, Valongo C, Cardoso ML, Vilarinho L, et al. Creatine and guanidinoacetate: diagnostic markers for inborn errors in creatine biosynthesis and transport. *Mol Genet Metab* 2004;82(3):214–19. doi:10.1016/j.ymgme.2004.05.001.
- [2] Ardon O, Procter M, Mao R, Longo N, Landau YE, Shilon-Hadass A, et al. Creatine transporter deficiency: novel mutations and functional studies. *Mol Genet Metab Rep* 2016;8:20–3. doi:10.1016/j.ymgmr.2016.06.005.
- [3] Bahl S, Cordeiro D, MacNeil L, Schulze A, Mercimek-Andrews S. Urine creatine metabolite panel as a



- screening test in neurodevelopmental disorders. *Orphanet J Rare Dis* 2020;15(1):339. doi:10.1186/s13023-020-01617-z.
- [4] Battini R, Chilosi AM, Casarano M, Moro F, Comparini A, Alessandri MG, et al. Language disorder with mild intellectual disability in a child affected by a novel mutation of SLC6A8 gene. *Mol Genet Metab* 2011;102(2):153–6. doi:10.1016/j.ymgme.2010.11.005.
- [5] Bruun TUJ, Sidky S, Bandeira AO, Debray FG, Ficicioglu C, Goldstein J, et al. Treatment outcome of creatine transporter deficiency: international retrospective cohort study. *Metab Brain Dis* 2018;33(3):875–84. doi:10.1007/s11011-018-0197-3.
- [6] Cecil KM, DeGrauw TJ, Salomons GS, Jakobs C, Egelhoff JC, Clark JF. Magnetic resonance spectroscopy in a 9-day-old heterozygous female child with creatine transporter deficiency. *J Comput Assist Tomogr* 2003;27(1):44–7. doi:10.1097/00004728-200301000-00009.
- [7] Cecil KM, Salomons GS, Ball WS Jr, Wong B, Chuck G, Verhoeven NM, et al. Irreversible brain creatine deficiency with elevated serum and urine creatine: a creatine transporter defect? *Ann Neurol* 2001;49(3):401–4. doi:10.1002/ana.79.
- [8] Clark JF, Cecil KM. Diagnostic methods and recommendations for the cerebral creatine deficiency syndromes. *Pediatr Res* 2015;77(3):398–405. doi:10.1038/pr.2014.203.
- [9] deGrauw TJ, Salomons GS, Cecil KM, Chuck G, Newmeyer A, Schapiro MB, et al. Congenital creatine transporter deficiency. *Neuropediatrics* 2002;33(5):232–8. doi:10.1055/s-2002-36743.
- [10] Fons C, Campistol J. Creatine defects and central nervous system. *Semin Pediatr Neurol* 2016;23(4):285–9. doi:10.1016/j.spen.2016.11.003.
- [11] Heussinger N, Saake M, Mennecke A, Dorr HG, Trollmann R. Variable white matter atrophy and intellectual development in a family with X-linked creatine transporter deficiency despite genotypic homogeneity. *Pediatr Neurol* 2017;67:45–52. doi:10.1016/j.pediatrneurol.2016.10.007.
- [12] Joncquel-Chevalier Curt M, Bout MA, Fontaine M, Kim I, Huet G, Bekri S, et al. Functional assessment of creatine transporter in control and X-linked SLC6A8-deficient fibroblasts. *Mol Genet Metab* 2018;123(4):463–71. doi:10.1016/j.ymgme.2018.02.010.
- [13] Mencarelli MA, Tassini M, Pollazzon M, Vivi A, Calderisi M, Falco M, et al. Creatine transporter defect diagnosed by proton NMR spectroscopy in males with intellectual disability. *Am J Med Genet A* 2011;155A(10):2446–52. doi:10.1002/ajmg.a.34208.
- [14] Mercimek-Mahmutoglu S, Connolly MB, Poskitt KJ, Horvath GA, Lowry N, Salomons GS, et al. Treatment of intractable epilepsy in a female with SLC6A8 deficiency. *Mol Genet Metab* 2010;101(4):409–12. doi:10.1016/j.ymgme.2010.08.016.
- [15] [15] Mercimek-Mahmutoglu, S., & Salomons, G. S. (2009 Jan 15 [Updated 2015 Dec 10]). Creatine deficiency syndromes. In M. P. Adam, H. H. Ardinger, R. A. Pagon, T. D. Bird, C. R. Dolan, & K. Stephens (Eds.), *GeneReviews* [internet]. Available from: <http://www.ncbi.nlm.nih.gov/pubmed/20301745>.
- [16] Morkrid L, Rowe AD, Elgstoen KB, Olesen JH, Ruijter G, Hall PL, et al. Continuous age- and sex-adjusted reference intervals of urinary markers for cerebral creatine deficiency syndromes: a novel approach to the definition of reference intervals. *Clin Chem* 2015;61(5):760–8. doi:10.1373/clinchem.2014.235564.
- [17] Patel J, Mercimek-Mahmutoglu S. Epileptic encephalopathy in childhood: a stepwise approach for identification of underlying genetic causes. *Indian J Pediatr* 2016;83(10):1164–74. doi:10.1007/s12098-015-1979-9.
- [18] Provencher SW. Estimation of metabolite concentrations from localized in vivo proton NMR spectra. *Magn Reson Med* 1993;30(6):672–9. doi:10.1002/mrm.1910300604.
- [19] Salomons GS, van Dooren SJ, Verhoeven NM, Cecil KM, Ball WS, DeGrauw TJ, et al. X-linked creatine-transporter gene (SLC6A8) defect: a new creatine-deficiency syndrome. *Am J Hum Genet* 2001;68(6):1497–500. doi:10.1086/320595.
- [20] Thurm A, Himmelstein D, D'Souza P, Rennert O, Jiang S, Olatunji D, et al. Creatine transporter deficiency: screening of males with neurodevelopmental disorders and neurocognitive characterization of a case. *J Dev Behav Pediatr* 2016;37(4):322–6. doi:10.1097/DBP.0000000000000299.
- [21] Valayannopoulos V, Boddaert N, Chabli A, Barbier V, Desguerre I, Philippe A, et al. Treatment by oral creatine, L-arginine and L-glycine in six severely affected patients with creatine transporter defect. *J Inher Metab Dis* 2012;35(1):151–7. doi:10.1007/s10545-011-9358-9.
- [22] Valongo C, Cardoso ML, Domingues P, Almeida L, Verhoeven N, Salomons G, et al. Age related reference values for urine creatine and guanidinoacetic acid concentration in children and adolescents by gas chromatography-mass spectrometry. *Clin Chim Acta* 2004;348(1-2):155–61. doi:10.1016/j.cccn.2004.05.013.
- [23] van de Kamp JM, Mancini GM, Pouwels PJ, Betsalel OT, van Dooren SJ, de Koning I, et al. Clinical features and X-inactivation in females heterozygous for creatine transporter defect. *Clin Genet* 2011;79(3):264–72. doi:10.1111/j.1399-0004.2010.01460.x.