

Maternal Loews–Dietz syndrome (transforming growth factor ligand 2) in a twin pregnancy: Case report and discussion

SAGE Open Medical Case Reports
Volume 7: 1–4
© The Author(s) 2019
Article reuse guidelines:
sagepub.com/journals-permissions
DOI: 10.1177/2050313X19852539
journals.sagepub.com/home/sco



Homira Bashari¹ , Alexandra Brooks^{1,2}, Orla O'Brien¹, Shaun Brennecke^{1,2,3} and Dominica Zentner^{4,5}

Abstract

Loews–Dietz syndrome is a rare autosomal dominant connective tissue disorder. Pregnant women with Loews–Dietz syndrome are at increased risk of serious vascular and visceral complications, including aortic dissection and uterine rupture. Multidisciplinary tertiary management aims to mitigate such complications by preconception counselling and vascular assessment, medical therapy, regular echocardiography in pregnancy and joint decision-making re-mode and timing of delivery. We report an in vitro fertilisation twin pregnancy in a woman with Loews–Dietz syndrome first seen at our institution at 26 weeks' gestation. After monitoring via serial echocardiograms, caesarean delivery occurred at 30 + 1 weeks' gestation to allow planned delivery with suspected fetal growth restriction before uterine distension was considered an indication. The patient was discharged on Day 9 with a planned early aortic root replacement due to an increase in diameter from 39 to 43 mm, followed by the discharge of twin boys at term equivalent.

Keywords

Obstetrics/gynaecology, women's health

Date received: 19 January 2019; accepted: 30 April 2019

Introduction

Loews–Dietz syndrome (LDS; Online Mendelian Inheritance in Man number 614816) is a rare autosomal dominant connective tissue disorder¹ most commonly caused by mutations in transforming growth factor receptors 1/2 (*TGFBR1/2*),^{2,3} as well as in decapentaplegic homolog 2/3 (*SMAD2/3*) and transforming growth factor ligand 2/3 (*TGFB2/3*).³ Initially described as a triad of arterial tortuosity, hypertelorism and bifid uvula ± cleft palate,¹ LDS has a tendency for more aggressive aortic dissection (including in normally sized vessels), extra-aortic vascular involvement and a wide phenotypic expression including individuals lacking the originally described clinical features of the syndrome.³ Pregnant women with LDS are at higher risk of aortic aneurysms and uterine rupture.⁴ Counselling, imaging of the entire vascular tree (head to pelvis, ideally by magnetic resonance imaging (MRI)), identification of a genetic mutation with the option of pre-implantation or early-pregnancy genetic diagnosis and transition to medication that is acceptable in pregnancy should ideally lead to preconception.⁵ It is important for

affected women to understand that aortic dimensions alone do not predict complications and that pregnancy remains a time of increased risk irrespective of investigation results. Women should be educated about typical symptoms and advised to call an ambulance and state 'I am having an aortic dissection' if these occur. In pregnancy, regular imaging with

¹Maternity Services, The Royal Women's Hospital, Melbourne, VIC, Australia

²Department of Maternal Fetal Medicine, The Royal Women's Hospital, Melbourne, VIC, Australia

³Department of Obstetrics and Gynaecology, University of Melbourne and The Royal Women's Hospital, Melbourne, VIC, Australia

⁴Departments of Cardiology and Genetic Medicine, The Royal Melbourne Hospital, Melbourne, VIC, Australia

⁵Faculty of Medicine, Dentistry and Health Sciences, University of Melbourne and Royal Melbourne Hospital Clinical School, Melbourne, VIC, Australia

Corresponding Author:

Homira Bashari, Maternity Services, The Royal Women's Hospital, Melbourne, Parkville, VIC, Australia.

Email: homira.bashari@thewomens.org.au



Table 1. Serial echocardiogram of heart over the course of pregnancy.

Gestation (weeks + days)	11 + 3	17 + 3	21 + 3	25 + 1	28 + 3	29 + 2
Aortic root (mm)	39	41	42	42	42	42

echocardiography of the aortic root and ascending aorta should be undertaken.^{4,6}

We describe a twin delivery in a patient with LDS and a mutation that has been rarely reported in association with pregnancy. A dichorionic diamniotic (DCDA) twin pregnancy was conceived via in vitro fertilisation (IVF). Delivery occurred via planned caesarean section (CS) at 30 + 1 weeks' gestation due to concerns regarding fetal welfare secondary to placental insufficiency and avoidance of unplanned delivery.

Case report

A 37-year-old primigravida with LDS was referred to our tertiary level maternity hospital at 26 weeks' gestation after IVF elsewhere resulted in a DCDA twin pregnancy.

Genetic testing in 2015 made the diagnosis of LDS due to a *TGFB2* exon 6 c.979 C > T mutation. Maternal past history included talipes equinovarus requiring operations resulting in chronic pain and treatment with ×2 sacral nerve stimulators, diplopia, asthma, depression, and multiple hernia repairs.

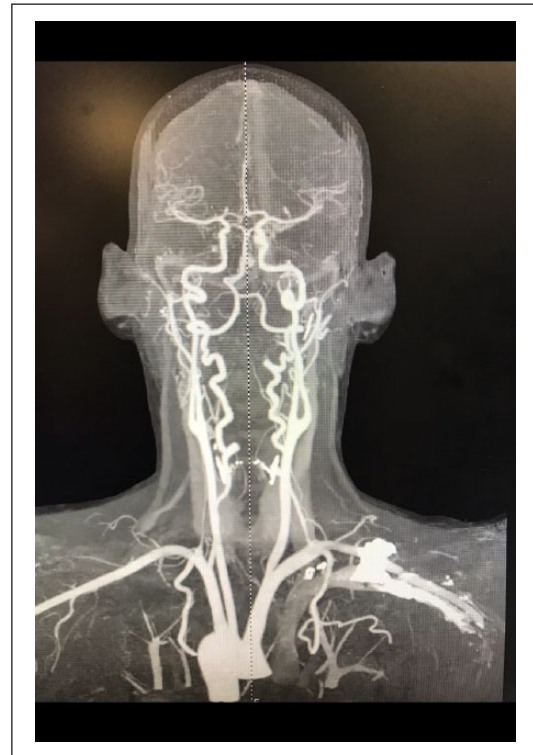
Her family history identified eight affected individuals, with one aortic dissection in an aunt aged 49 (aortic root diameter 45 mm), multiple aortic operations, and two gene-positive relatives with reportedly uncomplicated vaginal and caesarean deliveries.

Regular cardiology review with annual echocardiograms had been undertaken elsewhere since her teenage years. Before pregnancy, the aortic root diameter was 39 mm. No prior imaging of the entire vascular tree had been undertaken and sacral nerve stimulators precluded MRI. Spinal computed tomography (CT) 3 years earlier suggested sacral dural ectasia.

During pregnancy, echocardiograms showed an increase in the aortic root diameter from 39 to 42 mm (Table 1).

Pre-pregnancy irbesartan 300 mg once daily had been transitioned to labetalol 100 mg twice daily due to the contraindication of angiotensin receptor blockers in pregnancy. At 28 weeks' gestation, this was increased to 200 mg three times a day with the aim of reducing the heart rate to 60–70 beats per minute.

Inpatient management commenced at 28 weeks' gestation due to suspected growth restriction in Twin 2 (absent-end diastolic flow in the umbilical artery Doppler). Although delivery was initially planned via CS at 32–34 weeks' gestation due to concerns around the theoretical risk of uterine rupture, the caesarean actually occurred at 30 + 1 weeks' gestation due to fetal welfare and desire to avoid unplanned delivery. Prior to delivery, betamethasone

**Figure 1.** Postnatal cerebral CT angiogram.

was given to promote fetal lung maturity. Twin boys (birth weights of 1430 g and 1150 g) were delivered and admitted to neonatal intensive care. An atonic postpartum haemorrhage (PPH) of 1.3 L required oxytocin infusion and, despite the relative contraindication, 250 µg intramuscular ergometrine for management. She was subsequently transferred to the cardiology coronary care unit for 48 h of planned monitoring. Echocardiogram on Day 1 reported an aortic root dilatation of 43 mm, confirmed with a CT angiogram showing a trans-sinus (cusp-cusp) diameter of 43 mm. She was discharged to the postnatal ward on Day 3, and a repeat echocardiogram on Day 8 showed a stable aortic root diameter of 43 mm.

Although animal data in a mouse Marfan Syndrome (MFS) model has raised the possibility that breastfeeding increases the risk of aortic dissection,⁷ our patient elected to express her breast milk after discussion of the potential theoretical risk.

After delivery, medication was changed to metoprolol 125 mg twice daily. The postpartum course was uneventful with good wound healing, and she was discharged home on Day 9 with a plan for a repeat echocardiogram and clinical review at 6 weeks postpartum with subsequent early aortic root repair planned. A postnatal cerebral CT revealed the

arterial tortuosity considered characteristic for the condition (Figure 1).

Discussion

Reports of LDS and pregnancy are limited, and the largest series only includes the commonest mutations.⁸ This case report highlights the challenges of managing women with rare conditions. Preconception counselling and embryo transfer occurred at another medical service. The decision to not undergo pre-implantation genetic diagnosis (PGD) was made by the patient. Double embryo transfer would not be advised in conditions with propensity for uterine rupture.

There is little published on the management of pregnancy in these patients. Preconception, vascular system assessment is recommended via CT or MRI. Prophylactic preconception aortic root replacement is advised; however, there is a lack of consensus regarding the precise indication for such surgery, and most consensus statements refer to MFS rather than specifically to LDS. European guidelines suggest preconception aortic root replacement at 45 mm or greater.⁹ North American guidelines¹⁰ suggest preconception surgery at greater than 40 mm and a Canadian position statement suggests preconception surgery at 41–45 mm.¹¹ In contrast, the 2018 European guidelines advise against pregnancy if 45 mm or greater.¹² Patients with LDS can have dural ectasia and cervical spine abnormalities.^{6,13} Pre-pregnancy imaging of the spine allows anaesthetic planning.

As LDS is an autosomal dominant disorder, there is a 50% risk that a fetus will be affected if either parent has the condition. PGD or early-pregnancy testing potentially allow antenatal identification of affected pregnancies.⁴

Multidisciplinary care should be provided in a tertiary-level maternity hospital with clear plans for preconception, antenatal, peri-delivery and postnatal management between specialties. Regular follow-up, close blood pressure monitoring and use of β -blockers to maintain low normal blood pressure and heart rate are crucial.⁶ Monthly assessment of aortic diameter via echocardiography is recommended.⁴

The risk of vaginal delivery versus CS is difficult to quantify with very little evidence available, particularly in multiple pregnancy and with this mutation. The most recent European guidelines suggest vaginal delivery in patients with aortic connective tissue disorders if the aortic diameter is less than 40 mm, which this mode may be considered between 40 and 45 mm and that CS should be considered when it is greater than 45 mm.¹² Preterm CS is often undertaken due to reports of uterine rupture and the hypothetical risk of aortic dissection.^{2,4}

In the case of PPH, tranexamic acid, misoprostol and surgical procedures are recommended. In general, ergometrine is usually contraindicated due to concerns about resultant hypertension; however, it is recognised that at times, blood loss may be severe enough to warrant its use, as occurred in

this case. To date, there is no established guideline concerning the use or type of oxytocin for the management of the third stage of labour in women with LDS. However, the accepted consensus is oxytocin infusion rather than bolus administration.⁴

Increased risk of aortic dissection persists for some weeks post-delivery.^{2,14–16} Extended inpatient monitoring, repeat aortic root imaging, and maintaining normal blood pressure are important.⁴

Conclusion

LDS is a rare condition with a significant risk of pregnancy-related complications. Preconception counselling and assessment is strongly recommended. Pregnancy should be managed by a multidisciplinary team in a tertiary-level maternity hospital with regular aortic root imaging and β -blockade. Management of these women is limited by the paucity of data. This case is reported to add to the body of experience. Sharing of pregnancy data, regardless of outcomes, ideally through a registry is the likely best way to ascertain the true risks and reasonable management options in such rare maternal diseases.

Declaration of conflicting interests

The author(s) declared no potential conflicts of interest with respect to the research, authorship and/or publication of this article.

Ethical approval

Our institution does not require ethical approval for reporting anonymised individual cases or case series.

Funding

The author(s) received no financial support for the research, authorship and/or publication of this article.

Informed consent

Written informed consent was obtained from the patient for their anonymized information to be published in this article.

ORCID iD

Homira Bashari  <https://orcid.org/0000-0001-6765-7646>

References

1. Loeys BL, Chen J, Neptune ER, et al. A syndrome of altered cardiovascular, craniofacial, neurocognitive and skeletal development caused by mutations in TGFBR1 or TGFBR2. *Nat Genet* 2005; 37(3): 275–281.
2. Loeys BL, Schwarze U, Holm T, et al. Aneurysm syndromes caused by mutations in the TGF-beta receptor. *N Engl J Med* 2006; 355(8): 788–798.
3. Schepers D, Tortora G, Morisaki H, et al. A mutation update on the LDS-associated genes TGFBR2/3 and SMAD2/3. *Hum Mutat* 2018; 39(5): 621–634.

4. Frise CJ, Pitcher A and Mackillop L. Loeys–Dietz syndrome and pregnancy: the first ten years. *Int J Cardiol* 2017; 226: 21–25.
5. Zentner D, West M, Ades LC, et al. Update on the diagnosis and management of inherited aortopathies, including Marfan syndrome. *Heart Lung Circ* 2017; 26(6): 536–544.
6. MacCarrick G, Black JH 3rd, Bowdin S, et al. Loeys–Dietz syndrome: a primer for diagnosis and management. *Genet Med* 2014; 16(8): 576–587.
7. Habashi JP, Gallo EM, Huso N, et al. A causative role for oxytocin in pregnancy-induced aortic dissection in Marfan syndrome mouse models. In: *Presented at the Annual Meeting of the American Society of Human Genetics*, San Diego, CA, 12 October 2014.
8. Jondeau G, Ropers J, Regalado E, et al. International registry of patients carrying TGFBR1 or TGFBR2 mutations: results of the Montalcino Aortic Consortium. *Circ Cardiovasc Genet* 2016; 9(6): 548–558.
9. Erbel R, Aboyans V, Boileau C, et al. 2014 ESC guidelines on the diagnosis and treatment of aortic diseases: document covering acute and chronic aortic diseases of the thoracic and abdominal aorta of the adult. *Eur Heart J* 2014; 35(41): 2873–2926.
10. Hiratzka LF, Bakris GL, Beckman JA, et al. 2010 ACCF/AHA/AATS/ACR/ASA/SCA/SCAI/SIR/STS/SVM guidelines for the diagnosis and management of patients with thoracic aortic disease. A report of the American College of Cardiology Foundation/American Heart Association Task Force on Practice Guidelines, American Association for Thoracic Surgery, American College of Radiology, American Stroke Association, Society of Cardiovascular Anesthesiologists, Society for Cardiovascular Angiography and Interventions, Society of Interventional Radiology, Society of Thoracic Surgeons, and Society for Vascular Medicine. *Circ* 2010; 121(13): 266–369.
11. Boodhwani M, Andelfinger G, Leipsic J, et al. Canadian cardiovascular society position statement on the management of thoracic aortic disease. *Can J Cardiol* 2014; 30(6): 577–589.
12. Regitz-Zagrosek V, Roos-Hesselink JW, Bauersachs J, et al. 2018 ESC Guidelines for the management of cardiovascular diseases during pregnancy. *Eur Heart J* 2018; 39: 3165–3241.
13. Cronin J, Bazick HC, Dong H, et al. Anaesthesia considerations for caesarean delivery in a patient with Loeys–Dietz syndrome. *Anesth Analg Case Rep* 2015; 4(4): 47–48.
14. Kunishige H, Ishibashi Y, Kawasaki M, et al. Surgical treatment for acute type A aortic dissection during pregnancy (16 weeks) with Loeys–Dietz syndrome. *Gen Thorac Cardiovasc Surg* 2012; 60(11): 764–767.
15. Braverman AC, Moon MR, Geraghty P, et al. Pregnancy after aortic root replacement in Loeys–Dietz syndrome: high risk of aortic dissection. *Am J Med Genet A* 2016; 170(8): 2177–2180.
16. Fujita D, Takeda N, Morita H, et al. A novel mutation of TGFBR2 causing Loeys–Dietz syndrome complicated with pregnancy-related fatal cervical arterial dissections. *Int J Cardiol* 2015; 201: 288–290.