

Gram-negative folliculitis caused by *Morganella morganii*



Fatemeh Livani, MD,^a and Soodeh Kabir, MD^b
Gorgan and Rasht, Iran

Key words: folliculitis; gram-negative bacteria; *Morganella morganii*.

INTRODUCTION

Morganella morganii (MM) is an anaerobic gram-negative enteric bacterium belonging to the Enterobacteriaceae family. Urinary and hepatobiliary tracts, blood, and skin are the main ports of entry. The microorganism is an opportunistic pathogen usually presenting as a nosocomial infection involving the urinary tract and surgical wounds.¹ However, MM can also present as bacteremia, meningitis, ecthyma gangrenosum, spontaneous bacterial peritonitis, cellulitis, chorioamnionitis, septic arthritis, endophthalmitis, and cutaneous abscess.² Here we present a gram-negative folliculitis (GNF) caused by MM.

CASE REPORT

A 30-year-old man with unremarkable medical history referred to our clinic with a 1-year history of resistant nodulocystic lesions on his face and neck. The patient had already been treated with several courses of antibiotics including doxycycline, azithromycin, and clindamycin with only partial improvement. His medication history was also notable for 1-year intermittent use of a potent topical steroid on facial lesions. On physical examination, multiple pustular and nodulocystic lesions were noted mainly on his cheeks and neck (Fig 1).

Using a sterile technique, lesions were sampled, and obtained pus was sent for Gram staining and culture. Gram staining was positive for gram-negative rods. Three culture media including blood agar, MacConkey agar, and eosin methylene blue agar were used. After 24 hours, monomorphic

Abbreviations used:

GNF:	gram-negative folliculitis
MM:	<i>Morganella morganii</i>
MMGNF:	<i>Morganella morganii</i> -induced gram-negative folliculitis

gram-negative, catalase-positive, oxidase-negative, urease-positive, H₂S-negative bacillus grew similarly on all media. Finally, biochemical standard methods confirmed the isolation of MM. Antibiogram found susceptibility to ciprofloxacin, cotrimoxazole, imipenem, and ceftriaxone; relative susceptibility to gentamycin; and resistance to tobramycin and azithromycin.

With the final diagnosis of *Morganella morganii*-induced gram-negative folliculitis (MMGNF), the patient was started on oral ciprofloxacin, 500 mg twice a day. In addition, weekly abscess drainage was done up to 3 weeks, and at 4 weeks, the lesions had resolved completely (Fig 2). Ciprofloxacin was continued for 4 more weeks and stopped. Finally, lesions did not recur over the 2-year course of follow up.

DISCUSSION

In 1968, Fulton et al³ first described GNF in a group of acne vulgaris patients whose disease was resistant to conventional therapies. GNF mainly occurs in acne patients who have been using broad-spectrum antibiotics for a long time.

Generally, GNF caused by long-term antibiotic use has 2 different presentations. Commonly, it

From the Infectious Disease Research Center, Golestan University of Medical Sciences^a and the Dermatology Research Center, Guilan University of Medical Sciences.^b

Funding sources: None.

Conflicts of interest: None disclosed

This case was presented as a poster in the American Academy of Dermatology Annual Meeting, Washington, DC, March 1-5, 2019.

Correspondence to: Soodeh Kabir, MD, 111 West Centre Street, Apt: 1105, Baltimore, MD, 21201. E-mail: Soodehkabir@yahoo.com.

JAAD Case Reports 2019;5:558-9.
2352-5126

© 2019 by the American Academy of Dermatology, Inc. Published by Elsevier, Inc. This is an open access article under the CC BY-NC-ND license (<http://creativecommons.org/licenses/by-nc-nd/4.0/>).

<https://doi.org/10.1016/j.jidcr.2019.04.021>

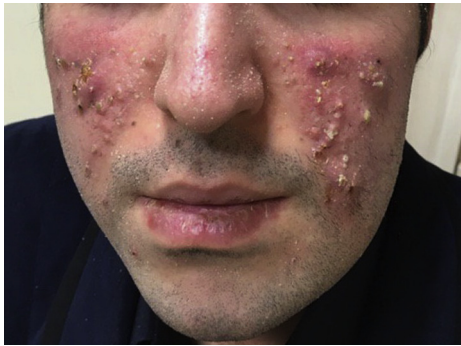

Fig 1. Initial presentation of multiple pustular and nodulocystic lesions on the cheeks and neck.

presents with superficial pustular lesions mostly on the perinasal area (type I), which is mainly caused by infection with lactose-fermenting gram-negative rods including *Escherichia*, *Klebsiella*, and *Serratia*. Type II presentation, however, includes nodulocystic lesions developing from infection with *Proteus* species.⁴ Clinical presentation of this case was similar to that of *Proteus*-induced GNF (ie, nodulocystic lesions). This can be because both MM and *Proteus* belong to the tribe III of the Enterobacteriaceae, which could explain their similar presentation of infecting deeper layers of skin.

It is suggested that immunologic factors might play a role in the development of GNF.⁵ Given that MM is found mostly in immunosuppressed individuals,¹ the fact that we found it in an immunocompetent person may, in part, be explained by the patient's frequent topical corticosteroid use.

In our review of the literature, we did not find any report regarding MMGNF. This case presentation, adds *Morganella morganii*, another member of the Enterobacteriaceae family, to the list of other already-known pathogens that cause GNF. In addition, MMGNF can be treated with a similar approach used to treat GNF caused by other pathogens.

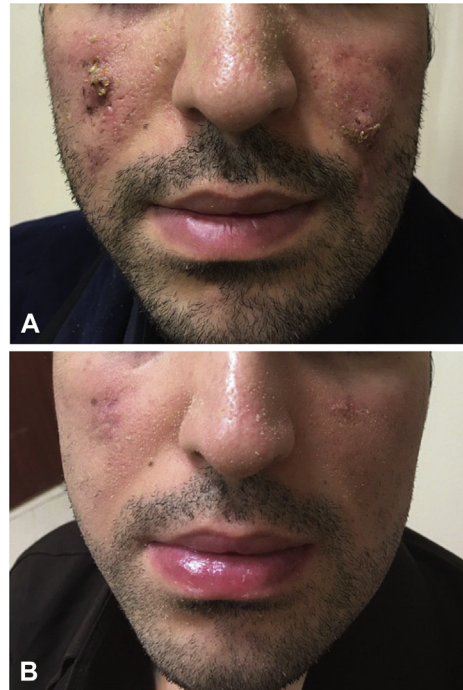


Fig 2. **A**, Partial improvement after 2 weeks of treatment with oral ciprofloxacin. **B**, Complete improvement after 4 weeks of treatment.

REFERENCES

1. Liu H, Zhu J, Hu Q, Rao X. *Morganella morganii*, a non-negligent opportunistic pathogen. *Int J Infect Dis*. 2016;50:10-17.
2. D V, Jv S, Mk Y, S S. *Morganella morganii* causing abscess over the anterior chest wall- a case report. *J Clin Diagn Res*. 2014;8(9):DD03.
3. Fulton JE Jr, McGinley K, Leyden J, Marples R. Gram-negative folliculitis in acne vulgaris. *Arch Dermatol*. 1968;98(4):349-353.
4. Leyden JJ, Marples RR, Mills OH Jr, Kligman AM. Gram-negative folliculitis-a complication of antibiotic therapy in acne vulgaris. *Br J Dermatol*. 1973;88(6):533-538.
5. Neubert U, Jansen T, Plewig G. Bacteriologic and immunologic aspects of gram-negative folliculitis: a study of 46 patients. *Int J Dermatol*. 1999;38(4):270-274.