

Case Report

Terson syndrome with persistent vitreous hemorrhage following traumatic brain injury



Mehmet Citirik*; Kemal Tekin; Mehmet Yasin Teke

Abstract

The objective of this study was to report clinical findings and surgical outcomes of 3 patients with persistent vitreous hemorrhage diagnosed as Terson syndrome (TS). Posterior segment changes, optical coherence tomography scans, fundus autofluorescence images, and fundus fluorescein angiography findings of patients were evaluated and pars plana vitrectomy (PPV) was performed on 3 eyes of three patients. All eyes operated after 6 months from the date of injury and final visual acuities were 20/200, 20/60 and 20/30. PPV is found as a safe and effective procedure for vitreous hemorrhage in TS. Delayed surgery in a young patient predicts a worse outcome.

Keywords: Intracerebral hemorrhage, Intraocular hemorrhage, Subarachnoid hemorrhage, Traumatic brain injury, Terson syndrome

© 2018 The Authors. Production and hosting by Elsevier B.V. on behalf of Saudi Ophthalmological Society, King Saud University. This is an open access article under the CC BY-NC-ND license (<http://creativecommons.org/licenses/by-nc-nd/4.0/>).
<https://doi.org/10.1016/j.sjopt.2018.11.003>

Introduction

Traumatic brain injury (TBI) is a kind of brain damage from an external mechanical force associated with diminished or altered state of consciousness.¹ The mechanisms of neural injury in TBI have been categorized as primary (those occurring at the time of the injury) and secondary (those occurring minutes to days after the injury, and are broadly the consequence of the host response). These are mostly similar in military and civilian TBI.¹

Vitreous hemorrhage caused by subarachnoid hemorrhage (SAH) was reported as Terson syndrome (TS). At present, any kind of intraocular hemorrhage (IOH) including vitreous, pre-, intra-, and sub-retinal hemorrhage in the patients suffering from SAH, intracerebral hemorrhage (ICH), or TBI defined as TS.² It is closely associated with trau-

matic intracranial hemorrhage, neurological symptoms and high mortality risk.³ Although the pathogenesis of TS is still controversial, the most currently accepted mechanism is a sudden increase in intracranial pressure (ICP) transmitted by the optic nerve sheath to the optic nerve head results in rupture of retinal vessels secondary to intraocular venous hypertension.⁴ Vitreous and retinal hemorrhages associated with TS are spontaneously resolved with conservative treatment in most patients and surgical intervention is required for only few patients. Modern pars plana vitrectomy (PPV) is currently an effective and safe surgical procedure for the treatment of persistent vitreous hemorrhage in the patients with TS.⁵

In this report, we describe successful treatment of three cases of TS with PPV. In addition, we discussed clinical findings and ancillary testing modalities in the patients with TS.

Received 4 November 2017; received in revised form 5 November 2018; accepted 27 November 2018; available online 7 December 2018.

University of Health Sciences, Ankara Uluçanlar Eye Education and Research Hospital, Ankara, Turkey

* Corresponding author at: University of Health Sciences, Ankara Uluçanlar Eye Education and Research Hospital, Uluçanlar Cad. No: 59 06230, Altındag, Ankara, Turkey. Fax: +90 312 312 48 27.
e-mail address: mcitirik@hotmail.com (M. Citirik).



Peer review under responsibility of Saudi Ophthalmological Society, King Saud University



Production and hosting by Elsevier

Access this article online:
www.saudiophthaljournal.com
www.sciencedirect.com

Case Reports

All of the study procedures were conducted in accordance with the Declaration of Helsinki, and informed consents were taken from the participants after approval from the Institutional Review Board. All patients were Turkish Caucasians.

Case #1

A 22-year-old woman was admitted to the hospital with decreased visual acuity in her left eye. Relevant past ocular history included extensive SAH with intraventricular hemorrhage following fall down from the first floor 8 months ago. Computed tomography scan showed evidence of brain contusion. Endovascular treatment by coiling to prevent rebleeding was performed previously. Her best-corrected visual acuity (BCVA) was 20/20 in OD and hand movement in OS. Intraocular pressure values were 14 and 15 mmHg with applanation in the right and left eyes, respectively. Slit-lamp examination of the left eye showed hemorrhage inferiorly spreading throughout the vitreous cavity. Spectral domain optical coherence tomography (OCT) showed the outer retinal layers were contracted. Also, the proliferative epiretinal fibroglial membranes, that causes the tangential traction by thickening and tightening the detached posterior hyaloid and anchoring the posterior hyaloid to the surrounding retinal surface were observed (Fig. 1A). 23-G transconjunctival sutureless PPV with ILM-peeling was performed. Follow-up examinations were performed at 3 months after surgery. The patient's BCVA had improved to 20/200 and intraocular pressure was 12 mmHg with applanation. OCT revealed disappearance of macular traction with the loss of photoreceptor layer (Fig. 1B). Fundus photography showed that surface irregularity has disappeared (Fig. 1C). Fundus autofluorescence (FAF) showed scattered foci of hyper- and hypo- autofluorescence (Fig. 1D).

Case #2

A 26-year-old woman was admitted to the hospital with decreased visual acuity in her right eye. She was struck by a passenger car and strongly hit her forehead on the road 7 months ago. Her history included extensive SAH caused by traffic accident. Large intracerebral hematomas were removed with decompressive craniectomy. At the same time, she developed visual acuity loss in the right eye. Her BCVA was hand movement in OD and 20/20 in OS. Intraocular pressures were 14 and 16 mmHg with applanation in the right and left eyes, respectively. Slit-lamp examination of right eye displayed dense hemorrhage located centrally in the vitreous cavity (Fig. 2A). Fluorescein angiogram showed blockage of fluorescence by hemorrhage (Fig. 2B). PPV from posterior vitreous-to-vitreous base was performed using 23-G transconjunctival sutureless technique. On third month after surgery, her visual acuity was 20/60 in OD. An intraocular pressure with applanation was 10 mmHg. The vitreous had become clear and the retina was clearly visible (Fig. 2C). Fluorescein angiogram showed late hyperfluorescence resulting from the accumulation of fluorescein dye in previous margin of hemorrhage (Fig. 2D). ILM detachment was detected by OCT (Fig. 2E).

Case #3

A 25-year-old man was admitted to the hospital with decreased visual acuity in his left eye. He had fallen down while running in sport center 6 months ago. He had undergone craniotomy and clipping of the artery. Meanwhile, he developed visual acuity loss in the left eye. His BCVA was 20/20 in OD and hand movement in OS. Intraocular pressures were 11 and 12 mmHg with applanation in the right and left eyes respectively. Slit-lamp examination of left eye showed hemorrhage diffusely spreading throughout the vitreous cavity (Fig. 3A, B). OCT scan showed the loss of the foveal depression and overlying vitreous hemorrhage (Fig. 3C). 23-G transconjunctival sutureless PPV with posterior hyaloid removal was performed. Follow-up examinations were performed at 3 months after surgery. The patient's visual acuity had improved to 20/30. An intraocular pressure was 13 mmHg with applanation. The vitreous had become clear. OCT showed the loss of the foveal depression and minimal epiretinal membrane (Fig. 3B).

Discussion

TBI is an important global public health problem. It occurs when a force transmitted to the head or body results in neuropathologic damage and dysfunction.⁶ It is the major cause of disability, mortality and morbidity in many countries and particularly in the younger age groups. TBI kills more people than cancer or AIDS but contrary to these diseases, most of the causes are known and can be prevented.⁶ The incidence of TBI continues to increase despite awareness of the causes. The leading causes of TBI are car crashes, falls, injury in military and sports.⁶ In our case series, a predisposing factor causing vitreous hemorrhage was present in each patient; falling was in the first one, car crush was in the second, and injury in sports was in the last patient.

Military related TBI is a main cause among military personnel in active war zones and includes concussion, subconcussion, and most exposures to explosive blast from improvised explosive devices.⁷ In the recent years, sport-related traumatic brain injury (SrTBI) is discussed increasingly. SrTBI may be acute or chronic; acute injury may lead to concussion, subconcussion, hemorrhage or other structural brain damages, while chronic injury may cause a neurodegenerative condition, chronic traumatic encephalopathy, in which progressive clinical signs often start several years after retiring from the sport.⁸ In the case 3, vitreous hemorrhage due to retinal capillary disruption as a result of an acute SrTBI mechanism may have caused to loss of vision.

Terson syndrome, a known complication of cerebral hemorrhage, may lead to loss of vision. Vision loss develops subsequent to vitreous hemorrhage, as a result of retinal capillary disruption secondary to cerebral hemorrhage. The pathogenesis of TS has been suggested to be associated with an impairment of the retinal microcirculation as a result of increased ICP following cerebral hemorrhage, which ultimately results in venous hypertension and hemorrhage.

TBI may cause many short or long term vision disorders including accommodative dysfunction, version deficits, vergence dysfunction, visual field deficits, photosensitivity and other cognitive and perceptual impairments.⁹ It is so important because vision disorders following TBI are common,

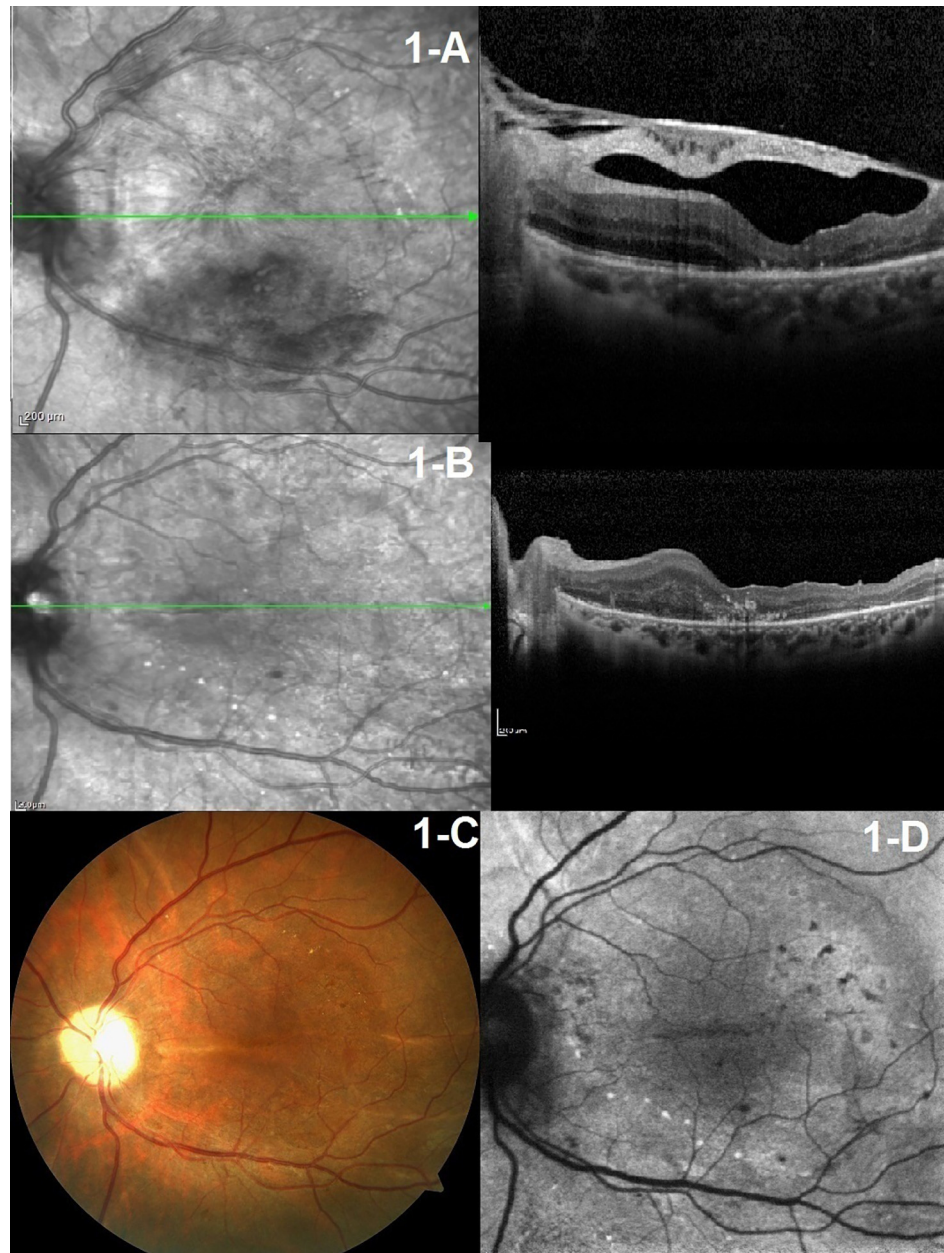


Fig. 1. Preoperative and postoperative retinal images in patient 1.

the prevalence varies from 30% to 85% depending on the condition.⁹

Terson syndrome is a monocular vision disorder recognized as IOH associated with SAH, ICH, or TBI. It occurs in 8–14.5% of SAH, 9.1% of ICH, 3.1% of TBI, and accounts for 5.5% of all non-traumatic and non-diabetic vitreous hemorrhages.¹⁰ The study of Kuhn et al.¹⁰ showed that IOHs seems to be related to the severity of the SAH, 89% of the patients with IOH had a history of coma compared with 46% of those without intraocular hemorrhage. The exact mechanism of TS is still controversial, only a few prospective studies have been reported by now, and there are even fewer concerning the context of TS and TBI. There are some theories to explain the surge of IOHs. Ogawa et al.⁴ reported a patient with SAH and unilateral vitreous hemorrhage and proposed another mechanism where ICP is transmitted down

the optic nerve sheath directly damaging peripapillary tissue results in vitreous hemorrhage. A recent study using scanning laser ophthalmoscopy and intraoperative imaging showed that blood may enter the vitreous cavity from the retinal vessels around the optic disc and it may spread intraretinally, sub-internal limiting membrane, or along the retinal vessels inside the eye.¹¹ Although the source of hemorrhage has still not been exactly determined, the prevailing theory is that a sudden increase in ICP transmitted via the optic nerve sheath to the optic nerve head results in a rupture of retinal vessels due to the intraocular venous hypertension. Nasseri et al.¹² described a case of TS following epidural saline injection which supports the theory of intraocular venous hypertension, in the absence of intracranial hemorrhage.

TS may present with any kind of intraocular hemorrhage (IOH) including vitreous, pre-, intra-, and sub-retinal hemor-

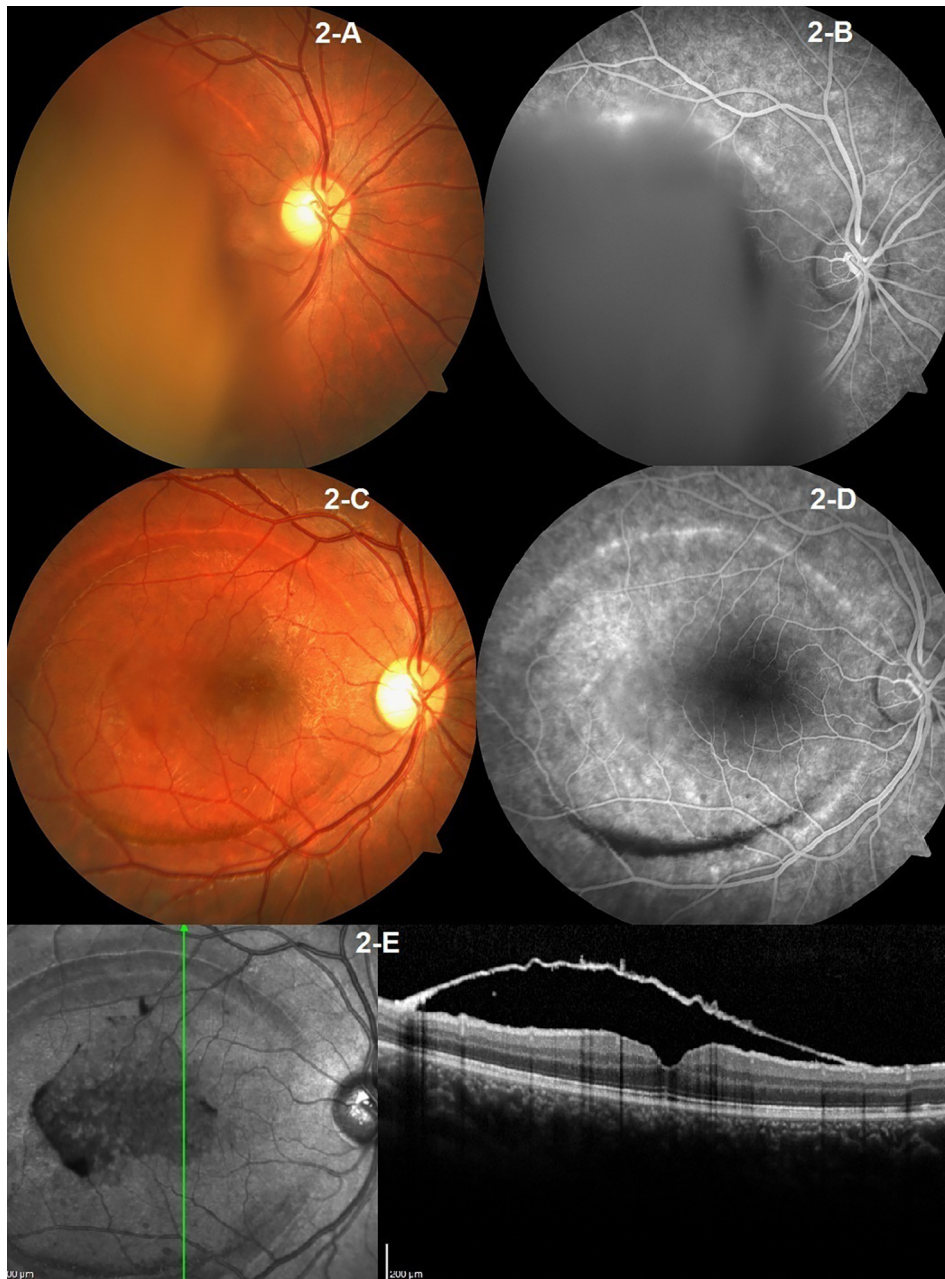


Fig. 2. Preoperative and postoperative retinal images in patient 2.

rhage.² In our case series, vitreous hemorrhage was seen in all of the patients and it was treated with PPV. Although, there is no consensus on the optimal timing for PPV in TS, timely surgical removal of the vitreous hemorrhage usually results in significant and immediate improvement of visual acuity and may also prevent hemorrhage related complications.¹² The absorption of vitreous hemorrhage in TS may be fairly slow. It is reported that vitreous hemorrhage may persist for as long as 6 years in TS.¹² In another study, Shaw and Landers¹³ showed that 44% of vitreous hemorrhages is not resorbed followed for a mean of 19 months. PPV not only leads to shortening the time for visual recovery but also prevents potential complications of persistent vitreous hemorrhage such as hemosiderosis, epiretinal membranes, retinal detachment, proliferative vitreoretinopathy, iron toxicity,

and other macular abnormalities.¹⁰ Kuhn et al.¹⁰ reported 96% of patients had rapid visual improvement and 81% had better than 20/30 visual acuity after performing PPV for dense vitreous hemorrhage in the patients with TS. Moreover, Garveg and Korner¹⁴ reviewed 45 cases with TS in order to assess factors interfering with the functional outcome after PPV and showed that final visual acuities of the eyes, which were operated within 90 days of occurrence of vitreous hemorrhage, were better than eyes that were operated after 90 days.

In addition, Augten et al.¹⁵ recommended PPV within four to eight weeks after the injury in the patients with bilateral TS. In our case series, delayed PPV was performed. Especially, persistent vitreous hemorrhage can damage the photoreceptors and contribute to retinal atrophy in case 1.

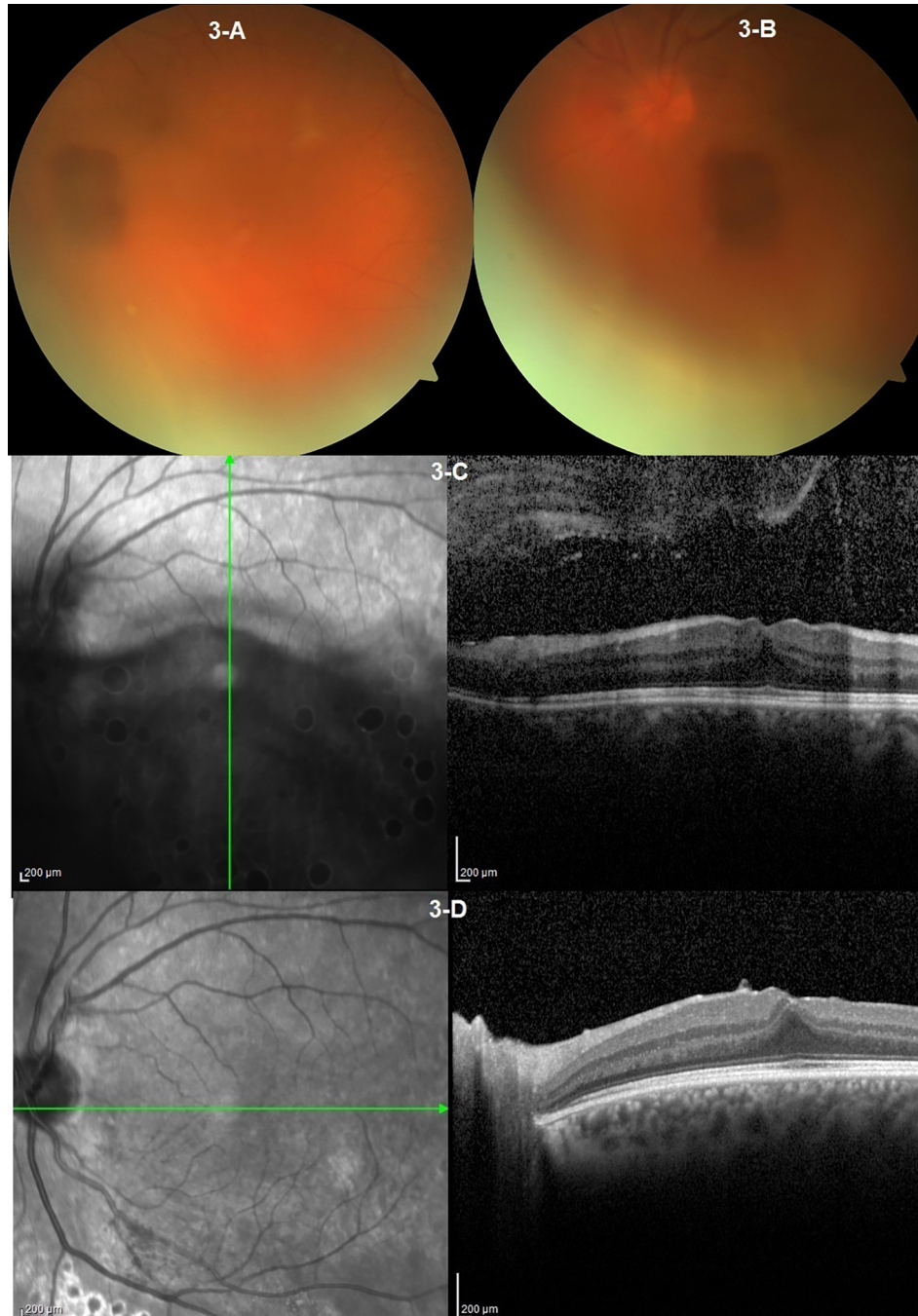


Fig. 3. Preoperative and postoperative retinal images in patient 3.

As a conclusion, PPV is a safe and effective procedure for vitreous hemorrhage in TS. Early surgery may prevent alteration in retinal structure. Delayed surgery may cause major risks and poor visual prognosis. The greatest risk to delaying surgery is the deterioration of retinal tissue and the progressive loss of photoreceptor cells. A longer time between occurrence of vitreous hemorrhage and surgery as well as a younger patient age may predict a worse outcome.

Disclosures on conflict of interest

The authors indicate no financial support or financial conflict of interest.

References

1. Risdall JE, Menon DK. Traumatic brain injury. *Philos Trans R Soc Lond B BiolSci* 2011;**366**(1562):241–50.
2. Castren JA. Pathogenesis and treatment of terson-syndrome. *Acta Ophthalmol (Copenh)* 1963;**41**:430–4.
3. Fountas KN, Kapsalaki EZ, Lee GP, et al. Terson hemorrhage in patients suffering aneurysmal subarachnoid hemorrhage: predisposing factors and prognostic significance. *J Neurosurg* 2008;**109**(3):439–44.
4. Ogawa T, Kitaoka T, Dake Y, Amemiya T. Terson syndrome: a case report suggesting the mechanism of vitreous hemorrhage. *Ophthalmology* 2001;**108**(9):1654–6.
5. Gnanaraj L, Tyagi AK, Cottrell DG, et al. Referral delay and ocular surgical outcome in Terson syndrome. *Retina* 2000;**20**(4):374–7.

6. Blennow K, Hardy J, Zetterberg H. The neuropathology and neurobiology of traumatic brain injury. *Neuron* 2012;**76**(5):886–99.
7. Warden D. Military TBI during the Iraq and Afghanistan wars. *J Head Trauma Rehabil* 2006;**21**(5):398–402.
8. Ling H, Hardy J, Zetterberg H. Neurological consequences of traumatic brain injuries in sports. *Mol Cell Neurosci* 2015;**66**(Pt B):114–22.
9. Kapoor N, Ciuffreda KJ. Vision disturbances following traumatic brain injury. *Curr Treat Options Neurol* 2002;**4**(4):271–80.
10. Kuhn F, Morris R, Witherspoon CD, Mester V. Terson syndrome. Results of vitrectomy and the significance of vitreous hemorrhage in patients with subarachnoid hemorrhage. *Ophthalmology* 1998;**105**(3):472–7.
11. Michalewska Z, Michalewski J, Nawrocki J. Possible methods of blood entrance in Terson syndrome. *Ophthal Surg Lasers Imag* 2010;**41**:s42–9.
12. Naseri A, Blumenkranz MS, Horton JC. Terson's syndrome following epidural saline injection. *Neurology* 2001;**57**(2):364.
13. Shaw Jr HE, Landers MB. Vitreous hemorrhage after intracranial hemorrhage. *Am J Ophthalmol* 1975;**80**(2):207–13.
14. Garweg JG, Koerner F. Outcome indicators for vitrectomy in Terson syndrome. *Acta Ophthalmol* 2009;**87**(2):222–6.
15. Augsten R, Königsdörffer E, Strobel J. Surgical approach in terson syndrome: vitreous and retinal findings. *Eur J Ophthalmol* 2000;**10**(4):293–6.