

RESEARCH ARTICLE

# Liver biopsy in type 2 diabetes mellitus: Steatohepatitis represents the sole feature of liver damage

Mario Masarone<sup>1</sup>, Valerio Rosato<sup>2</sup>, Andrea Aglitti<sup>1</sup>, Tommaso Bucci<sup>1</sup>, Rosa Caruso<sup>1</sup>, Teresa Salvatore<sup>2</sup>, Ferdinando Carlo Sasso<sup>2</sup>, Marie Françoise Tripodi<sup>1</sup>, Marcello Persico<sup>1\*</sup>

**1** Internal Medicine and Hepatology Unit, University of Salerno, Salerno, Italy, **2** Internal Medicine and Hepatology Department, University of Campania “L. Vanvitelli”, Naples, Italy

\* [mpersico@unisa.it](mailto:mpersico@unisa.it)



**OPEN ACCESS**

**Citation:** Masarone M, Rosato V, Aglitti A, Bucci T, Caruso R, Salvatore T, et al. (2017) Liver biopsy in type 2 diabetes mellitus: Steatohepatitis represents the sole feature of liver damage. PLoS ONE 12(6): e0178473. <https://doi.org/10.1371/journal.pone.0178473>

**Editor:** Patricia Aspichueta, University of Basque Country, SPAIN

**Received:** October 24, 2016

**Accepted:** May 13, 2017

**Published:** June 1, 2017

**Copyright:** © 2017 Masarone et al. This is an open access article distributed under the terms of the [Creative Commons Attribution License](https://creativecommons.org/licenses/by/4.0/), which permits unrestricted use, distribution, and reproduction in any medium, provided the original author and source are credited.

**Data Availability Statement:** According to the rules of Ethics Committee of the University of Campania “L. Vanvitelli” which approved the present study, supplementary material will be available upon request within an email to be sent to the corresponding author (M Persico: [mpersico@unisa.it](mailto:mpersico@unisa.it)) who will subsequently send a request for approval to the Ethics Committee, which, in turn, will release its permit to access the anonymized data for researchers who meet the criteria for access to confidential material.

## Abstract

Recent studies report a prevalence of non-alcoholic fatty liver disease (NAFLD) of between 70% and 80% in patients with metabolic syndrome (MS) and type 2 diabetes mellitus (T2DM). Nevertheless, it is not possible to differentiate between simple steatosis and non-alcoholic steatohepatitis (NASH) with non-invasive tests. The aim of this study was to differentiate between simple steatosis and NASH by liver biopsy in patients with hypertransaminasemia and MS or T2DM. Two hundred and fifteen patients with increased ALT levels and MS, and 136 patients at their first diagnosis of T2DM regardless of ALT values were consecutively admitted to a tertiary hepatology center between January 2004 and November 2014. Exclusion criteria were other causes of liver disease/ALT increase. Each patient underwent a clinical, laboratory and ultrasound evaluation, and a liver biopsy. Gender distribution, age, and body mass index were similar in the two groups of patients, whereas cholesterol levels, glycemia and blood pressure were significantly different between the two groups. The prevalence of NAFLD was 94.82% in MS patients and 100% in T2DM patients. NASH was present in 58.52% of MS patients and 96.82% of T2DM. Consequently, this study reveals that, by using liver biopsy, almost all patients with T2DM or MS have NAFLD, which in patients with T2DM means NASH. Importantly, it suggests that NASH may be one of the early complications of T2DM due to its pathophysiological correlation with insulin resistance.

## Introduction

Liver diseases encompass a wide range of clinical signs and histological damage that lead to different degrees of necrosis, inflammation and fibrosis, of which the pathological accumulation of fat in the liver cell (namely steatosis) is often considered one of the first steps of an evolving chronic process [1,2]. Liver steatosis is frequently reported in patients affected by obesity or type 2 diabetes mellitus (T2DM) [3]. The main pathophysiological mechanisms underlying liver steatosis are, at intracellular level, mitochondrial alterations that are also involved in insulin resistance (IR) [4]. These alterations represent the pathophysiological link to the clinical

**Funding:** The authors received no specific funding for this work.

**Competing interests:** The authors have declared that no competing interests exist.

**Abbreviations:** HCC, hepatocellular carcinoma; HOMA, homeostasis model assessment; IR, insulin resistance; NAFL, non-alcoholic fatty liver; NAFLD, non-alcoholic fatty liver disease; NASH, non-alcoholic steatohepatitis.

manifestations (hypertension and dyslipidemia) of metabolic syndrome (MS) [5]. The latter syndrome is a cardiovascular disease risk factor. Liver steatosis has been indicated as a cardiovascular risk factor even irrespective of the presence of MS [6] and is significantly related to biological parameters of IR [7].

A diagnosis of liver steatosis (without a history of alcohol abuse, toxic exposure, medication or metabolic disorders), also known as “non-alcoholic fatty liver disease” (NAFLD), is made in case of at least two clinical and histological entities: simple fat accumulation in the liver (“simple steatosis” or “non-alcoholic fatty liver” NAFL) and non-alcoholic steatohepatitis (NASH), which is characterized by fat accumulation, necroinflammation, cellular ballooning, and different stages of liver fibrosis, up to cirrhosis [2]. Simple steatosis and NASH differ in terms of their evolution over time, simple steatosis being a condition that generally does not progress to advanced fibrosis, whereas NASH can progress to liver cirrhosis and/or hepatocellular carcinoma (HCC) [2]. Thus, the differential diagnosis between these two entities is necessary in order to characterize and appropriately monitor patients who are at risk [8].

A series of studies, most of which were based on the non-invasive diagnosis of hepatic steatosis, reported that up to 70–80% of patients with MS and/or T2DM have NAFLD-like features [9–12]. Although clinical and ultrasound signs can identify liver cirrhosis, it is not possible to stage liver steatosis/steatohepatitis using the currently available non-invasive tests [13], and thus patients should undergo a histological examination for staging purposes [14]. Reliable staging of NAFLD is crucial because T2DM is an independent risk factor for HCC in NAFLD, also in non-cirrhotic patients [15–17]. Finally, opinions differ as to whether or not NAFL could chronically evolve and necessarily lead to steatohepatitis and cirrhosis [18]. Therefore, it is conceivable that steatosis might be considered the first insult to the liver that might evolve to liver fibrosis/cirrhosis depending on the patient’s genetic background, their dietetic habits and/or the underlying main disease (i.e., T2DM or MS) [18].

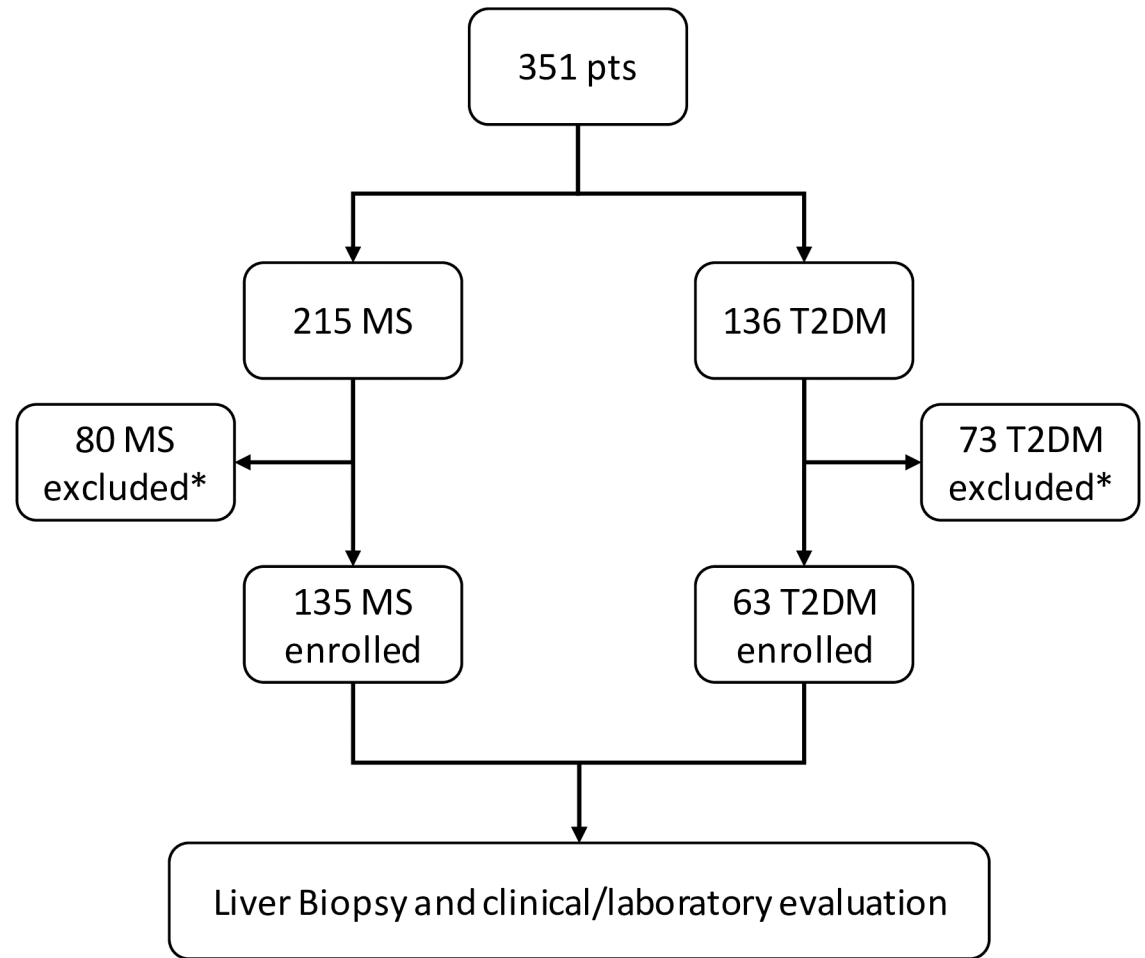
The aim of this study was to assess and stage by liver biopsy steatosis/NASH in patients with hypertransaminasemia and a diagnosis of MS or T2DM.

## Materials and methods

### Patients

As shown in Fig 1, 351 patients (215 with MS and 136 with T2DM) consecutively admitted to a tertiary center of Internal Medicine and Hepatology were evaluated for enrollment in this study between 1 January 2004 and November 2014. Inclusion criteria were: age >18 years, a clinical history (at least 3 evaluations taken within 1 month of each other) of ALT above normal values (>35 U/mL in males and >15 U/mL in females) and a diagnosis of MS according to ATP III criteria [19] or the first diagnosis of T2DM according to ADA criteria [20]. Exclusion criteria were any known cause of ALT increase, viral hepatitis (HCV, HBV, HSV, EBV or CMV), autoimmune disease, primary or secondary hemochromatosis, Wilson disease, Budd-Chiari disease, cardiac cirrhosis, elevated alcohol intake (>20 grams in females and >30 grams in males per day), and/or celiac disease. Active intravenous drug abuse and/or a history of pharmacotherapy with drugs capable of inducing ALT derangement in the three months prior to admission.

All patients without clinical/laboratory/ultrasound signs of liver cirrhosis (i.e. low platelet count, esophageal varices, spleen enlargement, caudate lobe hypertrophy at ultrasound examination) were asked to undergo liver biopsy. A total of 135/215 MS patients and 63/136 T2DM patients provided written informed consent to liver biopsy and enrolled in the present study. All enrolled patients underwent clinical, laboratory and ultrasound examinations. This study



\* Excluded patients were who didn't provide informed consent and/or presented with any of the exclusion criteria described in methods

**Fig 1. Flow chart of the present study protocol.**

<https://doi.org/10.1371/journal.pone.0178473.g001>

was approved by the Ethics Committee of the University of Campania “L. Vanvitelli”, and was conducted in agreement with the Helsinki Declaration 1975.

### Laboratory and virology tests

Upon hospital admission, each patient underwent a physical examination (body mass index [BMI], blood pressure and waist circumference [WC] measurements), and ultrasound examination of the abdomen, and blood samples were collected for fasting glucose and insulin, HbA1C, triglycerides, HDL cholesterol measurement, complete blood count, ALT and AST, routine biochemistry assay, hepatitis B surface antigen (HBsAg), hepatitis B core antibody (HBcAb), hepatitis A virus antibody (HAVAb) IgM (antibodies by ELISA, Orthodiagnostic system), hepatitis C antibody (HCVAb) (with commercial enzyme linked immunosorbent assay III, Abbot Laboratories Chicago), herpes simplex virus (HSV), anti-nuclear autoantibodies (ANA), anti-mitochondrial antibodies (AMA), smooth muscle antibodies (SMA), and liver

kidney microsomal antibodies (LKM). In patients without a diagnosis of T2DM, we calculated the HOMA-IR index and assessed MS according to ATPIII criteria [19,21].

## Liver biopsy and histological examination

Ultrasound guided biopsy was performed in the 135 MS and 63 T2DM patients who provided informed consent, and specimens were obtained from the right hepatic lobe using 17-gauge Menghini modified needles inserted through the intercostal space. The biopsy specimens were formalin-fixed, paraffin-embedded and stained with hematoxylin-eosin, Red Sirius, Ubiquitin, trichrome and Prussian blue. All liver biopsies were read by two experienced pathologists (TS and MP), with an inter-operator diagnostic concordance  $k > 0.8$ . Liver samples measuring  $\geq 15$  mm in length were deemed suitable for histologic analysis when they contained at least 5 entire portal spaces; samples  $< 15$  mm were not analyzed. Biopsies were evaluated with the Kleiner score [14] for necroinflammation grading, fibrosis staging and NASH activity score (NAS), and with the Brunt score [22] for the presence and extent of steatosis. Steatosis was graded 1 ( $< 33\%$  of hepatocytes), 2 (33–66% of hepatocytes) or 3 ( $> 66\%$  of hepatocytes), based on the number of fat-replete hepatic cells per microscopic field. Lipid vacuoles were divided according to size, and designated “micro-vacuolar”, “macro-vacuolar” or “mixed”. The minimal histological criteria for a diagnosis of NASH were: macrovesicular steatosis, hepatocyte ballooning, Mallory hyaline bodies, mixed lobular inflammation with polymorphonuclear leukocytes, zone 3 acinar pericellular fibrosis and/or perivenular fibrosis [1,23].

## Statistical analysis

Statistical analyses were performed using the Statistical Program for Social Sciences (SPSS<sup>®</sup>) ver.16.0 for Macintosh<sup>®</sup> (SPSS Inc., Chicago, Illinois, USA). The Student t-test and the Mann-Whitney U test were performed to compare continuous variables, chi-square with Yates correction or Fisher-exact test to compare categorical variables. Data were reported as mean  $\pm$  standard deviation for continuous variables with a normal distribution and as median and interval for those with “non-normal” distribution. Statistical significance was defined when  $p < 0.05$  in a two-tailed test with a 95% confidence interval.

## Results

The demographic, clinical and laboratory findings of our study population are reported in Table 1. The two groups of patients were comparable in terms of gender distribution, age and BMI. The levels of ALT and parameters related to IR (hypertension, total and HDL cholesterol) were significantly higher in MS patients. The significantly higher ALT levels ( $p = 0.0014$ ) in MS patients is due to the large number of T2DM patients with normal ALT levels. The histological diagnosis in the two groups of patients is reported in Table 2. The prevalence of NASH and cirrhosis was higher in patients with T2DM than in patients with MS ( $p < 0.0001$ ). NASH was diagnosed in 61/63 (98.6%) of patients with T2DM and in 58.52% patients with MS.

Prevalence of NAFLD and NASH reported in Fig 2 is in line with the data reported in Table 2. In particular, All T2DM patients had NAFLD, and 96.82% had NASH. Moreover, 7/135 (5.18%) MS patients had neither simple steatosis nor steatohepatitis signs at liver biopsy. Five of these 7 patients had a normal liver biopsy, whereas 2 had a histological presentation in which the only notable alteration was mild enlargement of hepatic sinusoids, which is compatible with a very mild presentation of “peliosis hepatis” [24], a rare type of liver injury that has been associated with a variety of causes, from drugs and chemotherapeutics, infections (including AIDS), neoplasms, malnutrition, cadmium intoxication, anabolic steroids use,

**Table 1. Demographical, clinical and laboratory parameters of study population.** (Data presented as mean (+ standard deviation) except where indicated differently.\* Cirrhosis diagnosis: 3 clinical, 13 by liver biopsy.

	MS	T2DM	p
Screened patients (n)	215	136	-
Liver Biopsy (n)	135	63	<b>0.002</b>
M/F (n)	80/55	33/30	0.036
AGE (years)	54.85 ±14.33	57.27 (±10.50)	0.955
BMI (kg/sqm)	33.8 (±6.8)	34.4 (±6.3)	0.473/
Waist Circumference (cm)	92.4 (±7.6)	93.2 (±9.3)	0.272
CHOL (mg/dL)	189.06 (±50.73)	182.27 (±31.85)	0.163
HDL (mg/dL)	37.79 (±13.59)	41.61(±10.46)	<b>0.005</b>
TRI Median (interval) (mg/dL)	151 (104–208)	159 (115–238)	0.178
HYPERTENSION (Y/N)	71/64	20/43	<b>0.01</b>
Glucose (mg/dL)	90.92 (±23.07)	148.07 (±50.51)	<b>&lt;0.0001</b>
HOMA Median (interval)	4.1 (2.5–5.8)	-	-
ALT (U/L)	143.41(±155.36)	45.33 (±29.99)	<b>&lt;0.0001</b>
AST (U/L)	140.86 (±131.28)	41.27 (±29.23)	<b>&lt;0.0001</b>
GGT (U/L)	85.71 (±53.94)	81.34 (±50.86)	0.459
Total bilirubin (U/L)	1.22 (±0.45)	1.18 (±0.47)	0.426
HBV (n)	0	0	-
HCV (n)	0	0	-
Cirrhosis (n)	0	16 (3+13)*	-

<https://doi.org/10.1371/journal.pone.0178473.t001>

myelo-lymphoproliferative disorders, and liver and renal transplantation [25]. Of note, neither of these two patients had any of these previously reported causes. The two “peliosis” patients and subjects with a normal liver biopsy were investigated for any possible extrahepatic cause of ALT derangement and none was found (i.e., no autoimmune/traumatic muscular damage, no cardiac diseases, no drug use, misuse or intoxication, no thyroid dysfunctions etc.).

The HOMA scores of patients with simple steatosis and NASH are reported in Fig 3. HOMA scores were significantly higher in NASH patients than in patients with simple steatosis (p<0.01). Notably, the HOMA scores of these two groups were above the value considered to be diagnostic for IR in Italy [21]. Lastly, as reported in Table 3, the histological activity scores evaluated according to Kleiner et al, [14] for NAFL/NASH were significantly higher in MS patients than in T2DM patients.

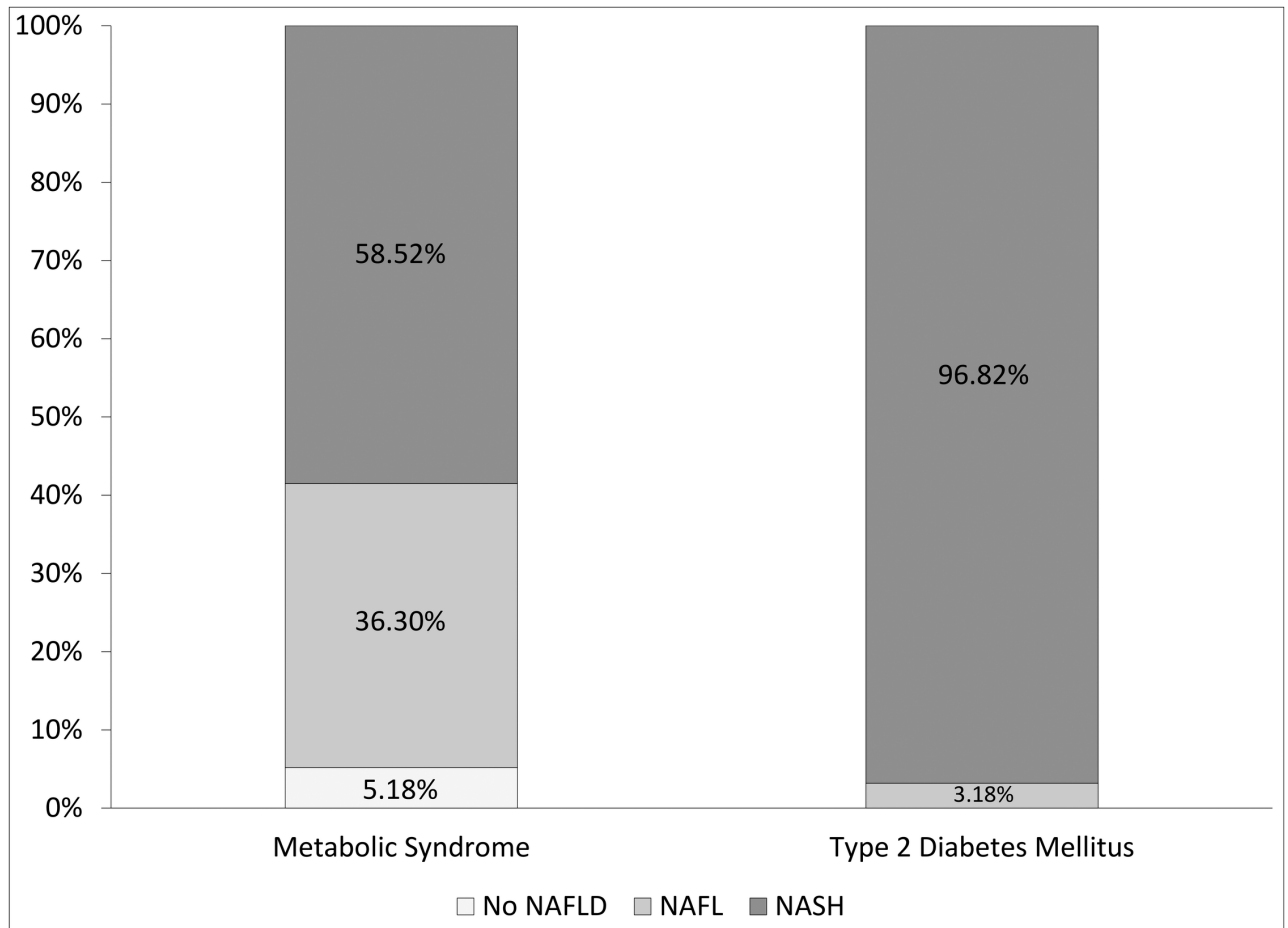
## Discussion

Non-alcoholic fatty liver disease is considered a benign disease, mostly related to the different clinical expression of IR, which ranges from altered lipid metabolism to MS and/or T2DM [8]. While simple steatosis can safely be considered a non-evolutive condition, steatohepatitis (NASH) should not be considered a benign disease because it may evolve into liver cirrhosis

**Table 2. Prevalence of NAFLD, NASH and cirrhosis in patients undergone to liver biopsy.** (NA: Not Applicable).

	MS	DM	OR (95%CI)	p
N	135	63	-	-
NAFLD n (%)	128/135 (94.82%)	63/63 (100%)	0.001 (0.001–1.138)	0.1
NASH	79/135 (58.52%)	61/63 (96.82%)	21.620 (5.58–83.11)	<b>&lt;0.0001</b>
Cirrhosis	0/135	13/63	NA	<b>&lt;0.0001</b>

<https://doi.org/10.1371/journal.pone.0178473.t002>

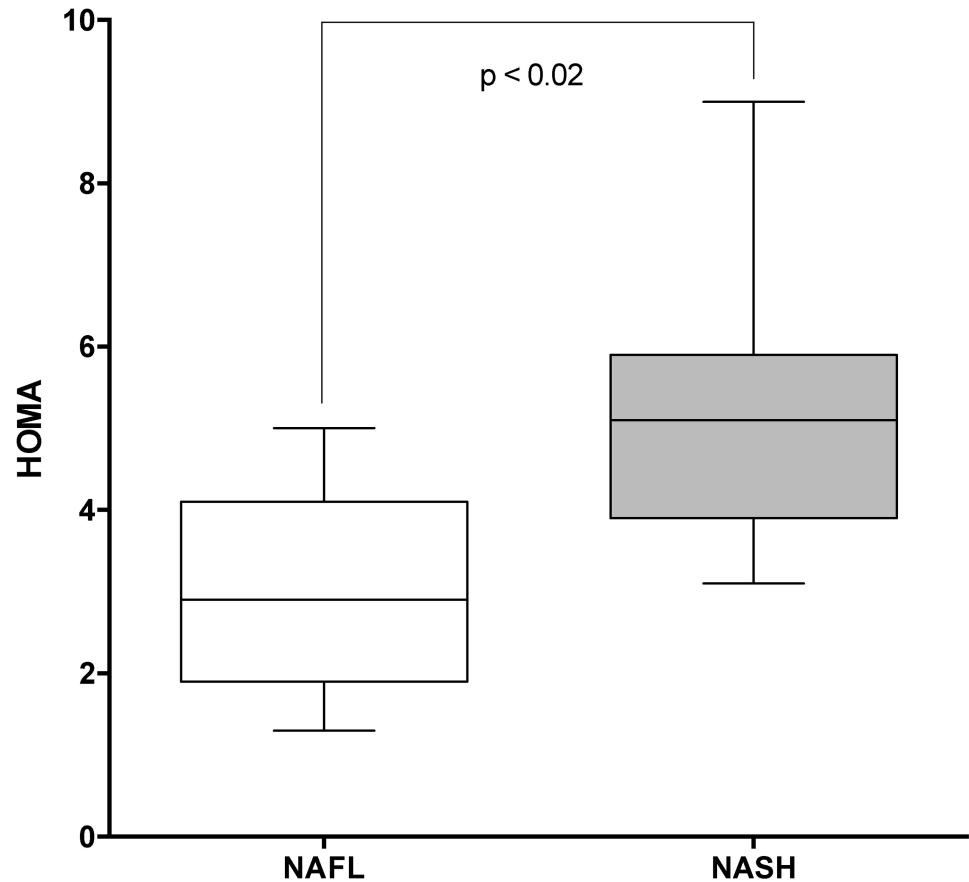


**Fig 2. Distribution of the histological diagnosis on the basis of liver biopsy (NAFL, non-alcoholic fatty liver: Simple steatosis without necroinflammation and fibrosis; NASH: Non-alcoholic steatohepatitis; No NAFLD: No histologic signs of steatosis/steatohepatitis).**

<https://doi.org/10.1371/journal.pone.0178473.g002>

and/or HCC [2, 16, 19]. The presence of liver steatosis is easily diagnosed by ultrasound examination, with high sensitivity and specificity [8,9,26]. However, echography is not a reliable method with which to stage the evolution and the degree of liver fibrosis in steatohepatitis, and liver biopsy remains the gold standard for this purpose [27]. Moreover, ultrasonography often fails to identify steatosis that affects less than 20% of hepatocytes [27]. Consequently, the prevalence of NAFLD in MS and T2DM patients, although very high (above 70% to 80%), was often identified with indirect diagnostic methods that may have underestimated the burden of the problem [12]. Moreover, although liver biopsy is considered an invasive practice, Gaidos et al demonstrated that a histological evaluation of NAFLD patients resulted in a survival benefit. In fact, by applying a statistical modeling system liver biopsy outperformed a no-biopsy approach with respect to both mortality and progression to severe disease in NAFLD [28].

It is important to determine whether MS and T2DM patients are affected by simple steatosis or by steatohepatitis in order to assess their prognosis, both in terms of risk of developing liver cirrhosis and in terms of cardiovascular risk [29–31]. In this context, we performed the present study to diagnose and stage liver steatosis in a cohort of patients with MS and increased ALT levels or T2DM upon diagnosis. A large number of patients consented to liver biopsy, which enabled us to directly evaluate the liver disease at histological level. There is a



**Fig 3. HOMA-IR score in NAFL and NASH patients.** \*The HOMA-IR score in both NAFL and NASH patients exceeded the diagnostic criteria for insulin resistance.

<https://doi.org/10.1371/journal.pone.0178473.g003>

close link between liver steatosis and IR-related metabolic derangements and their complications in both MS and T2DM patients [11,29,30]. The question arises as to whether or not it is possible to predict a progressive chronic pathological mechanism in which, the clinical severity of IR, parallels the clinical severity of liver steatosis.[30] The results reported herein support this concept of liver damage associated to a progressively more severe clinical manifestation of IR. Indeed, we found significantly higher HOMA scores in NASH patients than in patients with simple steatosis (Fig 3). Moreover, the prevalence of NAFLD increased as HOMA levels increased and eventually affected 100% of all T2DM patients, 98% of whom were affected by NASH at histological level. Moreover, 12% of T2DM patients had liver cirrhosis at the

**Table 3. Histological scores [mean±SD] according to Kleiner score in our study population.** (\*NAS: NAFLD activity score).

	MS	DM	p
Steatosis [0–3]	1.6 ± 0.7	2.5 ± 1.3	<0.0001
Lobular Inflammation [0–3]	0.9 ± 0.7	2.3 ± 1.1	<0.0001
Hepatocellular Ballooning [0–2]	1.1 ± 0.2	1.2 ± 1.2	ns
Fibrosis [0–4]	2.0 ± 0.8	3.1 ± 1.1	<0.0001
NAS*	5.6 ± 2.4	10.0 ± 4.7	<0.0001

<https://doi.org/10.1371/journal.pone.0178473.t003>



histological evaluation, which confirms that the clinical severity IR parallels the degree of liver damage.

We are aware that the prevalence of NAFLD and NASH was very high in our MS and T2DM patients. The 60% prevalence of NASH in MS patients may reflect the fact that 94.81% of these patients had a NAFLD. The prevalence of NASH in NAFLD is reported to be about 60% [12]. The vast majority of studies that have investigated this high prevalence, irrespective of the diagnostic method used, assessed the prevalence of the metabolic syndrome and/or diabetes in NAFLD and not the opposite [12]. Notably, NAFLD itself is generally considered a risk factor for MS and also a consequence of it [29]. In this context, we show that even if not all NAFLD patients may have MS, almost all MS patients may have NAFLD. Regarding T2DM, it has also been frequently reported that NAFLD predicts T2DM and that the studies based on liver biopsy reported higher prevalence rates of NAFLD versus laboratory-based or imaging-based studies [12,32,33]. Finally, as mentioned above, our data may be less surprising considering that deranged ALT levels are a not reliable method with which to discriminate between NASH and NAFLD, particularly in diabetic patients [13].

The limitations of this study are its observational and cross-sectional nature. Therefore, we cannot give any insight on the natural history of our patients. Nevertheless, it is noteworthy that almost all the T2DM patients were affected by NASH.

In conclusion, steatohepatitis might be considered the onset of the liver damage in T2DM patients. Thus, it is conceivable that steatosis, in T2DM, is part of a simultaneous process encompassing fat accumulation, chronic inflammation and liver fibrosis that results in liver damage. Given the mounting evidence that NAFLD affects the risk of developing T2DM [29], we can consider that NAFLD, and in particular NASH, are specific clinical signs of T2DM. Routine follow-up with ultrasound examination, and recommending liver biopsy in diabetic patients at the first diagnosis, may be useful tools with which to assess the onset of the disease, to predict overall survival and to evaluate the risk of developing liver cirrhosis, HCC and cardiovascular disease.

## Acknowledgments

We thank Jean Ann Gilder (Scientific Communication srl., Naples, Italy) for editing the article.

We thank Dr. Berardo Guzzi (English Certificate of Proficiency released by University of Cambridge) for his English assistance.

## Author Contributions

**Conceptualization:** MM MP VR FCS.

**Data curation:** MM VR AA RC TB TS FCS MFT MP.

**Formal analysis:** MM VR AA MP.

**Funding acquisition:** MM MP.

**Investigation:** MM VR AA RC MP.

**Methodology:** MM VR TS FCS MFT MP.

**Project administration:** MM MP.

**Resources:** MM MP.

**Software:** MM.



**Supervision:** MP.

**Validation:** MM MP.

**Visualization:** MM VR MP.

**Writing – original draft:** MM MP.

**Writing – review & editing:** MM VR AA RC TB TS FCS MFT MP.

## References

1. Angulo P (2002) Nonalcoholic fatty liver disease. *N Engl J Med* 346: 1221–1231. <https://doi.org/10.1056/NEJMra011775> PMID: 11961152
2. Matteoni CA, Younossi ZM, Gramlich T, Boparai N, Liu YC, et al. (1999) Nonalcoholic fatty liver disease: a spectrum of clinical and pathological severity. *Gastroenterology* 116: 1413–1419. PMID: 10348825
3. Valenti L, Bugianesi E, Pajvani U, Targher G (2016) Nonalcoholic fatty liver disease: cause or consequence of type 2 diabetes? *Liver Int.*
4. Hafizi Abu Bakar M, Kian Kai C, Wan Hassan WN, Sarmidi MR, Yaakob H, et al. (2015) Mitochondrial dysfunction as a central event for mechanisms underlying insulin resistance: the roles of long chain fatty acids. *Diabetes Metab Res Rev* 31: 453–475. <https://doi.org/10.1002/dmrr.2601> PMID: 25139820
5. Marchesini G, Bugianesi E, Forlani G, Cerrelli F, Lenzi M, et al. (2003) Nonalcoholic fatty liver, steatohepatitis, and the metabolic syndrome. *Hepatology* 37: 917–923. <https://doi.org/10.1053/jhep.2003.50161> PMID: 12668987
6. Lonardo A, Loria P (2009) NAFLD and cardiovascular risk: direct evidence for the tale of two ages. *Am J Gastroenterol* 104: 1851–1852. <https://doi.org/10.1038/ajg.2009.233> PMID: 19574981
7. Marchesini G, Brizi M, Morselli-Labate AM, Bianchi G, Bugianesi E, et al. (1999) Association of nonalcoholic fatty liver disease with insulin resistance. *Am J Med* 107: 450–455. PMID: 10569299
8. Yki-Jarvinen H (2016) Diagnosis of non-alcoholic fatty liver disease (NAFLD). *Diabetologia* 59: 1104–1111. <https://doi.org/10.1007/s00125-016-3944-1> PMID: 27091184
9. Williams CD, Stengel J, Asike MI, Torres DM, Shaw J, et al. (2011) Prevalence of nonalcoholic fatty liver disease and nonalcoholic steatohepatitis among a largely middle-aged population utilizing ultrasound and liver biopsy: a prospective study. *Gastroenterology* 140: 124–131. <https://doi.org/10.1053/j.gastro.2010.09.038> PMID: 20858492
10. Williamson RM, Price JF, Glancy S, Perry E, Nee LD, et al. (2011) Prevalence of and risk factors for hepatic steatosis and nonalcoholic Fatty liver disease in people with type 2 diabetes: the Edinburgh Type 2 Diabetes Study. *Diabetes Care* 34: 1139–1144. <https://doi.org/10.2337/dc10-2229> PMID: 21478462
11. Targher G, Bertolini L, Padovani R, Rodella S, Tessari R, et al. (2007) Prevalence of nonalcoholic fatty liver disease and its association with cardiovascular disease among type 2 diabetic patients. *Diabetes Care* 30: 1212–1218. <https://doi.org/10.2337/dc06-2247> PMID: 17277038
12. Younossi ZM, Koenig AB, Abdelatif D, Fazel Y, Henry L, et al. (2016) Global epidemiology of nonalcoholic fatty liver disease—Meta-analytic assessment of prevalence, incidence, and outcomes. *Hepatology* 64: 73–84. <https://doi.org/10.1002/hep.28431> PMID: 26707365
13. Uslusoy HS, Nak SG, Gulten M, Biyikli Z (2009) Non-alcoholic steatohepatitis with normal aminotransferase values. *World J Gastroenterol* 15: 1863–1868. <https://doi.org/10.3748/wjg.15.1863> PMID: 19370784
14. Kleiner DE, Brunt EM, Van Natta M, Behling C, Contos MJ, et al. (2005) Design and validation of a histological scoring system for nonalcoholic fatty liver disease. *Hepatology* 41: 1313–1321. <https://doi.org/10.1002/hep.20701> PMID: 15915461
15. Pocha C, Kolly P, Dufour JF (2015) Nonalcoholic Fatty Liver Disease-Related Hepatocellular Carcinoma: A Problem of Growing Magnitude. *Semin Liver Dis* 35: 304–317. <https://doi.org/10.1055/s-0035-1562949> PMID: 26378646
16. Dyson J, Jaques B, Chattopadyhay D, Lochan R, Graham J, et al. (2014) Hepatocellular cancer: the impact of obesity, type 2 diabetes and a multidisciplinary team. *J Hepatol* 60: 110–117. <https://doi.org/10.1016/j.jhep.2013.08.011> PMID: 23978719
17. Perumpail RB, Wong RJ, Ahmed A, Harrison SA (2015) Hepatocellular Carcinoma in the Setting of Non-cirrhotic Nonalcoholic Fatty Liver Disease and the Metabolic Syndrome: US Experience. *Dig Dis Sci* 60: 3142–3148. <https://doi.org/10.1007/s10620-015-3821-7> PMID: 26250831

18. Yilmaz Y (2012) Review article: is non-alcoholic fatty liver disease a spectrum, or are steatosis and non-alcoholic steatohepatitis distinct conditions? *Aliment Pharmacol Ther* 36: 815–823. <https://doi.org/10.1111/apt.12046> PMID: 22966992
19. Expert Panel on Detection E, Treatment of High Blood Cholesterol in A (2001) Executive Summary of The Third Report of The National Cholesterol Education Program (NCEP) Expert Panel on Detection, Evaluation, And Treatment of High Blood Cholesterol In Adults (Adult Treatment Panel III). *JAMA* 285: 2486–2497. PMID: 11368702
20. American Diabetes A (2015) (2) Classification and diagnosis of diabetes. *Diabetes Care* 38 Suppl: S8–S16.
21. Shashaj B, Luciano R, Contoli B, Morino GS, Spreghini MR, et al. (2016) Reference ranges of HOMA-IR in normal-weight and obese young Caucasians. *Acta Diabetol* 53: 251–260. <https://doi.org/10.1007/s00592-015-0782-4> PMID: 26070771
22. Brunt EM, Janney CG, Di Bisceglie AM, Neuschwander-Tetri BA, Bacon BR (1999) Nonalcoholic steatohepatitis: a proposal for grading and staging the histological lesions. *Am J Gastroenterol* 94: 2467–2474. <https://doi.org/10.1111/j.1572-0241.1999.01377.x> PMID: 10484010
23. Brunt EM, Tiniakos DG (2010) Histopathology of nonalcoholic fatty liver disease. *World J Gastroenterol* 16: 5286–5296. <https://doi.org/10.3748/wjg.v16.i42.5286> PMID: 21072891
24. DeLeve LD (2007) Hepatic microvasculature in liver injury. *Semin Liver Dis* 27: 390–400. <https://doi.org/10.1055/s-2007-991515> PMID: 17979075
25. Tzirogiannis KN, Papadimas GK, Kondyli VG, Kourentzi KT, Demonakou MD, et al. (2006) Peliosis hepatis: microscopic and macroscopic type, time pattern, and correlation with liver cell apoptosis in a model of toxic liver injury. *Dig Dis Sci* 51: 1998–2006. <https://doi.org/10.1007/s10620-006-9242-x> PMID: 17053957
26. Palmentieri B, de Sio I, La Mura V, Masarone M, Vecchione R, et al. (2006) The role of bright liver echo pattern on ultrasound B-mode examination in the diagnosis of liver steatosis. *Dig Liver Dis* 38: 485–489. <https://doi.org/10.1016/j.dld.2006.03.021> PMID: 16716779
27. Bedossa P (2016) Histological Assessment of NAFLD. *Dig Dis Sci* 61: 1348–1355. <https://doi.org/10.1007/s10620-016-4062-0> PMID: 26874689
28. Gaidos JK, Hillner BE, Sanyal AJ (2008) A decision analysis study of the value of a liver biopsy in nonalcoholic steatohepatitis. *Liver Int* 28: 650–658. <https://doi.org/10.1111/j.1478-3231.2008.01693.x> PMID: 18331241
29. Yki-Jarvinen H (2014) Non-alcoholic fatty liver disease as a cause and a consequence of metabolic syndrome. *Lancet Diabetes Endocrinol* 2: 901–910. [https://doi.org/10.1016/S2213-8587\(14\)70032-4](https://doi.org/10.1016/S2213-8587(14)70032-4) PMID: 24731669
30. Anstee QM, Targher G, Day CP (2013) Progression of NAFLD to diabetes mellitus, cardiovascular disease or cirrhosis. *Nat Rev Gastroenterol Hepatol* 10: 330–344. <https://doi.org/10.1038/nrgastro.2013.41> PMID: 23507799
31. Targher G, Byrne CD, Lonardo A, Zoppini G, Barbui C (2016) Nonalcoholic Fatty Liver Disease and Risk of Incident Cardiovascular Disease: A Meta-Analysis of Observational Studies. *J Hepatol*.
32. Bril F, Cusi K (2016) Nonalcoholic Fatty Liver Disease: The New Complication of Type 2 Diabetes Mellitus. *Endocrinol Metab Clin North Am* 45: 765–781. <https://doi.org/10.1016/j.ecl.2016.06.005> PMID: 27823604
33. Lallukka S, Yki-Jarvinen H (2016) Non-alcoholic fatty liver disease and risk of type 2 diabetes. *Best Pract Res Clin Endocrinol Metab* 30: 385–395. <https://doi.org/10.1016/j.beem.2016.06.006> PMID: 27432073