

# Hybrid argon plasma coagulation-assisted endoscopic mucosal resection for large sessile colon polyps to reduce local recurrence: a prospective pilot study



## Authors

Victoria L. Motz<sup>1</sup> , Courtney Lester<sup>2</sup>, Matthew T. Moyer<sup>2</sup>, Jennifer L. Maranki<sup>2</sup>, John M. Levenick<sup>2</sup>

## Institutions

- 1 Department of Medicine, Penn State College of Medicine, Hershey, Pennsylvania, United States
- 2 Division of Gastroenterology and Hepatology, Penn State Health Milton S. Hershey Medical Center, Hershey, Pennsylvania, United States

submitted 23.2.2021

accepted after revision 4.8.2021

published online 14.12.2021

## Bibliography

Endoscopy 2022; 54: 580–584

DOI 10.1055/a-1677-3954

ISSN 0013-726X

© 2021. The Author(s).

This is an open access article published by Thieme under the terms of the Creative Commons Attribution-NonDerivative-NonCommercial License, permitting copying and reproduction so long as the original work is given appropriate credit. Contents may not be used for commercial purposes, or adapted, remixed, transformed or built upon. (<https://creativecommons.org/licenses/by-nc-nd/4.0/>)

Georg Thieme Verlag KG, Rüdigerstraße 14,  
70469 Stuttgart, Germany

## Corresponding author

Victoria L. Motz, DO, Department of Medicine, Penn State Health Milton S. Hershey Medical Center, 500 University Dr, Hershey, PA 17033, United States  
vmotz@pennstatehealth.psu.edu

## ABSTRACT

**Background** Endoscopic mucosal resection (EMR) of large, sessile colon polyps often results in incomplete resection with subsequent recurrence. The aim of this prospective pilot study was to evaluate the efficacy and safety of a novel technique, hybrid argon plasma coagulation-assisted EMR (hAPC-EMR), to remove large, sessile polyps.

**Methods** 40 eligible patients underwent hAPC-EMR for the removal of one or more nonpedunculated colon polyps  $\geq 20$  mm. Participants were contacted 30 days post-procedure to assess for adverse events and were recommended to return for a surveillance colonoscopy at 6 months to assess for local recurrence.

**Results** At the time writing, 32 patients with 35 polyps (median size 27 mm; interquartile range 14.5 mm) resected by hAPC-EMR had undergone the 6-month follow-up colonoscopy. Recurrence rate was 0% (95% confidence interval [CI] 0–0) at follow-up. Post-polypectomy bleeding was experienced by three patients (7.5%; 95%CI 0.00–0.15), and no patients developed post-polypectomy syndrome.

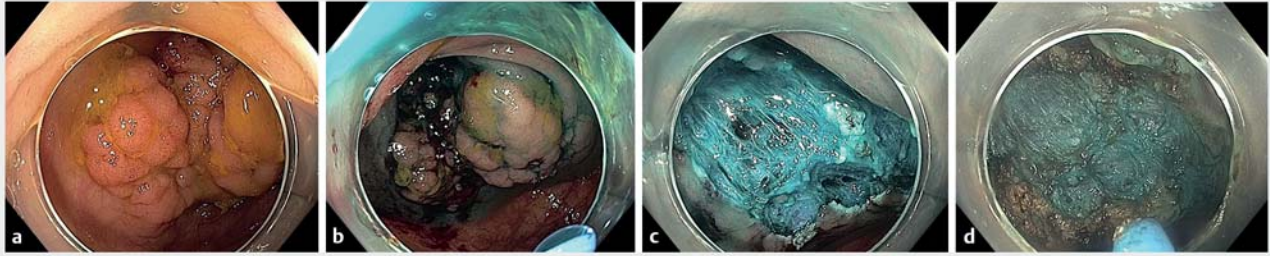
**Conclusion** These preliminary results showed 0% local recurrence rate at 6 months and demonstrated the safety profile of hAPC-EMR. A large, randomized, controlled trial is required to confirm these results.

## Introduction

Endoscopic mucosal resection (EMR) is currently the standard therapy for the removal of large colon polyps. EMR is an endoscopic alternative to surgery and involves expansion of the submucosal space to create a plane for safe resection without injuring the underlying muscle tissue [1]. EMR has been shown to be cost effective, have a rapid recovery time, carry a low risk for adverse events, and achieve successful resection rates upwards of 85% [2–4]. The drawbacks of EMR include a 10%–30% recurrence rate at first surveillance, a 1%–2% perforation rate, and a 5%–10% delayed bleeding rate [3–5].

Although EMR continues to be the standard of care for removal of large laterally spreading lesions, investigations into adjunctive methods aimed at reducing the rates of recurrence and adverse events are crucial. As a result, many thermal ablation techniques have been used to eliminate macroscopic and microscopic disease at the edges of the post-EMR defect; however, their effects on recurrence and safety outcomes remain inconclusive.

A novel technique, hybrid argon plasma coagulation-assisted EMR (hAPC-EMR), utilizes a two-step process to ensure complete eradication of large colon polyps. The technique is derived from hAPC therapy for Barrett's esophagus [6], in



► **Fig. 1** The hybrid argon plasma coagulation-assisted endoscopic mucosal resection (hAPC-EMR) technique for removal of colon polyps. **a** Cecal polyp. **b** Cecal polyp after the first needleless injection prior to EMR. **c** The resection area after EMR and the second needleless injection, and prior to APC of the edges and base. **d** The resected area after hAPC of the edges and base.

which the bed of previously treated areas is reinjected and re-treated. Needleless injection with the hAPC catheter allows for a reliable lift or fluid cushion between the mucosa and muscularis propria in the submucosa, and avoids any extramural injection that can hinder resection [7, 8]. Following complete resection of the colon polyp, the submucosa undergoes repeat needleless injection, followed by APC of both the edges and base of the defect.

No prospective studies published to date have evaluated the efficacy and safety of hAPC-EMR as the initial resection technique for removal of large colon polyps. We hypothesize that the microscopic remnant disease that leads to high rates of recurrence after EMR may actually lie at the base of the lesion as well as at its edges, and that treating both the base and edges of the defect with hAPC will reduce recurrence. In the present report, we describe a prospective, single-center pilot study aimed at assessing the recurrence rate and safety of this novel hAPC-EMR technique.

## Methods

### Study design

This was a prospective, single-center, pilot study assessing the recurrence rate and safety of hAPC-EMR for the removal of large sessile colonic polyps. The study was approved by the Penn State College of Medicine/Penn State Health Institutional Review Board. All authors had access to the raw study data, and reviewed and approved the final manuscript.

### Patients and lesions

Patients were considered eligible for inclusion in the study if they met the following criteria: age >18 to <89 years, with at least one large ( $\geq 20$  mm) nonpedunculated polyp, and ability to provide informed consent. Patients were excluded from the study if they had any of the following: biopsy-proven invasive carcinoma, pedunculated polyps (Paris classification type Ip or Isp), ulcerated depressed lesions (Paris classification type III), lesions meeting Narrow-band imaging (NBI) International Colorectal Endoscopic (NICE) classification type 3 criteria, inflammatory bowel disease, poor general health (American Society of Anesthesiologists class >3), coagulopathy (international nor-

malized ratio >1.5 or platelets <10), poor bowel preparation, target sign or perforation during initial EMR, need for endoscopic submucosal dissection or complete resection prior to APC, or patients who were pregnant and/or breastfeeding.

Consent and basic demographic details were obtained by the principal investigator or research coordinator in the preprocedure area prior to bringing the patient to the endoscopy room. Patients were informed that the colonoscopy procedure would take place even if they chose not to participate in the voluntary research study.

### Procedure

All study colonoscopies were performed by two experienced therapeutic endoscopists using Olympus 190 high definition colonoscopes with digital chromoendoscopy capability (Olympus, Tokyo, Japan). Before the endoscopy procedure, patients underwent a standard split-dose bowel preparation. During the procedure, each polyp was identified using conventional colonoscopic views, and polyp characteristics were recorded in the electronic endoscopy recording system. White-light imaging and NBI with near focus were used to evaluate the morphology of each polyp according to the Paris classification [9] and to assess for submucosal invasion based on NICE classification criteria [10].

After identification and evaluation of the polyp for inclusion in the study (► **Fig. 1a**), each eligible polyp underwent needleless injection in order to lift the polyp away from the muscularis propria (► **Fig. 1b**). The injectate was either a colloid mixture (half sodium chloride 0.9% + half hetastarch) or sodium chloride 0.9% alone, according to endoscopist preference. Polyps were resected using an electrocautery snare until complete resection was achieved (► **Fig. 1c**). Following complete resection, the submucosal defect was visualized with white light and NBI before being reinjected with the same injectate solution to allow the base to be lifted. The polypectomy base and peripheral edges were then thermally ablated using hAPC with a flow of 0.8 L/min and 40 watts (► **Fig. 1d**).

All polyp tissue was retrieved for histopathological evaluation. The resection base was closed using endoscopic clips according to the endoscopist's usual practice; however, by the end of the trial, only polyps in the cecum and ascending colon

were closed based on evidence from the CLIP randomized controlled trial (RCT) [11]. Patients were monitored continuously throughout the procedure, as is standard of care during any routine colonoscopy, and monitored for any adverse events in the recovery room prior to discharge.

### Standardized surveillance protocol

At 30 days following the initial resection, the research coordinator telephoned each patient to assess for any signs of post-procedural adverse events such as post-polypectomy bleeding (PPB) and post-polypectomy syndrome (PPS). Approximately 6 months after the initial resection, patients underwent a surveillance colonoscopy. The site of the previous resection was identified using the polypectomy scar or previous tattoo, and targeted biopsy was performed. All biopsy specimens were sent for histopathological evaluation to confirm the absence of microscopic recurrent disease at follow-up.

### Study end points

The primary end point of the study was the local recurrence rate at the 6-month surveillance colonoscopy. Secondary study end points included rates of PPS and PPB. PPS was defined as colonic wall injury from electrocoagulation that induced a transmural burn and localized peritoneal inflammation without radiographic imaging evidence of perforation [12]. Patients with PPS were identified by presentation of fever, leukocytosis, and/or abdominal pain within 1 week of colonoscopy. PPB was recorded as either immediate or delayed bleeding. Delayed PPB was defined as bleeding occurring within hours to 30 days post-procedure. Patients with delayed PPB presented with signs or symptoms of hematochezia, acute blood loss anemia, hemodynamic instability, and/or end-organ damage [13].

### Statistical analysis

Statistical analysis was performed using SAS software version 9.4 (SAS Institute Inc., Cary, North Carolina, USA). Descriptive statistics were calculated for patient demographic details and polyp characteristics. Recurrence at 6 months and adverse events were described using frequencies.

Study data were collected and managed using Research Electronic Data Capture (REDCap) electronic data capture tools hosted at the Penn State Health Milton S. Hershey Medical Center and College of Medicine [14, 15]. REDCap is a secure, web-based software platform designed to support data capture for research studies.

## Results

### Patient demographics and polyp characteristics

A total of 40 patients with 44 eligible polyps were included in the study. Enrolled patients were mostly male (62.5%) with a mean age of 64.6 (SD 7.8) years. Included polyps had a median size of 27 mm (interquartile range 14.5 mm) and were located in the ascending colon (cecum to the hepatic flexure; 65.9%), the transverse colon (to the splenic flexure; 22.7%), and the descending colon (11.4%). The majority of patients (82.5%) had endoscopic clips placed following hAPC treatment. Patho-

► **Table 1** Patient characteristics.

	n = 40
Sex, n (%)	
▪ Female	15 (37.5)
▪ Male	25 (62.5)
Age, mean (SD) [range]	64.6 (7.8) [50.0–78.0]
BMI, mean (SD) [range] <sup>1</sup>	31.2 (6.9) [21.0–48.0]
Race, n (%)	
▪ Black or African American	4 (10.0)
▪ White	36 (90.0)
Ethnicity, n (%)	
▪ Hispanic or Latino	0
▪ Not Hispanic or Latino	40 (100)
ASA class, n (%)	
▪ I	1 (2.5)
▪ II	18 (45.0)
▪ III	21 (52.5)
Comorbid conditions, n (%) <sup>2</sup>	
▪ Hypertension	33 (82.5)
▪ Coronary artery disease	13 (32.5)
▪ Stroke or TIA	2 (5.0)
▪ COPD	6 (15.0)
▪ Diabetes mellitus	13 (32.5)
▪ Chronic kidney disease	6 (15.0)
▪ Other	15 (37.5)
▪ No comorbid conditions	3 (7.5)
Received endoscopic clipping, n (%)	
▪ Yes	33 (82.5)
▪ No	7 (17.5)

BMI, body mass index; ASA, American Society of Anesthesiologists; TIA, transient ischemic attack; COPD, chronic obstructive pulmonary disease; DM, diabetes mellitus.

<sup>1</sup> BMI available for 37 patients.

<sup>2</sup> Comorbid conditions are not mutually exclusive.

logical analysis of the 44 polyps showed tubular adenomas (68.2%) or sessile serrated polyps (22.7%). Additional patient demographic details and polyp characteristics are shown in ► **Table 1** and ► **Table 2**, respectively.

### Primary outcome

At the time of writing, 32 patients (80%) with 35 treated study polyps (79.5%) completed the 6-month follow-up colonoscopy. Three patients were lost to follow-up, one patient withdrew for personal reasons, and four patients were still waiting for their colonoscopies to be rescheduled due to the COVID-19 pandemic. At follow-up, all 35 prior resection sites could be identi-

► **Table 2** Polyp characteristics.

	n = 44
Size, mean (SD) [range], mm	35.2 (12.6) [20.0–75.0]
Location, n (%)	
▪ Cecum to hepatic flexure	29 (65.9)
▪ Transverse colon to splenic flexure	10 (22.7)
▪ Descending colon to rectum	5 (11.4)
Paris classification, n (%)	29 (65.9)
▪ Is or Is + Ila or Is + Ilc	14 (31.8)
▪ Ila or Ila + Ilc or Ila + Ilb	26 (59.1)
▪ Ilb	3 (6.8)
▪ Ilc	1 (2.3)
Surface, n (%)	
▪ Granular	28 (63.6)
▪ Nongranular	2 (4.6)
▪ Mixed	11 (25.0)
▪ Serrated appearance	3 (6.8)
Adequacy of lift, n (%)	
▪ Complete	31 (70.4)
▪ Partial	11 (25.0)
▪ None	2 (4.6)
Pathology, n (%)	
▪ Tubular adenoma	30 (68.2)
▪ Sessile serrated lesion	10 (22.7)
▪ Tubular adenoma with high grade dysplasia	2 (4.5)
▪ Tubulovillous adenoma	2 (4.5)

fied using standard colonoscopic views, and none showed evidence of visible or biopsy-proven recurrence.

### Secondary outcome

Delayed PPB following the initial resection was experienced by three patients (7.5%; 95%CI 0.00–0.15). Each case required hospital admission for at least 1 day. One patient underwent an additional endoscopy with endoscopic clipping of a transverse colon ulcer, and one patient underwent colonoscopy with hemostatic spray for a bleeding vessel. No patients required blood transfusion and no patients experienced PPS.

### Discussion

EMR is the established gold standard for removal of large laterally spreading lesions >20mm. The associated complication rate is relatively low, and previous studies have shown that EMR results in reduced rates of mortality, morbidity, and costs

compared with surgical resection [5,16,17]. However, EMR alone has a high recurrence rate of up to 30% at 6 months, which is its main limitation. Routine surveillance has been shown to be effective at treating recurrence, although it is very burdensome for patients, increases morbidity rates, and was not found to be cost effective in previous reports [3,18]. In the present study, adherence to the surveillance colonoscopy at 6 months was low due to scheduling issues surrounding the SARS-CoV-2 outbreak. Therefore, based on decreased follow-up rates alone, it is becoming increasingly important to augment EMR to improve efficacy and reduce recurrence so that routine surveillance is required less frequently.

This prospective, single-arm, data-collection study assessing recurrence 6 months following hAPC-EMR resulted in a 0% local recurrence rate. Our study serves as a proof-of-concept pilot study suggesting that hAPC-EMR appears to offer a reduction in lesion recurrence rates when compared with conventional EMR technique, which has been used over the past 10 years. Secondary end points assessing PPB and PPS following hAPC-EMR revealed incidences of 7.5% and 0%, respectively, which are similar to rates seen with standard EMR [19]. While these results are attractive and suggest a reduction in recurrence using this technique, a larger RCT comparing hAPC-EMR with other ablative strategies, such as snare tip soft coagulation, will be required before definitive conclusions can be drawn.

We believe that the promising results shown with this technique are largely due to the needleless injection and hAPC application. Needleless injection allows for lifting of both the initial lesion and the post-polypectomy site without extramural injection. The second lift may be the critical step because it allows for safe ablation of the microscopic tissues thought to be the precursor of recurrent disease by preventing thermal injury from reaching the muscularis propria. Both the needleless injection and second lift offer added protection to the muscularis propria tissues and may help to reduce rates of PPB and PPS, as was suggested by our data. In addition, we believe that application of hAPC to both the base and edges of the post-polypectomy site may contribute to the reduced rate of recurrence seen in this study. Although there are increased costs associated with hAPC therapy, we believe that preventing recurrence is key in continuing to increase the value of EMR; doing so prevents additional endoscopy and further limits the need for endoscopic submucosal dissection and surgery.

### Limitations

The present study has several notable limitations. The small sample size and nonrandomized, noncontrolled design limit our ability to draw major conclusions from the results. The protocol was written with the intention of being a pilot study, hence the small sample size. However, the pandemic further decreased the sample size of our primary analysis due to participant withdrawal. In addition, this study was conducted at a single endoscopy center by only two skilled endoscopists. A more robust, multicenter, RCT is needed before more definitive conclusions can be drawn.

## Conclusion

In conclusion, this pilot study provides evidence to suggest that hAPC-EMR is safe and may result in improved recurrence rates compared with EMR alone. However, further investigation of hAPC-EMR, including larger RCTs, is recommended before definitive conclusions can be drawn.

## Acknowledgments

The REDCap tools used in this project are supported by The Penn State Clinical & Translational Research Institute, Pennsylvania State University CTSA, NIH/NCATS Grant Number UL1 TR002014.

## Funding

ClinicalTrials.gov (<http://www.clinicaltrials.gov/>) | Prospective, single-center, pilot study | NCT03390907

## Competing interests

The authors declare that they have no conflict of interest.

## References

- [1] Buchner AM, Guarner-Argente C, Ginsberg GG. Outcomes of EMR of defiant colorectal lesions directed to an endoscopy referral center. *Gastrointest Endosc* 2012; 76: 255–263
- [2] Jayanna M, Burgess NG, Singh R et al. Cost analysis of endoscopic mucosal resection vs surgery for large laterally spreading colorectal lesions. *Clin Gastroenterol Hepatol* 2016; 14: 271–278
- [3] Moss A, Bourke MJ, Williams SJ et al. Endoscopic mucosal resection outcomes and prediction of submucosal cancer from advanced colonic mucosal neoplasia. *Gastroenterology* 2011; 140: 1909–1918
- [4] Arezzo A, Passera R, Marchese N et al. Systematic review and meta-analysis of endoscopic submucosal dissection vs endoscopic mucosal resection for colorectal lesions. *United European Gastroenterol J* 2016; 4: 18–29
- [5] Klein A, Tate DJ, Jayasekeran V et al. Thermal ablation of mucosal defect margins reduces adenoma recurrence after colonic endoscopic mucosal resection. *Gastroenterology* 2019; 156: 604–613
- [6] Manner H, May A, Kouti I et al. Efficacy and safety of hybrid-APC for the ablation of Barrett's esophagus. *Surg Endosc* 2016; 30: 1364–70
- [7] Brooker JC, Saunders BP, Shah SG et al. Treatment with argon plasma coagulation reduces recurrence after piecemeal resection of large sessile colonic polyps: a randomized trial and recommendations. *Gastrointest Endosc* 2002; 55: 371–375
- [8] Watson JP, Bennett MK, Griffin SM et al. The tissue effect of argon plasma coagulation on esophageal and gastric mucosa. *Gastrointest Endosc* 2000; 52: 342–345
- [9] Rastogi A, Keighley J, Singh V et al. High accuracy of narrow band imaging without magnification for the real-time characterization of polyp histology and its comparison with high-definition white light colonoscopy: a prospective study. *Am J Gastroenterol* 2009; 104: 2422–2430
- [10] Hattori S, Iwatate M, Sano W et al. Narrow-band imaging observation of colorectal lesions using NICE classification to avoid discarding significant lesions. *World J Gastroenterol* 2014; 6: 600–605
- [11] Pohl H, Grimm IS, Moyer MT et al. Clip closure prevents bleeding after endoscopic resection of large colon polyps in a randomized trial. *Gastroenterology* 2019; 157: 977–984
- [12] Jehangir A, Bennett KM, Rettew AC et al. Post-polypectomy electrocoagulation syndrome: a rare cause of acute abdominal pain. *J Community Hosp Intern Med Perspect* 2015; 5: 29147
- [13] Reumkens A, Rondagh EJ, Bakker CM et al. Post-colonoscopy complications: a systematic review, time trends, and meta-analysis of population-based studies. *Am J Gastroenterol* 2016; 111: 1092–1101
- [14] Harris PA, Taylor R, Minor BL et al. The REDCap consortium: building an international community of software platform partners. *J Biomed Inform* 2019; 95: 103208
- [15] Harris PA, Thielke R, Payne J et al. Research electronic data capture (REDCap)—a metadata-driven methodology and workflow process for providing translational research informatics support. *J Biomed Inform* 2009; 42: 377–381
- [16] Knabe M, Pohl J, Gerges C et al. Standardized long-term follow-up after endoscopic resection of large, nonpedunculated colorectal lesions: a prospective two-center study. *Am J Gastroenterol* 2014; 109: 183–189
- [17] Belderbos TD, Leenders M, Moons LM et al. Local recurrence after endoscopic mucosal resection of nonpedunculated colorectal lesions: systematic review and meta-analysis. *Endoscopy* 2014; 46: 388–402
- [18] Ahlenstiel G, Hourigan LF, Brown G et al. Actual endoscopic versus predicted surgical mortality for treatment of advanced mucosal neoplasia of the colon. *Gastrointest Endosc* 2014; 80: 668–676
- [19] Burgess NG, Bassan MS, McLeod D et al. Deep mural injury and perforation after colonic endoscopic mucosal resection: a new classification and analysis of risk factors. *Gut* 2017; 66: 1779–1789