

Distraction Osteogenesis Technique for the Treatment of Nonsyndromic Sagittal Synostosis

Dana Johns, MD*

Ross Blagg, MD*

John R. W. Kestle, MD†

Jay K. Riva-Cambrin, MD,
MSc†

Faizi Siddiqi, MD*

Barbu Gociman, MD, PhD*

Background: Historically, surgical treatment of children with a delayed presentation of cranial synostosis required complex cranial vault reconstruction. Recently, less invasive options for surgical correction, such as internal distraction osteogenesis, have been explored. In this study, we describe the successful management of delayed presentation of sagittal synostosis using distraction osteogenesis.

Methods: A bicoronal incision was made and 2 large rectangular osteotomies were performed bilaterally, involving the frontal, parietal, temporal and occipital bones. A 2 cm strut of bone over the sagittal sinus was preserved, creating bilateral free-floating bone segments. Two pairs of distractors were placed transversely, along the midline strut of bone, providing lateral distraction of these segments. This placement allowed maximum displacement at the apex of the cranial vault. Distraction was performed differentially at 1 mm per day anteriorly and 2 mm per day posteriorly, for a total of 17 days, allowing for a greater degree of expansion of the posterior vault. The consolidation phase lasted for 10 weeks. The distractors were removed via the same bicoronal incision and cranioplasty was performed to smooth prominent ridging at the margins of the distracted segments.

Results: The child's cranial index improved from 0.67 preoperatively to 0.76 postoperatively. The overall vault contour was smooth with no bony defects. There was a significant cosmetic improvement of the child's head shape. No major complications requiring reoperation or rehospitalization were encountered.

Conclusion: The use of distraction osteogenesis to laterally expand the cranial vault is a useful alternative in the treatment of delayed presentation, nonsyndromic, sagittal synostosis. (*Plast Reconstr Surg Glob Open* 2015;3:e474; doi: 10.1097/GOX.0000000000000442; Published online 24 July 2015.)

Sagittal synostosis is the most common form of isolated, nonsyndromic craniosynostosis, accounting for more than half of all the craniosyn-

ostosis cases.¹⁻³ Traditionally, sagittal craniosynostosis has been surgically managed by open cranial vault reconstruction. More recently, endoscopic-assisted strip craniectomy with postoperative helmet molding has been used effectively in children younger than 6 months old.⁴⁻⁶ The surgical treatment of delayed presentation of sagittal synostosis has largely been limited to open vault reconstruction. Although excellent cosmetic outcomes and resolution of intracranial hypertension are obtained, there are drawbacks including long operative times, high volume blood loss, and a high incidence of persistent postoperative cranial vault bony defects.⁷⁻¹⁰

From the *Department of Plastic Surgery, University of Utah Health Sciences Center, Salt Lake City, Utah; and †Department of Neurosurgery, University of Utah Health Sciences Center, Salt Lake City, Utah.

Received for publication March 26, 2015; accepted June 9, 2015.

Copyright © 2015 The Authors. Published by Wolters Kluwer Health, Inc. on behalf of The American Society of Plastic Surgeons. All rights reserved. This is an open-access article distributed under the terms of the Creative Commons Attribution-NonCommercial-NoDerivatives 3.0 License, where it is permissible to download and share the work provided it is properly cited. The work cannot be changed in any way or used commercially.

DOI: 10.1097/GOX.0000000000000442

Disclosure: The authors have no financial interest to declare in relation to the content of this article. The Article Processing Charge was paid for by the authors.

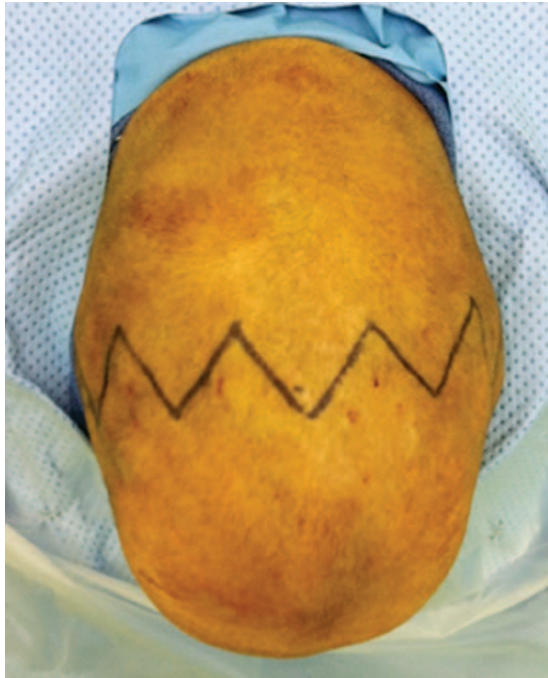

Fig. 1. Preoperative findings. Cephalic view photograph displaying severe scaphocephaly.

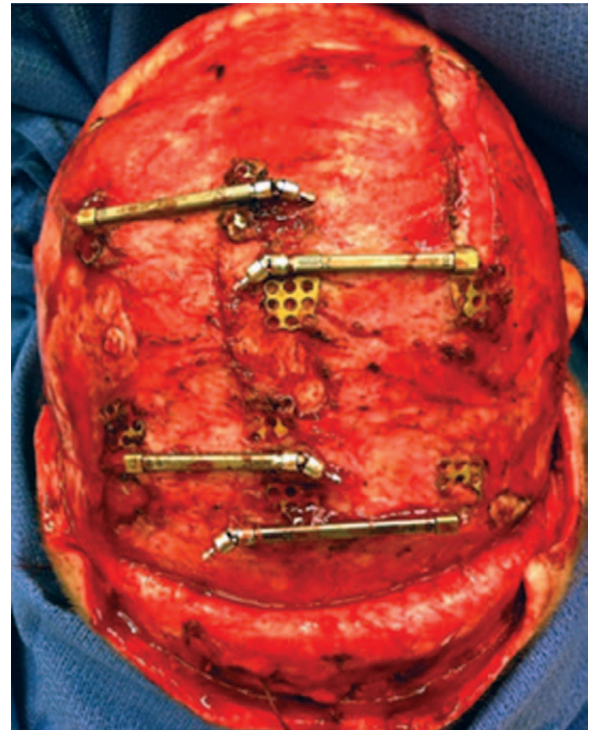


Fig. 3. Postdistraction findings. Removal of distractors.

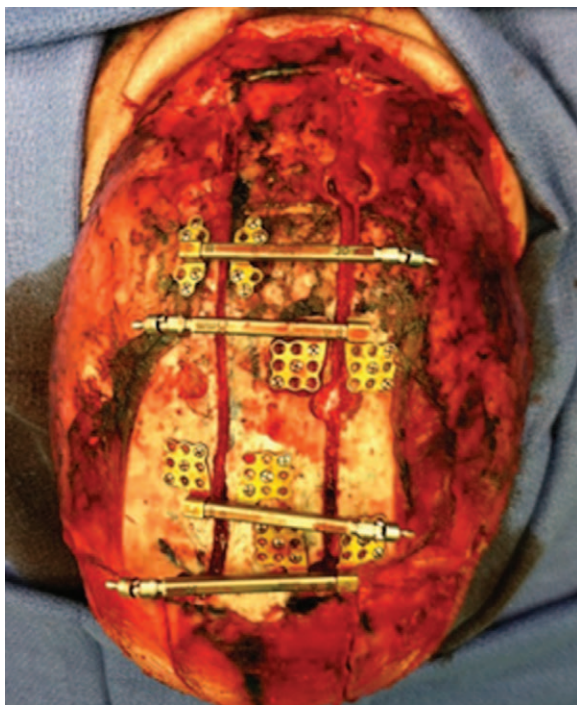

Fig. 2. Distraction osteogenesis technique. Placement of distractors.

To avoid the morbidities associated with open vault reconstruction, surgical correction using internal distraction osteogenesis has been explored. The majority of previous studies evaluated the effectiveness of distraction osteogenesis in the setting of multiple suture synostosis.¹¹⁻¹⁷ Limited information

has been published concerning the use of distraction osteogenesis for the treatment of isolated sagittal synostosis.^{18,19}

In this report, we describe the successful management of delayed presentation of sagittal synostosis using our distraction osteogenesis technique. The technique was designed so that the anterior and posterior vault expansion can be individualized to specific patient needs to obtain a normal head shape.

METHODS

The patient was positioned prone with the neck extended. The cranial vault was approached through a bicoronal incision (Fig. 1). Bilateral rectangular craniotomies were performed (Fig. 2). These involved the parietal, temporal, and occipital bones on each side and extended to the coronal suture anteriorly and the lambdoid suture posteriorly. A 2 cm strut of bone over the sagittal sinus, connecting the frontal to the occipital areas, was preserved. In situ barrel stave osteotomies were performed in the frontal, temporal, and occipital regions. Two pairs of linear internal distractors were placed transversely (Fig. 2). Distractor extension arms were attached and exteriorized through stab incisions. The scalp flaps were reapproximated and incision was closed.

To achieve a greater degree of expansion of the posterior vault, distraction was performed differentially at 0.5 mm per day anteriorly and 1 mm per day

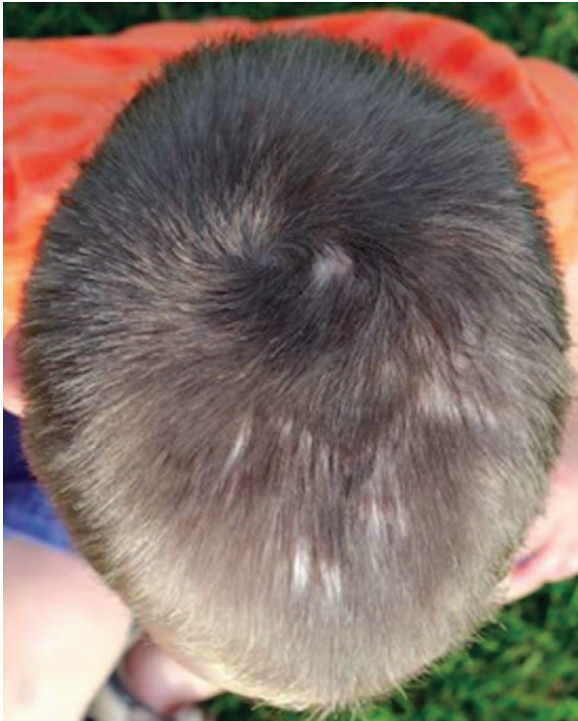

Fig. 4. One-year follow-up cephalic view photograph displaying excellent correction of the scaphocephaly.

posteriorly. The activation was done for a total of 17 days, with an endpoint of satisfactory cranial vault contour on physical examination. After 10 weeks of consolidation, clinical ossification at the level of the distracted areas was obtained and the distractors were removed (Fig. 3). Concomitantly, with the removal of the distractors, a contouring cranioplasty was performed to smooth the prominent step-offs generated by the distraction process.

RESULTS

A 20-month-old boy presented to Primary Children's Hospital in Salt Lake City, Utah, for evaluation of abnormal head shape. Severe scaphocephaly with frontal bossing was noted on physical examination (Fig. 1). No significant clinical evidence of increased intracranial pressure was apparent. A computed tomographic (CT) imaging study was performed, which confirmed the diagnosis of isolated sagittal synostosis. The preoperative cranial index measured on CT axial images was 0.67.

There were no intraoperative or postoperative complications. Estimated blood loss was 200 mL. No transfusions were required. The patient was admitted postoperatively and discharged home on day 4. The patient was seen in clinic weekly until the activation was completed and had excellent head shape on physical examination. Objectively, on x-ray imaging, the cranial index improved to 0.8. The patient was

subsequently seen in clinic monthly. After 1 month of consolidation, there were no palpable bony defects.

A 1-year follow-up CT scan was performed. Small areas lacking ossification were seen bilaterally at the sites of distraction. The physical examination showed continued excellent head shape (Fig. 4). No bony defects were appreciated on palpation. The measured cranial index remained stable at 0.8.

DISCUSSION

Delayed presentation of craniosynostosis has traditionally been managed with complex cranial vault reconstruction. This carries with it long operating room times, high-volume blood losses, extended postoperative hospital stays, and persistent large bony defects (as the closure of cranial bony defects after vault surgery is significantly decreased after 12 months of age²⁰).

Since calvarial distraction for craniosynostosis was first described by Sugawara et al¹³ in 1998, it has been gaining popularity for treatment of syndromic and multiple suture synostosis.^{11,12,14–17} Few studies have addressed its usefulness in the management of patients with single-suture synostosis.^{18,19} Techniques employing distraction osteogenesis have shown several advantages over vault reconstruction. These include decreased operative time, decreased blood loss,^{17,19} and association with smaller persistent bony defects.

The goals of the surgical correction for patients with scaphocephaly are to treat or prevent the development of increased intracranial pressure and to improve head shape. To recreate a normal skull shape, posterior cranial expansion must be greater than anterior cranial expansion. To achieve this, separate anterior and posterior cranial distractors were placed to control the differential lateral expansion. The inferior cranium was expanded via circumferential multiple barrel staves.

Three previous studies used cranial vault distraction in the setting of scaphocephaly. Lao and Denny¹⁸ used a single distractor placed posteriorly with a hinge plate placed anteriorly to completely restrict the lateral expansion of the anterior vault. Sakamoto et al¹⁹ introduced the "morcellation craniotomy" technique using 2 distractors in parallel at the level of the posterior vault, with passive remodeling of anterior vault osteotomies. A third technique, by Sugawara et al,¹⁴ involved creation of multiple craniotomies of the entire superior vault. Multidirectional expansion was achieved using individual distractors attached to each craniotomy segment. Of note, none of these techniques provided any significant lateral expansion of the inferior cranium.

The technique described in the current report is unique as it is relatively simple, quick, and allows differential lateral expansion of the entire superior cranium as well as lateral expansion of the inferior cranium to provide excellent aesthetic head reshaping.

CONCLUSION

The use of distraction osteogenesis to laterally expand the anterior and posterior cranial vault at different rates has a very good cosmetic outcome and represents a viable alternative in the treatment of delayed presentation of sagittal synostosis.

Dana Johns, MD

Department of Plastic Surgery
University of Utah Health Sciences Center
30 North 1900 East, 3B400, Salt Lake City, UT 84132
E-mail: dana.johns@hsc.utah.edu

REFERENCES

1. Anderson FM, Geiger L. Craniosynostosis: a survey of 204 cases. *J Neurosurg*. 1965;22:229–240.
2. Hunter AG, Rudd NL. Craniosynostosis. I. Sagittal synostosis: its genetics and associated clinical findings in 214 patients who lacked involvement of the coronal suture(s). *Teratology* 1976;14:185–193.
3. Shillito J Jr, Matson DD. Craniosynostosis: a review of 519 surgical patients. *Pediatrics* 1968;41:829–853.
4. Berry-Candelario J, Ridgway EB, Grondin RT, et al. Endoscope-assisted strip craniectomy and postoperative helmet therapy for treatment of craniosynostosis. *Neurosurg Focus* 2011;31:E5.
5. Gociman B, Agko M, Blagg R, et al. Endoscopic-assisted correction of metopic synostosis. *J Craniofac Surg*. 2013;24:763–768.
6. Gociman B, Marengo J, Ying J, et al. Minimally invasive strip craniectomy for sagittal synostosis. *J Craniofac Surg*. 2012;23:825–828.
7. Pensler JM, Ciletti SJ, Tomita T. Late correction of sagittal synostosis in children. *Plast Reconstr Surg*. 1996;97:1362–1367; discussion 1368–1370.
8. Rottgers SA, Kim PD, Kumar AR, et al. Cranial vault remodeling for sagittal craniosynostosis in older children. *Neurosurg Focus* 2011;31:E3.
9. Smyth MD, Tenenbaum MJ, Kaufman CB, et al. The “clamshell” craniotomy technique in treating sagittal craniosynostosis in older children. *J Neurosurg*. 2006;105 (4 Suppl):245–251.
10. Weinzeig J, Baker SB, Whitaker LA, et al. Delayed cranial vault reconstruction for sagittal synostosis in older children: an algorithm for tailoring the reconstructive approach to the craniofacial deformity. *Plast Reconstr Surg*. 2002;110:397–408.
11. Marchac A, Arnaud E. Cranium and midface distraction osteogenesis: current practices, controversies, and future applications. *J Craniofac Surg*. 2012;23:235–238.
12. Sargent LA, Griner D. Use of osteogenesis distractors in cloverleaf skull reconstruction. *Ann Plast Surg*. 2013;70:546–548.
13. Sugawara Y, Hirabayashi S, Sakurai A, et al. Gradual cranial vault expansion for the treatment of craniofacial synostosis: a preliminary report. *Ann Plast Surg*. 1998;40:554–565.
14. Sugawara Y, Uda H, Sarukawa S, et al. Multidirectional cranial distraction osteogenesis for the treatment of craniosynostosis. *Plast Reconstr Surg*. 2010;126:1691–1698.
15. Taylor JA, Tahiri Y, Paliga JT, et al. A new approach for the treatment of unilateral coronal synostosis based on distraction osteogenesis. *Plast Reconstr Surg*. 2014;134:176e–178e.
16. Wiberg A, Magdum S, Richards PG, et al. Posterior calvarial distraction in craniosynostosis—an evolving technique. *J Craniomaxillofac Surg*. 2012;40:799–806.
17. Yamaguchi K, Imai K, Fujimoto T, et al. Cranial distraction osteogenesis for syndromic craniosynostosis: long-term follow-up and effect on postoperative cranial growth. *J Plast Reconstr Aesthet Surg*. 2014;67:e35–e41.
18. Lao WW, Denny AD. Internal distraction osteogenesis to correct symptomatic cephalocranial disproportion. *Plast Reconstr Surg*. 2010;126:1677–1688.
19. Sakamoto Y, Nakajima H, Tamada I. Outcome analysis of morcellation craniotomy with distraction osteogenesis for scaphocephaly. *Pediatr Neurosurg*. 2013;49:248–253.
20. Paige KT, Vega SJ, Kelly CP, et al. Age-dependent closure of bony defects after frontal orbital advancement. *Plast Reconstr Surg*. 2006;118:977–984.