

New insights into erythropoietin and erythropoietin receptor in laryngeal cancer tissue

Jelena Vukelic, MD, PhD^a, Renata Dobrila-Dintinjana, MD, PhD^b, Blazen Marijic, MD^a, Diana Marzic, MD^c, Tamara Braut, MD, PhD^{a,*}, Marko Velepik, MD, PhD^a

Abstract

To investigate whether laryngeal cancer cells express erythropoietin (Epo) and erythropoietin receptor (EpoR) and what is their possible relationship with clinical and pathological features of the tumor.

We performed immunohistochemical analysis of Epo and EpoR expression on 78 tissue samples of invasive and in situ squamous cell laryngeal carcinoma.

The statistical analysis showed a weak positive and statistically significant correlation of EpoHS and EpoR HS expression levels. Epo HS and EpoR HS levels did not correlate with patient sex or age, type of diagnosis, cancer stage, histological tumor grade, presence or absence of disease recurrence, type of oncologic cancer therapy provided, or results of selected laboratory blood work. The results show a statistically significant difference in Epo expression with respect to survival.

We confirmed the presence of Epo and EpoR in malignant laryngeal tumors and demonstrated the correlation between Epo expression and survival. Further studies are needed to more precisely define the role of Epo and EpoR in treatment of patients with laryngeal cancer.

Abbreviations: DAB = diaminobenzidine, Epo = erythropoietin, Epo HS = erythropoietin histoscore, EpoR = erythropoietin receptor, EpoR HS = erythropoietin receptor histoscore, HE = hematoxylin and eosin, Hgb = hemoglobin, HS = histoscore, Ht = hematocrit, MCHC = mean corpuscular hemoglobin concentration, rHuEpo = recombinant human erythropoietin, TNM = tumor-nodus-metastasis.

Keywords: erythropoietin, erythropoietin receptor, head and neck cancer, laryngeal cancer, malignancy

1. Introduction

Erythropoietin (Epo) is a glycoprotein hormone responsible for erythropoiesis.^[1] The effects of Epo to promote growth, prevent apoptosis and induce differentiation are achieved by its binding to the erythropoietin receptor (EpoR) expressed on the surface of erythroid precursor cells. EpoR is essential for erythropoietin-dependent growth and survival of erythroid precursors, from the

blast colony-forming cell stage to the mature erythroid cell.^[2] Epo secretion is primarily regulated by the oxygen levels in the blood. Hypoxia is the main stimulus for Epo secretion. The principal targets of Epo are erythroid precursors in the bone marrow. Epo was once thought to act exclusively on erythroid precursor cells. However, recent studies have refuted the theory and demonstrated Epo to be a pleiotropic hormone that via EpoR may also exert its effect in non-hematopoietic tissues, endothelial cells, epicardium and pericardium, kidney, pancreas, placenta, and certain brain regions.^[3,4]

Malignant tumors of the larynx are the most common and leading death-causing malignancy of the head and neck region.^[5,6] Adequate treatment of malignant laryngeal tumors requires identification of the histological type of cancer and spread of the disease according to the tumor-nodus-metastasis (TNM) classification system. Decision about the type of cancer treatment is made by health professionals, including otorhinolaryngologist, radiologist, cytologist, pathologist, oncologist, and logopedist. Experience shows that information about the tumor size, presence of both regional lymph node and distant metastases, and histological type of the tumor is often insufficient for a conclusion of the course of the disease, tumor aggressiveness, and recurrence.

The aim of our study was to investigate whether laryngeal cancer cells express Epo and EpoR and what is their possible relationship with clinical and pathological features of the tumor.

2. Materials and methods

2.1. Materials

We performed a retrospective study on 78 tissue samples from patients with laryngeal cancer who underwent surgery and

Editor: Chao Mao.

This work was supported by the project of University of Rijeka, Croatia (grant number: uniri-biomed-18-121).

The authors declare that they have no conflicts of interest to the publication of this article.

The datasets generated during and/or analyzed during the current study are available from the corresponding author on reasonable request.

^aDepartment for Otolaryngology and Head and Neck surgery, ^bDepartment for radiotherapy and oncology, ^cCenter for audiology and phoniatry, Clinical Hospital Center Rijeka, Kresimirova 42, Rijeka, Croatia.

* Correspondence: Tamara Braut, Clinic for Otolaryngology and Head and Neck surgery, Clinical Hospital Center Rijeka, Kresimirova 42, Rijeka 51000, Croatia (e-mail: tamara_braut@hotmail.com).

Copyright © 2021 the Author(s). Published by Wolters Kluwer Health, Inc. This is an open access article distributed under the terms of the Creative Commons Attribution-Non Commercial-No Derivatives License 4.0 (CCBY-NC-ND), where it is permissible to download and share the work provided it is properly cited. The work cannot be changed in any way or used commercially without permission from the journal.

How to cite this article: Vukelic J, Dobrila-Dintinjana R, Marijic B, Marzic D, Braut T, Velepik M. New insights into erythropoietin and erythropoietin receptor in laryngeal cancer tissue. *Medicine* 2021;100:3(e23943).

Received: 20 March 2020 / Received in final form: 22 October 2020 / Accepted: 30 November 2020

<http://dx.doi.org/10.1097/MD.00000000000023943>

postoperative therapy at the Rijeka University Hospital Center Departments: Department of Otorhinolaryngology and Head and Neck Surgery and Department of Radiotherapy and Oncology, respectively. The study included patients diagnosed with squamous cell carcinoma of the larynx. According to the diagnosis the patients were divided into 2 groups. Group 1 consisted of 68 (87.2%) patients with laryngeal cancer, and group 2 of 10 (12.8%) patients with the diagnosis of laryngeal cancer with metastases to the regional lymph nodes. The patients' age at diagnosis ranged from 45 to 81 years, with the median of 60 years. All the patients underwent surgical treatment. A partial laryngectomy was performed in 36 patients, and 42 received a total laryngectomy. A total of 55 patients required further oncology treatment; radiotherapy was administered to 47 and chemoradiotherapy to 8 patients. Patients were further divided according to the stage of their disease. There were 36 (46.2%) and 42 (53.8%) patients with early-stage (stages 1 and 2) and advanced-stage (stages 3 and 4) disease, respectively. As regards histological grade, the patients were divided into 4 groups. Patients with grade 2 tumor accounted for the largest share (51.3%), followed by patients with grade 1 (23.1%), then those with grade 3 (14.1%), while patients with grade 0 tumor accounted for the smallest share (11.5%). For all patients information on local recurrence, metastases to the regional lymph nodes and occurrence of a second primary tumor was collected from the medical records. Local recurrence occurred in 8 (10.2%) patients, regional lymph node metastases in 9 (11.5%), and a second primary tumor was identified in 7 (9.0%) patients. Information on erythrocyte count, hemoglobin (Hgb), hematocrit (Ht) and mean corpuscular hemoglobin concentration (MCHC) was selected from laboratory tests done on the day of surgery. After surgical treatment, the patients were followed up for 5 years. The total number of patients alive after 5 years of follow up was 50 (64.1%). Given that this is a bench research, there was no need to establish a control group. In the study, we observed the 4 basic ethical principles (personal integrity-autonomy, beneficence, nonmaleficence, justice), and also the ones that are deduced from them (privacy, trust). The study was conducted in accordance with the Nuremberg Code, the most recent revision of the Declaration of Helsinki and other relevant documents. Bioethical standards for medical information collection were met, and the privacy (medical confidentiality) of study patients and their data confidentiality protection ensured.

3. Methods

Tissue samples of invasive and in situ squamous cell carcinoma were immunohistochemically processed. Histopathological analysis was performed using light microscopy. All the specimens were fixed in 10% buffered formalin (Kemika, Zagreb, Croatia), embedded into paraffin blocks and stained with hematoxylin and eosin (HE). To validate the reliability of immunohistochemical staining slides with kidney tissue normally expressing Epo and EpoR were used as a positive control. The specimens were also determined for the degree of histologic differentiation according to the World Health Organization grading scheme.

3.1. Immunohistochemical analysis

Representative tissue samples of laryngeal carcinoma were selected to make a paraffin block further cut into 4 to 5 μm thick sections. Overnight, sections were kept in a thermostat at

37°C, then deparaffinized using the standard procedure with a xylene substitute (Clear Sakura) ($3 \times 10'$), and rehydrated in absolute ethyl alcohol ($2 \times 5'$), 96% ethyl alcohol ($5'$), 70% ethyl alcohol ($5'$) until washed with distilled water. The samples were treated using the EnVision method-based visualization system. The visualization system (Dako Real EnVision Detection System Peroxidase/DAB+, Rabbit/Mouse K5007) was used with an automated immunostainer (Dako Autostainer Plus). Diaminobenzidine (DAB) was employed as chromogen, and the following primary antibodies: Epo (H-162):sc-7956, EpoR (H-194):sc-5624 were applied. After implementation of the visualization system, the sections were counterstained with hematoxylin for 1 minute, washed with tepid water, dehydrated in ethyl alcohol of different concentration (70%, 96%, and 100%), and then rinsed in a xylene substitute. Finally, coverslips were mounted in GLC Mounting Medium. Washes between each step were performed using Dako Wash Buffer 10x \times S 3006.

3.2. Evaluation of immunohistochemical staining

The evaluation of immunohistochemical staining for Epo and EpoR on the tumor cell surface was performed in a semiquantitative manner according to results already published in the medical literature.^[7] Cytoplasmic and membranous staining was assessed by 2 independent pathologists N.J. and A.D. We used histoscore (HS) that takes into consideration the intensity of the staining and the percentage of positive cells, by applying the formula $HS = 1 \times (\% \text{ light staining}) + 2 \times (\% \text{ moderate staining}) + 3 \times (\% \text{ strong staining})$. This HS ranges from 0 to 300. The intensity of staining for Epo and EpoR antibodies is shown in Figures 1 and 2, respectively.

3.3. Ethical statement

The study was conducted in accordance with the Nuremberg Code, the most recent revision of the Declaration of Helsinki and other relevant documents. Bioethical standards for medical information collection were met, and the privacy (medical confidentiality) of study patients and their data confidentiality protection ensured. The Local Ethics Committee approval has been obtained.

3.4. Statistical analysis

Statistical analysis of the collected data was performed using Statistica software package (Version 10.0, StatSoft Inc. Tulsa, OK, USA). Appropriate statistical tests were employed to analyze the collected data, with a statistical significance level of $P < .05$ to form a conclusion.

4. Results

The expression of Epo and EpoR was assessed in a semiquantitative manner evaluating immunohistochemical staining (evaluation of the staining intensity and percentage of stained tumor cells). The final result for expression was determined as the product of multiplication of the percentage and the intensity, labeled as an erythropoietin histoscore (Epo HS) and erythropoietin receptor histoscore (EpoR HS) that may reach levels within the interval of 0-300.

Epo HS and EpoR HS levels were not normally distributed (Kolmogorov-Smirnov test, Epo HS $P < .050$, EpoR HS

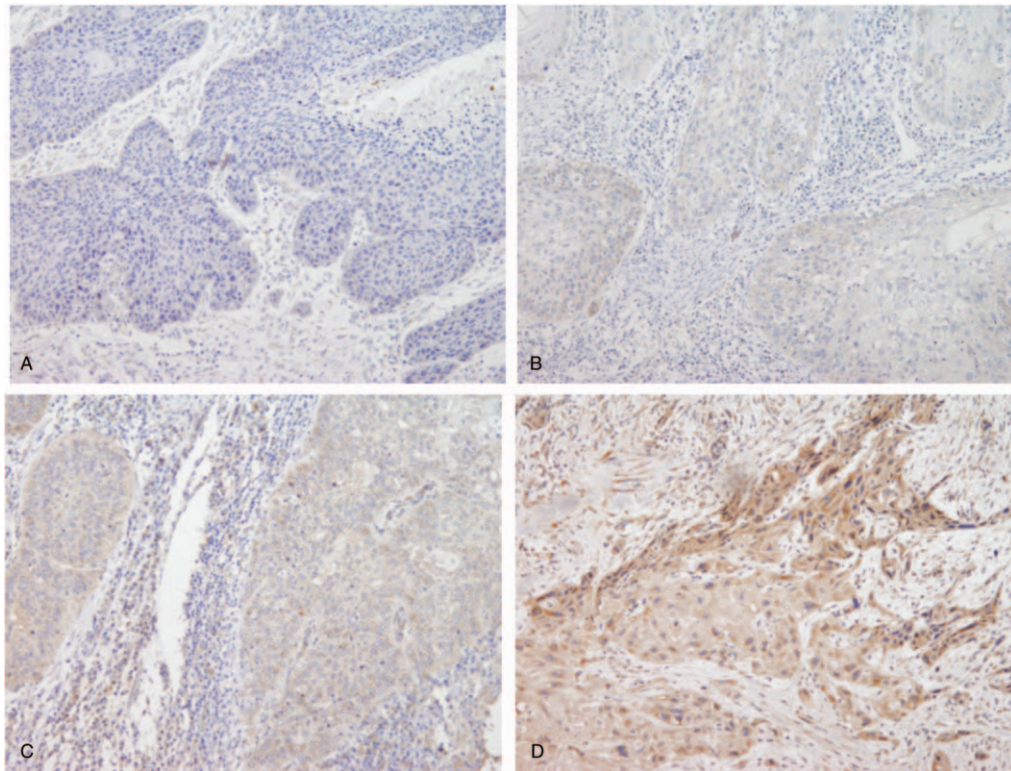


Figure 1. Immunohistochemical Epo expression in squamous laryngeal cancer cells. A- negative staining, B- light positive staining, C- moderate positive staining, D- strong positive, cytoplasmic staining, magnification x4.

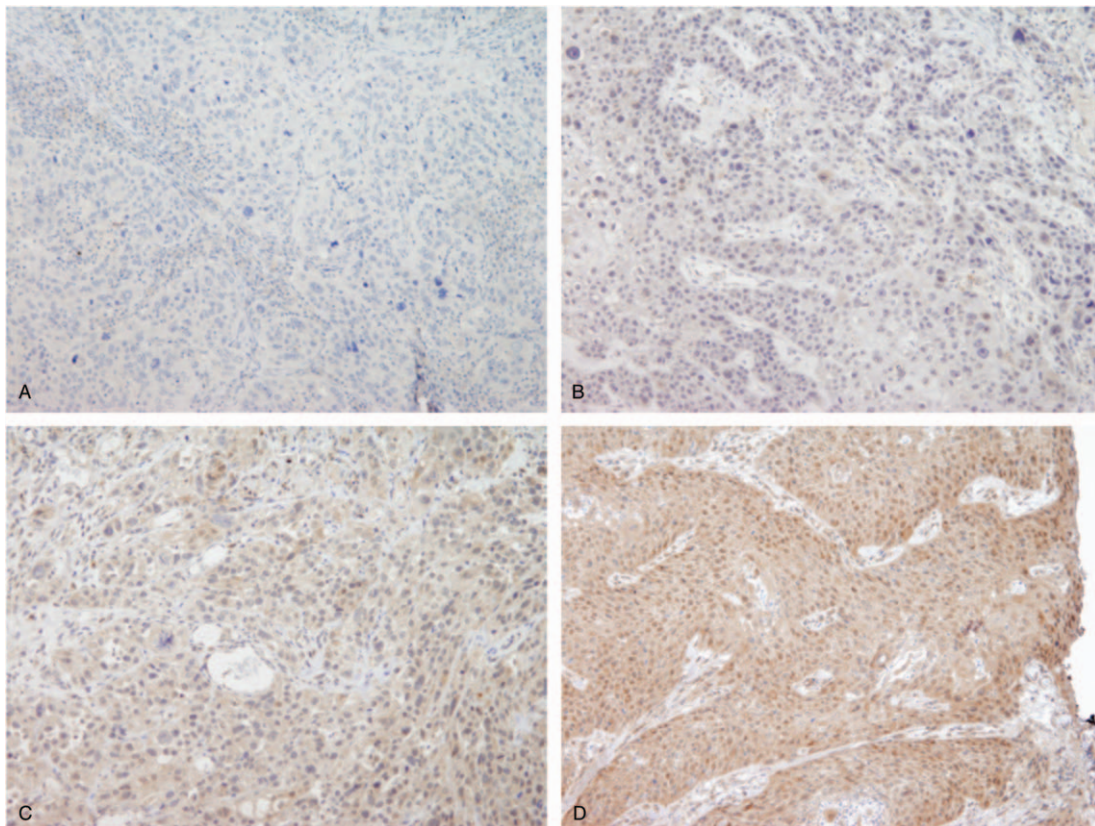


Figure 2. Immunohistochemical EpoR expression in squamous laryngeal cancer cells. A- negative staining, B- light positive staining, C- moderate positive staining, D- strong positive, cytoplasmic staining, magnification x4.

Table 1
Epo HS and EpoR HS levels in patient samples.

	Median	q25-q75	Range
Epo HS	52.5	36.7–100.0	0–200
EpoR HS	48.4	31.7–100.0	0–300

$P < .010$). The result is shown in Table 1. The statistical analysis showed a weak positive and statistically significant correlation (Pearson correlation coefficient $r = 0.26$, $P = .022$) of EpoHS and EpoR HS expression levels (Fig. 3). Epo HS and EpoR HS levels did not differ either in respect of patient sex (Mann–Whitney U test, Epo HS: $Z = 0.63$, $P = .530$; EpoR HS $Z = 1.48$, $P = .139$) or diagnosis (Mann–Whitney U test, Epo HS: $Z = 0.63$, $P = .530$; EpoR HS $Z = 1.27$, $P = .204$). There was also no correlation between these levels and patient age (Spearman correlation coefficient, Epo HS $r = -0.13$; EpoR HS $r = -0.07$, $P > .05$). Likewise, there was no difference shown for cancer stage (Mann–Whitney U test, Epo HS: $Z = 0.07$, $P = .948$; EpoR HS $Z = 1.23$, $P = .218$). Furthermore, differences were not observed between the levels of Epo HS and EpoR HS in respect to histological tumor grade (Kruskal–Wallis ANOVA, Epo HS $H = 5.76$, $P = .124$; EpoR HS $H = 2.30$, $P = .513$). Epo HS and EpoR HS levels did not differ in patients either in regard to the presence or absence of disease recurrence (Mann–Whitney U test, Epo HS: $Z = -1.78$, $P = .075$; EpoR HS $Z = -1.06$, $P = .298$), or in regard to the type of disease recurrence including local recurrence, metastasis in regional lymph nodes, and occurrence of second primary tumor (Kruskal–Wallis ANOVA, Epo HS $H = 3.85$, $P = .289$; EpoR HS $H = 5.19$, $P = .158$). With respect to the type of cancer therapy provided (radiotherapy, radiotherapy/chemotherapy, not provided), the levels of Epo HS and EpoR HS did not show a statistically significant difference (Kruskal–Wallis ANOVA,

Table 2
Epo and EpoR expression in relation to treatment outcome.

	Outcome		<i>P</i>
	Survived	Deceased	
Epo HS	67.7 ± 38.5	49.9 ± 38.1	.046
EpoR HS	67.0 ± 58.7	64.4 ± 55.8	.338

Epo HS $H = 1.75$, $P = .416$; EpoR HS $H = 0.125$, $P = .939$). Laboratory blood work (erythrocytes, Hgb, Htc, and MCHC) did not detect any correlation with Epo and EpoR expression (in all regression analyses the Spearman correlation coefficient was $r < 0.15$, showing the absence of correlation). Analysis of a potential correlation between Epo and EpoR expression and treatment outcome produced results as shown in Table 2. The results show a statistically significant difference in Epo expression with respect to treatment outcome (Mann–Whitney U test, $Z = 1.995$, $P = .046$). Figure 4 is showing comparison of Epo HS levels with respect to treatment outcome. EpoR expression levels do not reveal any significant difference in regard to treatment outcome. Treatment outcome in respect of Epo HS was further investigated using logistic regression analysis showing that the model is statistically significant, that is, that Epo HS is a significant predictor of treatment outcome (model score $F2 = 3.99$, $P = .046$). The logistic regression curve is given in Figure 5. Based on the logistic regression results, ROC analysis to obtain the criterion value for Epo HS (the cut-off value of Epo HS parameter for discriminating between the groups with respect to an increased mortality risk) was also performed. The result is shown in Figure 6. The result of ROC analysis has shown that Epo HS is a significant predictor of fatal outcome ($AUC = 0.637$, $P = .039$), with the criterion value for Epo HS being 148 (cut-off point).

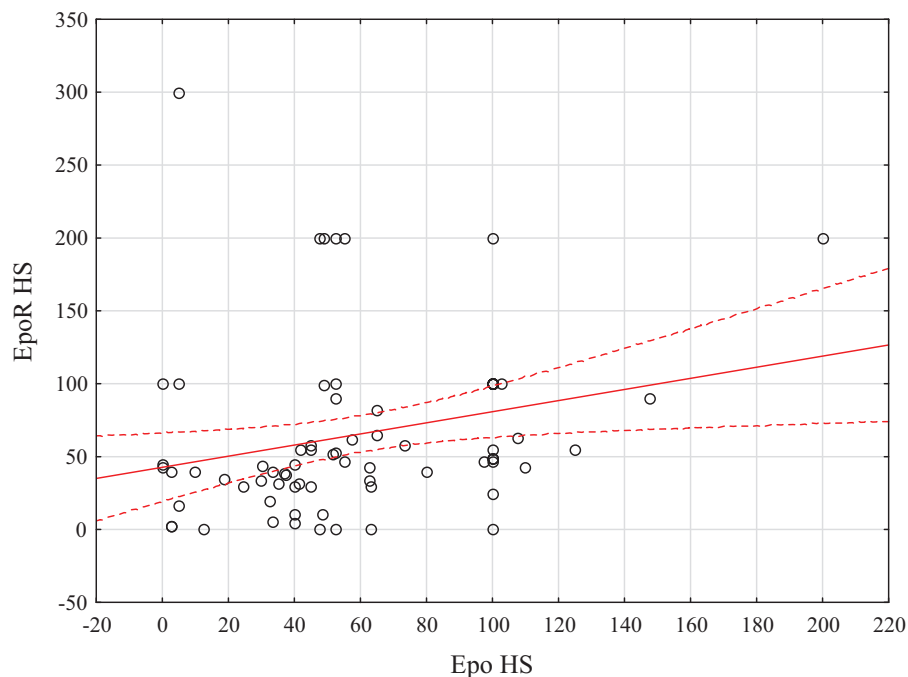


Figure 3. Correlation diagram for variables of Epo HS and EpoR HS. The regression line and its 95% confidence interval are constructed.

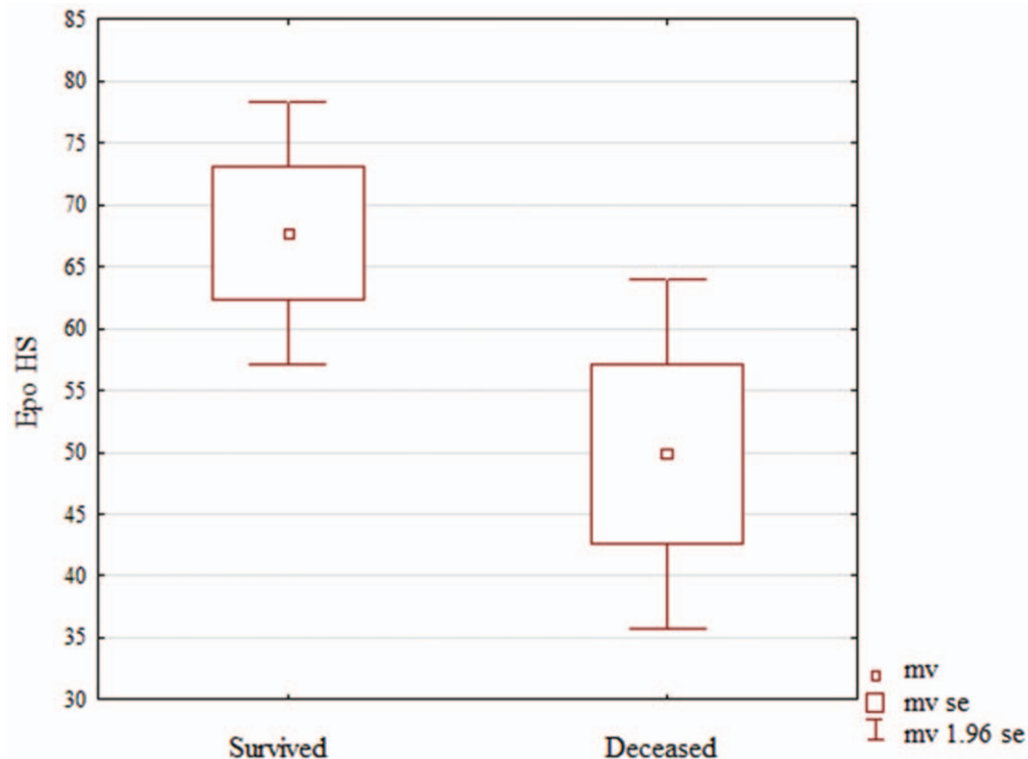


Figure 4. Comparison of Epo HS levels with respect to treatment outcome.

5. Discussion

Hypoxia is the main stimulus for the production of erythropoietin, which exerts its effects via the erythropoietin receptor. Epo was once thought to act exclusively on erythroid precursor cells and reported to play a role in promoting growth, inhibiting

apoptosis, and inducing erythroid differentiation. Further studies have provided evidence of the Epo and EpoR presence in tumor cells, and also recognized other roles they play. The majority of studies investigated the role of recombinant human erythropoietin (rHuEpo) considering that the correction of anemia was used

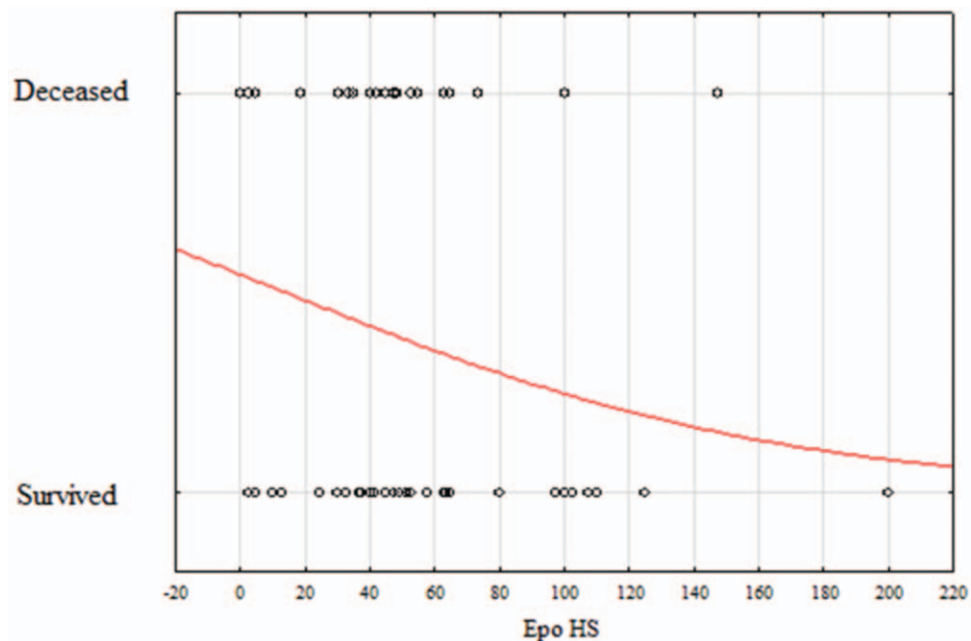


Figure 5. Logistic regression curve for the predictive value of Epo HS as outcome parameter.

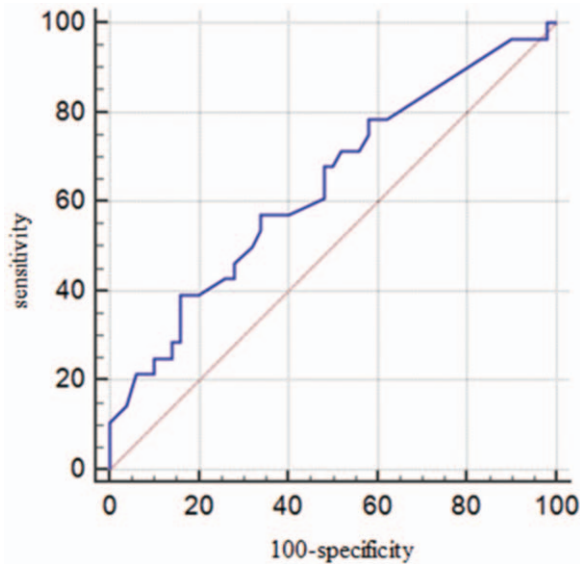


Figure 6. ROC curve for determining the predictive value of Epo HS for treatment outcome.

in an attempt to improve the clinical course and treatment outcomes. Only a small number of studies addressed the effects that endogenous Epo exerts through EpoR in tumor cells. It has been shown that the secretion of Epo, either endogenous or hypoxia-induced, may affect tumor angiogenesis and disease progression.^[8] The study by Lin et al pointed out that a high expression of EpoR is significantly correlated with advanced TNM stage which is represented with the rapid proliferation of tumor cells. Such condition may outpace the blood and nutrition supply. It is supposed that this leads to tumor necrosis and hypoxia in the microenvironment of tumor and may result into the higher level of EpoR.^[9]

Tumor hypoxia affects malignant progression and alters the response to administered therapies. Zuo et al provided evidence that hypoxia promotes laryngeal cancer cell invasion and migration.^[10] Xu et al demonstrated that hypoxia in laryngeal squamous cell carcinoma could induce cell apoptosis decreased and enhance chemotherapeutic resistance.^[11]

In order to elicit effects on the target cell, Epo must bind to EpoR upon which a series of signaling pathways become activated. Our study demonstrated the expression of both Epo and EpoR in cell lines of malignant neoplasm of the larynx, and also showed a weak positive and significant correlation of Epo HS and EpoR HS expression levels. Elliott et al substantiated EpoR expression not to be Epo-dependent by demonstrating increased EpoR expression in spite of the absence of Epo expression on erythroid precursors.^[3] In contrast, Arcasoy et al reported both Epo and EpoR expression in the majority of squamous cell tumors of the head and neck, but failed to provide a correlation between their expression.^[12] The study of Winter et al showed high expression of erythropoietin and its receptor and their positive correlation in patients with head and neck tumors.^[13] Our results fit with the findings of Arcasoy and Winter, so a conclusion may be drawn that Epo expression in laryngeal tumors correlates with the expression of EpoR and that laryngeal cancer cells behave in the same manner as other head and neck tumor cell lines.

Our study did not demonstrate any correlation of Epo HS or EpoR HS expression with respect to tumor stage, histological grade, proliferation factor, occurrence or absence of disease recurrence, administered cancer therapy, and anemia. A detailed literature search revealed scarce information on the above issues. Mohyeldin et al showed statistical significance of the correlation between tumor progression and Epo and EpoR immunohistochemical staining while Winter et al provided evidence that the expression of Epo and EpoR is not correlated with either survival or disease-free survival.^[13,14] The result was unexpected since erythropoietin, as a hypoxia marker, was long thought to be a predictor of outcome in head and neck tumor patients. The authors are of the opinion that such results are due to the discrepancy in half-lives between Epo and hypoxia-inducible factor 1 α (HIF-1 α); that is, the half-life of Epo is measured in hours while the half-life of HIF-1 α is measured in minutes and Epo is therefore assumed not to be suitable as an indicator of hypoxia, and as such, it cannot be useful as a predictor of treatment outcome.^[13]

Seibold et al investigated the prognostic significance of Epo and EpoR expression in patients with advanced head and neck carcinoma; improved locoregional disease control and significantly longer metastasis-free survival were reported in patients showing no Epo expression. Survival was the only factor that correlated with Epo and EpoR, and was reported to be significantly longer in patients with no expression of Epo or EpoR.^[15]

The study of Henke et al demonstrated a negative effect of epoetin beta administration in patients who were positive for EpoR expression. This group of patients had significantly higher rates of locoregional progression and shorter survival in relation to patients in whom EpoR expression was not observed.^[16]

In their study, Lai et al showed that Epo affects cell invasion and disease progression in patients with squamous cell carcinoma of the head and neck. They estimate the expression of Epo to be related with morbidity and mortality of head and neck tumor patients as it promotes tumor progression that eventually leads to local invasion and spread of cancer to vital structures such as the trachea and the carotid artery. In addition, the study demonstrated increased expression of Epo and EpoR in metastases to lymph nodes in the neck leading to the assumption that Epo/EpoR signaling may be a factor that plays a role in disease progression and metastasis occurrence.^[17]

Our study did not show any correlation between Epo/EpoR expression and anemia. In their study, Arcasoy et al also demonstrated no correlation between the expression of hemoglobin or hematocrit and Epo/EpoR.^[12]

The results of our study revealed a statistically significant difference of Epo HS expression with respect to treatment outcome. Higher expression of Epo HS was found to be related to longer survival, while its lower expression levels correlated with death outcome. This new insight into the behavior of laryngeal carcinoma reveals a different tumor behavior in relation to current knowledge. As already mentioned, increased Epo expression is related to tumor progression, reduced locoregional control of the disease and occurrence of metastasis. As regards the relationship of Epo expression and treatment outcome, a group of authors provided evidence that Epo cannot be used as a predictor of treatment outcome, which is in contrast to findings of another group of authors who demonstrated the correlation between survival and Epo and EpoR, and showed significantly longer survival in patients not expressing Epo or EpoR.^[13,15,18]

Our results are not in accordance with former findings, and taking into consideration that none of the previous studies included laryngeal tumor cells we may assume that their biology differs from the biology of other tumor cells. Further studies are needed to confirm or refute our results as they may have clinical consequences. In fact, the confirmation of our results (correlation of Epo HS exclusively to treatment outcome, without correlation between Epo and any other factor that might influence the course of the disease) would imply less aggressive therapy in patients with high Epo levels.

In our study, the expression of EpoR HS was not correlated with treatment outcome. This lead us to the conclusion that malignant laryngeal cells express both Epo and EpoR, yet EpoR may not be functional causing Epo not to produce expected effects as in other tumor cell lines. Additional studies are required to confirm our suspicion about the EpoR's lack of functionality and the resultant incapacity of Epo to exert its effects so we may take a definite stand on the efficacy and benefits of routine Epo and EpoR testing in patients with malignant neoplasms of the larynx.

6. Conclusion

Despite a range of diagnostic procedures available, precise diagnosis and then prediction of the course of malignant laryngeal disease remain a great challenge. Present protocols based on the TNM system and histological classification of these tumors are insufficient which shows a need for figuring out additional factors which would enable more precise staging and an individualized approach to treat patients with malignant neoplasms of the larynx.

The aim of our study was to investigate the significance of erythropoietin and the erythropoietin receptor in malignant laryngeal tissue as novel markers that could predict course of disease. The results confirmed the presence of Epo and EpoR in malignant laryngeal tumors and demonstrated the correlation between Epo expression and survival.

We are aware of limitations of our study as it is done as basic scientific research. Despite that we believe that this new insights about expression of Epo and EpoR and its connection with the pathological characteristics of cancer (histological grade) and with clinical features (laboratory findings, disease recurrence, or overall survival) could serve as starting point for further observational case-control studies that will more precisely define the role of of Epo and EpoR in diagnostic and treatment protocols of patients with laryngeal cancer.

Author contributions

Conceptualization: Jelena Vukelic, Blazen Marijic, Tamara Braut, Marko Velepuc.

Data curation: Jelena Vukelic, Blazen Marijic, Diana Marzic.

Formal analysis: Blazen Marijic, Diana Marzic.

Funding acquisition: Tamara Braut.

Methodology: Renata Dobrila-Dintinjana.

Project administration: Tamara Braut.

Supervision: Renata Dobrila-Dintinjana, Tamara Braut, Marko Velepuc.

Validation: Renata Dobrila-Dintinjana.

Writing – original draft: Jelena Vukelic.

Writing – review & editing: Jelena Vukelic, Tamara Braut.

References

- [1] Zhang Y, Wang L, Dey S, et al. Erythropoietin action in stress response, tissue maintenance and metabolism. *Int J Mol Sci* 2014;15:10296–333.
- [2] Dzierzak E, Philipsen S. Erythropoiesis: development and differentiation. *Cold Spring Harb Perspect Med* 2013;3:a011601.
- [3] Elliott S, Sinclair AM. The effect of erythropoietin on normal and neoplastic cells. *Biologics* 2012;6:163–89.
- [4] Lombardero M, Kovacs K, Scheithauer BW. Erythropoietin: a hormone with multiple functions. *Pathobiology* 2011;78:41–53.
- [5] Croatian National Cancer Registry. Cancer incidence in Croatia 2015. Bilten br. 40 Zagreb. Available at: https://www.hzjz.hr/wp-content/uploads/2018/03/Bilten_2015_rak_final.pdf. Accessed March 14, 2019
- [6] Siegel RL, Miller KD, Jemal A. Cancer statistics, 2017. *CA Cancer J Clin* 2017;67:7–30.
- [7] La Ferla K, Reimann C, Jelkmann W, et al. Inhibition of erythropoietin gene expression signaling involves the transcription factors GATA-2 and NF-kappaB. *FASEB J* 2002;16:1811–3.
- [8] Kimáková P, Solár P, Solárová Z, et al. Erythropoietin and its angiogenic activity. *Int J Mol Sci* 2017;18:1519.
- [9] Lin YT, Chuang HC, Chen CH, et al. Clinical significance of erythropoietin receptor expression in oral squamous cell carcinoma. *BMC Cancer* 2012;12:194.
- [10] Zuo J, Wen J, Lei M, et al. Hypoxia promotes the invasion and metastasis of laryngeal cancer cells via EMT. *Med Oncol* 2016;33:15.
- [11] Xu O, Li X, Wang J, et al. The impact of hypoxia improvement on laryngeal squamous cell carcinoma chemotherapy. *Lin Chung Er Bi Yan Hou Tou Jing Wai Ke Za Zhi* 2015;29:824–7.
- [12] Arcasoy MO, Amin K, Chou SC, et al. Erythropoietin and erythropoietin receptor expression in head and neck cancer: relationship to tumor hypoxia. *Clin Cancer Res* 2005;11:20–7.
- [13] Winter SC, Shah KA, Campo L, et al. Relation of erythropoietin and erythropoietin receptor expression to hypoxia and anemia in head and neck squamous cell carcinoma. *Clin Cancer Res* 2005;11:7614–20.
- [14] Mohyeldin A, Lu H, Dalgard C, et al. Erythropoietin signaling promotes invasiveness of human head and neck squamous cell carcinoma. *Neoplasia* 2005;7:537–43.
- [15] Seibold ND, Schild SE, Gebhard MP, et al. Prognosis of patients with locally advanced squamous cell carcinoma of the head and neck. Impact of tumor cell expression of EPO and EPO-R. *Strahlenther Onkol* 2013;189:559–65.
- [16] Henke M, Mattern D, Pepe M, et al. Do erythropoietin receptors on cancer cells explain unexpected clinical findings? *J Clin Oncol* 2006;24:4708–13.
- [17] Lai SY, Childs EE, Xi S, et al. Erythropoietin-mediated activation of JAK-STAT signaling contributes to cellular invasion in head and neck squamous cell carcinoma. *Oncogene* 2005;24:4442–9.
- [18] Hwa JS, Kwon OJ, Park JJ, et al. The prognostic value of immunohistochemical markers for oral tongue squamous cell carcinoma. *Eur Arch Otorhinolaryngol* 2015;272:2953–9.