

Available online at [www.sciencedirect.com](http://www.sciencedirect.com)

ScienceDirect

journal homepage: [www.elsevier.com/locate/radcr](http://www.elsevier.com/locate/radcr)

## Case Report

# A rare case of primary spinal cord oligodendroglioma <sup>☆</sup>

K Eppy Buchori Aristiady, MD, Ellya, MD\*

Department of Radiology, Faculty of Medicine, Universitas Padjadjaran, and Hasan Sadikin General Hospital, Jl. Pasteur No. 38, Pasteur, Kec. Sukajadi, Bandung, Jawa Barat, 40161, Indonesia

## ARTICLE INFO

## Article history:

Received 7 February 2023

Revised 17 March 2023

Accepted 23 March 2023

Available online 20 April 2023

## Keywords:

Oligodendroglioma

Spinal cord tumor

Syringomyelia

## ABSTRACT

Primary spinal cord oligodendroglioma is a rare tumor that originates from oligodendrocytes. Oligodendroglioma itself is commonly found in the cerebral hemisphere and spinal oligodendroglioma is an unusual presentation of this disease. Here, we present a case of a 48-year-old patient with low back pain, weakness of the lower extremities, and numbness. Spinal magnetic resonance imaging (MRI) showed an intradural intramedullary vertebral mass at level T4-T5 which proved to be an oligodendroglioma after histopathological examination.

© 2023 The Authors. Published by Elsevier Inc. on behalf of University of Washington.

This is an open access article under the CC BY-NC-ND license

(<http://creativecommons.org/licenses/by-nc-nd/4.0/>)

## Introduction

Oligodendroglioma is a type of tumor that originates from oligodendrocytes, the myelination cells of the brain and spinal cord. Oligodendroglioma is commonly found in the cerebral hemisphere; however, in rare cases, it may primarily occur in the spinal cord with an incidence of 2% of all tumors arising from the spinal cord and film terminal 1.59% of all oligodendrogliomas [1–5]. The most common anatomic location of spinal oligodendrogliomas is at the thoracic level, followed by the cervical spine, thyrocervical junction, lumbar, and thoracolumbar levels [4–7]. This report presents a rare case of primary spinal oligodendroglioma and the role of MRI in the diagnosis.

## Case presentation

A 48-year-old male presented to our emergency room with weakness in his lower extremities and numbness. The patient had been relatively well before and only developed symptoms within the last few months. The patient had low back pain as well as defecation and urinary disturbances. Routine laboratory examinations were performed and the results were within normal limits. Thoracic-lumbar x-ray revealed scoliosis vertebrae thoracal with a cob angle of 3° (Fig. 1).

MRI of the cervicothoracic spine showed an intramedullary mass extending from the T4 to T5 level. Blocks that decrease signal on T1W images and increase signal on T2W images. Gadolinium-enhanced scan demonstrated a heterogeneous

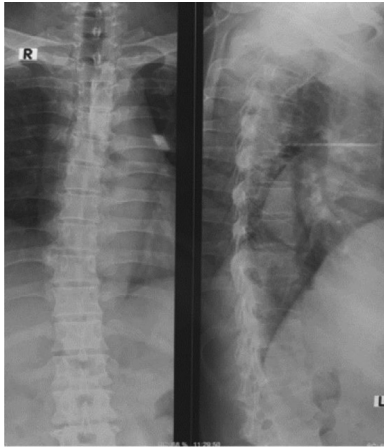
<sup>☆</sup> Competing Interests: The authors have declared that no competing interests exist.

\* Corresponding author.

E-mail address: [ellyasyofian@gmail.com](mailto:ellyasyofian@gmail.com) (Ellya).

<https://doi.org/10.1016/j.radcr.2023.03.050>

1930-0433/© 2023 The Authors. Published by Elsevier Inc. on behalf of University of Washington. This is an open access article under the CC BY-NC-ND license (<http://creativecommons.org/licenses/by-nc-nd/4.0/>)



**Fig. 1 – The thoracic radiograph reveals scoliosis of a thoracic vertebra with a Cobb angle of 3°.**

enhancing intramedullary mass. Additionally, T2-weighted images showed extensive syringomyelia above and under the mass (Fig. 2).

The patient underwent a laminectomy under general anesthesia, and a reddish mass was found within the canal spine at a T4 - T5 level with gelatinous and infiltrative characteristics (Fig. 3). The tumor was then removed by microsurgery. After surgery, the neurological deficits were slowly returning to a stable state.

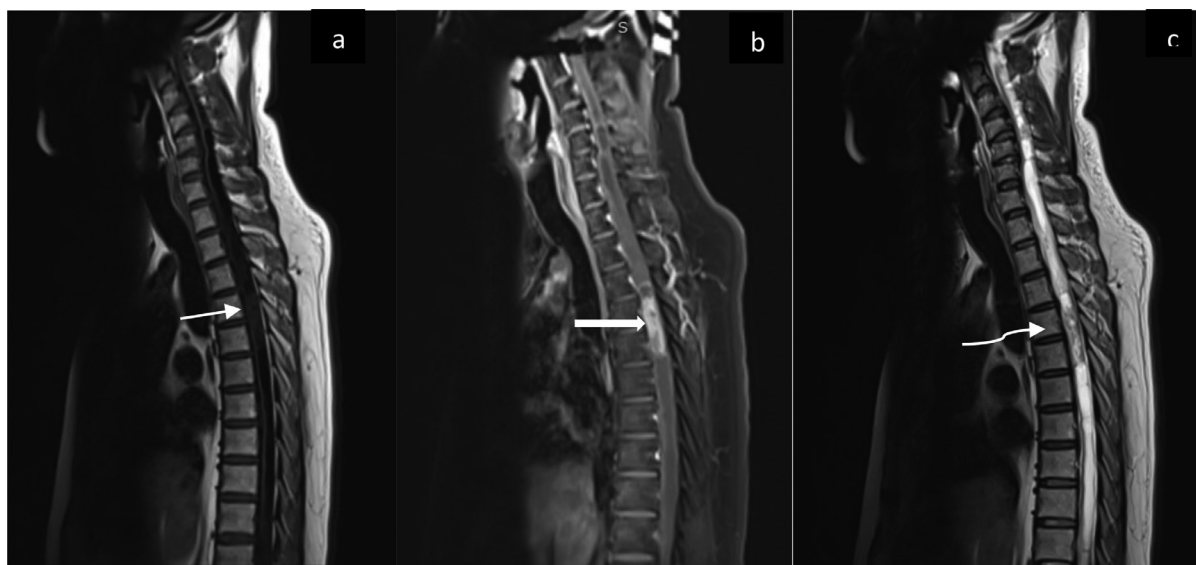
Microscopic evaluation showed round and oval cells that were hyperplastic, condensed, pleomorphic, hyperchromatic, and partially vesicular with clear nuclei and mitoses (Fig. 4). The patient was then diagnosed with oligodendroglioma. The patient then underwent a brain MRI to search for any intracranial tumor and the result was normal (Fig. 5).

## Discussion

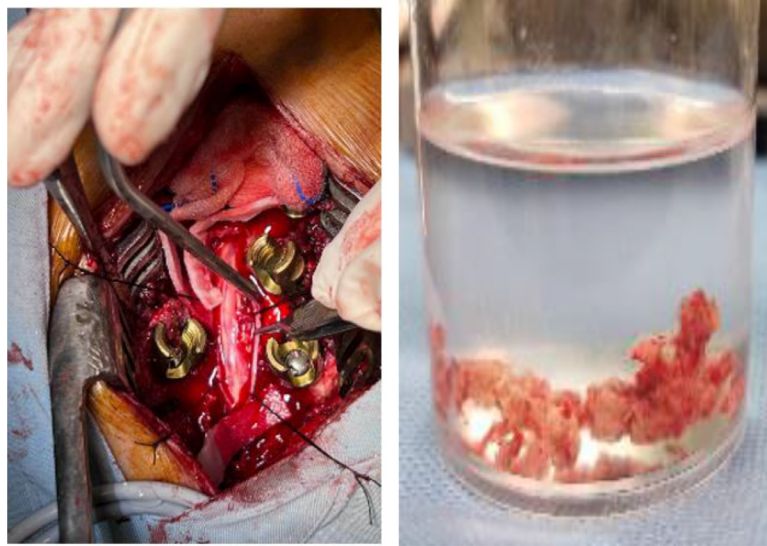
Oligodendrogliomas arise from oligodendrocyte cells in the brain and spinal cord, that produce substances to protect nerve cells in the spinal cord, most oligodendrocytes derive from oligodendrocyte progenitor cells in the ventral ventricular zone, migrate through the spinal cord, and differentiate into oligodendrocytes [5,6].

Histologically, most tumors are classified as WHO grade II oligodendrogliomas [7]. On histological examination, oligodendrogliomas are moderately cellular, with tumor cells having uniformly rounded, homogenous nuclei and swollen, clear cytoplasm. The nuclei of oligodendrogliomas are slightly larger than those of normal oligodendrocytes and have increased chromatin density. This typical histological appearance called the “honeycomb” or “fried egg” appearance is embedded in a framework of “chicken wire” vessels [8,9]. Immunohistochemical analysis shows that spinal cord oligodendrogliomas generally do not express GFAP but may exhibit focal immunoreactivity due to the presence of scattered astrocytes or minihemistocytes in the tumor bed [5,8–10].

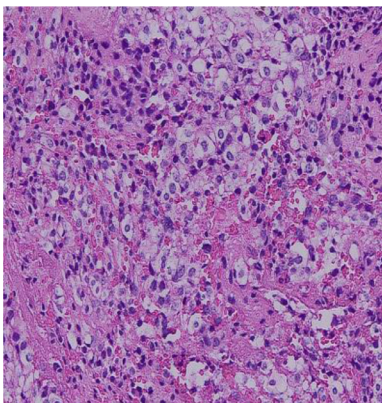
MRI is the modality of choice for diagnosing primary spinal oligodendrogliomas. Primary spinal cord oligodendrogliomas usually present as heterogeneous hypointense or isointense lesions on T1WI and hyperintense lesions on T2WI, most of the spine oligodendrogliomas show mild to moderate heterogeneous patchy enhancement on postgadolinium imaging [11]. If areas of cystic necrosis may appear it is especially observed in high-grade spinal cord oligodendrogliomas [5,10–12]. In addition to MRI, plain radiographs and CT scans help assess the presence of tumor-related skeletal deformities and calcifications. Calcification of spinal cord oligodendrogliomas is estimated to occur in 28%-40% of cases, and this is the case. The significant discovery that distinguishes it from other gliomas [5,10].



**Fig. 2 – The sagittal plane of MRI of the cervicothoracic spinal cord. There was a hypointense mass from T4 to T5 level T1-weighted images (thin arrow) (A). The lesion showed heterogeneous enhancement on T1-weighted image with gadolinium injection (thick arrow) (B). The lesion (curved arrow) was hyperintense on T2-weighted images with extensive syringomyelia (C).**



**Fig. 3 – Laminectomy was performed on the patient under general anesthesia (A), a cut section of the tumor (B).**

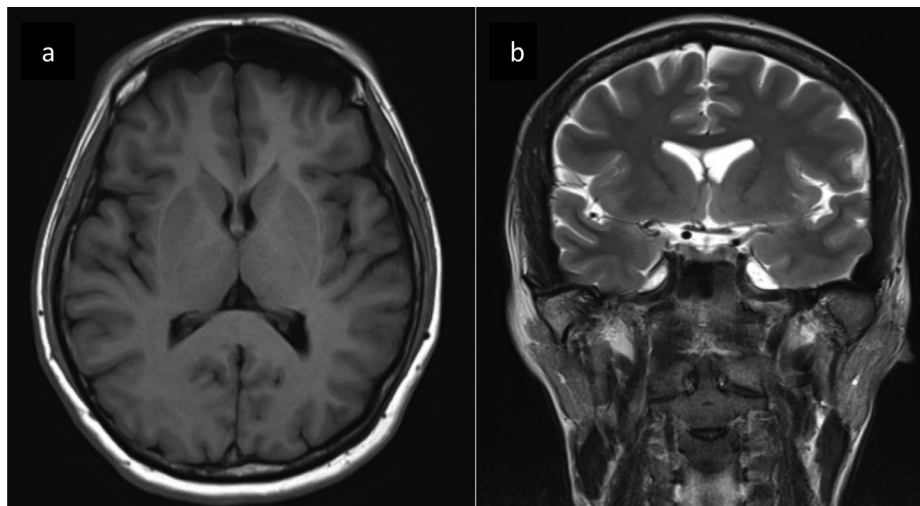


**Fig. 4 – High power (200 x) microscopic image revealing pleomorphic, hyperchromatic, and partially vesicular with clear nuclei and mitoses.**

The diagnosis of primary spinal oligodendrogliomas is difficult to distinguish from other gliomas by magnetic resonance imaging, as these findings are found in spinal astrocytoma and ependymoma. However, microcalcification is an important finding that mentioned oligodendroglioma similar to intracranial oligodendroglioma [5,13].

Besides the primary lesion, MRI is also important in detecting any coexisting condition, such as syringomyelia. Syringomyelia is a multifactorial disorder comprising fluid-filled cavitations within the spinal cord, but mostly due to local disturbances of spinal cerebrospinal fluid circulation following spinal cord trauma, infection, or inflammation [14,15].

Although treatment guidelines have not yet been established, maximal surgical resection is paramount in the treatment of spinal oligodendroglioma. Adjuvant radiotherapy remains controversial, and it is unclear whether there is a benefit from chemotherapy. Fortuna et al. In 1980, he reported that radiation therapy after surgery appeared to prolong survival. Their study analyzed only 11 cases before 1980, so



**Fig. 5 – MRI of the brain axial T1-weighted image (A) Coronal T2-weighted (B) and showed no intracranial tumor.**

their analysis was limited. On the other hand, radiation therapy is associated with complications such as postradiation myelopathy and radiation-induced spinal deformity, especially in children's patience [2,4,5,16]. Therefore, the decision to receive postoperative radiotherapy should be made very carefully, taking into account age, the extent of resection, tumor grade and histologic features, and tumor genetics [10].

In our case, the patient had a spinal mass at the thoracic level with characteristics of oligodendroglioma and extensive syringomyelia, presumably due to the oligodendroglioma obstructing the cerebrospinal fluid circulation. This report concludes that primary spinal oligodendroglioma should be considered in a patient with spinal thoracic mass, even though oligodendroglioma occurs mostly in the brain hemisphere.

---

## Conclusion

Primary spinal cord oligodendrogliomas are extremely rare tumors. Even when a confirmed diagnosis is made by histopathological examination, preoperative imaging tests help to locate and characterize the mass and select appropriate treatment.

---

## Patient consent

Complete written informed consent was obtained from the patient for the publication of this study and accompanying images.

---

## REFERENCES

- [1] Choe WJ, Chung CK, Cho BK, Kim HJ. Spinal cord tumors: an analysis of 654 cases (1973-1999). *J Korean Neurosurg Soc* 2001;30:1004–12.
- [2] Fortuna A, Celli P, Palma L. Oligodendrogliomas of the spinal cord. *Acta Neurochir (Wien)* 1980;52:305–29.
- [3] Pagni CA, Canavero S, Gaidolfi E. Intramedullary “holocord” oligodendroglioma: case report. *Acta Neurochir* 1991;113:96–9.
- [4] Yuh WT, Chung CK, Park SH. Primary spinal cord oligodendroglioma with postoperative adjuvant radiotherapy: a case report. *Korean J Spine* 2015;12(3):160–4.
- [5] Tunthanathip T, Oearsakul T. Primary spinal cord oligodendroglioma: a case report and review of the literature. *Chinese Neurosurg J* 2016;2(1):2.
- [6] Bradl M, Lassmann H. Oligodendrocytes: biology and pathology. *Acta Neuropathol* 2010;119:37–53.
- [7] Wang F, Qiao G, Lou X. Spinal cord anaplastic oligodendroglioma with 1pdeletion: report of a relapsing case treated with temozolomide. *J Neurooncol* 2011;104:387–94.
- [8] Fountas KN, Karampelas I, Nikolakakos LG, Troup EC, Robinson JS. Primary spinal cord oligodendroglioma: case report and review of the literature. *Childs Nerv Syst* 2004;21:171–5.
- [9] Bigner DD, McLendon RE, Bruner LM. *Russell & Rubinstein's pathology of tumors of the nervous system*. London: Arnold; 1998. p. 307–571.
- [10] Hayat MA. *Tumors of the Central Nervous System, Volume 6: Spinal tumors*. Netherlands: Springer; 2012. p. 61–70.
- [11] Zimmerman RA, Bilaniuk LT. Imaging of tumors of the spinal canal and cord. *Radiol Clin North Am* 1998;26:965–1007.
- [12] Gilmer-Hill HS, Ellis WG, Imbesi SG, Boggan JE. Spinal oligodendroglioma with gliomatosis in a child: a case report. *J Neurosurg* 2000;92:109–13.
- [13] Koeller KK, Rosenblum RS, Morrison AL. Neoplasms of the spinal cord and filum terminale: radiologic pathologic correlation. *Radiographics* 2000;20:1721–49.
- [14] Fischbein NJ, Dillon WP, Cobbs C, Weinstein PR. The “syrinx” state is a reversible myelopathic condition that may precede syringomyelia. *Am J Neuroradiol* 1999;20:7–20.
- [15] Greitz D. Unraveling the riddle of syringomyelia. *Neurosurg Rev* 2006;29(4):251–64.
- [16] Ushida T, Sonobe H, Mizobuchi H, Toda M, Tani T, Yamamoto H. Oligodendroglioma of the “widespread” type in the spinal cord. *Childs Nerv Syst* 1998;14:751–5.