



Contents lists available at ScienceDirect

Respiratory Medicine Case Reports

journal homepage: <http://www.elsevier.com/locate/rmcr>

Case report

DO NOT FALL to the VAPE TRAP!

Sudeep Acharya, Syed Ibaad Ali, Shamsuddin Anwar^{*}, Allison Glaser

Staten Island University Hospital, Northwell Health, United States



ARTICLE INFO

Keywords:

Critical care
Internal medicine
Vape induced lung injury
Respiratory medicine

ABSTRACT

Introduction: Whilst the use of combustible tobacco products continues to decline in the United States, the use of e-cigarettes has seen an explosive rise in recent years. In 2019 an outbreak on EVALI was seen across the country, highlighting the fact that e-cigarettes may not be as harmless as previously perceived.

Case description: A 22-year-old male came to the emergency department complaining of vomiting and shortness of breath. Patient reported using a “pod” a day of a “JUUL” e-cigarette. Patient’s oxygen requirement continued to increase and was eventually shifted to the intensive care unit and mechanically ventilated. After a course of intravenous glucocorticoids, the patient was successfully weaned off the mechanical ventilation to oral glucocorticoids and discharged.

Discussion: Our patient’s clinical course can be described as a “classic” case of EVALI. But in contrast to previously reported cases, our patient did not use e-cigarettes known to contain vitamin E acetate or THC two common substances implicated in EVALI. Our patient exclusively used a JUUL e-cigarette at a rate much higher than the typical user. The widespread use of JUUL and e-cigarettes especially amongst the younger demographics is especially concerning.

Conclusion: Research efforts must be directed towards the substances utilized in e-cigarettes, and their use should be actively discouraged.

1. Introduction

Over the past decade consumption of traditional tobacco products amongst high school students has almost been halved (18.7% in 2011 to 7.6% in 2018). Concurrently, the use of e-cigarettes amongst the same group has skyrocketed (1.5% in 2011 to 20.8% in 2018) [1]. Noncombustible tobacco products, such as e-cigarettes were initially marketed to help users quit smoking, e-cigarettes have cultivated their own user base especially amongst non-smokers. E-cigarettes are widely perceived to be harmless, but the outbreak of EVALI (e-cigarette or vaping associated lung injury) cases in 2018 has proven this perception to be wrong [2]. As of February 2020 more than 2500 cases of EVALI have been reported across the United States with the popular brand “JUUL” commanding more than 70% of the e-cigarette market [1,3].

A public health investigation conducted in July 2019 showed that patients with EVALI universally present with respiratory and constitutional symptoms. The severity of EVALI in each patient and its management has been under close investigation and guidelines continue to evolve. Chest X-ray and CT (computed tomographic) image findings prove that almost all cases of EVALI involve some form of pneumonitis.

The exact cause of EVALI remains difficult to investigate given the extreme heterogeneity in the types of e-cigarettes available in both the formal and informal markets [1–3].

Our case is of a previously healthy 22-year-old male who presented with constitutional symptoms and vomiting after a month of heavy use of a “JUUL” e-cigarette and developed severe EVALI.

2. Case description

A 22-year-old Hispanic male presented with nausea, vomiting and fever (101 °F) for three days. On systemic review, he reported generalized weakness, body aches and a mild productive cough with white sputum. Patient had a past medical history of exercise-induced asthma and used a rescue inhaler as needed. His social history revealed a smoking history of 2–3 cigarettes daily for 3–4 months and recent transition to a “JUUL” e-cigarette. The patient reported daily use of JUUL for one month and consumption of one cartridge or “pod” per day. The patient upon admission met the SIRS (systemic inflammatory response syndrome) criteria and a CXR showed bilateral lower lobe opacities (Fig. 1).

^{*} Corresponding author.

E-mail address: shamsduhs15@gmail.com (S. Anwar).

<https://doi.org/10.1016/j.rmcr.2020.101165>

Received 3 July 2020; Accepted 5 July 2020

Available online 10 July 2020

2213-0071/© 2020 The Author(s).

Published by Elsevier Ltd.

This is an open access article under the CC BY-NC-ND license

(<http://creativecommons.org/licenses/by-nc-nd/4.0/>).

At this point intravenous Ceftriaxone & Azithromycin prophylaxis for community acquired pneumonia were initiated. As the patient had multiple episodes of vomiting and continued nausea, a CT of the chest and abdomen with intravenous contrast was obtained. Diffuse ground glass opacities in both lung fields with subpleural scarring were seen. No abdominal pathology was demonstrated on the CT scan.

The patient initially remained stable on room air and further work up was carried out for suspected pneumonia. Viral PCR panel, blood culture, HIV and urine Legionella & Streptococcus tests were obtained which resulted as negative. The patient's oxygen requirement continued to worsen despite supportive care with a nasal cannula & non-invasive mechanical ventilation. On the third day of hospitalization his oxygen saturation dropped to 70%. Patient was tachypneic, tachycardiac and was gradually getting fatigued. An arterial blood gas obtained showed primary respiratory alkalosis (pH 7.41, pCO₂ 32, HCO₃ 20, pO₂ 51 and arterial oxygen saturation 86%). Immediate CT angiogram of the chest was obtained to rule out pulmonary embolism. It did not show any blood clots however, it demonstrated rapid progression of previously demonstrated bilateral ground glass opacities now involving the upper lobes of both lungs compatible with acute respiratory distress syndrome (ARDS). (Figs. 2–5).

Patient was intubated and transferred to the intensive care unit. He was initiated on intravenous corticosteroids and mechanical ventilation with high positive end expiratory pressure and low tidal volume as a part of ARDS protocol. After three days, he was successfully weaned off the mechanical ventilation to a high flow nasal cannula. Inflammatory markers (C-reactive protein, procalcitonin) and deep endotracheal cultures did not show any signs of airway tract infection and pneumonia, thus antibiotics were discontinued. Patient was successfully transitioned to oral prednisone and was discharged home with tapering oral steroids and a close follow up by the pulmonology department.

3. Discussion

“Vaping” is defined as inhaling an aerosolized substance which is created by heating a liquid or wax essentially containing elements such as nicotine, THC (tetrahydrocannabinol), vitamin E and other additives. Since 2019, EVALI has been recognized as an emerging respiratory illness, a total of 2807 cases and 68 deaths have been identified by the CDC (Centers for Disease Control and Prevention) as of February 2020. Our patient belongs to the most affected age group being males between the ages of 18–24 years old [1–3].

In current clinical practice, EVALI is a diagnosis of exclusion.

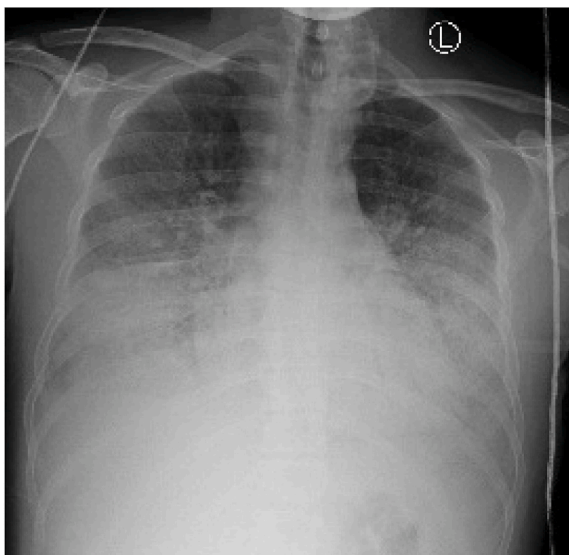


Fig. 1. Chest X-ray Showing bilateral lung opacities.

Although no robust guidelines are present but extracting from medical literature suggest the following criteria for EVALI diagnosis: use of e-cigarettes in the last 90 days, other causes of lung infections have been ruled out, demonstration of opacities on imaging studies as well as an absence of an alternative diagnosis. A wide spectrum of lung injury including pneumonitis, pneumonia, bronchiolitis and diffuse alveolar damage has been described in EVALI [4,5]. The common presentation of EVALI includes shortness of breath, cough, chest pain and hemoptysis. Fever, hypoxemia and tachycardia associated with opacities in the imaging studies such as chest X-ray and computed tomography (CT) may support further in establishing the diagnosis of given other causes have been ruled out. Ground glass opacities usually bilateral are typical findings of EVALI, but consolidation and pleural fluid may also be noted on imaging studies [6]. Bronchoscopy with bronchoalveolar lavage is usually performed in patients with progressive symptoms to exclude other causes of lung pathology and infection.

The first step in the management of EVALI is to first exclude other possible causes of lung injury. Supportive care is highly recommended with supplemental oxygenation via nasal cannula, venturi mask or high flow, with target saturation of >88%. On incidence of worsening respiratory status, utilization of mechanical ventilation and rarely ECMO (extra corporeal membrane oxygenation) has also been warranted as seen in medical literature [7]. The use of glucocorticoids has been controversial with some evidence of short-term course of steroids having observational benefit especially in mechanically vented patients. After recovery from the acute phase of lung injury, patients with EVALI should be closely monitored for progression of the disease and the need for rehospitalization [8].

Vitamin E acetate has been found in multiple BAL (Bronchoalveolar lavage) samples from known EVALI patients. Vitamin E acetate is most commonly found in noncommercial or THC infused vapor mixtures. A study done on an animal model showed that vitamin E acetate elevates the levels of albumin and leukocytes in the lungs, which can be considered as markers of pulmonary epithelial cell damage. In addition to this, vitamin E acetate might also release Ketene gas within the lungs, a known toxic substance [9,10]. It is interesting to note that in our clinical scenario, the patient only used a JUUL vape which does not have vitamin E or THC as constituents, suggesting that several un-identified compounds may also play a part in lung injury. “JUUL” as reported by the company itself has benzoic acid and propylene glycol both compounds have been implicated in causing epithelial injury. What makes “JUUL” different from other e-cigarettes is the sheer amount of nicotine a user is inhaling [11].

“JUUL” is by far the most popular commercially available e-cigarette commanding over 70% of “market share. JUUL is especially popular amongst younger demographics. “JUUL” operates through the use of disposable pods which come in a variety of flavors. In a study done in 2019, most users reported using ten pods in a 30-day period or around a single pod every three days [12]. It is interesting to highlight that our patient did not report the use of THC infused vapors or any products known to contain vitamin E acetate. Hence, the patient by the above discussed standards are an above average user and is an outlier when it comes to JUUL use but at the same time he represents a sizable minority amongst e-cigarette users.

As the number of e-cigarette and vape users exponentially grows each day, creating concerns in the medical community at large; a big portion of these users do not perceive e-cigarettes to be hazardous to health. A similar portion of the community seemed to be unaware of the fact that they were consuming nicotine in a startling amount found in a single JUUL pod. Given their composition and widespread use, the theory that e-cigarettes are a “gateway” to reduce the use of traditional tobacco products is currently under study. If suggested otherwise the e-cigarettes will in fact be contributing towards an increase in tobacco use, a complete opposite effect from their initial marketed use.

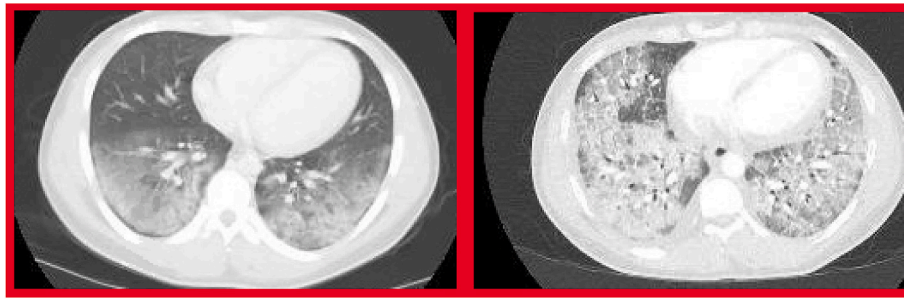


Fig. 2. Comparison of CT scan images from admission (left) to intubation (right).

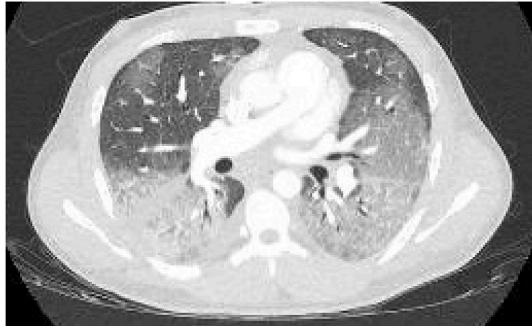


Fig. 3. Axial sections of CT chest showing diffuse bilateral ground glass opacities in lungs.

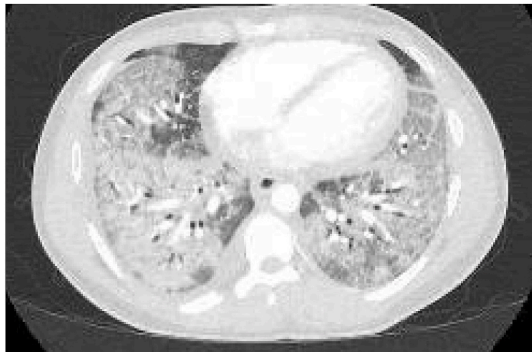


Fig. 4. Axial sections of CT chest showing diffuse bilateral ground glass opacities in lungs.

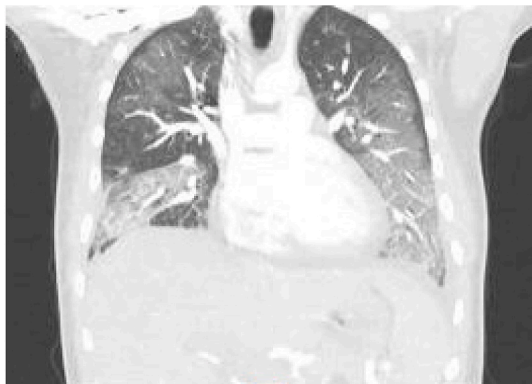


Fig. 5. Coronal section of the CT chest showing diffuse bilateral ground glass opacities in lungs.

4. Conclusion

The aforementioned clinical scenario and extensive medical literature provides substantial evidence that e-cigarettes such as JUUL have detrimental effects on health and their use should be actively discouraged by clinicians and public health officials. EVALI should be kept as a differential diagnosis for lower respiratory tract problems in cases where e-cigarette use is reported, and patients present with typical symptoms. Additionally, we recommend extensive research into the vapor used in e-cigarettes, in order to establish the etiology of EVALI. Given the widespread use of e-cigarettes and the lack of formal treatment guidelines, further outbreaks of EVALI may be just over the horizon.

Declaration of competing interest

To Whom it may concern, I am submitting a manuscript for publication entitled 'DO NOT FALL TO THE VAPE TRAP!' As a corresponding author, I would like to declare that I know of no conflict of interest for this case report, and none of the authors have received any financial support for this work that could have influenced its outcome. As a corresponding author, I confirm that the manuscript has been read and approved by all the named co-authors (Sudeep Acharya M. D, Syed Ibaad Ali M. D, Shamsuddin Anwar M. D, Allison Glaser M). Feel free to contact me on my email for any questions or concerns.

References

- [1] M.C. Fadus, T.T. Smith, L.M. Squeglia, The rise of e-cigarettes, pod mod devices, and JUUL among youth: factors influencing use, health implications, and downstream effects, *Drug Alcohol Depend.* 201 (2019) 85–93, <https://doi.org/10.1016/j.drugalcdep.2019.04.011>.
- [2] J.E. Layden, I. Ghinai, I. Pray, et al., Pulmonary illness related to E-cigarette use in Illinois and Wisconsin - final report, *N. Engl. J. Med.* 382 (10) (2020) 903–916, <https://doi.org/10.1056/NEJMoa1911614>.
- [3] Centers for Disease Control and Prevention, Outbreak of lung injury associated with use of E-cigarette, or vaping, products. https://www.cdc.gov/tobacco/basic_information/e-cigarettes/severe-lung-disease.html.
- [4] M. Agustin, M. Yamamoto, F. Cabrera, R. Eusebio, Diffuse alveolar hemorrhage induced by vaping, *Case Rep Pulmonol* 2018 (2018), <https://doi.org/10.1155/2018/9724530>, 9724530. Published 2018 Jun 7.
- [5] J.G. Schier, J.G. Meiman, J. Layden, et al., Severe pulmonary disease associated with electronic-cigarette-product use - interim guidance [published correction appears in *MMWR morb mortal wkly rep.* 2019 sep 27;68(38):830], *MMWR Morb. Mortal. Wkly. Rep.* 68 (36) (2019) 787–790, <https://doi.org/10.15585/mmwr.mm6836e2>. Published 2019 Sep. 13.
- [6] S. Kligerman, C. Raptis, B. Larsen, et al., Radiologic, pathologic, clinical, and physiologic findings of electronic cigarette or vaping product use-associated lung injury (EVALI): evolving knowledge and remaining questions, *Radiology* 294 (3) (2020) 491–505, <https://doi.org/10.1148/radiol.2020192585>.
- [7] S.D. Maddock, M.M. Cirulis, S.J. Callahan, et al., Pulmonary lipid-laden macrophages and vaping, *N. Engl. J. Med.* 381 (15) (2019) 1488–1489, <https://doi.org/10.1056/NEJMc1912038>.
- [8] C.A. Mikosz, M. Danielson, K.N. Anderson, et al., Characteristics of patients experiencing rehospitalization or death after hospital discharge in a nationwide outbreak of E-cigarette, or vaping, product use-associated lung injury - United States, 2019, *MMWR Morb. Mortal. Wkly. Rep.* 68 (5152) (2020) 1183–1188, <https://doi.org/10.15585/mmwr.mm685152e1>. Published 2020 Jan 3.
- [9] T.A. Bhat, S.G. Kalathil, P.N. Bogner, B.C. Blount, M.L. Goniewicz, Y.M. Thanavala, An animal model of inhaled vitamin E acetate and EVALI-like lung injury, *N. Engl. J. Med.* 382 (12) (2020) 1175–1177, <https://doi.org/10.1056/NEJMc2000231>.

- [10] D. Wu, D.F. O'Shea, Potential for release of pulmonary toxic ketene from vaping pyrolysis of vitamin E acetate, *Proc. Natl. Acad. Sci. U. S. A.* 117 (12) (2020) 6349–6355, <https://doi.org/10.1073/pnas.1920925117>.
- [11] G.A. Salzman, M. Alqawasma, H. Asad, Vaping associated lung injury (EVALI): an explosive United States epidemic, *Mo. Med.* 116 (6) (2019) 492–496.
- [12] E.L.S. Leavens, E.M. Stevens, E.I. Brett, et al., JUUL electronic cigarette use patterns, other tobacco product use, and reasons for use among ever users: results from a convenience sample, *Addict. Behav.* 95 (2019) 178–183, <https://doi.org/10.1016/j.addbeh.2019.02.011>.