



Contents lists available at ScienceDirect

International Journal of Surgery Case Reports

journal homepage: www.casereports.com

Pleomorphic rhabdomyosarcoma on the chest wall which infiltrated intercostal muscles: A case report

Kamal Basri Siregar^{a,*}, Arjumardi Azrah^b^a Oncology Surgery Department, Faculty of Medicine, Universitas Sumatera Utara, Universitas Sumatera Utara Hospital, Jl. Dr Mansyur No. 66, Medan, 20154, Indonesia^b General Surgery Department, Faculty of Medicine, Universitas Sumatera Utara, Universitas Sumatera Utara Hospital, Jl. Dr Mansyur No. 66, Medan, 20154, Indonesia

ARTICLE INFO

Article history:

Received 6 June 2020

Received in revised form 4 September 2020

Accepted 5 September 2020

Available online 21 September 2020

Keywords:

Pleomorphic rhabdomyosarcoma

Reconstruction

Wide excision

ABSTRACT

INTRODUCTION: Rhabdomyosarcoma (RMS) is the malignant tumor of skeletal muscles that origin from rhabdomyoblast. RMS is the most common soft tissue tumor in children, but this is a sporadic condition in adults and only 1% of any solid malignancies of an adult. The most prevalent subtype of RMS in an adult is a pleomorphic type.

PRESENTATION OF CASE: We reported a case of a 57 years old woman with swelling on the left chest with pain for three years. Physical examination revealed swelling on the left chest with solid consistency and immobile. The thorax CT-scan with IV contrast suspicious soft tissue tumor on the anteromedial of the left chest wall that stuck to the left lung.

DISCUSSION: Histopathological examination confirmed the pleomorphic subtype of rhabdomyosarcoma. The interdisciplinary idea was reported to be superior to a single therapeutic modality. The patient underwent an incisional biopsy.

CONCLUSION: This is a case of pleomorphic rhabdomyosarcoma diagnosed base on histopathology from an incisional biopsy, and IHC performed wide excision gave satisfactory results.

© 2020 The Authors. Published by Elsevier Ltd on behalf of IJS Publishing Group Ltd. This is an open access article under the CC BY-NC-ND license (<http://creativecommons.org/licenses/by-nc-nd/4.0/>).

1. Introduction

Rhabdomyosarcomas (RMSs) are generally a pediatric neoplasm representing 5% of all childhood cancers [1,2], although it can sometimes be seen in adults. Rhabdomyosarcomas are rarely found in adults and only accounts for less than 1% of all solid malignant tumors [3,4]. RMS is generally asymptomatic or provides symptoms related to the location of the tumor where 20% of patients are reported with distant metastases: mainly 39% lung metastases, 32% bone marrow metastases, 30% lymph nodes metastases and 27% bone metastases [5]. The primary locations of RMSs are generally in the head and neck, in the genitourinary system, and the extremities. Other unusual central locations include the torso, chest wall area, gastrointestinal tract, and perianal area [6,7].

Rhabdomyosarcoma histopathologically consists of embryonal, pleomorphic, and alveolar types [5,8]. Pleomorphic rhabdomyosarcoma (PRMS) is a rare and controversial phenotype of a skeletal muscle tumor. Stout first introduced PRMS in 1974 as a classic rhabdomyosarcoma [2]. Over the next three decades, the diagnosis was made solely based on morphological features and possibly

also includes other types of sarcomas (including malignant fibrous histiocytoma and pleomorphic leiomyosarcoma). In 1958, Horn and Enterline introduced four rhabdomyosarcoma subtypes and named the classic rhabdomyosarcoma as pleomorphic rhabdomyosarcoma. Ideally, complete resection with margins higher than 1 cm should be performed. Complete resection of the primary lesion may not be possible or recommended due to the location of the lesions, loss of function, and cosmetic impact [6]. Optimal therapy for rhabdomyosarcoma remains undefined [2]. Hence, we report a case of a 57-years-old woman that was diagnosed with pleomorphic rhabdomyosarcoma of intercostal muscle in a public hospital. This study had been written according to SCARE 2018 guidelines for case report [9].

2. Case report

A 57-years-old woman, came to the hospital with a referral from a primary physician, with the chief complaint a lump on the left chest wall since three years ago and had been worsening since six months ago. The occupation of the patient is house-wives, and the patient acknowledges no history of trauma, infection, inflammation, or history of any surgical procedures. The patient also complained of left chest pain since four months ago. Lump on the

* Corresponding author.

E-mail address: kamal@usu.ac.id (K.B. Siregar).

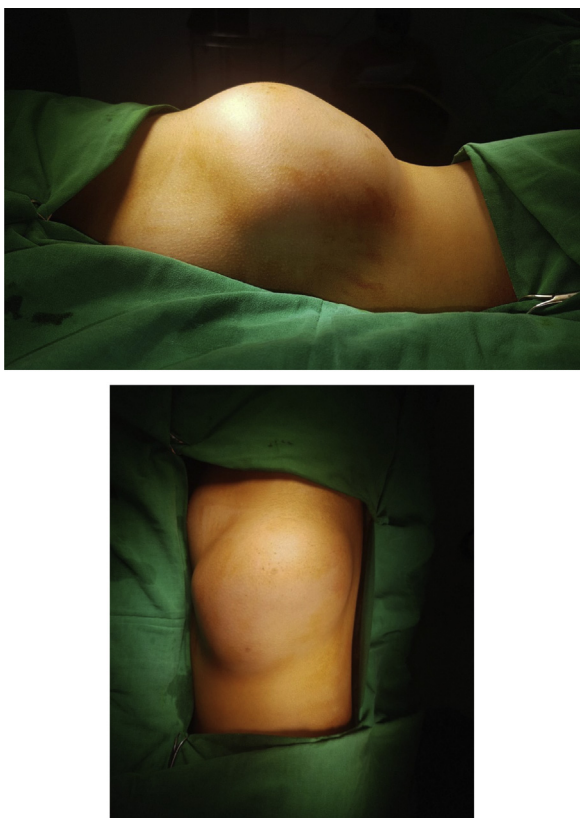


Fig. 1. A tumor on the left anteromedial of the chest wall.

chest has been complained since three years ago, and the lump gradually increased in size.

From physical examination found solid and immobile lumps on the left chest wall, unclear margins with pain (Fig. 1). The chest plain radiograph shows a homogeneous consolidation picture on the left chest wall.

On the CT scan of the thorax, soft tissue pictures of the left anteromedial chest wall tumor infiltrated the intercostal muscles (Fig. 2). The patient underwent histopathology of incisional biopsy, in which we discover spherical and spindle cells, suggestive of a pleomorphic rhabdomyosarcoma (Fig. 3), and then immunohistochemistry was performed (Fig. 4).

The regimen management includes the multidisciplinary concept with a primary focus on local control of the tumor (surgery, radiation) and systemic control of the tumor (chemotherapy). The interdisciplinary idea was reported to be superior to a single therapeutic modality. For the pleomorphic rhabdomyosarcoma, there is no evidence of the effectivity of chemotherapy or radiotherapy. Therefore surgery was recommended. Preoperative measures were taken, and the patients underwent wide local excision. During the operation, the surgical oncologist encounters no difficulties and discovers a tumor with the size 100 mm × 130 mm × 70 mm and weight 500 g. Five days after the surgery, the patient shows no signs of complication with stable hemodynamics, and the patients were discharged from the hospital after two weeks of monitoring and scheduled for a six months follow-up for a chest X-ray and CT-Scan.

3. Discussion

Rhabdomyosarcomas are found in less than 1% of all solid malignant tumors in adults. Three main histopathological variations of this tumor were found: embryonal RMS (ERMS), alveolar RMS

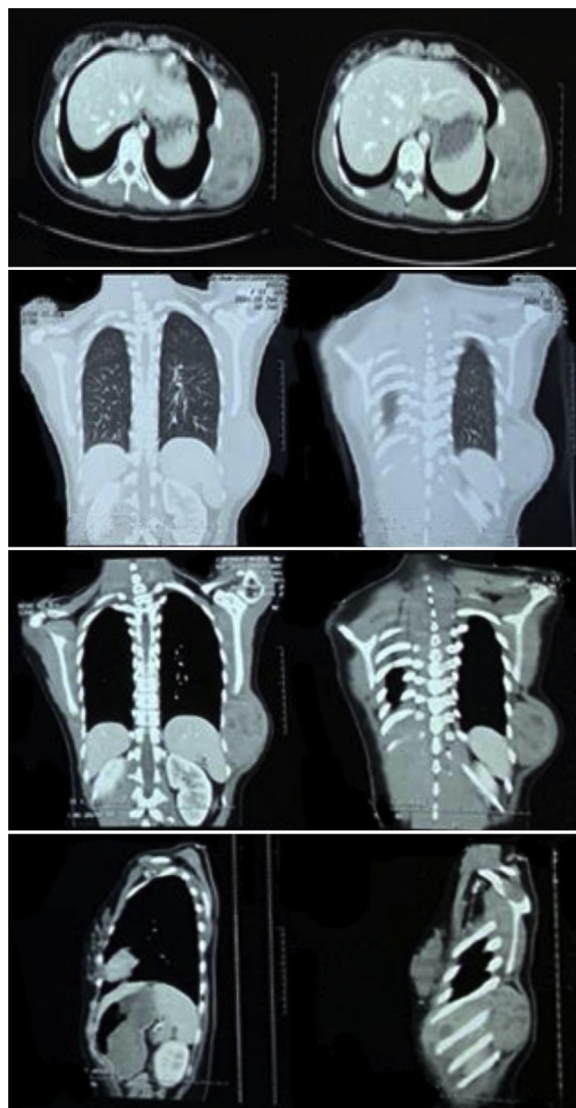


Fig. 2. CT-scan of the Thorax: mass on the anteromedial of the right chest wall infiltrating the ribs and attached the left lung.

(ARMS), and pleomorphic RMS (PRMS), where PRMS is the most common subtype found in adults. We report one case of pleomorphic rhabdomyosarcoma in the chest wall.

The etiology of RMS is still unknown, as the common sarcoma with a small incidence, so it is difficult to find a correlation about predisposing factors with the tumor. In the adult population, no etiology-related studies were found from RMS. Pleomorphic RMS is an aggressive type of sarcoma, generally originating in the extremities of adult men over 45 years. Less than 1% of pediatric RMS is pleomorphic RMS.

Rhabdomyosarcoma is generally an asymptomatic mass or has symptoms associated with primary lesions. Patients present with pain due to the compression effect of neural structures by the mass. Common locations, as mentioned above, include the head and neck region, genitourinary tract, trunk, and extremities. All RMS patients require a complete laboratory examination, including total blood count, electrolytes, liver function tests, and renal function tests. Imaging of the primary lesion should be done with CT-scan or MRI. Imaging will determine the location of the tumor against vital structures and determine the size of the tumor. This parameter is an essential feature in determining operating actions. On physical examination, found a lump in the left chest wall. CT scan shows a

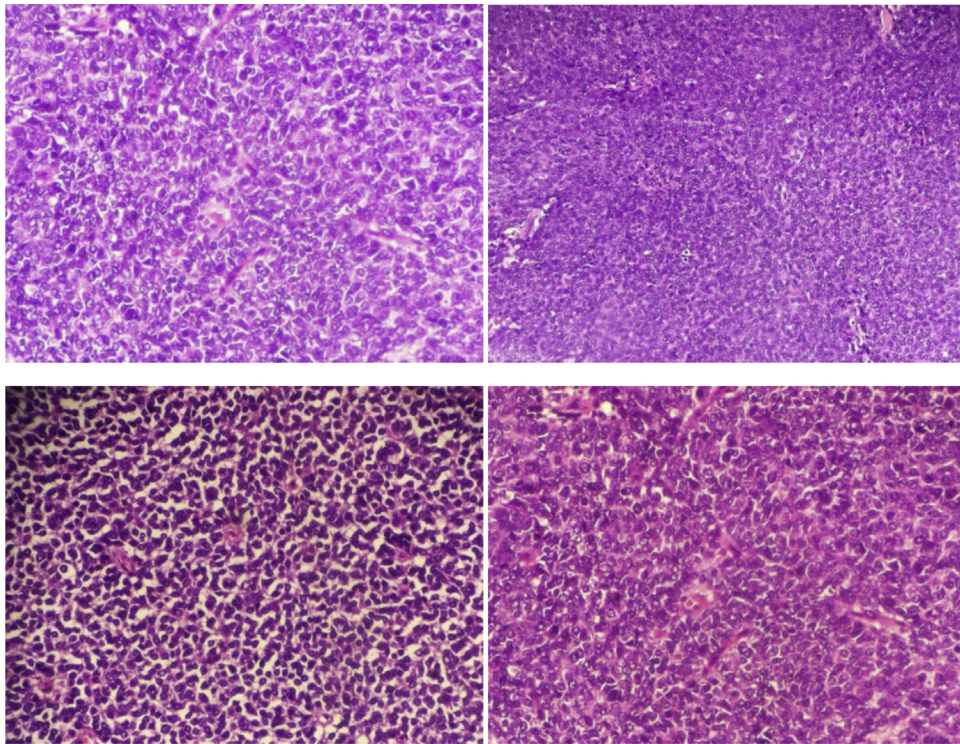


Fig. 3. Histopathology from the incisional biopsy with sheets of atypical, bizarre, large, polygonal pleomorphic rhabdomyoblasts with abundant eosinophilic cytoplasm suggestive pleomorphic rhabdomyosarcoma.

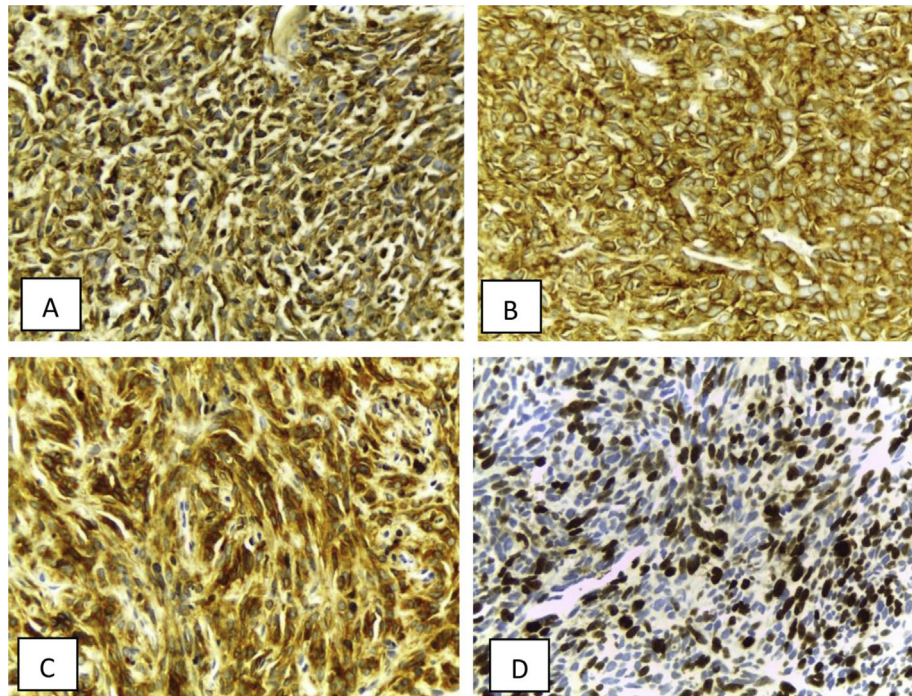


Fig. 4. IHC of the Pleomorphic Rhabdomyosarcoma myoglobin positivity.

soft tissue tumor in the anteromedial of the chest wall attached to the left lung.

PRMS is a common subtype in adults, where large pleomorphic rhabdomyoblasts are found with eosinophilic cytoplasm. Three morphological variants were found: classical, round cell, and spindle cell. Mixed types include a combination of more than one histological subtype. Establishing a diagnosis based on histopathol-

ogy examination is difficult, so the experienced pathologist is essential. Rhabdomyosarcomas rare malignancies associated with a rhabdomyoblastic phenotype that can be demonstrated morphologically or by immunohistochemistry for MYOD1 and myogenin [4]. Specific immunohistochemical markers for skeletal muscle differentiation help in the diagnosis of pleomorphic RMS. PRMS is found at least one specific skeletal muscle marker (myoglobin,

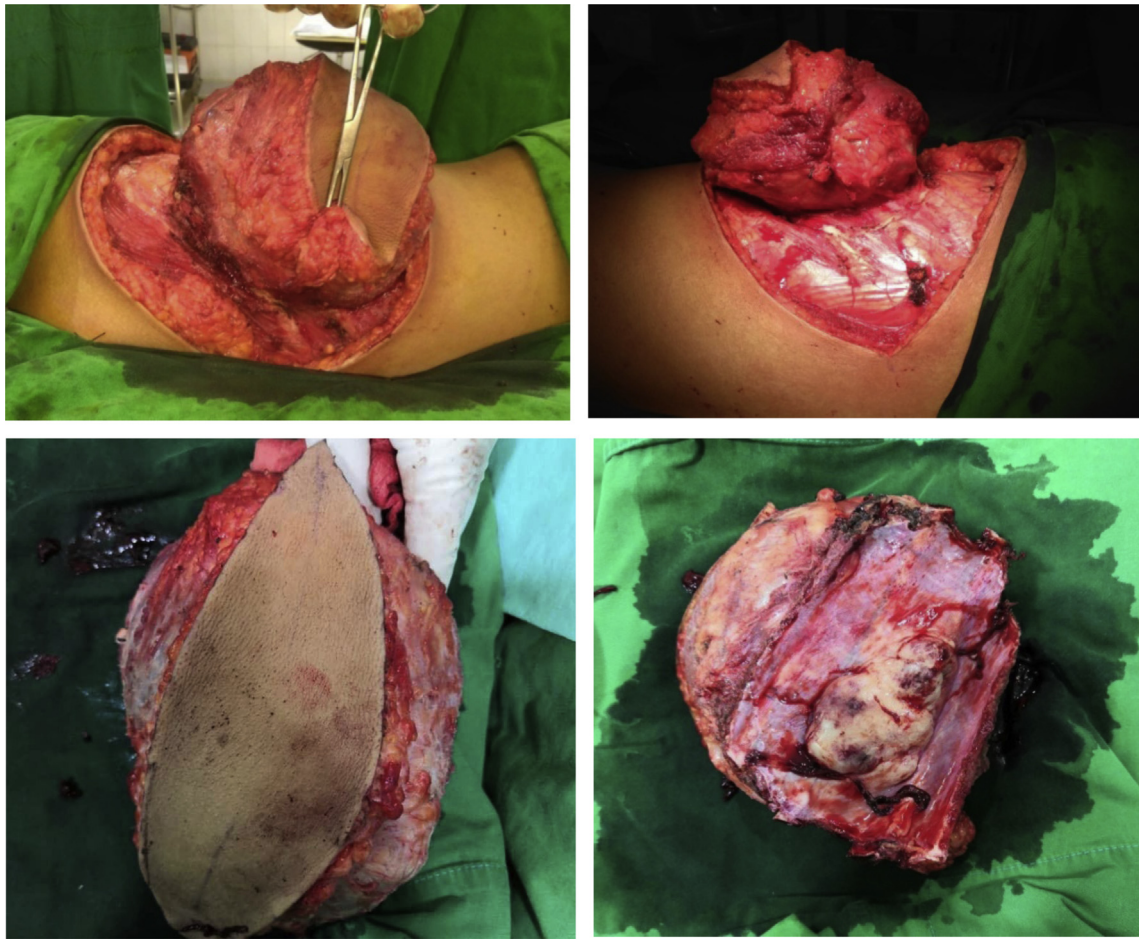


Fig. 5. Wide excision of the tumor with the removal of the ribs.

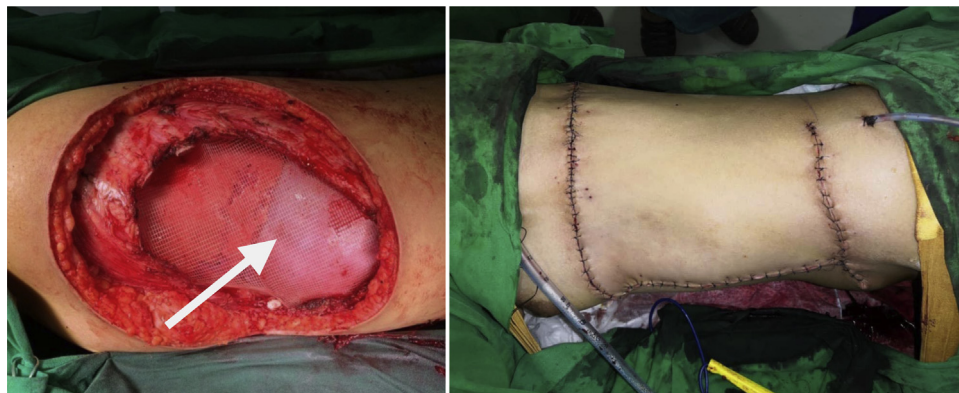

Fig. 6. Rotational flap from pectoralis major muscle to close the defect.

(arrow: pleura and lung).

MyoD1 nucleus, myf4 nucleus, fast myosin) and nonspecific markers (desmin, myogenin). Myoglobin (95%) and skeletal muscle myosin (80%) are sensitive markers for PMRS. Histopathology of incisional biopsy, in this case, were found spherical and spindle cells, suggestive of a pleomorphic rhabdomyosarcoma, and immunohistochemistry was performed (Fig. 4).

The European cooperative group (COG), previously known as the Intergroup Rhabdomyosarcoma Study Group (IRSG), categorizes patients into four risk groups depending on the clinical staging system: Low-risk, standard-risk, high-risk, and very high risk. With 83% survival rates on stage I, 70% on stage II, 52% on stage III, and 20%

on stage IV. The absence of distant metastases, favorable anatomic locations, total tumor removal when surgery, and tumor size less than 5 cm are useful prognostic factors. As explained above, the outcome for rhabdomyosarcoma cases is worse in adults than in children due to a small number of cases and protocols which are not standardized. With a 5-year overall survival rate is 27% in adults. This tumor has the worst prognosis compared to other pleomorphic sarcomas. The regimen management includes the multidisciplinary concept with a primary focus on local control of the tumor (surgery, radiation) and systemic control of the tumor (chemotherapy). The interdisciplinary idea was reported to be superior to a single ther-

apeutic modality. Since there is no evidence of the effectivity of chemotherapy or radiotherapy for pleomorphic rhabdomyosarcoma. Therefore, surgical resection is still the chosen treatment. The role of surgery depends on the size of the tumor and the location of the tumor. Single modality of surgery is not curative, but better outcomes are reported in cases where total or marginal resection or even debulking is performed (Fig. 5). In our case, we found a tumor with the size 100 mm × 130 mm × 70 mm and weight 500 g, performed extensive excision based on oncological margin principles and cutting ribs III, IV, V, VI, excision of left latisimus dorsi muscle, then the chest wall was reconstructed with the paul tohalele method by closing the defect with a rotational flap of pectoralis major muscle (Fig. 6). From this case, we can determine the prognosis and recurrence of pleomorphic rhabdomyosarcoma based on the time of the first diagnosis made, size of the tumor, and surgical procedure.

4. Conclusion

We presented a case of a 57-year-old woman without prior illness diagnosed with rhabdomyosarcoma pleomorphic based on histopathological findings from an incisional biopsy. We underwent surgical resection, and the results were satisfactory.

Declaration of Competing Interest

The authors report no declarations of interest.

Funding

There is no financial funding that contributes to collecting, interpreting data, writing, and publishing the manuscript.

Ethical approval

The Ethical Committee has approved this study of the Faculty of Medicine Universitas Sumatera Utara 2020.

Consent

Written informed consent was obtained from the patient for publication of this case report and accompanying images. A copy of the written consent is available for review by the Editor-in-Chief of this journal on request. There is no ethical issue of all identifying identities from this manuscript.

Author contribution

Kamal Basri Siregar is a doctor in charge of these patients and has made substantial contributions to collecting, analyzing, and contributing data. Arjumardi Azrah is in charge of drafting and writing the article. All authors have approved the final version of this manuscript before submitting it to this journal.

Registration of research studies

This article is a case report. No trials or new experiment was conducted in this study.

Guarantor

The guarantor for this manuscript will be Dr. Kamal Basri Siregar, the corresponding author.

Provenance and peer review

Not commissioned, externally peer-reviewed.

References

- [1] M.B. McCarville, S.L. Spunt, A.S. Pappo, Rhabdomyosarcoma in pediatric patients: the good, the bad, and the unusual, *AJR Am. J. Roentgenol.* 176 (6) (2001) 1563–1569, <http://dx.doi.org/10.2214/ajr.176.6.1761563>.
- [2] Jonathan Noujaim, et al., Adult pleomorphic rhabdomyosarcoma: a multicentre retrospective study, *Anticancer Res.* 35 (2015) 6213–6218, Switzerland: s.n., 2015.
- [3] Mary A. Furlong, et al., Pleomorphic rhabdomyosarcoma in adults: a clinicopathologic study of 38 cases with emphasis on morphologic variant and recent skeletal muscle specific markers, *Mod. Pathol.* 4 (2001) 595–603.
- [4] D.J. Little, M.T. Ballo, G.K. Zagars, P.W. Pisters, S.R. Patel, A.K. El-Naggar, A.S. Garden, R.S. Benjamin, Adult rhabdomyosarcoma: outcome following multimodality treatment, *Cancer* 95 (2) (2002) 377–388, <http://dx.doi.org/10.1002/cncr.10669>.
- [5] Matthias Spalteholz, Jens Gulow, Pleomorphic rhabdomyosarcoma infiltrating thoracic spine in a 59-year-old female patient: Case report, *GMS Interdiscip. Plast. Reconstr. Surg. DGPW* 6 (2017).
- [6] Catalina Ruiz-Mesa, et al., Rhabdomyosarcoma in adults: new perspectives on therapy, *Curr. Treat. Opt. Oncol.* 16 (2015), 2, s.l.: Springer.
- [7] S.W. Weiss, J.R. Goldblum, in: S.W. Weiss, J.R. Goldblum (Eds.), *Enzinger and Weiss's Soft Tissue Tumors. Rhabdomyosarcoma*, 5th ed., Elsevier, St. Louis, 2008, pp. 595–632.
- [8] M. Miettinen, Rhabdomyosarcoma in patients older than 40 years of age, *Cancer* 62 (9) (1988) 2060–2065.
- [9] R.A. Agha, M.R. Borrelli, R. Farwana, K. Koshy, A. Fowler, D.P. Orgill, For the SCARE Group, The SCARE 2018 statement: updating consensus Surgical Case Report (SCARE) guidelines, *Int. J. Surg.* 60 (2018) 132–136.

Open Access

This article is published Open Access at [sciencedirect.com](https://www.sciencedirect.com). It is distributed under the [IJSCR Supplemental terms and conditions](#), which permits unrestricted non commercial use, distribution, and reproduction in any medium, provided the original authors and source are credited.