

Terminal ileum hemosiderosis secondary to prolonged oral iron ingestion

Georgios Mavrogenis^a, Julie Lelotte^b, Anne Jouret-Mourin^b, Kassem Azzouzi^a

Cliniques Universitaires Saint Luc, Université Catholique de Louvain, Brussels, Belgium

A 74-year-old Asian woman was referred for outpatient upper and lower endoscopic screening. She had history of hyperlipidemia and vegetarianism. Her medications included atorvastatin and self-medication of oral iron for the last 10 years. Routine blood tests were normal. Esophagogastroduodenoscopy was macroscopically and histologically normal. Colonoscopy disclosed diffuse brownish tiny spots of the mucosa of the terminal ileum (Fig. 1). Biopsy specimens showed pigment deposition at the level of the lamina propria (Fig. 2). A positive iron stain indicated hemosiderin deposition. Retrospective review of the patient's medical archives over the last 16 years revealed normal iron studies without any signs of iron deficiency anemia, hemolysis or hemochromatosis. She was consequently asked to discontinue iron supplements.

Hemosiderosis of the gastrointestinal tract is usually associated with hemochromatosis, chronic renal failure, diabetes, oral or parenteral iron therapy, multiple blood transfusions and several antihypertensive medications (primary hydralazine and furosemide). It has been described to affect the whole gastrointestinal tract, with the duodenum reported as the most common extracolonic site. A PubMed research revealed only 5 case reports of hemosiderosis isolated to the terminal ileum, associated with chronic oral iron intake (2 cases) and/or chronic renal failure (2 cases) or hemochromatosis (1 case) [1-3]. Gastroenterologists should be aware of this rare endoscopic entity and its association with long-term iron supplementation to avoid unnecessary further investigation.

Departments of ^aHepatogastroenterology (Georgios Mavrogenis, Kassem Azzouzi); ^bPathology (Julie Lelotte, Anne Jouret-Mourin), Cliniques Universitaires Saint Luc, Université Catholique de Louvain, Brussels, Belgium

Conflict of Interest: None

Correspondence to: Georgios Mavrogenis, Department of Hepatogastroenterology, Cliniques Universitaires Saint Luc, Université Catholique de Louvain, Avenue Hippocrate 10, 1200, Brussels, Belgium, Tel.: +32 474 458025, Fax: +32 027 648927, e-mail: mavrogenis@gmail.com

Received 11 October 2014; accepted 13 October 2014

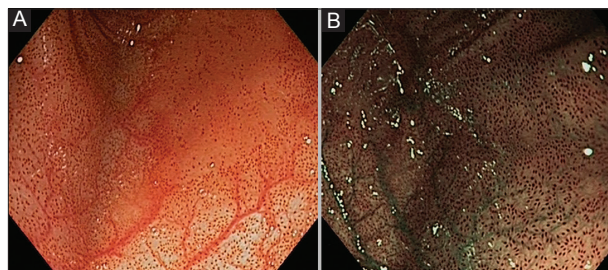


Figure 1 (A) Pigmented mucosa of the terminal ileum as seen by white light and (B) narrow-band imaging

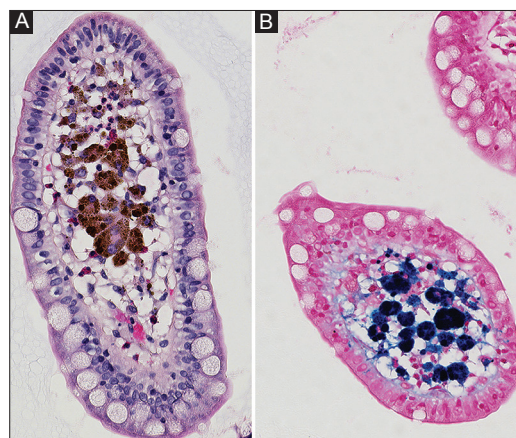


Figure 2 (A) Histology revealed brown pigment deposition within macrophages in lamina propria of normal villi (Hematoxylin-Eosin, 40x) (B) Positive Prussian blue stain suggesting hemosiderosis (40x)

References

1. Moore JD, Baichi M, Toledo R, Sitrin M. Pseudomelanosis of jejunum and ileum. *Gastrointest Endosc* 2007;**66**:857-859.
2. Kibria R, Ali SA, Akram S. Pseudomelanosis ilei associated with ingestion of oral iron therapy. *Endoscopy* 2010;**42**:E243-244.
3. Cha JM, Lee JI, Joo KR, Jung SW, Shin HP. Melanosis ilei associated with chronic ingestion of oral iron. *Gut Liver* 2009;**3**:315-317.