

Orbital exenteration under trigeminal block: An innovative method of regional anesthesia

Manjunath Timmappa Bhat,

Harihar V. Hegde,

M. C. B. Santhosh,

Raghavendra P. Rao,

Department of Anesthesiology,
SDM Medical College, Sattur,
Dharwad, India

Address for correspondence:

Dr. Manjunath T. Bhat,
Department of Anesthesiology,
SDM Medical College, Sattur,
Dharwad, Karnataka - 580 009, India.
E-mail: drmn05@gmail.com

ABSTRACT

Orbital exenteration is a disfiguring operation involving the removal of the entire contents of the orbit, with or without the eyelids. It is widely felt that such extensive surgery can only be performed under general anesthesia. We report our experience with a patient who underwent orbitalexenteration under trigeminal block with intravenous sedation. A 68-year-old male patient was diagnosed to have orbital cellulitis (mucormycosis), uncontrolled diabetes mellitus, ischemic heart disease, dilated cardiomyopathy with severe left ventricular systolic dysfunction with severe pulmonary artery hypertension, and nephropathy. We decided to avoid general anesthesia for such a high-risk patient with many co-morbid illnesses. We gave trigeminal block using a 22-G spinal needle with local anesthetic solution of bupivacaine 0.5% by classic approach. A standard exenteration was performed and the patient tolerated the procedure well with no complications.

Key words: *Orbital exenteration, trigeminal nerve anatomy, trigeminal nerve block*

INTRODUCTION

Orbital exenteration is an extensive surgery of the eye, which causes the disfigurement of the face. It involves the removal of the entire contents of the orbit, with or without the eyelids, and was first described by Gaisford in 1963.^[1] The most common indications for these surgeries are malignancies such as choroidal/lid/conjunctival melanoma,^[2,3] basal cell carcinoma,^[4] sebaceous or squamous cell carcinoma,^[5,6] lacrimal gland tumors,^[7] and sino-nasal tumors with orbital spread.^[8] It is also indicated in benign conditions such as end-stage socket contracture^[9] and infections such as mucormycosis.^[10] It is widely felt that such extensive surgery can only be performed under general anesthesia. There are very few cases in literature reporting the anesthetic management of orbital exenteration under local anesthesia with sedation, but there are no cases reporting orbital exenteration under trigeminal block. We report our experience with a patient who underwent orbital exenteration under trigeminal block with intravenous sedation.

CASE REPORT

A 68-year-old male patient was admitted with complaints of pain in the left eye associated with redness for 3 days, nasal block with discharge for 5 days, breathlessness for 10 days, and cough with expectoration for 10 days. He was diagnosed to have fungal rhino sinusitis (mucormycosis), orbital cellulitis (mucormycosis), uncontrolled diabetes mellitus, ischemic heart disease, dilated cardiomyopathy with severe left ventricular systolic dysfunction with severe pulmonary artery hypertension, and nephropathy. He was on treatment with insulin for diabetes, tablet ecospirin for ischemic heart disease, and injection amphotericin for fungal rhino sinusitis. He was proposed for left orbital exenteration surgery. On examination, the patient was drowsy. His pulse rate was 86/min, irregular in rhythm, and blood pressure measured in right arm in supine position was 100/60 mm Hg. There was swelling of left eye with discharge. Cardiovascular system examination showed split in second heart sound. Respiratory system examination showed bilateral extensive rhonchi and rales. Oxygen saturation on room air was 91-92%. Airway examination showed modified Mallampati score of 3. His fasting blood glucose was 409 mg/dl and random glucose level was 329 mg/dl. His hemoglobin was 10.7 gm/dl, blood urea was 92 mg/dl, and serum creatinine was 2.0 mg/dl. Serum sodium level was 133 mEq/L and potassium level was 3.5 mEq/L. ECG showed right bundle branch block pattern and Q wave in leads V1-V3. Echocardiography

Access this article online

Quick Response Code:



Website:

www.saudija.org

DOI:

10.4103/1658-354X.121051

showed global hypokinesia of left ventricle with left ventricular ejection fraction of 25%, severe pulmonary arterial hypertension, dilated cardiac chambers with apical clot in the right ventricle, and sclerosed aortic valve. Chest radiography showed features of cardiomegaly and congestive cardiac failure. Computed tomography (CT) scan of paranasal sinuses with orbit showed pan sinusitis and left orbital cellulitis with no intracranial extension. Considering the risk factors like congestive cardiac failure, sepsis, inadequate control of blood sugar, renal failure, and ischemic heart disease with poor left ventricular ejection fraction, grave risk consent was taken. All standard monitors like pulse oximetry, non-invasive blood pressure (NIBP) and ECG, were connected. Intravenous access was obtained with 18 G cannula. Oxygen was administered through nasal prongs.

Trigeminal block

The patient was placed in supine position with the head in neutral position and the eyes staring straight ahead. The anatomic landmark was marked at a point 3 cm lateral to the angle of the mouth on the left side. The skin over the cheek on the involved site was prepared with povidone-iodine and draped. A skin wheal was raised with a local anesthetic. A 22G, 10 cm-long spinal needle was inserted here [Figure 1] and advanced upward toward the mandibular condyle in a plane lining with the patient's pupil as the patient's eyes stared ahead, and the trajectory was cephalad toward the external auditory meatus. At a depth of 5 cm, the greater wing of the sphenoid at the base of the skull was contacted. The needle was withdrawn and redirected more posteriorly to enter the foramen ovale. It was then advanced 1.5 cm. Paresthesia at the mandible was elicited, followed by paresthesia in the maxilla and orbit. Before injecting the local anesthetic, the needle was carefully aspirated to check for cerebrospinal fluid (CSF) and 2 ml of lignocaine 2% with 5 ml of bupivacaine 0.5% was given. Supraorbital and supratrochlear block was given with 0.5%

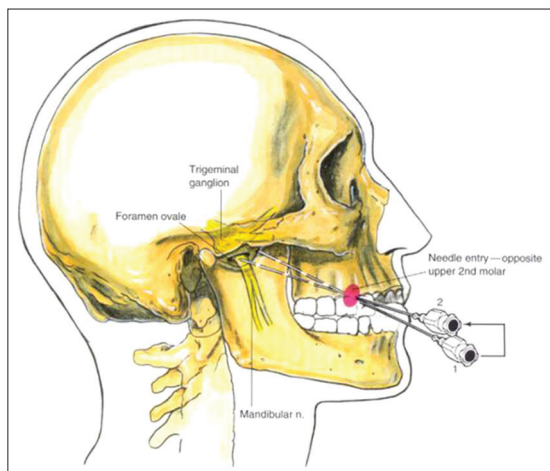


Figure 1: Trigeminal ganglion block technique

bupivacaine 3 ml each. Intravenous sedation was given with midazolam 1 mg and morphine 3 mg. Patient was monitored all the time during surgery. Oxygen saturation was between 97% and 98%, blood pressure was ranging from 100/60 to 110/60 mm Hg, and heart rate was between 90/min and 106/min. The patient was specifically monitored for signs of an oculo-cardiac reflex. A standard exenteration was performed and the patient tolerated the procedure well with no episodes of hypoxia or bradycardia. The patient was comfortable during surgery. Blood sugar was controlled with insulin 5 U bolus and at an infusion rate of 2U/h. Blood sugar was between 170 and 220 mg/dl. Postoperatively pain was controlled with injection tramadol 50 mg tid.

DISCUSSION

Orbital exenteration is commonly done in elderly friable patients with many co-morbid illnesses. It is commonly done under general anesthesia. Most patients requiring an exenteration are elderly, with significant co-morbidities, like in our patient who had uncontrolled diabetes mellitus, ischemic heart disease, dilated cardiomyopathy with severe left ventricular systolic dysfunction with severe pulmonary artery hypertension, and nephropathy, in which case general anesthesia poses significant risks. We decided to avoid general anesthesia for such a high-risk patient with many co-morbid illnesses. We planned for regional anesthesia and reviewed the literature for regional anesthesia for orbit exenteration. Sedation in the form of intravenous midazolam has previously been successfully used for the management of intraoperative anxiety during routine oculoplastic procedures performed on a day-case basis.^[11] Cook *et al.* reported five patients who underwent orbital exenteration under local anesthesia. In their study, local anesthesia was provided with a 10 ml peribulbar injection of bupivacaine 0.5% with adrenaline 1:200,000 and 5000 units of hyaluronidase. Thereafter, a further 10 ml injection of bupivacaine 0.5% with adrenaline 1:200,000 was infiltrated locally around the orbital rims to directly block the supratrochlear, supraorbital, infratrochlear, infra-orbital, anterior ethmoidal, zygomaticofacial, and zygomatico-temporal nerves. They demonstrated that such extensive orbital surgery can be carried out safely and satisfactorily in elderly patients.^[12] We reviewed the trigeminal nerve anatomy as the nerve supply of the eyeball is mainly by the branches of trigeminal nerve, namely, the supratrochlear, supraorbital, infratrochlear, infra-orbital, anterior ethmoidal, zygomaticofacial, and zygomatico-temporal nerves, as reported in Cook *et al.*'s study. We, therefore, wished to enhance this technique for the more extensive procedure of orbital exenteration, with the understanding of anatomy and technical considerations of trigeminal (gasserian ganglion) block.

Trigeminal nerve anatomy

The trigeminal nerve [Figure 2] is the largest cranial nerve, and is the great sensory nerve of the head and face and the motor nerve of the muscles of mastication.^[13] The fibers of the sensory root arise from the cells of the semilunar ganglion which lies in a cavity of the dura mater near the apex of the petrous part of the temporal bone. The trigeminal nerve ganglion (also referred to as the gasserian ganglion) lies in the trigeminal cave (also known as the Meckel's cave), which is a dural invagination in the petrous part of the temporal bone. The trigeminal ganglion is bounded medially by the cavernous sinus, superiorly by the inferior surface of the temporal lobe, posteriorly by the brainstem, and anteriorly by its exiting three branches (ophthalmic, maxillary, and mandibular).^[13] The dural pouch (trigeminal cistern) contains CSF and lies behind the ganglion. The postganglionic fibers are the sensory nerves to the face and exit via various foramina at the base of the skull. From the semilunar ganglion, the trigeminal nerve divides into three branches, ophthalmic, maxillary, and mandibular. The ophthalmic and maxillary nerves are purely sensory. The mandibular nerve has sensory and motor functions.

The ophthalmic nerve or first division of the trigeminal supplies branches to the cornea, ciliary body, and iris; to the lacrimal gland and conjunctiva; to part of the mucus membrane of the nasal cavity; and to the skin of the eyelids, eyebrow, forehead, and nose. Just before entering the orbit, through the superior orbital fissure, it divides into three branches, lacrimal, frontal, and nasociliary. The frontal nerve is the largest branch of the ophthalmic and divides into two branches, supratrochlear and supraorbital. The nasociliary branch gives rise to infratrochlear nerve.^[13]

The maxillary nerve or second division of the trigeminal carries sensory information from the lower eyelid and cheek, the nares and upper lip, the upper teeth and gums,

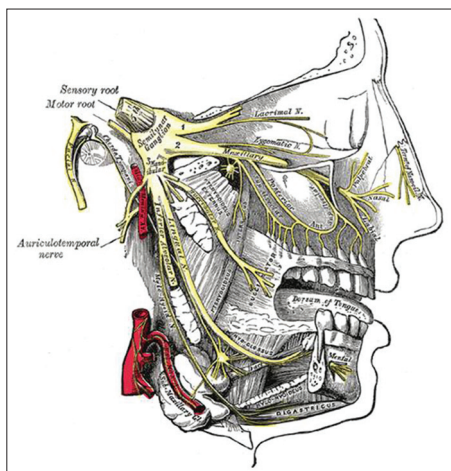


Figure 2: Trigeminal nerve anatomy

the nasal mucosa, the palate and roof of the pharynx, the maxillary, ethmoid, and sphenoid sinuses, and parts of the meninges. The maxillary nerve is divided into three branches: the zygomatic, pterygopalatine, and posterior superior alveolar nerves. The mandibular nerve supplies the teeth and gums of the mandible, the skin of the temporal region, the auricula, the lower lip, the lower part of the face, and the muscles of mastication; it also supplies the mucus membrane of the anterior two-thirds of the tongue.

Trigeminal (gasserian ganglion) block

Trigeminal nerve block provides hemi facial anesthesia and is used predominantly in the diagnosis and treatment of facial neuralgias like trigeminal neuralgia, post-herpetic neuralgia, and recalcitrant herpes zoster ophthalmicus.^[14,15] Although its principal use is as a diagnostic block before trigeminal neurolysis in patients with facial neuralgias, it is possible that the trigeminal ganglion block with local anesthetics can be used for surgical procedures involving the face in those patients with severe underlying cardiopulmonary disease.^[16] It is contraindicated in patients who have coagulation abnormalities or are taking anticoagulant drugs.

It is a relatively underused procedure, mainly owing to the difficulty of achieving a reliable block. Before proceeding with the block, one should have a precise knowledge of the anatomy, should be thoroughly familiar with the details of the procedure, and should be fully aware of the potential complications. Possible complications involve injecting local anesthetic into subarachnoid space owing to the close anatomic relation between trigeminal ganglion and the dural reflection. Likewise, the needle passes through highly vascular regions on its way to the foramen ovale, and hematoma formation is a possibility. The block can also be painful for the patient, and so, the patient may require effective sedation before final needle placement.

CONCLUSION

We conclude in our case report that orbital exenteration can be carried out safely and satisfactorily in elderly patients with co-morbid illnesses under trigeminal block with intravenous sedation.

REFERENCES

1. Gainsford JC, Hanna DC. Orbital Exenteration. *Plast Recon Surg* 1963;31:363-9.
2. Murthy GG, Ingole AB, Desai S. Malignant Melanoma in eviscerated Eyeball. *Clin Exp Ophthalmol* 2004;32:103-5.
3. Mittica N, Vemuganti GK, Duffy M, Torczynski E, Edward DP. Late recurrence of a choroidal melanoma following internal resection. *Survey Ophthalmol* 2003;48:181-90.
4. Bonner PK, Bregman DK, Mc Lean IW, LaPiana FG. Mixed

- type basal cell carcinoma of the eyelids. *Ophthalmol Plast Reconstr Surg* 1998;14:216-21.
5. Snow SN, Larson PO, Lucarelli MJ, Lemke BN, Madjar DD. Sebaceous carcinoma of the eyelids treated by mohs micrographic surgery. *Dermatol Surg* 2002;28:623-31.
 6. McElvie PA, Daniell M, McNabb A, Loughnan M, Santamaria JD. Squamous cell carcinoma of the conjunctiva. *Br J Ophthalmol* 2002;86:168-73.
 7. Becelli R, Carboni A, Cassoni A, Renzi G, Giancarlo R, Lanetti G. Pleomorphic adenoma of the lacrimal gland. *J Craniofac Surg* 2002;13:49-52.
 8. Bridger GP, Kwok B, Baldwin M, William J, Smee R. Craniofacial resection for paranasal sinus cancers. *Head Neck* 2002;22:772-80.
 9. Dolphin KW. Complications of Post nucleation/Evisceration Implants. *Curr Opin Ophthalmol*. 1998;9:75-7.
 10. Nithyanandam S, Jacob MS, Battu RR, Thomas PK, Correa MA, D'Souza O. Rhino-orbito-cerebral Mucormycosis. *Indian J Ophthalmol* 2003;51:231-6.
 11. Biswas S, Leatherbarrow B, Bhatnagar M, Rhatigan M, Kincell J, Slater R. Low dose midazolam infusion for oculoplastic surgery under local anesthesia. *Eye* 1999;13:537-40.
 12. Cook A, Slater RM, Leatherbarrow B. Orbital exenteration under local anesthesia with intravenous sedation. *Ophthalm Anesth News* 2004;10:6-8.
 13. Drake RL, Vogl AW, Mitchell AWM. Trigeminal nerve anatomy, *Gray's Anatomy for students*, 2nd ed. Churchill Livingstone, An Imprint of Elsevier; 2010, p. 851-52.
 14. Greenberg C, Papper EM. The indications for gasserian ganglion block for trigeminal neuralgia. *Anesthesiology* 1969;31:566-73.
 15. Peters G, Nurmikko TJ. Peripheral and gasserian ganglion-level procedures for the treatment of trigeminal neuralgia. *Clin J Pain* 2002;18:28-34.
 16. Brown DL, Trigeminal nerve block, *Atlas of Regional Anesthesia*, 3rd ed. Saunders, An Imprint of Elsevier; 2006. p. 159-63.

How to cite this article: Bhat MT, Hegde HV, Santhosh M, Rao RP. Orbital exenteration under trigeminal block: An innovative method of regional anesthesia. *Saudi J Anaesth* 2013;7:470-3.
Source of Support: Nil, **Conflict of Interest:** None declared.