


RESEARCH ARTICLE

Open Access



Randomized phase II study comparing the efficacy and safety of SOX versus mFOLFOX6 as neoadjuvant chemotherapy without radiotherapy for locally advanced rectal cancer (KSCC1301)

Keisuke Miwa¹, Eiji Oki^{2*} , Masanobu Enomoto³, Keisuke Ihara⁴, Koji Ando², Fumihiko Fujita⁵, Masahiro Tominaga⁶, Shinichiro Mori⁷, Goro Nakayama⁸, Mototsugu Shimokawa^{9,10}, Hiroshi Saeki¹¹, Hideo Baba¹², Masaki Mori² and Yoshito Akagi⁵

Abstract

Background: Preoperative chemoradiotherapy (CRT), the current standard of care for locally advanced rectal cancer (LARC), is associated with many radiotherapy (RT)-related side effects. We aimed to evaluate whether S-1 and oxaliplatin (SOX) or folinic acid, 5-FU, and oxaliplatin (mFOLFOX6) can be as effective as neoadjuvant chemotherapy (NAC) regimens for LARC without RT.

Methods: Patients with untreated resectable LARC were randomly assigned to receive SOX or mFOLFOX6. The NAC protocol period was 3 months. The primary endpoint was 3-year disease-free survival (DFS), and the secondary endpoints included pathological effects, surgical completion rate, 3-year survival, and safety.

Results: From September 2013 to October 2015, 56 and 54 patients were enrolled in the SOX and mFOLFOX6 arms, respectively. The 3-year DFS rates were 69.4% (95% confidence interval [CI] 54.9–83.6) and 73.4% (95% CI 58.7–83.6) in the SOX and mFOLFOX6 arms, respectively; no significant differences were found between the arms (log-rank test; $P = 0.5315$, hazard ratio: 0.808, 95% CI 0.414–1.578). The 3-year survival rates were 92.3 and 91.8% in the SOX and mFOLFOX6 arms, respectively. The surgical completion rate was 98.1% overall, 100% in the SOX arm, and 96.0% in the mFOLFOX6 arm. The incidences of pathological response rates \geq grade 1b were 41.5 and 43.8% in the SOX and mFOLFOX6 arms, respectively. Both treatments were manageable and tolerable.

Conclusion: We demonstrated the effectiveness and safety of SOX and mFOLFOX6, both of which may be new neoadjuvant treatment candidates in previously untreated LARC cases.

(Continued on next page)

* Correspondence: okieiji@surg2.med.kyushu-u.ac.jp

²Department of Surgery and Science, Graduate School of Medical Sciences, Kyushu University, Maidashi 3-1-1, Higashi-ku, Fukuoka 812-8582, Japan
Full list of author information is available at the end of the article



© The Author(s). 2021 **Open Access** This article is licensed under a Creative Commons Attribution 4.0 International License, which permits use, sharing, adaptation, distribution and reproduction in any medium or format, as long as you give appropriate credit to the original author(s) and the source, provide a link to the Creative Commons licence, and indicate if changes were made. The images or other third party material in this article are included in the article's Creative Commons licence, unless indicated otherwise in a credit line to the material. If material is not included in the article's Creative Commons licence and your intended use is not permitted by statutory regulation or exceeds the permitted use, you will need to obtain permission directly from the copyright holder. To view a copy of this licence, visit <http://creativecommons.org/licenses/by/4.0/>. The Creative Commons Public Domain Dedication waiver (<http://creativecommons.org/publicdomain/zero/1.0/>) applies to the data made available in this article, unless otherwise stated in a credit line to the data.

(Continued from previous page)

Trial registration: Date of enrolment of the first participant to the trial: 3rd Oct 2013; This study was registered in the UMIN clinical trials registry on 14th Aug, 2013. (Prospectively registered, UMIN-CTR number UMIN000011486). <https://upload.umin.ac.jp/cgi-open-bin/ctr/ctr.cgi?function=brows&recptno=R000013441&language=J>

Keywords: Rectal cancer, Neoadjuvant chemotherapy, Chemoradiotherapy, SOX, mFOLFOX6

Background

The incidence of colorectal cancer (CRC) is high worldwide, and the disease is third commonly occurring cancer of the United States, with rectal cancer accounting for approximately 30% of all CRCs [1]. Western countries have employed various treatment approaches for rectal cancer. The Swedish Rectal Cancer Trial showed significantly longer survival durations in association with preoperative short course radiation therapy (RT) than surgery alone [2, 3]. In a meta-analysis performed by Camma et al., who compared surgery alone with preoperative RT, the latter was associated with significantly prolonged survival durations and higher cancer-specific survival rates and significantly reduced local recurrence rates [4]. The efficacies of preoperative RT and preoperative chemoradiotherapy (CRT) were compared and reviewed in the EORTC trial 22,921, [5] FFCO 9203 trial, [6] and Polish 9203 trial [7]. Although none of the aforementioned studies showed that preoperative CRT was superior in terms of survival, the degree of downsizing, downstaging, and histological changes was significantly stronger after preoperative CRT, accompanied by a significant decrease in the rate of local recurrence. Based on the results of those clinical studies, Western guidelines recommend the use of preoperative RT or CRT for T3/T4 or N+ middle or low rectal cancer [8, 9]. However, although these preoperative treatments significantly improve local recurrence rates, no improvements in survival have been observed [10–13]. Bosset et al. reported 5 year local recurrence rates of 10.9 and 10.7% and 5 year distant recurrence rates of 32.1 and 29.8% in the CRT and CRT + adjuvant chemotherapy arms, respectively [14]. These results suggest that the suppression of distant metastasis is important for improving the survival of patients with locally advanced rectal cancer (LARC). Therefore, recently, the total neoadjuvant therapy (TNT)—characterized by the addition of systemic chemotherapy before or after CRT—has been focused to enhance the effectiveness of perioperative treatment [8, 15]. However, AEs, such as intestinal dysfunction, defecation dysfunction, sexual dysfunction, and secondary cancer occurrence, have been reported after preoperative RT. [16, 17] The toxicities caused by RT remain important concerns in such settings. A recent phase III trial examined the potential for the elimination of RT due to the effects of preoperative chemotherapy [18].

Several studies focusing on the use of preoperative chemotherapy with oxaliplatin-related regimens for rectal cancer have reported high radical resection rates (84–100%) [19–21]. Although the elimination of RT is expected to reduce the adverse event rates, there is a lack of sufficient data on the related outcomes. In particular, the use of preoperative chemotherapy, including S-1, an oral fluorinated pyrimidine for LARC, has not been investigated so far. In many clinical trials, chemotherapy using S-1 has demonstrated therapeutic results that are similar to those of chemotherapy using 5-fluorouracil (5-FU) for metastatic CRC [22–24]. We consider S-1 to be a fluorinated pyrimidine alternative to 5-FU with respect to patient preference and convenience. Therefore, we conducted a multicenter randomized phase II trial (KSCC1301) to evaluate whether S-1 and oxaliplatin (SOX) or folinic acid, 5-FU, and oxaliplatin (mFOLFOX6) are effective neoadjuvant chemotherapy (NAC) regimens without RT for LARC.

Methods

Patients

This trial adhered to the consort statement. This is a multicenter, open-label, randomized phase II trial. The inclusion criteria were as follows: presence of rectal or anal cancer with a low tumor border below the peritoneal reflection; histologically proven rectal anal adenocarcinoma; clinical T3–4 stage disease; clinical N0–2 disease; and M0 (TNM classification, 7th edition, 2010); however, the lymph node in the inferior mesenteric artery region was defined as N3 according to the Japanese Classification of Colorectal Carcinoma [25]; age ≥ 20 years; Eastern Cooperative Oncology Group performance status score 0–1; no prior chemotherapy or RT; ability to take medicine; and presence of adequate organ function. Patients were ineligible for participation if they had other primary tumors within the previous 5 years; serious cardiac disease; neurological disease; and renal, hepatic, or bone marrow dysfunction.

Signed informed consent form was obtained from all patients before enrollment to this study. The scientific and ethical aspects of the study were reviewed and approved by the institutional review board (IRB) in each participating institution. The study was conducted according to the principles of the Declaration of Helsinki, and was registered in the UMIN Clinical Trials Registry (UMIN000011486).

Randomization and masking

Patients were assigned randomly to (1:1) SOX or mFOLFOX6 arm at the data center of the Clinical Research Support Center Kyushu using the minimization method. Stratification factors were lymph node metastasis (N0 versus N1 and N2), depth of invasion (T3 versus T4) and institution. Of the series of treatments for LARC, including NAC, surgery, and adjuvant chemotherapy, the protocol treatment in this study was NAC. All patients received the protocol treatment within 14 days of enrollment in the study.

Procedure

In the SOX arm, S-1 + oxaliplatin was administered every 3 weeks (130 mg/m² oxaliplatin on day 1 and 80–120 mg oral S-1 on days 1–14). S-1 was administered orally at dosages according to the body surface area (BSA) (120 mg/day for BSA $\geq 1.50\text{m}^2$; 100 mg/day for BSA 1.25–1.50m²; 80 mg/day for BSA $< 1.25\text{m}^2$). The dosage was divided into two daily doses after meals. In the mFOLFOX6 arm, 5-FU and oxaliplatin were administered every 2 weeks (85 mg/m² oxaliplatin, 200 mg/m² leucovorin on day 1, followed by a 400 mg/m² bolus of 5-FU and a 46-h 2400 mg/m² 5-FU infusion).

Before surgery, patients were scheduled to receive four cycles in the SOX arm and six cycles in the mFOLFOX6 arm. However, imaging tests were performed after two cycles in the SOX arm and three cycles in the mFOLFOX6 arm for the evaluation of whether the tumor had grown and whether radical resection was possible. If chemotherapy could be continued, two cycles were added to the SOX arm and three cycles to the mFOLFOX6 arm. Toxicity was evaluated before the start of each cycle, according to the National Cancer Institute Common Terminology Criteria (NCI-CTC) for Adverse Events version 4.0.

After NAC, radical resection was finally evaluated by performing imaging tests, and if surgery was possible, total mesorectal excision (TME) with lymph node dissection was performed. Regarding the implementation of lateral lymph node dissection, the participating facilities made decisions based on their own criteria. Postoperative adjuvant chemotherapy was started within 8 weeks using the same regimen as preoperative chemotherapy with four cycles in the SOX arm and six cycles in the mFOLFOX6 arm. After completing adjuvant chemotherapy, surveillance was conducted to check for recurrence.

Statistical analysis

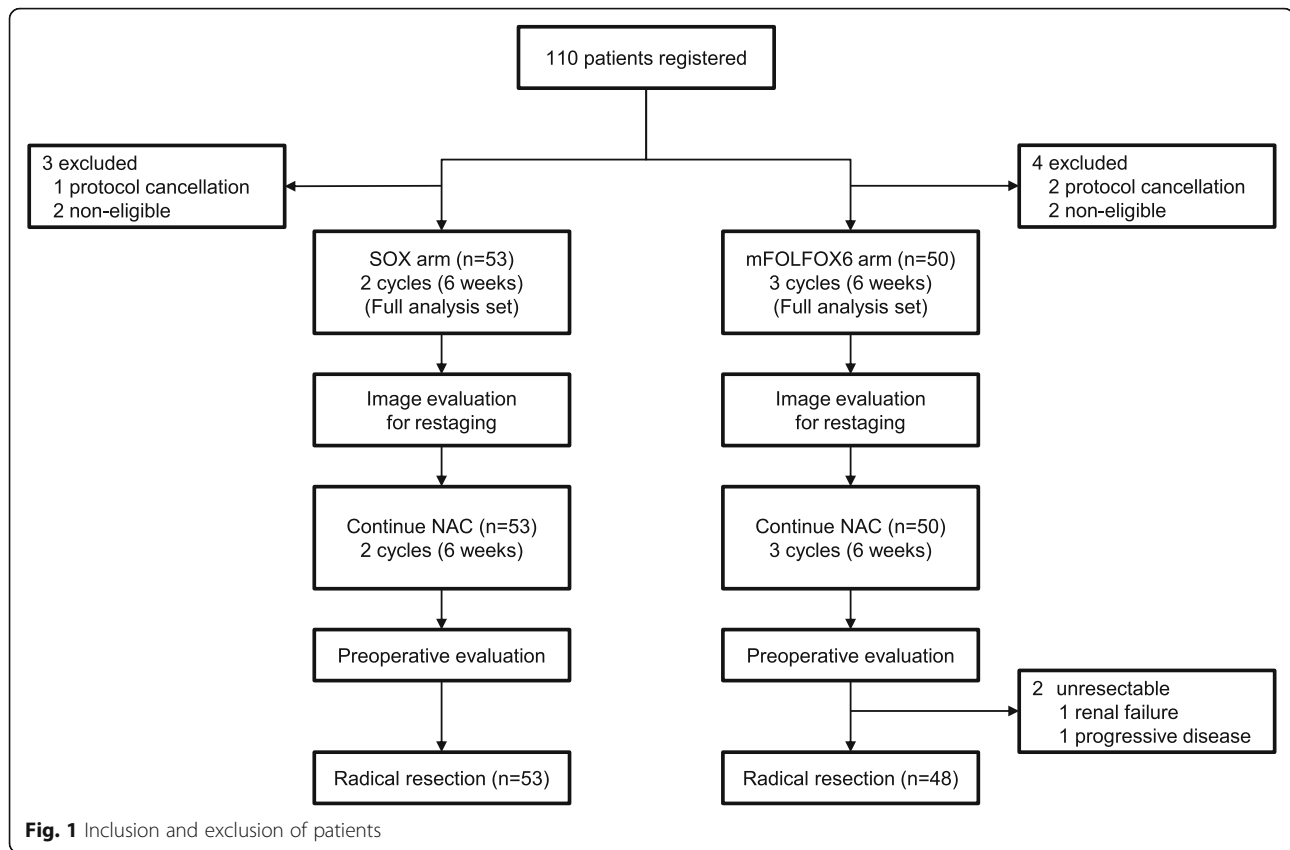
Three-year disease-free survival (DFS) was the primary endpoint. The secondary endpoints were pathological response rate, surgical completion rate, overall survival (OS) rate, and safety. This study assessed the efficacy and safety of NAC without RT using SOX or mFOLFOX6

for LARC and assessed comprehensively selected candidates in a phase III study. In the primary analysis, the 3-year DFS point estimates for the two treatments were calculated, and if one exceeded the other by more than 10%, it was determined to be a promising treatment. However, if the difference was lower than 10%, a decision was made about the right treatment option, which was deemed more likely to succeed by taking the toxicity of both into consideration. In this study, the 3-year DFS was set at 65% on the basis of previous large-scale clinical trials of preoperative RT for rectal cancer [5–7] and comprehensive evaluation of the treatment results at the participating facilities. To ensure that the probability of the accurate selection of the better treatment arm was $\geq 85\%$ when the 3-year DFS exceeded 65% by at least 10%, the number of cases required was 46 for each arm, using Simon's selection design. Finally, considering some withdrawals and cases that were deemed ineligible to receive preoperative chemotherapy, the target sample size was set as 110 cases, 55 cases in each arm. The registration period was 3 years, and the follow-up period was 5 years. DFS was defined as the duration from the date of surgery to the diagnosis of recurrence or any cause of death or the occurrence of a secondary cancer, whichever occurred first. OS was defined as the duration from the date of surgery until death of any cause. DFS and OS curves were created using the Kaplan–Meier method, and the 95% confidence intervals (CIs) were estimated using Greenwood's formula. For primary endpoint, a one-sided *p* value less than 0.05 was considered significant in statistical tests. Statistical analyses were done by SAS version 9.4 software (SAS Institute, Cary, NC).

Results

Overall, 110 patients were enrolled at 39 sites from September 2013 to October 2015. Although 56 and 54 patients were enrolled in the SOX and mFOLFOX6 arms, respectively, 7 patients did not meet the eligibility criteria. In total, 53 patients in the SOX arm and 50 in the mFOLFOX6 arm received NAC. Therefore, 103 patients were included in the primary endpoint analysis as the full analysis set (Fig. 1). All cases were lower rectal adenocarcinoma, and no case of anal adenocarcinoma was enrolled. The patients' baseline characteristics at the time of registration were well balanced (Table 1). The data cutoff point was October 2018, and median follow-up for DFS, which was the primary endpoint, was 43.3 months (range, 4.2–58.3 months).

The 3-year DFS rates 69.4% (95% CI, 54.9–83.6) and 73.4% (95% CI, 58.7–83.6) in the SOX and mFOLFOX6 arms, respectively. A significant difference was not found between the two arms (log-rank test; *p* = 0.5315; hazard ratio [HR], 0.808; 95% CI, 0.414–1.578) (Fig. 2a). The difference in the DFS rate between the SOX and mFOLFOX6



arms was 4.0% (less than 10%). The 3-year survival rates for the secondary endpoint were 92.3% (95% CI, 80.7–97.0) and 91.8% (95% CI, 79.8–96.9) in the SOX and mFOLFOX6 arms, respectively. No significant difference was found between the two arms (log-rank test; $p = 0.6897$; HR, 1.307; 95% CI, 0.350–4.876) (Fig. 2b).

A total of 101 patients underwent TME with lymphadenectomy; 31 of them underwent lateral lymph node dissection. The surgical completion rate was 98.1% (103 of 105) overall, 100% (53 of 53) in the SOX arm, and 96.0% in the mFOLFOX6 arm (48 of 50). Of the two cases in which radical resection failed, one was assessed as unresectable disease on the basis of second preoperative imaging, and the other was considered as being difficult to operate because of renal failure. The incidences of a pathological response rate of grade 1b or higher of NAC [25] were 41.5% (22 of 53) and 43.8% (21 of 48) in the SOX and mFOLFOX6 arms, respectively (Table 2). There was no significant difference between the regimens (log-rank test; $p = 0.7442$).

The incidence of AEs of all grades was 100% in both arms. The incidences of AEs of grade 3 or higher were 29.5 and 34.2% in the SOX and mFOLFOX6 arms, respectively. The AEs of grade 3 or higher that occurred in the SOX arm are shown in Table 3. The major AEs were thrombocytopenia (18.9%) and neutropenia (13.2%). In

the mFOLFOX6 arm (Table 4), they were neutropenia (32.0%) and leukopenia (6.0%).

The occurrence rates of perioperative complications of grade II or higher according to the Clavien-Dindo classification [26] were 37.7 and 18.6% in the SOX and mFOLFOX6 arms, respectively (Table 5). In particular, the SOX arm had a larger number of infection-related complications, including intestinal anastomotic leakage, intra-abdominal abscess, and wound infection, than the mFOLFOX6 arm. No grade IV or higher complications according to the Clavien-Dindo classification were observed in both arms. Finally, 44 (83.0%) and 38 (79.2%) patients in the SOX and mFOLFOX6 arms, respectively, received postoperative adjuvant chemotherapy.

Discussion

In the present study, we found that SOX and mFOLFOX6 as NAC without RT are effective and safe in LARC settings. Regarding NAC, we selected an oxaliplatin-based regimen that is effective against metastatic CRC and reportedly has a high R0 resection rate even in preoperative chemotherapy. Specifically, for convenience, we decided to compare the mFOLFOX6 regimen, widely used in metastatic CRC, with the SOX regimen, containing oral fluorinated pyrimidine. Although SOX and mFOLFOX6 have been demonstrated to show similar therapeutic

Table 1 Patient characteristics

Characteristics	SOX arm n=53 (%)	mFOLFOX6 arm n=50 (%)	p-value
Age (years)			
Median (range)	63 (37–79)	64 (36–79)	0.3440
Sex			
Male	44 (83.0)	40 (80.0)	0.6930
Female	9 (17.0)	10 (20.0)	
Performance status (ECOG)			
0	53 (100.0)	48 (96.0)	0.2332
1	0 (0.0)	2 (4.0)	
Depth of wall invasion			
T3	39 (73.6)	37 (74.0)	0.9618
T4	14 (26.4)	13 (26.0)	
Lymph node metastasis			
N0	20 (37.7)	16 (32.0)	0.6317
N1	20 (37.7)	20 (40.0)	
N2	13 (24.5)	12 (24.0)	
N3 ^a	0 (0.0)	2 (4.0)	
RAS status			
Unexamined	37 (70.0)	36 (72.0)	0.5945
Wild	8 (15.1)	11 (22.0)	
Mutant	8 (15.1)	3 (6.0)	
Past illness/comorbidity			
Yes	23 (43.4)	23 (46.0)	1.0000
Cerebral infarction	2 (3.8)	3 (6.0)	
Myocardial infarction	1 (1.9)	0 (0.0)	
Hypertension	15 (28.3)	14 (28.0)	
Diabetes	8 (15.1)	8 (16.0)	
Others	11 (20.8)	11 (22.0)	

^aLymph node in the inferior mesenteric artery region,

ECOG: Eastern Cooperative Oncology Group, SOX: 5-FU and oxaliplatin, mFOLFOX6: folinic acid, 5-FU, and oxaliplatin

effects in metastatic CRC, [24] no study to date has evaluated the therapeutic outcomes of SOX as an NAC regimen for LARC.

In this study, the 3-year DFS rates were 69.4 and 73.4% in the SOX and mFOLFOX6 arms, respectively. The 3-year DFS rates in a previous pivotal phase III trial using CRT for rectal cancer were 60–70% based on Kaplan–Meier curves, [5, 7] similar to our findings. In a recent phase III trial (FOWARC trial) conducted in China, the efficacies of infusional 5-FU + RT + TME, mFOLFOX6 + RT + TME, and mFOLFOX6 + TME were compared; the 3-year DFS rates were 72.9, 77.2, and 73.5%, respectively, and the 3-year OS rates were 91.3, 89.1, and 90.7%, respectively [27]. In terms of the 3-year DFS rate, which was the primary endpoint, no difference was noted between the three arms, but the

pathological complete response rate was significantly higher in the mFOLFOX6 + RT arm [28]. In our study, the 3-year OS rates were 92.3 and 91.8% in the SOX and mFOLFOX6 arms, respectively, and the 3-year DFS and 3-year OS rates were comparable to those in the FOWARC trial. Therefore, although no difference greater than 10% was observed between both arms, we considered that the treatment outcomes were satisfactory in both arms. Further follow-up is required in the future.

The overall rate of transition to radical resection in this study was 98.1% (103 of 105), which is a satisfactory result. According to the results of two Japanese prospective studies reporting the efficacy of capecitabine + oxaliplatin + bevacizumab as NAC for LARC, the surgical completion rates were 92% (23 of 25) [8] and 84% (27 of 32) [21]. Although the characteristics of our

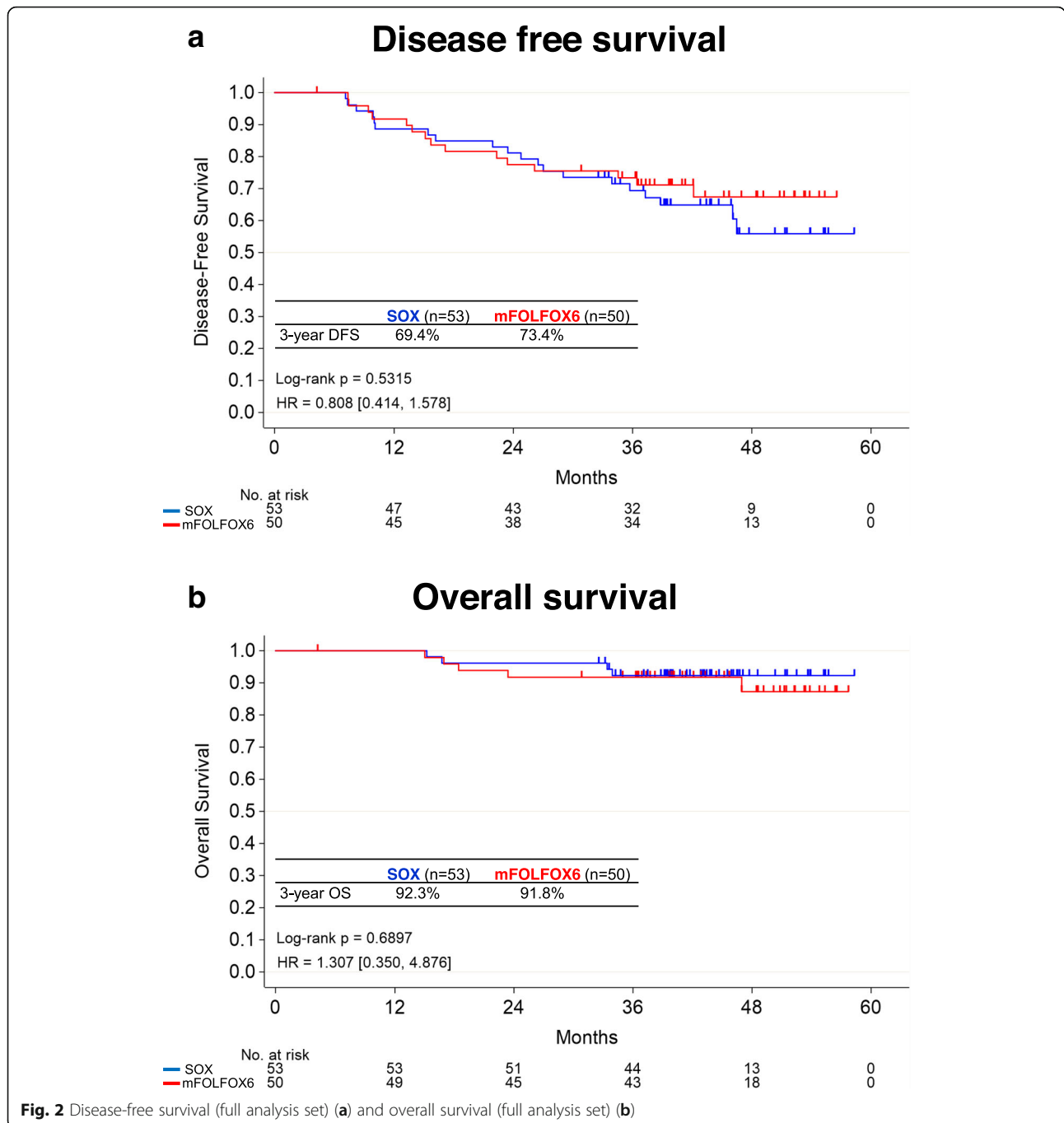


Fig. 2 Disease-free survival (full analysis set) (a) and overall survival (full analysis set) (b)

participants were different, the surgical completion rate in the SOX arm of this study was 100% (53 of 53), suggesting the effectiveness of SOX as an NAC regimen for LARC. In addition, there was no significant difference in the pathological effectiveness between the regimens, and we believe that it is acceptable to select either as an NAC regimen.

The AEs that occurred in both the regimens were the same as those noted in previously reported clinical phase III trials [29, 30] and are within expectations. Both

treatments were manageable and tolerable. In terms of perioperative complications, infection-related complications were more commonly observed in the SOX arm than in the mFOLFOX6 arm, but the cause was unknown. However, complications that were grade IV or higher according to the Clavien-Dindo classification were not observed in both arms. In addition, the transition rate to postoperative adjuvant chemotherapy was comparable between the arms (83.0% versus 79.2%). These results indicate the safety of both regimens.

Table 2 Pathological response rate

	SOX arm n=53 (%)	mFOLFOX6 arm n=48 (%)	Total n=101 (%)
Grade 0	6 (11.3)	5 (10.4)	11 (10.9)
Grade 1a	24 (45.3)	22 (45.8)	46 (45.6)
Grade 1b	12 (22.6)	8 (16.7)	20 (19.8)
Grade 2	8 (15.1)	12 (25.0)	20 (19.8)
Grade 3	2 (3.8)	1 (2.1)	3 (3.0)
Unknown	1 (1.9)	0 (0.0)	1 (1.0)

SOX: S-1 and oxaliplatin, mFOLFOX6: folinic acid, 5-FU, and oxaliplatin

In Japan, D3 dissection with lateral lymph nodes, which preserves pelvic autonomic nerve function without preoperative CRT, and subsequent adjuvant chemotherapy are widely used to improve the outcomes of patients with LARC [31]. Mizushima et al. reported that the 3-year DFS rate was 70.1% in a phase II study of 107 patients with high-risk stage II and stage III rectal cancer without preoperative treatment who had received capecitabine + oxaliplatin therapy as postoperative adjuvant chemotherapy, [32] similar to the findings of our study. There is controversy surrounding whether chemotherapy for LARC should be performed before or after TME in Japan; this issue needs to be resolved in a future phase III study.

Our study has some limitations. First, it had a phase II study design; it is necessary to plan a phase III trial that compares the efficacy of NAC with preoperative CRT or postoperative adjuvant chemotherapy. The standard treatment for LARC is CRT. The regimens used in this study are by no means a substitute for CRT. Second, the incidences of distant metastases and survival were not evaluated because of the insufficient follow-up period. Third, RT was not used. In this study, we selected an RT-free approach to avoid the side effects of RT and to

Table 3 Adverse events \geq grade 3 in the SOX arm (n=53)

	All grades n (%)	Grade 3–4 n (%)
Laboratory findings		
Thrombocytopenia	49 (92.5)	10 (18.9)
Neutropenia	42 (79.2)	7 (13.2)
Anemia	47 (88.7)	1 (1.9)
Hypoalbuminemia	46 (86.8)	1 (1.9)
Increased AST	42 (79.2)	1 (1.9)
Hyponatremia	23 (43.4)	1 (1.9)
Clinical findings		
Anorexia	25 (47.2)	2 (3.8)
Paresthesia	36 (67.9)	1 (1.9)
Fatigue/malaise	21 (39.6)	1 (1.9)

AST: aspartate aminotransferase, SOX: S-1 and oxaliplatin

Table 4 Adverse events \geq grade 3 in the mFOLFOX6 arm (n=50)

	All grades n (%)	Grade 3–4 n (%)
Laboratory findings		
Neutropenia	39 (78.0)	16 (32.0)
Leukopenia	28 (56.0)	3 (6.0)
Anemia	41 (82.0)	2 (4.0)
Hypoalbuminemia	44 (88.0)	2 (4.0)
Hyponatremia	18 (36.0)	2 (4.0)
Increased AST	38 (76.0)	1 (2.0)
Hypokalemia	14 (28.0)	1 (2.0)
Hyperkalemia	12 (24.0)	1 (2.0)
Clinical findings		
Anorexia	25 (50.0)	2 (4.0)
Catheter related		
Infection	2 (4.0)	2 (4.0)
Fatigue/malaise	23 (46.0)	1 (2.0)
Nausea	21 (42.0)	1 (2.0)
Diarrhea	21 (42.0)	1 (2.0)
Vascular disorder	1 (2.0)	1 (2.0)
Hyperglycemia	1 (2.0)	1 (2.0)

AST: aspartate aminotransferase, mFOLFOX6: folinic acid, 5-FU, and oxaliplatin

Table 5 Perioperative complications \geq grade II per the Clavien-Dindo classification

	SOX arm n=53 (%)	mFOLFOX6 arm n=48 (%)	Total n=101 (%)
Postoperative hemorrhage			
IIIa	0 (0.0)	1 (2.1)	1 (1.0)
Intestinal anastomotic leakage			
II	1 (1.9)	1 (2.1)	2 (2.0)
IIIa	1 (1.9)	0 (0.0)	1 (1.0)
IIIb	4 (7.5)	0 (0.0)	4 (4.0)
Intra-abdominal abscess			
II	1 (1.9)	0 (0.0)	1 (1.0)
IIIa	3 (5.7)	0 (0.0)	3 (3.0)
IIIb	2 (3.8)	0 (0.0)	2 (2.0)
Wound infection			
II	4 (7.5)	1 (2.1)	5 (5.0)
IIIa	2 (3.8)	1 (2.1)	3 (3.0)
Ileus			
IIIa	1 (1.9)	2 (4.2)	3 (3.0)
IIIb	1 (1.9)	2 (4.2)	3 (3.0)
Pneumonia			
II	0 (0.0)	1 (2.1)	1 (1.0)

SOX: S-1 and oxaliplatin, mFOLFOX6: folinic acid, 5-FU, and oxaliplatin

determine if a recently developed chemotherapy regimen could be used in a study arm compete with future CRTs. Further, the therapeutic efficacy of chemotherapy using these regimens as TNT remains unclear. We believe that these two regimens are worth assessing as TNT for LARC in the future.

This study demonstrated the efficacy of SOX and mFOLFOX6 containing oral fluoropyrimidine as NAC regimens for resectable LARC. Data on NAC without RT for T3–T4, N0–N2 resectable rectal cancer are currently very limited. Therefore, we believe that our study is extremely valuable because it provides data on the use of NAC without RT for rectal cancer.

Conclusion

SOX and mFOLFOX6 as NAC regimens without RT are effective and safe and may be new neoadjuvant treatment candidates in LARC settings.

Abbreviations

CRT: chemoradiotherapy; LARC: locally advanced rectal cancer; SOX: S-1 and oxaliplatin; mFOLFOX6: folinic acid, 5-FU, and oxaliplatin; NAC: neoadjuvant chemotherapy; RT: radiotherapy; DFS: disease-free survival; CRC: colorectal cancer; TNT: total neoadjuvant therapy; NCI-CTC: National Cancer Institute Common Terminology Criteria; TME: total mesorectal excision; CIs: confidence intervals (CIs); AEs: Adverse events

Acknowledgments

We express our gratitude to all the patients participated in this randomized study. We are grateful to all the physicians at the participating institutions. We also thank secretaries especially Ms. Sanae Sakamoto for their assistance at the data center.

Consent to participate

Not applicable.

Authors' contributions

KM and EO drafted the manuscript. EO, MS, HS, HB, MM and YA were involved in conception and design. MS and EO were involved in analysis and interpretation of data. ME, KI, KA, FF, MT, SM and GN were involved in data collection. All authors contributed in review, revise and approve the manuscript; and agree to be accountable to all aspects of the work.

Funding

This study was funding from Taiho Pharmaceutical Co. Ltd. under a research contract, and supported by KSCC (Kyushu study group of clinical cancer) as a division of Clinical Study and data center. The funders had no role in the design of the study and collection, analysis, and interpretation of data and in writing the manuscript.

Availability of data and materials

The datasets used and/or analysed during the current study are available from the corresponding author on reasonable request.

Ethics approval and consent to participate

This study was conducted in accordance with the Declaration of Helsinki and Ethical Guidelines for Clinical Studies in Japan, and the protocol was approved by the institutional review boards of all participating medical institutions; Tokyo Medical University Hospital, Dokkyo Medical University Hospital, Kyushu University Hospital, Kurume University, Hyogo Prefectural Cancer Center, Kagoshima University Hospital, Nagoya University Hospital, Fukuoka City Hospital, Nagasaki University Hospital, Kagoshima Kouseiren Hospital, Kitaharima General Medical Center, Saieikai Karatsu Hospital, Toho University Ohmori Hospital, Kumamoto University, JCHO Hitoyoshi Medical Center, Kyushu Medical Center, Kakizoe Hospital, Oita University Hospital, Iizuka Hospital, Okayama Rosai Hospital, St Marianna University School of

Medicine, Sasebo City General Hospital, Aichi Prefectural Cancer Center Hospital, Oita Medical Center, Saieikai Sendai Hospital, Kumamoto Medical Center, Imari Arita Kyouritsu Hospital, Tagawa City Hospital, Nagoya Medical Center, Kobe City Medical Center, Uraoe General Hospital, JCHO Kurume General Hospital, Matsuyama Red Cross Hospital, Fukui Saiseikai Hospital, Amakusa Medical Center Hospital. Patients decided whether or not they would participate in the trial after being given a detailed explanation, and written informed consent was obtained from all patients prior to enrolment.

Consent for publication

The informed consent form stated that the result would publish after completed the study. Japanese regulation. The consent of the family is not be demanded at article publication by the ethic guideline in Japan.

Competing interests

Outside the submitted work, Keisuke Miwa received grants and personal fees from Taiho Pharm., Ono Pharm., Chugai Pharm. and Takeda Pharm., grants from Merck Biopharm. and Pfizer Inc. and Tsumura & Co.; personal fees from Yakult Honsha Co., Ltd., Bristol-Myers Squibb Co. and Novartis Pharma K.K., personal fees from AstraZeneca K.K., Kyowa Kirin Co., Ltd., Nippon Kayaku Co., Ltd. and Eli Lilly. Outside the submitted work, Eiji Oki received personal fees from Taiho Pharm, Bayer, Chugai Pharm., Takeda Pharm., Ono Pharm., Merck Biopharma, MSD and Yakult Honsha. Outside the submitted work, Goro Nakayama received personal fees from Chugai Pharm., Janssen Pharmaceutical K.K., Yakult Honsha Co. Ltd., Taiho Pharm., Eli Lilly Japan K.K., Takeda Pharm., and Miyarinsan Pharm. Mototsugu Shimokawa received personal fees from Sysmex outside the submitted work. The other authors have no conflicts of interest to declare.

Author details

¹Multidisciplinary Treatment Cancer Center, Kurume University Hospital, Kurume, Japan. ²Department of Surgery and Science, Graduate School of Medical Sciences, Kyushu University, Maidashi 3-1-1, Higashi-ku, Fukuoka 812-8582, Japan. ³Gastrointestinal and Pediatric Surgery, Tokyo Medical University, Tokyo, Japan. ⁴First Department of Surgery, Dokkyo Medical University, Tochigi, Japan. ⁵Department of Surgery, Kurume University School of Medicine, Kurume, Japan. ⁶Department of Gastroenterological Surgery, Hyogo Cancer Center, Nishinomiya, Japan. ⁷Department of Digestive Surgery, Breast and Thyroid Surgery, Kagoshima University, Kagoshima, Japan. ⁸Department of Gastroenterological Surgery, Graduate School of Medicine, Nagoya University, Nagoya, Japan. ⁹Cancer Biostatistics Laboratory, Clinical Research Institute, National Hospital Organization Kyusyu Cancer Center, Fukuoka, Japan. ¹⁰Department of Biostatistics, Yamaguchi University Graduate School of Medicine, Ube, Japan. ¹¹Department of Gastroenterological Surgery, Gunma University Graduate School of Medicine, Maebashi, Japan. ¹²Department of Gastroenterological Surgery, Kumamoto University Graduate School of Medicine, Kumamoto, Japan.

Received: 30 September 2020 Accepted: 23 December 2020

Published online: 05 January 2021

References

1. Siegel R, Desantis C, Jemal A. Colorectal cancer statistics, 2014. *CA Cancer J Clin* 2014;64:104–117. <https://doi.org/https://doi.org/10.3322/caac.21220>.
2. Pahlman L, Glimelius B. Improved survival with preoperative radiotherapy in resectable rectal cancer. *N Engl J Med* 1997;336:980–987. <https://doi.org/https://doi.org/10.1056/NEJM199704033361402>.
3. Folkesson J, Birgisson H, Pahlman L, et al. Swedish rectal cancer trial: long lasting benefits from radiotherapy on survival and local recurrence rate. *J Clin Oncol* 2005;23:5644–5650. <https://doi.org/https://doi.org/10.1200/JCO.2005.08.144>.
4. Camma C, Giunta M, Fiorica F, Pagliaro L, Craxi A, Cottone M. Preoperative radiotherapy for resectable rectal cancer: a meta-analysis. *JAMA* 2000;284:1008–1015. <https://doi.org/https://doi.org/10.1001/jama.284.8.1008>.
5. Bosset JF, Collette L, Calais G, et al. Chemotherapy with preoperative radiotherapy in rectal cancer. *N Engl J Med* 2006;355:1114–1123. <https://doi.org/https://doi.org/10.1056/NEJMoa060829>.
6. Gerard JP, Conroy T, Bonnetain F, et al. Preoperative radiotherapy with or without concurrent fluorouracil and leucovorin in T3-4 rectal cancers: results of FFCD 9203. *J Clin Oncol* 2006;24:4620–4625. <https://doi.org/https://doi.org/10.1200/JCO.2006.06.7629>.

7. Bujko K, Nowacki MP, Nasierowska-Guttmejer A, Michalski W, Bebenek M, Kryj M. Long-term results of a randomized trial comparing preoperative short-course radiotherapy with preoperative conventionally fractionated chemoradiation for rectal cancer. *Br J Surg* 2006;93:1215–1223. <https://doi.org/https://doi.org/10.1002/bjs.5506>.
8. Benson AB, Venook AP, Al-Hawary MM, et al. Rectal Cancer, version 2.2018, NCCN clinical practice guidelines in oncology. *J Natl Compr Cancer Netw* 2018;16:874–901. <https://doi.org/https://doi.org/10.6004/jnccn.2018.0061>.
9. Glynn-Jones R, Wyrwicz L, Turet E, et al. Rectal cancer: ESMO Clinical Practice Guidelines for diagnosis, treatment and follow-up. *Ann Oncol* 2017;28:iv22–iv40. <https://doi.org/https://doi.org/10.1093/annonc/mdx224>.
10. Kapiteijn E, Marijnen CA, Nagtegaal ID, et al. Preoperative radiotherapy combined with total mesorectal excision for resectable rectal cancer. *N Engl J Med* 2001;345:638–646. <https://doi.org/https://doi.org/10.1056/NEJMoa010580>.
11. Peeters KC, Marijnen CA, Nagtegaal ID, et al. The TME trial after a median follow-up of 6 years: increased local control but no survival benefit in irradiated patients with resectable rectal carcinoma. *Ann Surg* 2007;246:693–701. <https://doi.org/https://doi.org/10.1097/01.sla.0000257358.56863.ce>.
12. Sauer R, Liersch T, Merkel S, et al. Preoperative versus postoperative chemoradiotherapy for locally advanced rectal cancer: results of the German CAO/ARO/AIO-94 randomized phase III trial after a median follow-up of 11 years. *J Clinical Oncol* 2012;30:1926–1933. <https://doi.org/https://doi.org/10.1200/JCO.2011.40.1836>.
13. van Gijn W, Marijnen CA, Nagtegaal ID, et al. Preoperative radiotherapy combined with total mesorectal excision for resectable rectal cancer: 12-year follow-up of the multicentre, randomised controlled TME trial. *Lancet Oncol* 2011;12:575–582. [https://doi.org/https://doi.org/10.1016/S1470-2045\(11\)70097-3](https://doi.org/https://doi.org/10.1016/S1470-2045(11)70097-3).
14. Bosset JF, Calais G, Mineur L, et al. Fluorouracil-based adjuvant chemotherapy after preoperative chemoradiotherapy in rectal cancer: long-term results of the EORTC 22921 randomised study. *Lancet Oncol* 2014;15:184–190. [https://doi.org/https://doi.org/10.1016/S1470-2045\(13\)70599-0](https://doi.org/https://doi.org/10.1016/S1470-2045(13)70599-0).
15. Goodman KA. Total neoadjuvant therapy for rectal cancer. *Cancer Radiother* 2018;22:459–465. <https://doi.org/https://doi.org/10.1016/j.canrad.2018.01.004>.
16. Birgisson H, Pahlman L, Gunnarsson U, Glimelius B. Occurrence of second cancers in patients treated with radiotherapy for rectal cancer. *J Clin Oncol* 2005;23:6126–6131. <https://doi.org/https://doi.org/10.1200/JCO.2005.02.543>.
17. Peeters KC, van de Velde CJ, Leer JW, et al. Late side effects of short-course preoperative radiotherapy combined with total mesorectal excision for rectal cancer: increased bowel dysfunction in irradiated patients—a Dutch colorectal cancer group study. *J Clinical Oncol* 2005;23:6199–6206. <https://doi.org/https://doi.org/10.1200/JCO.2005.14.779>.
18. Weiser MR, Fichera A, Schrag D, Boughey JC, You YQ. Progress in the PROSPECT trial: precision treatment for rectal cancer? *Bull Am Coll Surg* 2015;100:51–2.
19. Hasegawa J, Nishimura J, Mizushima T, et al. Neoadjuvant capecitabine and oxaliplatin (XELOX) combined with bevacizumab for high-risk localized rectal cancer. *Cancer Chemother Pharmacol* 2014;73:1079–1087. <https://doi.org/https://doi.org/10.1007/s00280-014-2417-9>.
20. Schrag D, Weiser MR, Goodman KA, et al. Neoadjuvant chemotherapy without routine use of radiation therapy for patients with locally advanced rectal cancer: a pilot trial. *J Clin Oncol* 2014;32:513–518. <https://doi.org/https://doi.org/10.1200/JCO.2013.51.7904>.
21. Uehara K, Hiramatsu K, Maeda A, et al. Neoadjuvant oxaliplatin and capecitabine and bevacizumab without radiotherapy for poor-risk rectal cancer: N-SOG 03 phase II trial. *Jpn J Clin Oncol* 2013;43:964–971. <https://doi.org/https://doi.org/10.1093/jco/hyt115>.
22. Muro K, Boku N, Shimada Y, et al. Irinotecan plus S-1 (IRIS) versus fluorouracil and folinic acid plus irinotecan (FOLFIRI) as second-line chemotherapy for metastatic colorectal cancer: a randomised phase 2/3 non-inferiority study (FIRIS study). *Lancet Oncol* 2010;11:853–860. [https://doi.org/https://doi.org/10.1016/S1470-2045\(10\)70181-9](https://doi.org/https://doi.org/10.1016/S1470-2045(10)70181-9).
23. Yamada Y, Denda T, Gamoh M, et al. S-1 and irinotecan plus bevacizumab versus mFOLFOX6 or CapeOX plus bevacizumab as first-line treatment in patients with metastatic colorectal cancer (TRICOLORE): a randomized, open-label, phase III, noninferiority trial. *Ann Oncol* 2018;29:624–631. <https://doi.org/https://doi.org/10.1093/annonc/mdx816>.
24. Yamada Y, Takahari D, Matsumoto H, et al. Leucovorin, fluorouracil, and oxaliplatin plus bevacizumab versus S-1 and oxaliplatin plus bevacizumab in patients with metastatic colorectal cancer (SOFT): an open-label, non-inferiority, randomised phase 3 trial. *Lancet Oncol* 2013;14:1278–1286. [https://doi.org/https://doi.org/10.1016/S1470-2045\(13\)70490-X](https://doi.org/https://doi.org/10.1016/S1470-2045(13)70490-X).
25. Japanese Classification of Colorectal, Appendiceal, and Anal Carcinoma: the 3d English Edition [Secondary Publication]. *J Anus Rectum Colon* 2019;3:175–95. <https://doi.org/https://doi.org/10.23922/jarc.2019-018>.
26. Clavien PA, Barkun J, de Oliveira ML, et al. The Clavien-Dindo classification of surgical complications: five-year experience. *Ann Surg* 2009;250:187–196. <https://doi.org/https://doi.org/10.1097/SLA.0b013e3181b13ca2>.
27. Deng Y, Chi P, Lan P, et al. Neoadjuvant modified FOLFOX6 with or without radiation versus fluorouracil plus radiation for locally advanced rectal cancer: final results of the Chinese FOWARC trial. *J Clin Oncol* 2019;37:3223–3233. <https://doi.org/https://doi.org/10.1200/JCO.18.02309>.
28. Deng Y, Chi P, Lan P, et al. Modified FOLFOX6 with or without radiation versus fluorouracil and leucovorin with radiation in neoadjuvant treatment of locally advanced rectal cancer: initial results of the Chinese FOWARC multicenter, open-label, randomized three-arm phase III trial. *J Clin Oncol* 2016;34:3300–3307. <https://doi.org/10.1200/JCO.2016.66.6198>.
29. Andre T, Boni C, Mounedji-Boudiaf L, et al. Oxaliplatin, fluorouracil, and leucovorin as adjuvant treatment for colon cancer. *N Engl J Med* 2004;350:2343–2351. <https://doi.org/https://doi.org/10.1056/NEJMoa032709>.
30. Hong YS, Park YS, Lim HY, et al. S-1 plus oxaliplatin versus capecitabine plus oxaliplatin for first-line treatment of patients with metastatic colorectal cancer: a randomised, non-inferiority phase 3 trial. *Lancet Oncol* 2012;13:1125–1132. [https://doi.org/https://doi.org/10.1016/S1470-2045\(12\)70363-7](https://doi.org/https://doi.org/10.1016/S1470-2045(12)70363-7).
31. Sugihara K, Kobayashi H, Kato T, et al. Indication and benefit of pelvic sidewall dissection for rectal cancer. *Dis Colon Rectum* 2006;49:1663–1672. <https://doi.org/https://doi.org/10.1007/s10350-006-0714-z>.
32. Mizushima T, Ikeda M, Kato T, et al. Postoperative XELOX therapy for patients with curatively resected high-risk stage II and stage III rectal cancer without preoperative chemoradiation: a prospective, multicenter, open-label, single-arm phase II study. *BMC Cancer* 2019;19:1–8. <https://doi.org/https://doi.org/10.1186/s12885-019-6122-2>.

Publisher's Note

Springer Nature remains neutral with regard to jurisdictional claims in published maps and institutional affiliations.

Ready to submit your research? Choose BMC and benefit from:

- fast, convenient online submission
- thorough peer review by experienced researchers in your field
- rapid publication on acceptance
- support for research data, including large and complex data types
- gold Open Access which fosters wider collaboration and increased citations
- maximum visibility for your research: over 100M website views per year

At BMC, research is always in progress.

Learn more biomedcentral.com/submissions

