



# Clinical Results of the Use of Amniotic Membrane Transplantation Alone or in Combination with Adjuvant Therapies in Conjunctival Fornix Reconstruction

© Yasemin Aslan Katırcıoğlu\*, © Ahmet Kaderli\*\*, © Evin Şingar Özdemir\*, © Firdevs Örneç\*

\*University of Health Sciences Turkey, Ankara Training and Research Hospital, Ankara, Turkey

\*\*Muğla Sıtkı Koçman University Faculty of Medicine, Muğla, Turkey

## Abstract

**Objectives:** To evaluate the clinical results of amniotic membrane transplantation alone or in combination with adjuvant therapies in conjunctival fornix reconstruction.

**Materials and Methods:** The clinical results of patients who presented to our clinic between 2002 and 2016 due to conjunctival fornix obliteration and underwent amniotic membrane transplantation alone or in combination with additional treatments were retrospectively analyzed. The Foster and Mondino classifications were used to grade fornix obliteration. In all cases, the area of conjunctival defect formed after symblepharon lysis was covered with amniotic membrane. In advanced fornix obliteration, amniotic membrane transplantation was combined with 0.04% mitomycin-C (MMC), oral mucosal transplantation, fornix formation (anchoring) sutures, symblepharon ring, eyelid surgery, fibrin glue, and limbal autograft. Deep and scarless restoration of the fornix was considered surgical success.

**Results:** Twenty-two men and 5 women with a mean age of  $45.54 \pm 4.17$  years were included in the study. The etiology of fornix obliteration was mechanical trauma in 16 cases, chemical burn in 6 cases, recurrent pterygium in 3 cases, thermal burn in 1 case, and recurrent chalazion surgery in 1 case. Indications for amniotic membrane transplantation were socket insufficiency in 12 cases, cosmetic reasons in 4 cases, keratoplasty preparation in 3 cases, ptosis in 3 cases, entropion in 2 cases, strabismus in 2 cases, and diplopia in 1 case. The mean follow-up period was  $45.04 \pm 8.4$  months. Twenty-four of 27 cases (88.8%) were successful, while 3 (12.2%) failed due to recurrence of symblepharon.

**Conclusion:** Amniotic membrane transplantation is a successful method when used alone in the reconstruction of early-stage conjunctival fornix obliteration and provides safe and effective results in advanced-stage fornix obliteration when performed in combination with topical 0.04% MMC, oral mucosal transplantation, and limbal autograft surgeries.

**Keywords:** Adjuvant treatments, amniotic membrane transplantation, fornix stenosis, mitomycin-C, symblepharon

**Address for Correspondence:** Ahmet Kaderli, Muğla Sıtkı Koçman University Faculty of Medicine, Muğla, Turkey

E-mail: akaderli@hotmail.com **ORCID-ID:** orcid.org/0000-0002-4725-1515

**Received:** 22.12.2020 **Accepted:** 24.08.2021

**Cite this article as:** Aslan Katırcıoğlu Y, Kaderli A, Şingar Özdemir E, Örneç F. Clinical Results of the Use of Amniotic Membrane Transplantation Alone or in Combination with Adjuvant Therapies in Conjunctival Fornix Reconstruction. Turk J Ophthalmol 2022;52:237-245

## Introduction

The conjunctival fornix is anatomically crucial for providing a tear reservoir and also facilitates the full range of ocular motility when there is natural, smooth contact between the lid and globe during blinking.<sup>1</sup> Obliteration of the fornix may be caused by various ocular surface disorders such as chemical and thermal burns, mechanical trauma, mucous membrane pemphigoid, Stevens-Johnson syndrome, adenoviral membranous conjunctivitis, recurrent pterygium, and evisceration or enucleation surgeries.<sup>1,2,3,4</sup>

Fornix obliteration associated with different etiologies may affect ocular surface health through a number of pathogenic mechanisms: reduction of the tear reservoir, interruption of tear flow and spread, blink-related microtrauma resulting from an irregular tarsal surface, cicatricial entropion and trichiasis, limitation of Bell's phenomenon, inflammation in the conjunctival epithelium, restriction of ocular motility, strabismus and visual loss related to ptosis, and inadequate socket for prosthesis wear.<sup>4,5</sup>

Symblepharon lysis is the first procedure performed in fornix reconstruction surgeries in patients with symblepharon or fornix contracture. Various tissue grafts (autologous conjunctiva, amniotic membrane, buccal or nasal mucosa) are used to cover the palpebral or bulbar conjunctival defects. This is usually followed by an additional procedure to prevent re-adhesion, such as the use of symblepharon rings, silicone implants, anchoring sutures, placement of a custom conformer, or application of beta radiation, topical cyclosporine, or topical 0.04% mitomycin-C (MMC).<sup>6,7,8,9,10</sup>

Limited usability and scarring in the donor area are serious problems in autologous conjunctival grafts.<sup>10</sup> Buccal-nasal mucosa grafts have the disadvantages of poor cosmetic outlook and risk of infection. Successful outcomes have been reported after fornix reconstructions with symblepharon lysis followed by amniotic membrane transplantation (AMT) and intraoperative MMC in cicatricial pemphigoid, Stevens-Johnson syndrome, chemical burns, recurrent pterygium excision, and contracted sockets.<sup>3,4,11,12</sup>

Herein we report the outcomes of AMT alone or in combination with adjuvant therapies such as MMC application, oral mucosa transplantation (OMT), anchoring sutures, and limbal autografting for reconstruction of the fornix in various ocular surface disorders.

## Materials and Methods

The study conformed to the tenets of the Declaration of Helsinki (clinical trial number: 3167). The medical records of patients with fornix obliteration and inadequate conjunctival tissue to cover the whole tarsus or symblepharon at the Ankara Training and Education Hospital between 2002 and 2016 were retrospectively screened. Patients with a follow-up duration shorter than 6 months were excluded. Two grading systems, the Foster and Mondino, were used to evaluate fornix obliteration.<sup>13</sup> Grade 1 and 2 were regarded as early stages, and grade 3 and 4 were considered advanced stages.

In patients with chemical or thermal burn, the surgery was delayed 6 months to allow the resolution of inflammation. All operations were performed after ocular surface inflammation signs subsided. All of the surgeries were done by the same surgeon (Y.K.).

### Surgical Procedures for Fornix Reconstruction

**Symblepharon Lysis:** After placing the lid margin and the limbal traction sutures, symblepharon was released by conjunctival dissections. All adhesions of the residual conjunctiva and/or lid margin to the sclera were meticulously dissected to expose the sclera. Subconjunctival scar tissue was removed extensively, leaving the conjunctiva intact. All scar tissues at the insertion of the rectus muscles were removed to achieve a free and mobile globe.

**AMT:** Amniotic membranes (AM) were prepared as described by Lee and Tseng.<sup>14</sup> The AM was trimmed to fit the entire conjunctival defect, including the bulbar surface of the fornix and the deeper portion of the palpebral aspect of the fornix. The membrane was then secured to the recessed conjunctival edge with a few interrupted stitches or continuous 8/0 Vicryl, with its margin placed under the conjunctival margins to facilitate epithelial growth over the membrane.

### Adjuvant Treatments

**MMC Application:** After cauterizing focal hemorrhages, 0.04% MMC-soaked sponges were applied to the conjunctival fornices for 3 minutes. After this procedure, the fornices were irrigated with 100 ml saline solution. AMT was performed to cover the defect area (Figure 1).

**OMT:** In advanced cases where there was no residual tarsal conjunctiva or it was not sufficient to cover the whole width of the tarsus, it was decided to use an oral mucosal graft with AMT. In these advanced cases, after minimal cauterization of the bleeding vessels to the defect area, multiple pieces of surgical sponge soaked in 0.04% MMC were applied to the fornix for 5 minutes, then the eye was washed with 100 mL of balanced salt solution. An oral mucosal graft 30% larger than the tarsal conjunctival defect was harvested from the lower lip using manual dissection. The submucosal tissue was shaved off to obtain a thin graft. With the anterior epithelial surface facing the globe, the superior edge of the oral mucosal graft was sutured to the residual conjunctival edge or lid margin using 8-0 Vicryl suture with a continuous lock technique. The inferior edge of the oral mucosal graft was secured deep in the fornix using one transcutaneous double-armed 5-0 polypropylene suture (Ethicon Inc, Somerville, NJ, USA) in each quadrant (anchoring sutures). Then, a single layer of cryopreserved AM, stromal side down, was used to cover the exposed sclera using fibrin glue (Tisseel; Baxter Inc, Vienna, Austria) when necessary. A muscle hook was used to push the AM deep into the fornix to create an anatomically deep fornix (Figure 2). When a socket procedure was needed, the conjunctiva of the contracted socket was incised at the involved fornix. Dissection was carried down to the orbital rim. All fibrotic scar tissue was carefully excised. The AM graft was placed over the exposed area. The graft was sutured to the

conjunctival margin with continuous 8/0 Vicryl sutures and secured to the fornix with anchoring sutures by passing two double-armed mattress sutures through the full thickness of the lid and tied over the skin with bolsters (Figure 3).

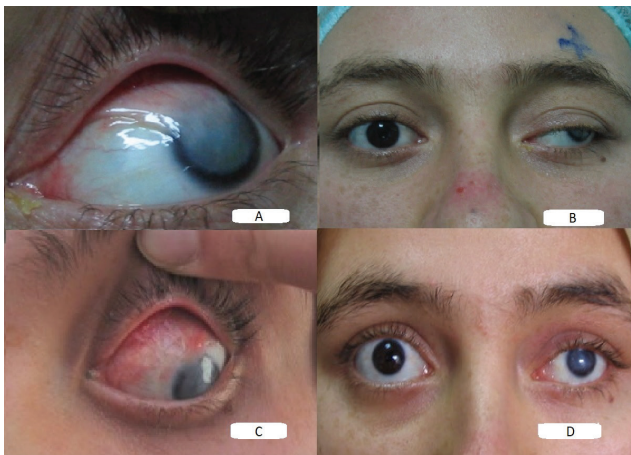A symblepharon ring was secured behind the eyelids with pressure into the fornix to prevent re-obliteration of the anatomical fornix that was formed at the end of the surgery. An anchoring suture was often placed for the same reason in advanced cases. The procedure was concluded with temporary tarsorrhaphy.

Postoperatively, all patients were treated with topical corticosteroids and tapered off in 3 months. Topical antibiotics were applied three or four times a day until epithelialization of the AM was completed. Full epithelialization was determined on the first visit at 2 weeks postoperatively, when no fluorescein staining was demonstrated over the AM. Sutures were removed at postoperative 2 weeks. The anchoring sutures and temporary tarsorrhaphy sutures and symblepharon ring were removed at postoperative 4 weeks.

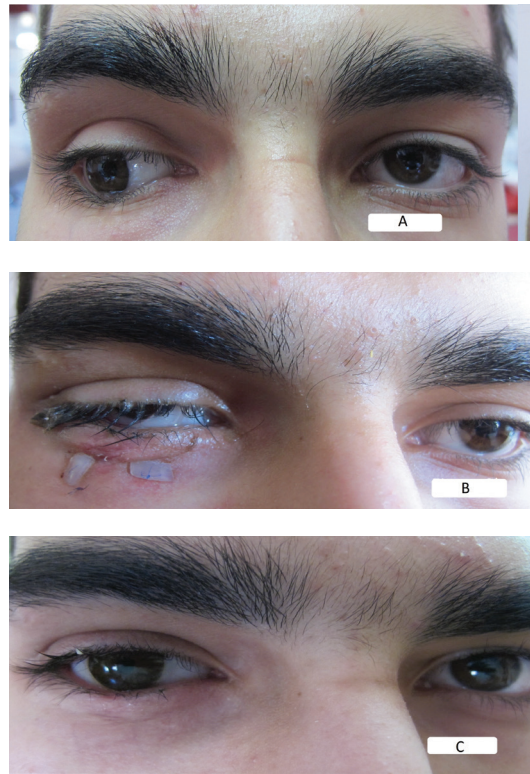Demographic characteristics, causes of acquired anophthalmia, the underlying disease, duration of obliteration, and the number of previous socket operations were recorded. Clinical data including follow-up time, results, ocular surface complications, and recurrences were also documented. Success was defined as an anatomically deep fornix without scarring or motility restriction and ability to wear prosthesis during the last visit. SPSS version 14 (SPSS Inc, Chicago, IL, USA) was used for descriptive statistics.

## Results

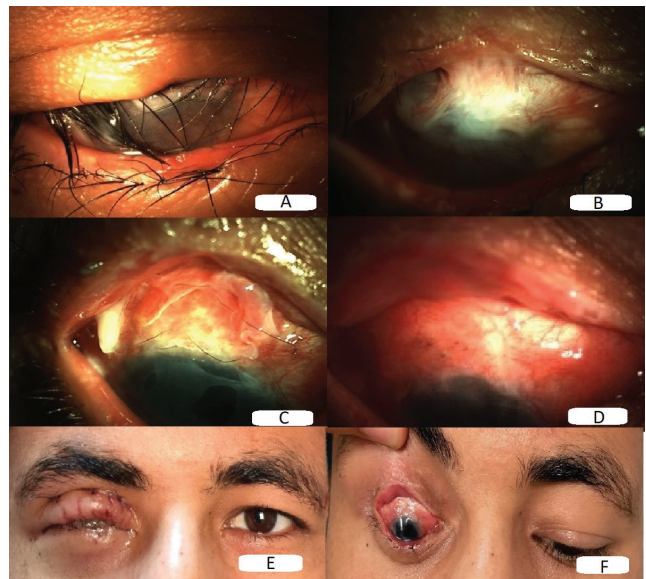
Our study included 27 eyes of 27 patients with fornix obliteration. The mean age was  $45.54 \pm 4.17$  years (range: 17-84); 22 patients (81.5%) were men and 5 (18.5%) were women. The demographic data, clinical presentation, and surgical outcomes are summarized in Table 1.



**Figure 1.** A, B) A 19-year-old woman with thermal burn, stage 3c obliteration of the upper fornix, and ptosis. C) Postoperative 1 month after symblepharon lysis, mitomycin-C application, and amniotic membrane transplantation. D) After 65 months, the patient has a deep upper fornix with no ptosis or recurrence



**Figure 2.** A) A 17-year-old male patient with stage 2c obliteration of the lower fornix, cicatricial entropion, and inability to wear the prosthesis after evisceration surgery. B) Postoperative 1 week after symblepharon lysis, amniotic membrane transplantation, and anchoring suture surgery. C) After 28 months, the patient has a deep lower fornix, no entropion or recurrence, and can wear the prosthesis



**Figure 3.** A, B) A 25-year-old man with grade 3a obliteration of the upper fornix after alkali burn and entropion. C) Postoperative 6 months after symblepharon lysis, mitomycin C application, and amniotic membrane transplantation. D) Deep upper fornix on downgaze. E) Postoperative 3 weeks after limbal autograft, amniotic membrane transplantation, oral mucosa graft, and anchoring suture surgery. F) After 25 months, the patient has a deep upper fornix with no entropion or recurrences.

**Table 1. Patient data and surgical outcomes**

Age/sex	Etiology	Previous surgeries	Indication	Preoperative FO grade	Recurrence	Outcome	Anchoring sutures	Symblepharon ring	Ocular motility disorder	Treatments	Follow-up time (months)
1 70, M	Mechanical trauma	1	FO	2b	-	S	+	-	++	AMT	62
2 45, M	Alkali burn	2	FO, cosmetic	1c	-	S	-	+	-	AMT, OMT	53
3 36, F	Mechanical trauma	1	FO, ptosis	2b	-	S	+	-	-	AMT, MMC	57
4 83, F	Mechanical trauma	2	FO	2d	-	S	-	+	-	AMT, MMC	34
5 40, F	Mechanical trauma	2	FO	2b	-	S	-	+	-	AMT, MMC	55
6 28, M	Mechanical trauma	2	FO	2a	-	S	+	-	-	AMT, MMC	29
7 19, M	Alkali burn	2	Ptosis	3d	3d	F	-	+	+++	AMT	175
8 54, M	Mechanical trauma	1	FO	2b	-	S	+	-	-	AMT, MMC	150
9 78, M	Mechanical trauma	4	FO	2b	-	S	-	+	-	AMT, MMC	64
10 46, M	Iatrogenic (recurrent chalazion)	3	FO, cosmetic	2a	-	S	+	-	++	AMT	49
11 38, M	Mechanical trauma	2	FO, entropion	2c	-	S	+	-	++	AMT, eyelid surgery	57
12 65, M	Mechanical trauma	2	FO	2c	-	S	-	+	-	AMT	57
13 19, F	Thermal burn	-	FO, ptosis	3c	-	S	+	-	++	AMT, MMC	65
14 17, M	Mechanical trauma	1	FO, entropion	2c	-	S	+	-	-	AMT, eyelid surgery	28
15 25, M	Mechanical trauma	1	FO	2b	-	S	-	+	-	AMT	55
16 44, M	Alkali burn	2	PrePK	3c	-	S	-	+	++	AMT, MMC	12
17 35, M	Alkali burn	5	PrePK, FO, entropion	3c	-	S	+	+	++	AMT, MMC, OMT	12

Table 1. Patient data and surgical outcomes												
	Age/ sex	Etiology	Previous surgeries	Indication	Preoperative FO grade	Recurrence	Outcome	Anchoring sutures	Symblepharon ring	Ocular motility disorder	Treatments	Follow-up time (months)
18	60, M	Mechanical trauma	1	FO	2b	2b	F	-	+	-	AMT, MMC	12
19	69, F	Recurrent pterygium	1	FO, strabismus	3b	3a	F	-	+	+++	AMT, MMC	8
20	19, M	Mechanical trauma	2	PrePK, FO, entropion	3c	-	S	+	-	++	AMT, eyelid surgery	6
21	64, M	Recurrent pterygium	3	FO, strabismus	4	-	S	+	-	+++	AMT, medial rectus recession, fibrin glue	6
22	35, M	Mechanical trauma	1	FO	2c	-	S	+	-	-	AMT	118
23	34, M	Mechanical trauma	0	Cosmetic	2c	-	S	-	+	-	AMT	6
24	84, M	Recurrent pterygium	2	Strabismus	3b	-	S	+	+	++	AMT, fibrin glue, OMT	6
25	76, M	Alkali burn	1	Cosmetic	3b	-	S	-	+	+	AMT	6
26	25, M	Alkali burn	1	Entropion	3a	-	S	+	-	+	AMT, MMC, OMT, LOG	25
27	21, M	Mechanical trauma	0	FO	3b	-	S	-	+	+++	AMT	9

+: Mild ocular motility disorder, ++: Moderate ocular motility disorder, +++: Severe ocular motility disorder  
 S: Success, F: Failure, AMT: Amniotic membrane transplantation, MMC: Mitomycin-C, OMT: Oral mucosa transplantation, LAG: Limbal autografting, PrePK: Before penetrating keratoplasty, FO: Fornix obliteration



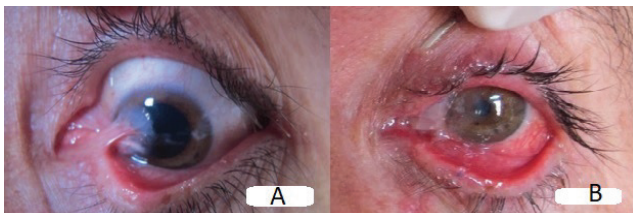
We performed only AMT in 6 patients in the early stage and obtained successful results in all cases. Additional treatments were applied in the other 10 early-stage patients because they had previous surgery or eyelid malposition. Failure was observed only in 1 of 16 (6.3%) patients with early-stage disease. We performed only AMT in 3 of 11 advanced cases and failure was observed in 1 case (9.1%). We achieved successful results with additional treatments in the other 8 advanced cases. The mean follow-up period was  $45.0 \pm 8.4$  months (range: 6-175).

The most common underlying etiology associated with symblepharon was mechanical trauma (blunt/penetrating eye injuries) ( $n=16$ , 59.2%). Other causes of symblepharon were alkali burns in 6 patients (22.2%), recurrent pterygium in 3 patients (11.1%), thermal trauma in 1 patient (3.7%), and recurrent chalazion surgery in 1 patient (3.7%).

The most common indication for surgery was fornix obliteration ( $n=12$ , 44.4%). The surgery was performed in 4 patients (14.8%) for cosmetic reasons, 3 patients (11.1%) for preparation before keratoplasty to maintain ocular surface regularity, 3 patients (11.1%) for blepharoptosis, 3 patients (11.1%) for restrictive strabismus, and 2 patients (7.4%) for entropion. Patients had an average of  $1.67 \pm 0.22$  (range: 0-5) ophthalmologic surgeries before symblepharon surgery.

AMT was performed in all cases after symblepharon lysis and symblepharon ring was used after surgery in 15 cases (55.5%). Adjuvant treatments were performed after AMT in necessary cases. MMC (0.04%) was applied topically for 3 minutes before the defect site was covered with AM in 11 patients (40.7%) with severe symblepharon. No surgical complications were encountered in any of these patients. Other methods and procedures used in combination with AMT for fornix reconstruction included OMT in 3 patients (11.1%), anchoring sutures in 14 patients (51.8%), eyelid surgery in 2 patients (7.4%), fibrin glue in 2 patients (7.4%), limbal autografting in 1 patient (3.7%), and medial rectus recession in 1 patient (3.7%). Fornix obliteration and restrictive strabismus were present in the patient with recurrence of pterygium (3 times). A defect in the medial rectus muscle was detected intraoperatively. The surgical treatment involved symblepharon lysis and AMT, as well as medial rectus repair and recession, fibrin glue, and anchoring sutures. The patient's strabismus improved and no recurrence was observed during follow-up (Figure 4a).

In postoperative examinations, the AM completely covered



**Figure 4.** A) A 64-year-old man with grade 4 obliteration of the lower fornix and restrictive strabismus after recurrent pterygium. B) Postoperative 3 weeks after amniotic membrane transplantation, medial rectus recession, fibrin glue, and anchoring suture surgery

the conjunctiva, and signs of transient inflammation in the AM graft site resolved within two weeks in all patients.

Anatomical success (deep fornix) was achieved in 24 patients (88.8%). In 3 patients, failure occurred due to symblepharon recurrence (11.1%). In one of the failed cases, the etiology was alkali burn and only AMT was performed. The other failed cases were associated with mechanical trauma or recurrent pterygium and we performed AMT with MMC. In three failed cases, symblepharon reoccurred 2-4 months postoperatively. In these 3 patients, in whom we used a symblepharon ring, the tarsorrhaphy sutures were opened in the first week, resulting in the ring becoming dislodged, which we believe allowed fornix obliteration to recur in a short time. In these cases, after 6 months to allow resolution of active inflammation, fornix reconstruction was planned with AMT and additional treatments. An anatomically successful deep fornix was followed up with photographic documentation. In socket patients, success was evaluated with photographic documentation and ability to wear the prosthesis.

## Discussion

The current study showed that a high success rate (88.8%) was achieved with or without adjuvant treatments such as intraoperative MMC application, anchoring sutures, OMT, eyelid surgery, limbal autografting, and medial rectus recession in addition to symblepharon lysis and AMT during  $45.04 \pm 8.4$  months of postoperative follow-up in 27 eyes with fornix obliteration.

Obliteration of the fornices can cause many ocular pathologies such as dry eye, irregular tarsal surface and blink-related microtrauma, entropion, trichiasis, limitation of Bell's phenomenon, restriction of eye movements, loss of vision due to strabismus and ptosis, inflammation in the conjunctival epithelium, and inability to retain an ocular prosthesis.

Numerous methods have been developed for reconstructing the fornix with cheek and lip mucosa grafts, conjunctival autograft, and AMT.<sup>12,15</sup> Fornix depth and conjunctival surface area should be augmented by using grafts of optimal type and appropriate size.<sup>16</sup> Advantages of oral mucosal grafts are graft stability and the ability to easily procure sufficiently sized grafts, even for repeated procedures. Disadvantages of oral mucosal grafts include prolonged operative time, discomfort at the donor site, color mismatch of the graft, and risk of failure due to infection. Kurtul et al.<sup>17</sup> pointed out that although AMT and OMT provided similar results in terms of socket reconstruction, AMT was superior in terms of impression cytology and inflammation. Conjunctival autograft also has limited availability, and fibrosis can occur in the recipient region.<sup>18</sup> Conjunctival autograft use after pterygium excision is very successful but may result in postoperative complications such as subconjunctival fibrosis in the harvest area and diplopia due to restrictive strabismus created by scar tissue.<sup>19</sup> AM consists of a single epithelium, thick basal membrane, and avascular stroma. It is used for many ocular and conjunctival disorders.<sup>20</sup> AM promotes the differentiation

of goblet cells and survival of conjunctival epithelium.<sup>20</sup> AM acts directly on ocular surface fibroblasts by suppressing tumor growth factor-beta signals and allowing the formation of the normal keratocyte phenotype not only pathologically, but also physiologically.<sup>21</sup> The advantages of AM over the mucous membrane and conjunctival autografts are its anti-inflammatory and anti-infective properties, lack of immunogenicity, unlimited availability, the absence of donor site trauma to the patient, shorter operative time, faster recovery, and matching the color of the surrounding conjunctiva after complete healing because of its translucency.<sup>3,10,22,23</sup> For this reason, we covered the defect area with AM in all our cases.

Although AMT alone has been successfully used to reconstruct the fornix in eyes with lower grades of symblepharon severity,<sup>16</sup> its usefulness is limited in eyes with severe symblepharon. We performed only AMT in 6 patients in the early stage and successful results were obtained in all cases. Since the other 10 early-stage cases had previous surgery or eyelid malposition, additional treatments were applied and only 1 failure occurred. We performed only AMT in 3 of 11 cases with advanced-stage disease, and although we observed failure in only 1 case, successful results were achieved with additional treatment in 8 cases.

Kheirkhah et al.<sup>15</sup> evaluated symblepharon severity according to photographic documentation and reported that cicatricial lysis and AMT achieved overall success in 92.8% of grade I eyes and in 100% of grade II eyes. Additional anchoring sutures improved success rates to 100% of grade I eyes and 71.4% of grade III/IV eyes. Additional oral mucosa or conjunctival autograft improved the success rate to 100% in grade III/IV eyes. In our study, OMT was required in 3 cases (11.1%), limbal autografting in 1 case (3.7%), and anchoring sutures in 14 cases (51.8%) in combination with AMT for fornix reconstruction. Success was achieved in cases where we used OMT and anchoring sutures with AMT.

Several reports also showed that fornix reconstruction could be accomplished by AMT with or without intraoperative MMC.<sup>18,24</sup> Some authors recommended the use of MMC for active and aggressive recurrent pterygium or in combination with a grafting procedure, as used in this study. This is because it is not theoretically possible to completely remove the subconjunctival fibrous tissue, especially in recurrent pterygium, as inflamed tissue extends deep into the fornix.<sup>25</sup> In our study, AMT with MMC failed in 2 of 10 cases. One of these patients had early-stage fornix obliteration, the other had advanced fornix obliteration, recurrent pterygium, and restrictive strabismus.

Restrictive esotropia is a rare severe complication after pterygium excision surgery. Restrictive esotropia may occur due to scarring of the conjunctiva surrounding complex connective tissue, direct trauma to the rectus muscle, formation of symblepharon, and recurrence of pterygium.<sup>2,26</sup> Increased pterygium recurrence increases the risk of restrictive strabismus.<sup>27</sup> Surgical treatment is challenging because it requires a combination of surgery on the conjunctival-perimuscular connective tissue complex and the medial rectus muscle. Surgery is effective in improving the

primary position deviation, but some restricted esotropia may persist.<sup>28</sup> AMT seems to help prevent recurrence of adhesions in patients with restrictive strabismus caused by conjunctival scarring.<sup>29</sup> Management of recurrent pterygium with severe symblepharon using MMC, double AMT, cryopreserved limbal allograft, and a conjunctival flap was reported to be effective.<sup>30</sup> In our study, two of three patients who developed restrictive esotropia due to recurrent pterygium achieved good results with the use of AMT plus adjuvant treatment. Only one of the three recurrent pterygium cases with restrictive strabismus recurred. We applied adjuvant therapies with AMT in all of them. In our unsuccessful case, we applied MMC together with AMT.

Kheirkhah et al.<sup>15</sup> showed that a combined approach of cicatricial lysis, intraoperative MMC application, OMT, and sutureless AMT is an effective surgical strategy for the management of severe symblepharon. They concluded that adjuvant mucosal grafting is needed to improve the clinical outcome and that oral mucosa may be a good option for this. Oral mucosal grafts have long been used to cover conjunctival defects during fornix reconstruction in eyes with symblepharon or surgical correction of anophthalmic contracted sockets.<sup>16,31</sup> We also achieved successful results when OMT was added to adjuvant treatments combined with AMT and intraoperative MMC application in 2 patients with advanced and 1 patient with early-stage fornix obliteration.

Contracted socket and fornix shortening in the anophthalmic orbit can lead to inadequate space for the retention of a prosthesis. Socket contracture may result from various processes such as fibrosis from a severe initial injury, implant extrusion, chronic infection, and inability to wear a prosthesis or conformer.<sup>32</sup> An AM is a useful option for forniceal reconstruction in socket contracture. This technique achieved a success rate of 80% without serious complications.<sup>33</sup> Bajaj et al.<sup>34</sup> evaluated 20 patients who underwent AMT or OMT for socket failure and reported that lower fornix depth and socket volume were similar in both of the groups. An AM has many advantages in socket reconstruction, such as having an anti-fibrotic effect on the mucous membrane, being translucent, and acting as a substrate graft. Hao et al.<sup>35</sup> emphasized that the use of AMT in contracted sockets was associated with a more favorable outcome compared to buccal mucosa and nasal mucosal grafts. In our study, we performed AMT alone in 5 of 12 patients with socket contracture and AMT with MMC in the other 7 patients, and obtained successful results in all cases.

#### Study Limitations

The main limitations of our study are the lack of a control group and our inability to compare results between the groups due to the small number of patients who developed symblepharon secondary to various diseases that may require different surgical approaches included in this study. With these limitations in mind, our results underlined that cicatricial lysis and AMT with or without adjuvant therapy is an effective surgical method for the management of fornix obliteration. Fornix reconstruction surgeries using the correct and effective approach according to

the severity of symblepharon and underlying reason for fornix obliteration yielded successful results both in functional and cosmetic terms.

## Conclusion

Surgical treatment with AMT alone yielded satisfactory outcomes in patients with early-stage fornix obliteration. In patients with early disease who have previous surgical history and eyelid malposition, successful results can be obtained by applying additional treatments together with AMT. In patients with advanced fornix obliteration for which AMT alone is inadequate, adjuvant treatment with OMT, anchoring sutures, eyelid surgery, fibrin glue, limbal autografting, and MMC in addition to AMT provides successful, safe, and effective outcomes.

## Ethics

**Ethics Committee Approval:** Ankara Training and Research Hospital, 2814.

**Informed Consent:** Retrospective study.

**Peer-review:** Externally peer reviewed.

## Authorship Contributions

Surgical and Medical Practices: Y.K., Concept: Y.K., A.K., Design: Y.K., A.K., E.Ş.Ö., Data Collection or Processing: Y.K., A.K., Analysis or Interpretation: Y.K., A.K., E.Ş.Ö., Literature Search: A.K., E.Ş.Ö., Writing: Y.K., A.K., E.Ş.Ö.

**Conflict of Interest:** No conflict of interest was declared by the authors.

**Financial Disclosure:** The authors declared that this study received no financial support.

## References

- Macdonald EA, Maurice DM. The kinetics of tear fluid under the lower lid. *Exp Eye Res.* 1991;53:421-425.
- Jenkins PF, Stavits MI, Jenkins DE 3rd. Esotropia following pterygium surgery. *Binocul Vis Strabismus Q.* 2002;17:227-228.
- Tsubota K, Satake Y, Ohyama M, Toda I, Takano Y, Ono M, Shinozaki N, Shimazaki J. Surgical reconstruction of the ocular surface in advanced ocular cicatricial pemphigoid and stevens-johnson syndrome. *Am J Ophthalmol.* 1996;122:38-52.
- Solomon A, Espana EM, Tseng SC. Amniotic membrane transplantation for reconstruction of the conjunctival fornices. *Ophthalmology.* 2003;110:93-100.
- Thatte S, Jain J. Fornix reconstruction with amniotic membrane transplantation: A cosmetic remedy for blind patients. *J Ophthalmic Vis Res.* 2016;11:193-197.
- Patel BC, Sapp NA, Collin R. Standardized range of conformers and symblepharon rings. *Ophthalm Plast Reconstr Surg.* 1998;14:144-145.
- Choy AE, Asbell RL, Taterka HB. Symblepharon repair using a silicone sheet implant. *Ann Ophthalmol.* 1977;9:197-204.
- Fein W. Repair of total and subtotal symblepharons. *Ophthalmic Surg.* 1979;10:44-47.
- Turan-Vural E, Torun-Acar B, Kivanc SA, Acar S. The effect of topical 0.05% cyclosporine on recurrence following pterygium surgery. *Clin Ophthalmol.* 2011;5:881-885.
- Mutlu FM, Sobaci G, Tatar T, Yildirim E. A comparative study of recurrent pterygium surgery: Limbal conjunctival autograft transplantation versus mitomycin c with conjunctival flap. *Ophthalmology.* 1999;106:817-821.
- Lee-Wing MW. Amniotic membrane for repair of exposed hydroxyapatite orbital implant. *Ophthalm Plast Reconstr Surg.* 2003;19:401-402.
- Tseng SC, Di Pascuale MA, Liu DT, Gao YY, Baradaran-Rafii A. Intraoperative mitomycin c and amniotic membrane transplantation for fornix reconstruction in severe cicatricial ocular surface diseases. *Ophthalmology.* 2005;112:896-903.
- Tauber J, Jabbur N, Foster CS. Improved detection of disease progression in ocular cicatricial pemphigoid. *Cornea.* 1992;11:446-451.
- Lee SH, Tseng SC. Amniotic membrane transplantation for persistent epithelial defects with ulceration. *Am J Ophthalmol.* 1997;123:303-312.
- Kheirkhah A, Ghaffari R, Kaghazkanani R, Hashemi H, Behrouz MJ, Raju VK. A combined approach of amniotic membrane and oral mucosa transplantation for fornix reconstruction in severe symblepharon. *Cornea.* 2013;32:155-160.
- Kheirkhah A, Blanco G, Casas V, Hayashida Y, Raju VK, Tseng SC. Surgical strategies for fornix reconstruction based on symblepharon severity. *Am J Ophthalmol.* 2008;146:266-275.
- Kurtul BE, Erdener U, Mocan MC, Irkec M, Orhan M. Clinical and impression cytology findings of amniotic membrane and oral mucosal membrane transplantation for the management of socket contracture. *Int J Ophthalmol.* 2014;7:340-344.
- Katircioglu YA, Altiparmak U, Engur Goktas S, Cakir B, Singar E, Ornek F. Comparison of two techniques for the treatment of recurrent pterygium: Amniotic membrane vs conjunctival autograft combined with mitomycin c. *Semin Ophthalmol.* 2015;30:321-327.
- Vrabec MP, Weisenthal RW, Elsing SH. Subconjunctival fibrosis after conjunctival autograft. *Cornea.* 1993;12:181-183.
- Celik T, Katircioglu YA, Singar E, Kosker M, Budak K, Kasim R, Duman S. Clinical outcomes of amniotic membrane transplantation in patients with corneal and conjunctival disorders. *Semin Ophthalmol.* 2013;28:41-45.
- Lee SB, Li DQ, Tan DT, Meller DC, Tseng SC. Suppression of tgf-beta signaling in both normal conjunctival fibroblasts and pterygial body fibroblasts by amniotic membrane. *Curr Eye Res.* 2000;20:325-334.
- Koizumi NJ, Inatomi TJ, Sotozono CJ, Fullwood NJ, Quantock AJ, Kinoshita S. Growth factor mRNA and protein in preserved human amniotic membrane. *Curr Eye Res.* 2000;20:173-177.
- Tseng SC, Li DQ, Ma X. Suppression of transforming growth factor-beta isoforms, TGF-beta receptor type II, and myofibroblast differentiation in cultured human corneal and limbal fibroblasts by amniotic membrane matrix. *J Cell Physiol.* 1999;179:325-335.
- Nava-Castañeda A, Tovila-Canales JL, Monroy-Serrano MH, Tapia-Guerra V, Tovilla-Y-Pomar JL, Ordóñez-Blanco A, Garnica-Hayashi L, Garfias-Becerra Y. [Estudio comparativo entre transplante de membrana amniótica con y sin aplicación simultánea de mitomicina c en reconstrucción de fondo de saco conjuntival [Comparative study of amniotic membrane transplantation, with and without simultaneous application of mitomycin C in conjunctival fornix reconstruction]. *Arch Soc Esp Oftalmol.* 2005;80:345-352.
- Hirst LW. The treatment of pterygium. *Surv Ophthalmol.* 2003;48:145-180.
- Xia Q, Huang Z, Shen DA, Dai H. [Clinical analysis of the diplopia and strabismus after ophthalmic surgeries]. *Zhonghua Yan Ke Za Zhi.* 2003;39:727-730.
- Ela-Dalman N, Velez FG, Rosenbaum AL. Incomitant esotropia following pterygium excision surgery. *Arch Ophthalmol.* 2007;125:369-373.
- Waland MJ, Stevens JD, Steele AD. The effect of recurrent pterygium on corneal topography. *Cornea.* 1994;13:463-464.
- Strube YN, Conte F, Faria C, Yiu S, Wright KW. Amniotic membrane transplantation for restrictive strabismus. *Ophthalmology.* 2011;118:1175-1179.



30. Monden Y, Nagashima C, Yokote N, Hotokezaka F, Maeda S, Sasaki K, Yamakawa R, Yoshida S. Management of Recurrent Pterygium with Severe Symblepharon Using Mitomycin C, Double Amniotic Membrane Transplantation, Cryopreserved Limbal Allograft, and a Conjunctival Flap. *Int Med Case Rep J.* 2020;13:201-209.
31. Klein M, Menneking H, Bier J. Reconstruction of the contracted ocular socket with free full-thickness mucosa graft. *Int J Oral Maxillofac Surg.* 2000;29:96-98.
32. Smith BC, Nesi FA, Levine MR, Lisman RD. *Smith's Ophthalmic Plastic and Reconstructive Surgery.* 2nd ed St. Louis, MO: Mosby; 1998:1015-1052.
33. Poonyathalang A, Preechawat P, Pomsathit J, Mahaisaviriya P. Reconstruction of contracted eye socket with amniotic membrane graft. *Ophthalmic Plast Reconstr Surg.* 2005;21:359-362.
34. Bajaj MS, Pushker N, Singh KK, Chandra M, Ghose S. Evaluation of amniotic membrane grafting in the reconstruction of contracted socket. *Ophthalmic Plast Reconstr Surg.* 2006;22:116-120.
35. Hao Y, Ma DH, Hwang DG, Kim WS, Zhang E. Identification of antiangiogenic and antiinflammatory proteins in human amniotic membrane. *Cornea.* 2000;19:348-352.