

# Cryolipolysis for Safe and Effective Inner Thigh Fat Reduction

Brian D. Zelickson, MD,<sup>1,2\*</sup> A. Jay Burns, MD, FACS,<sup>3</sup> and Suzanne L. Kilmer, MD<sup>4,5</sup>

<sup>1</sup>Zel Skin and Laser Specialists, Edina, Minnesota

<sup>2</sup>University of Minnesota Medical School, Minneapolis, Minnesota

<sup>3</sup>Dallas Plastic Surgery Institute, Dallas, Texas

<sup>4</sup>Laser and Skin Surgery Center of Northern California, Sacramento, California

<sup>5</sup>University of California, Davis Medical School, Sacramento, California

**Background and Objectives:** While cryolipolysis initially received FDA clearance for fat reduction in the abdomen and flanks, there was significant interest in non-surgical fat reduction for other sites, such as the inner and outer thighs. This article reports the results of an inner thigh study which contributed to FDA clearance of cryolipolysis for treatment of thighs.

**Study Design/Material and Methods:** A flat cup vacuum applicator (CoolFit applicator, CoolSculpting System) was used to treat 45 subjects bilaterally in the inner thighs. Single cycle treatments were delivered at Cooling Intensity Factor (CIF) 41.6 for 60 minutes followed by 2 minutes of manual massage. Follow-up visits were conducted at 8 and 16 weeks. Efficacy was assessed by ultrasound imaging, circumference measurements, and photographs. Safety was assessed by monitoring adverse events. Patient satisfaction was evaluated by questionnaire.

**Results:** Data is presented for  $n=42$  patients that completed the 16 week study follow-up and maintained their weight within 5 lbs. of baseline. Independent photo review from three blinded physicians found 91% correct identification of baseline clinical photographs. Ultrasound data indicate fat layer reduction of 2.8 mm. Circumferential measurements indicate mean reduction of 0.9 cm. Patient questionnaires reveal 93% were satisfied with the CoolSculpting procedure; 84% noticed visible fat reduction; 89% would recommend to a friend; and 91% were likely to have a second treatment. There were no device- or procedure-related serious adverse events.

**Conclusion:** The CoolFit flat cup vacuum applicator was found to deliver safe and effective cryolipolysis treatment to reduce inner thigh fat. Completed 16-week data from 42 subjects show 2.8 mm reduction in fat thickness and 0.9 cm reduction in circumference. Assessment of clinical photographs found 91% correct identification of baseline images. The results of this prospective, multi-center, interventional clinical study contributed to FDA clearance of cryolipolysis for treatment of thighs in April 2014. *Lasers Surg. Med.* 47:120–127, 2015. © 2015 The Authors. *Lasers in Surgery and Medicine* Published by Wiley Periodicals, Inc.

**Key words:** cryolipolysis; inner thighs; non-invasive body contouring; non-surgical fat reduction; subcutaneous fat

## INTRODUCTION

Cryolipolysis, the application of controlled cooling to non-invasively damage subcutaneous adipocytes, is based upon the greater susceptibility of lipid rich adipocytes to cold injury compared to surrounding water rich cells [1–3]. There have been numerous case reports of cold-induced damage to subcutaneous fat tissue, including “popsicle panniculitis,” reduction of fat in the cheeks of an infant that sucked on a popsicle [4–9]. From the observations in these case reports, cryolipolysis was developed to non-surgically reduce undesirable subcutaneous fat. Initial porcine studies demonstrated that significant fat layer reduction could be achieved by non-invasive application of cold without injury to the skin or significant change in serum lipids levels or liver function tests [1,2]. Based upon evidence of safe and effective body contouring clinical studies in humans, cryolipolysis received FDA clearance for fat reduction for the flanks in 2010 and then received clearance for the abdomen in 2012.

---

This is an open access article under the terms of the Creative Commons Attribution-NonCommercial-NoDerivs License, which permits use and distribution in any medium, provided the original work is properly cited, the use is non-commercial and no modifications or adaptations are made.

Disclosures: Dr. Zelickson is on the medical advisory boards for Zeltiq, Lumenis, Candela, Ulthera, and Eleme; received research grants from Sciton, Candela, Palomar, Syneron, Silk'n, Valeant, Lumenis, Ulthera, Zeltiq, Canfield, and Wave Rx. Dr. Burns is on the medical advisory boards for Zeltiq, Ulthera, Cynosure, Myoscience, and Thermi-Aesthetics; receives honoraria from Valeant, Sciton, Zeltiq, and Ulthera; receives funding through research grants from Valeant, Zeltiq, and Ulthera; owns stock and/or stock options in Zeltiq; and receives equipment discounts or loans from Palomar, Cynosure, Sciton, Zimmer, Zeltiq, and Cutera. Dr. Kilmer is on the medical advisory boards for Candela/Syneron, Living Proof/Strateris, Lumenis, Lutronics, and Zeltiq and receives research support from Candela/Syneron, Living Proof/Strateris, Lumenis, Lutronics, Zeltiq, Allergan, Cutera, Cynosure/Palomar, and Valeant.

\*Correspondence to: Brian D. Zelickson, MD, Zel Skin and Laser Specialists, 4100 W. 50th Street, Edina, MN 55424.

Email: zelic002@earthlink.net

Accepted 4 November 2014

Published online 13 January 2015 in Wiley Online Library (wileyonlinelibrary.com).

DOI 10.1002/lsm.22320

When this study was initiated, cryolipolysis had FDA clearance for cold-assisted lipolysis of the flanks and abdomen, but the procedure was also used for off-label treatment of the arms, thighs, knees, back, and chest [10–15]. A flat cup vacuum applicator was specifically designed for reducing longer and difficult-to-access bulges of fat areas, such as fat presented on the arms and inner thighs. Figure 1 shows the flat cup vacuum applicator (CoolFit) in comparison to the standard contoured cup vacuum applicator (CoolCore). This study investigates the safety and efficacy of a flat cup vacuum cryolipolysis applicator for reduction of fat in the inner thighs. A prototype of the flat cup vacuum applicator was evaluated for inner thigh treatment in a pilot study that showed promising results in  $n = 11$  subjects [13]. This article describes a more comprehensive multi-center study of  $n = 45$  subjects conducted using a commercially-available flat cup vacuum applicator (CoolFit applicator, CoolSculpting System, Zeltiq Aesthetics, Pleasanton, CA). A separate study investigated treatment of the outer thigh using a non-vacuum surface cryolipolysis applicator [16]. The data from both studies contributed to a regulatory submission that resulted in FDA clearance for cryolipolysis treatment of the thighs.

## MATERIALS AND METHODS

Male or female subjects were eligible to participate, between 18 and 65 years of age with clearly visible fat on their inner thighs and body mass index up to 30. For the duration of the study, subjects were instructed to avoid implementing major diet or lifestyle changes in order to maintain their weight within 5 lbs. of baseline measurement. Follow-up time was based on prior cryolipolysis studies with 8- and 16-week follow-ups [13,15,16]. Prior to treatment and at the 8- and 16-week follow-up visits, clinical assessments, photographs, circumferential measurements, and ultrasound images were obtained. Patient surveys were also conducted at the follow-up visits.

Treatment efficacy was assessed by clinical photographs, circumferential measurements, and ultrasound imaging. For the photographs, subjects were photographed with their feet separated at a fixed distance using a foot positioning guide fixture. At all baseline and follow-up visits, photographs were acquired using a standardized photography set-up (Nikon D300, Nikon 60 mm lens, DynaLite strobes) to ensure consistency. At the completion of the study, clinical photographs were reviewed by three blinded, independent physicians. Independent photo review data was generated by randomizing pre-treatment

and post-treatment photograph pairs of each subject, then asking the reviewers to determine which image was the pre-treatment image.

Circumference measurements were taken at baseline, and at the 8- and 16-week follow-up visits. An anthropometric tape measure was used in this study. Circumferential measurements of each thigh were performed at the peak of the bulge in the inner thighs and the vertical distance of the bulge from the floor was recorded at the baseline visit to ensure accurate placement at each interval. Measurements of the subject's thigh circumference were made in triplicate and averaged.

Ultrasound images were acquired with the subject standing and the non-measured leg raised on a step. A template was used to mark the ultrasound sites on the inner thigh treatment area. Next, a 7.5 MHz high-resolution linear transducer was used to acquire ultrasound images at each measurement site (SonoSite TITAN, Bothell, Washington). Images of untreated control areas were captured for normalization of fat reduction in the treated areas. For each study subject, a transparent template was created to align the ultrasound measurement sites to anatomic landmarks, such as moles and scars. The templates allowed the operator to consistently locate the ultrasound measurement sites from the baseline to the follow-up visits.

Figure 2 depicts the inner thigh treatment method. With the subject standing and the untreated leg raised on a step to provide access, a gelpad was draped over the treatment area. The flat cup vacuum applicator was placed over the treatment area slightly posterior to the thigh midline and as high as comfortably tolerated to capture the inner thigh bulge and vacuum suction was initiated. The subject was then carefully transitioned to the treatment table. The subject was seated with the legs slightly bent during the 60 minute treatment. At the conclusion of the cycle, the treat area was manually massaged for 2 minutes. For all study subjects, the vacuum applicator remained securely in place throughout the treatment cycles.

## RESULTS

From three clinical sites, 45 patients were enrolled and completed treatment. Three subjects did not maintain weight within 5 lbs. of baseline, as required in the protocol, and were excluded from efficacy analysis (photo review, circumference measurement, and ultrasound imaging data). Table 1 lists the subject weight measurements on the treatment visit and 16 week follow-up. Mean weight change was 0.5 lbs. gained with 2.3 lbs.

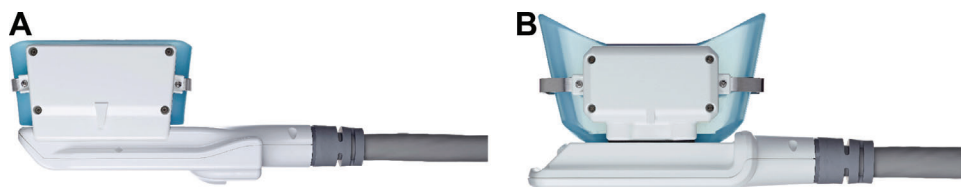


Fig. 1. Comparison of the **A)** flat cup CoolFit and **B)** contoured cup CoolCore vacuum applicators.

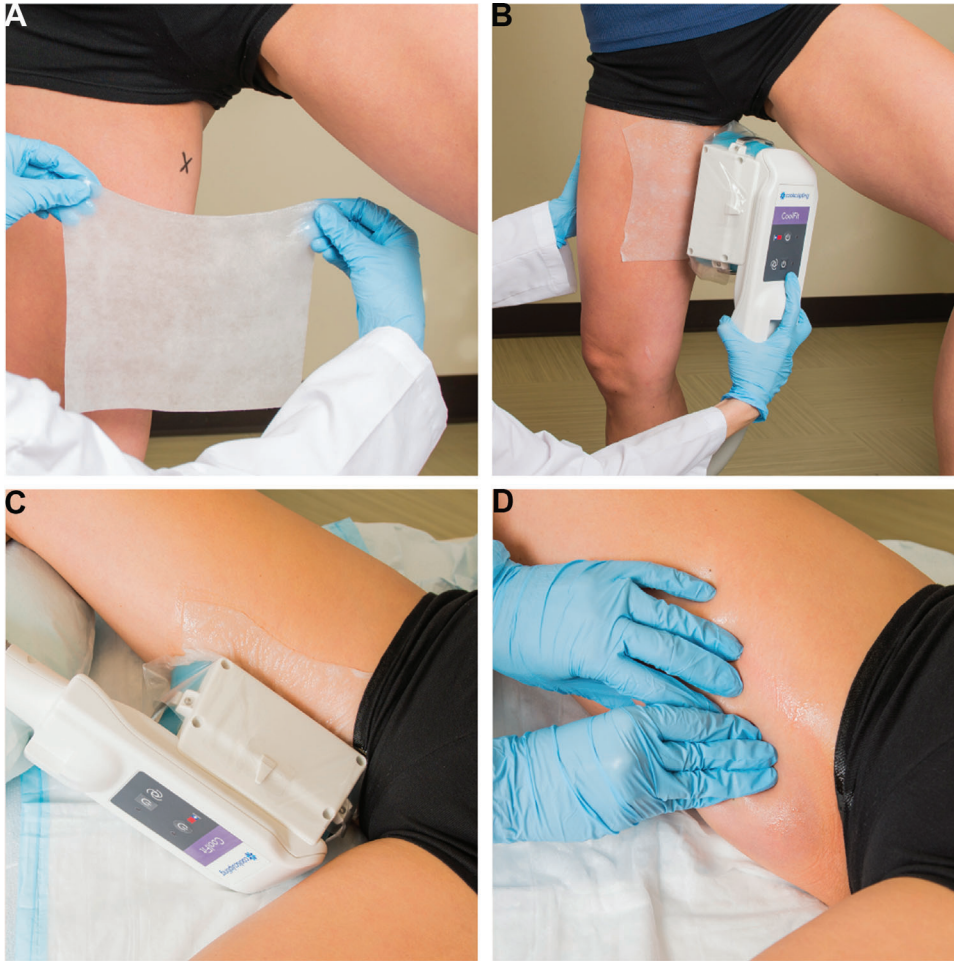


Fig. 2. Cryolipolysis treatment steps for the inner thigh. **A)** The protective gelpad was placed over the inner thigh. **B)** The flat cup vacuum applicator was placed over the treatment area and vacuum suction was initiated. **C)** The patient was seated with the legs slightly bent during treatment. **D)** Manual massage was administered following device removal.

standard deviation. A paired t-test determined there was not a statistically significant difference between the baseline and 16 week subject weights. All subjects were female with Fitzpatrick Skin Type I–V. The subject ages range from 35 to 60, with average 48.1 years. Weight ranged from 112.0 to 188.5 lbs., with average 147.1 lbs. Body Mass Index (BMI) ranged from 20.9 to 30.0, with average BMI 24.6.

Figures 3–6 show representative subjects at baseline and at 16 weeks post-treatment. The photos demonstrate visible reduction of the inner thigh contour from the pre- and post-treatment photographs in front and back views. From the independent photo review, three blinded, independent physicians reviewed the photographs in randomized pairs. The reviewers correctly identified the baseline images 91% of the time.

Thigh circumference measurements were obtained to assess treatment efficacy. At baseline, the mean was 58.1 cm (range 51.6–65.9 cm). At 16 weeks post-treat-

ment, the mean circumference was 57.2 cm (range 49.2–64.7), a 0.9 cm reduction. The paired, two-tailed Student's t-test was performed to identify significance between pre-treatment and 16-week measurements. Statistically significant reduction was found with  $P = 4.6E-6$ .

Ultrasound images were analyzed to calculate fat layer reduction. Figures 7 and 8 show example ultrasound images captured at baseline and 16 weeks post-treatment. Ultrasound measurements show a mean fat layer reduction of 2.8 mm (95% Confidence Interval of [2.23, 3.27]), with a standard deviation of 2.3 mm, and a range from an increase of 3.4 mm to a reduction of 9.0 mm. To account for fluctuations in study subject weight, the fat layer reduction was normalized for the treated sites by subtracting the fat layer change measured from the control sites. The mean normalized fat layer reduction was 2.6 mm. The ultrasound data was analyzed to test the hypothesis that average reduction in fat layer thickness was significantly

**TABLE 1. Baseline and 16 Week Subject Weight Measurements**

Subject	Treatment visit (lbs.)	16 week visit (lbs.)	Weight change (lbs.)
BUR-001	122.4	122.8	0.4
BUR-002	131.0	131.0	0.0
BUR-003	142.0	144.8	2.8
BUR-004	146.4	147.4	1.0
BUR-005	138.0	135.8	-2.2
BUR-006	135.5	135.4	-0.1
BUR-007	144.8	144.0	-0.8
BUR-008	145.5	148.8	3.3
BUR-009	131.0	135.4	4.4
BUR-010	148.0	149.8	1.8
BUR-011	132.0	130.8	-1.2
KIL-001	135.0	135.0	0.0
KIL-002	145.0	144.0	-1.0
KIL-003	142.0	142.0	0.0
KIL-004	135.0	137.0	2.0
KIL-005	149.0	149.6	0.6
KIL-006	180.0	185.0	5.0
KIL-007	157.0	159.0	2.0
KIL-008	140.0	139.6	-0.4
KIL-009	154.0	156.0	2.0
KIL-010	112.0	115.0	3.0
KIL-011	136.0	136.0	0.0
ZEL-001	160.5	161.0	0.5
ZEL-002	148.5	147.0	-1.5
ZEL-003	136.0	133.0	-3.0
ZEL-004	157.5	156.5	-1.0
ZEL-005	160.5	158.5	-2.0
ZEL-006	188.5	193.0	4.5
ZEL-007	178.5	179.5	1.0
ZEL-008	131.0	130.0	-1.0
ZEL-009	149.0	149.0	0.0
ZEL-010	126.5	125.5	-1.0
ZEL-011	148.5	147.5	-1.0
ZEL-012	145.0	147.5	2.5
ZEL-013	141.0	136.0	-5.0
ZEL-014	175.5	179.0	3.5
ZEL-015	175.5	176.5	1.0
ZEL-016	132.0	133.0	1.0
ZEL-017	168.5	168.5	0.0
ZEL-018	164.0	167.5	3.5
ZEL-019	140.5	139.5	-1.0
ZEL-020	156.0	150.5	-5.5
ZEL-021	140.5	143.5	3.0
ZEL-022	149.0	149.5	0.5
ZEL-023	148.0	147.0	-1.0

Three subjects did not maintain weight within 5 lbs. and were excluded from analysis for treatment efficacy. Mean weight change was 0.5 lb. gained with 2.3 lb. standard deviation. There was not a statistically significant difference between the baseline and 16 week subject weights.

greater for the treated region compared to the untreated control region; treated inner thigh fat layer reduction was significant with  $P = 1.2E-12$ .

Patient survey responses were taken at post-treatment follow-up visits. Data from the follow-up questionnaire were tabulated for all subjects. From the 16-week questionnaires, 93% of subjects were satisfied, 89% would recommend inner thigh cryolipolysis to a friend, 91% were likely to have a second procedure, and 84% noticed visible fat reduction in their inner thighs after one treatment. All side effects were transient and typical, such as erythema, mild swelling, and numbness. The longest time to full resolution for each of these side effects was 8 days for erythema, 12 days for mild swelling, and 132 days for mild numbness. There were no serious adverse events related to the device or procedure.

## DISCUSSION

A pilot study of cryolipolysis inner thigh treatment using a prototype flat cup applicator found safe and effective fat reduction in  $n = 11$  subjects treated [13]. This multi-center study of  $n = 45$  subjects using a commercial version of the flat cup applicator confirmed the pilot study results. Inner thigh fat was safely and effectively reduced non-surgically using cryolipolysis. The clinical photographs provide evidence of visible reduction in inner thigh contour 16 weeks after a single cryolipolysis treatment cycle. Quantified reduction by circumferential measurements and ultrasound imaging also demonstrate inner thigh reduction. For patients with more volume reduction desired, multiple treatment cycles can be delivered for increased subcutaneous fat layer reduction. Clinical results from this study were obtained with one treatment cycle. Patients should be reassessed following the initial treatment to determine whether additional treatment cycles would be beneficial. The authors stress the importance of careful applicator placement and recommend following the protocol described in this study, i.e., vertical, slightly posterior placement of the flat cup applicator to treat inner thigh fat (Fig. 2). Other colleagues have shared undesirable results attained by improper cryolipolysis treatment on the inner thighs, such as using a contoured rather than flat cup applicator or using horizontal rather than vertical applicator placement. To avoid contour irregularities and undesirable outcomes, it is important to remember that the cryolipolysis treatment is effective; thus, thoughtful patient assessment and careful applicator placement should be exercised to avoid complications and to achieve natural, aesthetically pleasing reduction of subcutaneous fat.

The flat cup vacuum applicator was designed for longer and difficult-to-access bulges of fat, such as the fat presented in the inner thighs. Many physicians have found cryolipolysis to be safe and efficacious for abdomen and flank treatments and, subsequently, explored off-label treatments elsewhere on the body, such as the inner thighs. With the flat cup vacuum applicator, there has also been interest in treating undesirable fat in the upper arms.

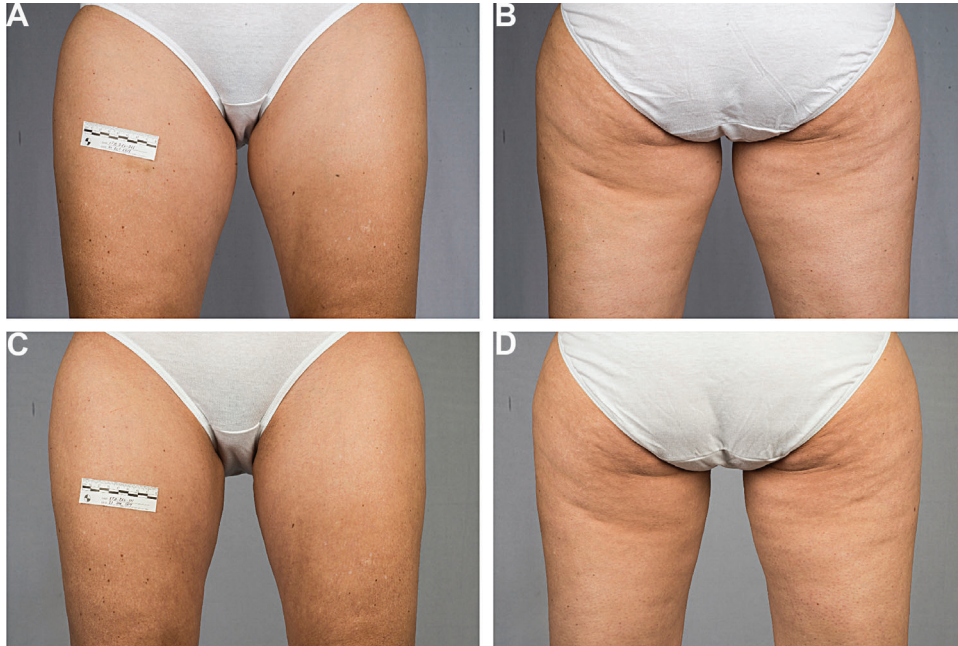


Fig. 3. Baseline (A, B) and 16 week (C, D) post-treatment photos for subject ZEL-011. Weight change  $-1.0$  lbs. from baseline. Procedure by Dr. Brian Zelickson.

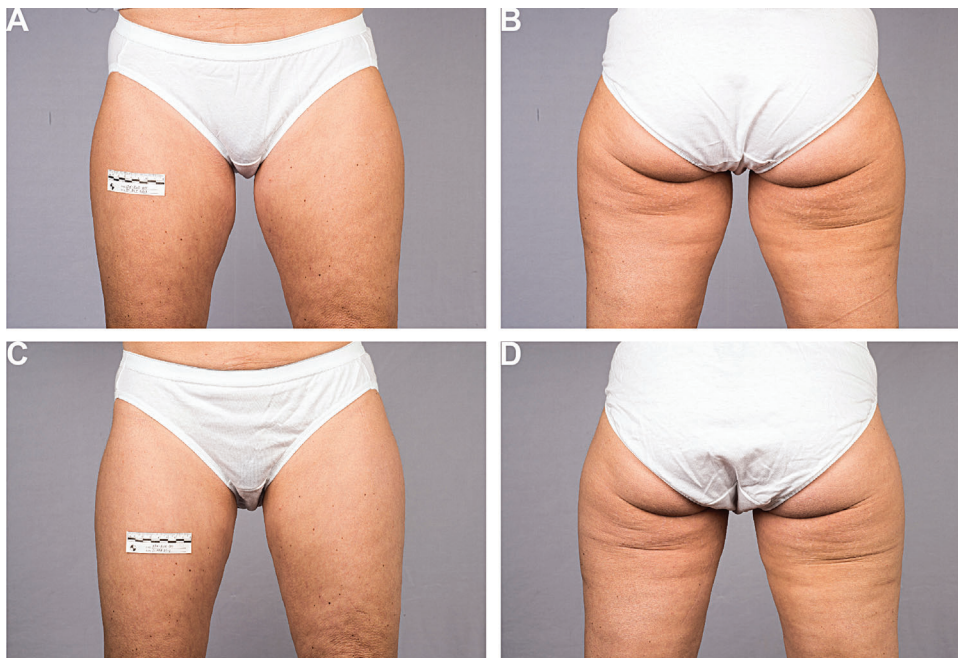

Fig. 4. Baseline (A, B) and 16 week (C, D) post-treatment photos for subject BUR-011. Weight change  $-1.2$  lbs. from baseline. Procedure by Dr. Jay Burns.

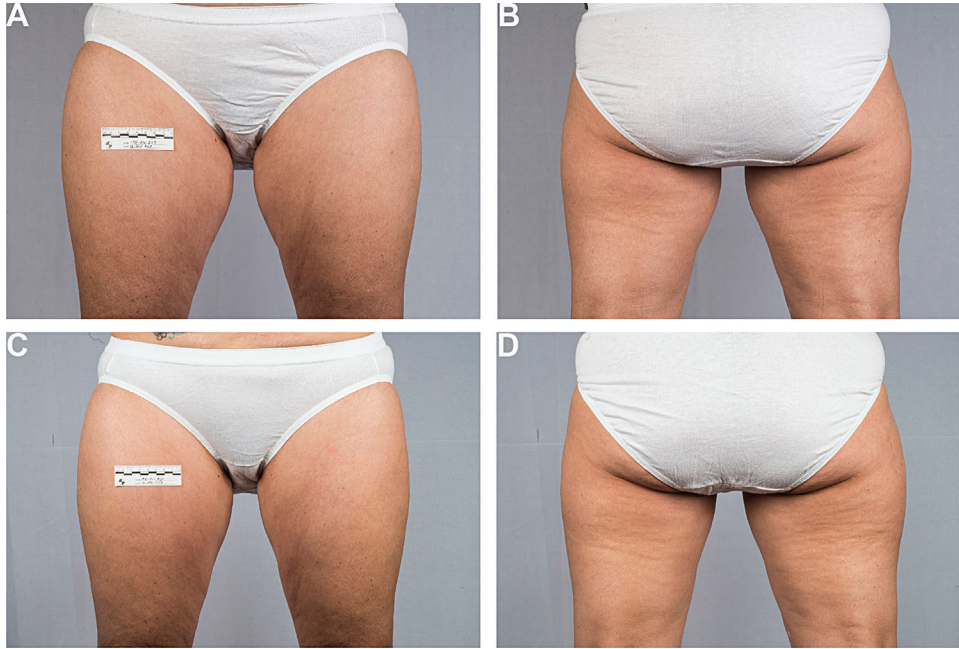

Fig. 5. Baseline (A, B) and 16 week (C, D) post-treatment photos for subject KIL-003. No weight change from baseline. Procedure by Dr. Suzanne Kilmer.

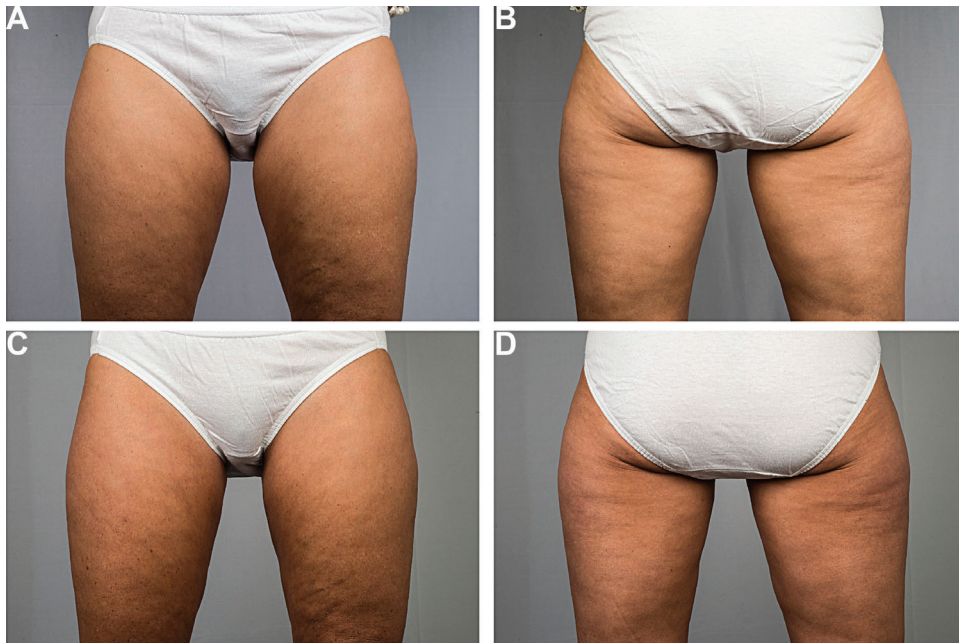

Fig. 6. Baseline (A, B) and 16 week (C, D) post-treatment photos for subject ZEL-008. Weight change -1.0 lbs. from baseline. Procedure by Dr. Brian Zelickson.

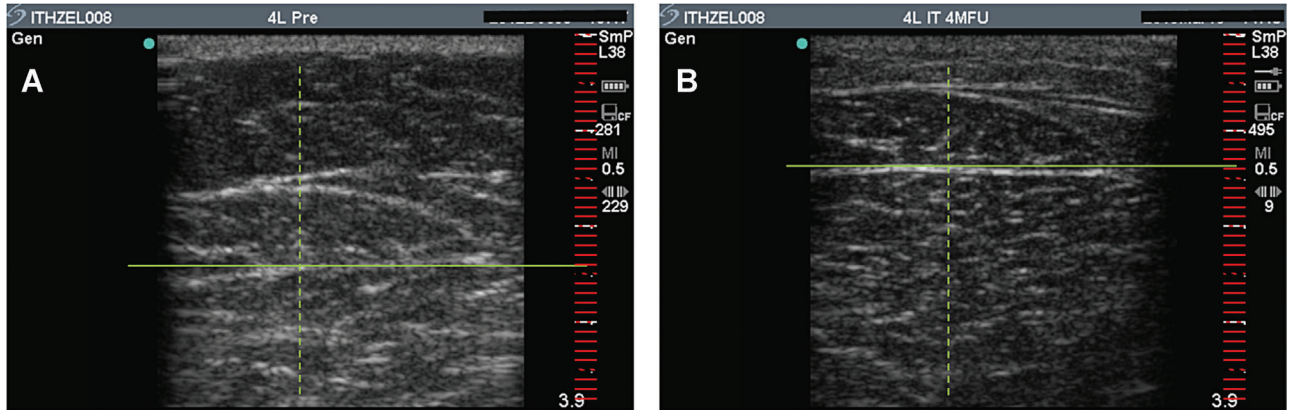


Fig. 7. Baseline (A) and 16 week (B) post-treatment ultrasound images for subject ZEL-008. The same anatomical feature is indicated in the baseline and post-treatment images to demonstrate fat reduction.

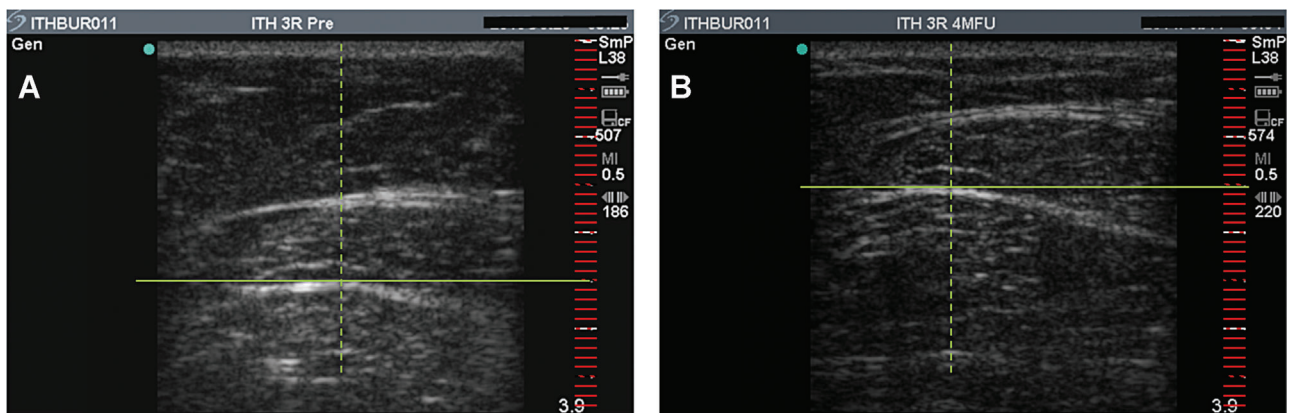


Fig. 8. Baseline (A) and 16 week (B) post-treatment ultrasound images for subject BUR-011. The same anatomical feature is indicated in the baseline and post-treatment images to demonstrate fat reduction.

This has not yet received FDA clearance and the authors caution that when treating arms, patient injury can occur if sufficient care is not exercised. The vacuum applicator should be carefully placed to avoid compression-related or cold-induced injury to superficial blood vessels and nerves in the treatment area.

For the inner thigh treatments discussed in this study, side effects, such as numbness and erythema, were typically mild, transient, and self-resolving. There were no reports of device- or procedure-related serious adverse events. Cryolipolysis treatment of the inner thigh using a flat cup vacuum applicator appears to be safe and produces visible, measurable reduction of the inner thigh contour.

## CONCLUSION

On the basis of these study results, the CoolFit flat cup vacuum applicator was found to deliver safe and effective cryolipolysis treatment to reduce inner thigh fat. Comple-

ed 16-week data from 42 subjects show 2.8 mm reduction of mean fat layer and 0.9 cm reduction in circumference. Blinded physician assessment of clinical photographs found 91% correct identification of the pre-treatment images. The results of this prospective, multi-center, interventional clinical study contributed to FDA clearance of cryolipolysis for treatment of thighs in April 2014.

## ACKNOWLEDGMENT

This clinical study was sponsored by ZELTIQ Aesthetics, manufacturers of the CoolSculpting system. The sponsor provided consumable study supplies, loan of the study applicator and control unit, ultrasound and photography support, and subject and study site compensation.

## REFERENCES

1. Manstein D, Laubach H, Watanabe K, Farinelli W, Zurakowski D, Anderson RR. Selective cryolysis: A novel

- method of non-invasive fat removal. *Lasers Surg Med* 2008;40:595–604.
2. Zelickson B, Egbert BM, Preciado J, Allison J, Springer K, Rhoades RW, Manstein D. Cryolipolysis for noninvasive fat cell destruction: Initial results from a pig model. *Dermatol Surg* 2009;35(10):1462–1470.
  3. Avram MM, Harry RS. Cryolipolysis for subcutaneous fat layer reduction. *Lasers Surg Med* 2009;41(10):703–708.
  4. Rotman H. Cold panniculitis in children. Adiponecrosis E frigore of Haxthausen. *Arch Dermatol* 1966;94:720–721.
  5. Hochsinger C. Über eine akute kongelative Zellgewebsverhärtung in der Submentalregion bei Kindern. *Möschl Kinderheilk* 1902;1:323–327.
  6. Haxthausen H. Adiponecrosis e frigore. *Br J Dermatol* 1941;53:83–89.
  7. Collins HA, Stahlman M, Scott HW Jr. The occurrence of subcutaneous fat necrosis in an infant following induced hypothermia used as an adjuvant in cardiac surgery. *Ann Surg* 1953;138:880–885.
  8. Solomon LM, Beerman H. Cold panniculitis. *Arch Dermatol* 1963;88:897–900.
  9. Epstein EH, Jr, Oren ME. Popsicle panniculitis. *N Engl J Med* 1970;82:966–967.
  10. Stevens WG, Pietrzak LK, Spring MA. Broad overview of a clinical and commercial experience with CoolSculpting. *Aesthet Surg J* 2013;33(6):835–846.
  11. Sasaki GH, Abelev N, Tevez-Ortiz A. Noninvasive selective cryolipolysis and reperfusion recovery for localized natural fat reduction and contouring. *Aesthet Surg J* 2014;34(3):420–431.
  12. Dierickx CC, Mazer JM, Sand M, Koenig S, Arigon V. Safety, tolerance, and patient satisfaction with noninvasive cryolipolysis. *Dermatol Surg* 2013;39:1209–1216.
  13. Boey GE, Wasilenchuk JL. Fat reduction in the inner thigh using a prototype cryolipolysis applicator. *Lasers Surg Med* 2014;40(9):1004–1009.
  14. Zelickson B, Wallander I. Safety and efficacy of cryolipolysis for inner thigh fat reduction. *Lasers Surg Med* 2013;45(4):282.
  15. Munavalli G. Cryolipolysis treatment of male pseudogynecomastia. *Lasers Surg Med* 2013;45(S25):16.
  16. Stevens WG, Bachelor EP. Cryolipolysis conformable surface applicator for non-surgical fat reduction in lateral thighs. *Aesthet Surg J* 2015;in press.