



Retroperitoneal hematoma post percutaneous sacral nerve evaluation: A case report

Nader A. Aldossary^{*}, Magdy Hassouna

Division of Urology University Health Network, University of Toronto, Canada

ARTICLE INFO

Keywords:

SNM
Sacral neuromodulation
PNE
Percutaneous nerve evaluation
Retroperitoneal hematoma
Rivaroxaban
Anticoagulation
Angioembolization

ABSTRACT

Sacral neuromodulation is an accepted therapy for various voiding dysfunction. We report a 71-year-old male with a history of BPH post TURP and overactive bladder. He was on anticoagulants for atrial fibrillation. He underwent uneventful percutaneous sacral nerve evaluation. Five days later, he showed no improvement. Temporary lead was removed in clinic without complications. On day ten, he developed lower abdominal, and genital skin bruising. CT scan showed presacral retroperitoneal hematoma. His Hemoglobin dropped. He was admitted, managed conservatively and discharged with a stable hemoglobin. Retroperitoneal hematoma post PNE is rare. Management is conservative. Angioembolization is reserved for unstable patients.

1. Introduction

Sacral neuromodulation (SNM) was developed in the early 1980s by Tanagho and Schmidt and has become a well-established and widely accepted therapy for refractory overactive bladder, non-obstructive urinary retention, and fecal incontinence.¹ Percutaneous sacral nerve evaluation (PNE) is a reliable and valuable tool for predicting whether the therapy is efficacious, provides adequate symptom relief, and the potential therapeutic success of SNM. It is performed in an office under local anesthesia that involves a 3.5 inch needle placed through the 3rd or 4th sacral foramen with recording of the sensory and/or motor responses to an applied electrical stimulus. A temporary lead, that is, a unipolar wire electrode is placed into the selected sacral foramen and connected to an external pulse generator. The patient experiences a test period for 4–7 days. Patients who demonstrate symptom improvement of >50% based on a voiding diary are considered good candidates for permanent implants. The temporary wire is usually removed in the office. PNE is a low-risk procedure with low complication rates, such as lead migration, infection, and pain.² Severe complications, such as retroperitoneal hemorrhage, can occur. Patients receiving chronic anticoagulation therapy may have a higher risk of such complications.

2. Case report

A 71 year-old male patient with benign prostatic hyperplasia after TURP and overactive bladder underwent uneventful percutaneous sacral nerve evaluation (PNE) without fluoroscopy guidance under local anesthesia with a lead in the left S3 foramen. Both S3 foramen were accessed easily. Five days post-PNE, he did not show improvement in voiding volumes based on PNE. The temporary sacral lead was completely removed in the clinic without complications. On day ten post-PNE, he developed lower abdominal, genital, and perineal skin bruising, prompting him to seek medical attention in the emergency room (Fig. 1a, b). He denied any abdominal or back pain, dizziness, malaise, palpitations, or syncope. There was no history of trauma or similar presentations. His medical history was significant for atrial fibrillation on Rivaroxaban 20 mg for three months. The patient was kept on his anticoagulant before PNE. On physical examination, he had slight tachycardia with suprapubic, genital, and perineal ecchymoses. The rest of the physical exam was unremarkable.

His hemoglobin level was 82 g/L (baseline, 130 g/L), Hematocrit was 0.25 L/L, Platelets count, 191 x10⁹/L and INR, 1.2. Creatine and electrolyte levels were normal. Enhanced computed tomography (CT) showed evidence of retroperitoneal hematoma in the presacral space measuring 6.7 x 7.4 cm. The hematoma extended inferiorly along the left retroperitoneum along the pelvic sidewall, and iliopsoas

Abbreviations: PNE, Percutaneous Nerve Evaluation; SNM, Sacral Neuromodulation.

*** Corresponding author.

E-mail addresses: virucide@gmail.com (N.A. Aldossary), magdy.hassouna@uhn.ca (M. Hassouna).

<https://doi.org/10.1016/j.eucr.2022.102068>

Received 14 February 2022; Received in revised form 18 March 2022; Accepted 23 March 2022

Available online 25 March 2022

2214-4420/© 2022 Published by Elsevier Inc. This is an open access article under the CC BY-NC-ND license (<http://creativecommons.org/licenses/by-nc-nd/4.0/>).

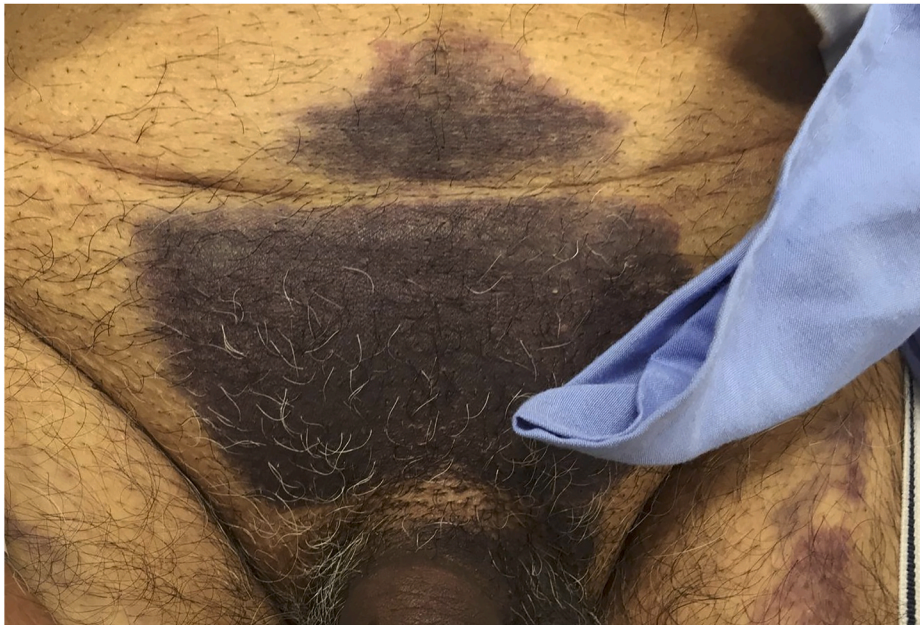

Fig. 1a. Suprapubic ecchymosis.

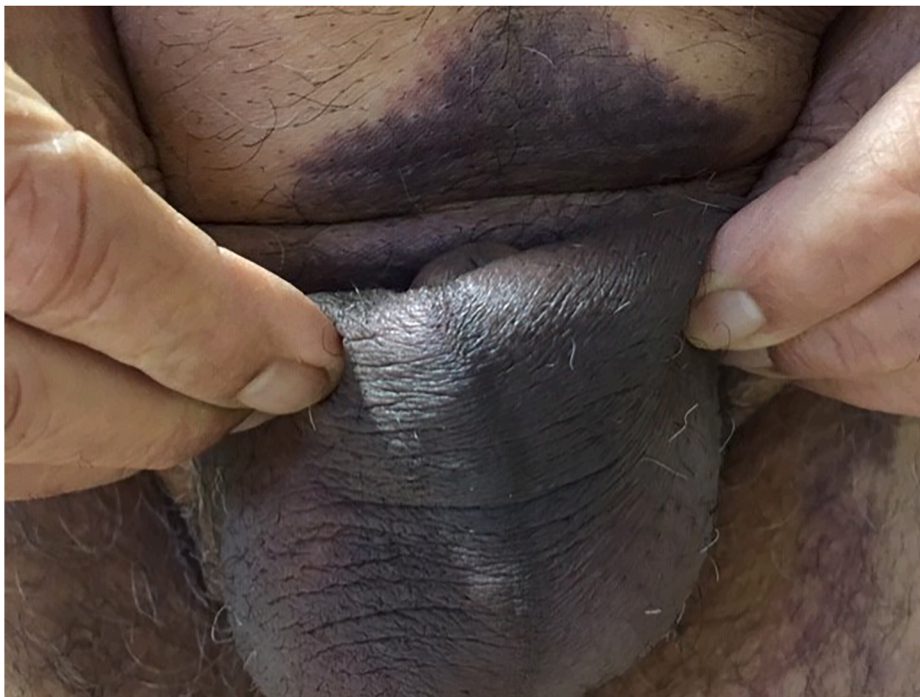

Fig. 1b. Genital ecchymosis.

musculature, and extended inferiorly displacing the rectum and anal canal anteriorly. No evidence of active extravasation was observed. His kidneys, ureters, and urinary bladder were unremarkable (Fig. 2 (A, B, C))

The patient was then admitted for observation. He stayed in the hospital for five days. Rivaroxaban was put on hold after reviewing the patient's cardiac status. The patient was hemodynamically stable during his stay. There was no progression of his ecchymosis. The hemoglobin level stabilized at approximately 77 g/L. No blood transfusions or interventions were required. He was discharged in a stable and satisfactory condition with a plan for follow-up pelvic ultrasonography three months later.

After one month, his hemoglobin level was 99 g/L. Ultrasonography showed resolution of the hematoma.

3. Discussion

A retroperitoneal hematoma post-PNE has not been previously reported in the literature. One case reported of a significant retroperitoneal hematoma after the implant of the permanent neurostimulator in a patient who was on chronic anticoagulation.³ The presacral space is a retroperitoneal space contains a large network of blood vessels including sacral venous plexus and lateral sacral artery which are close anterior sacral foramina. Blind passage of needles into sacral foramina during PNE

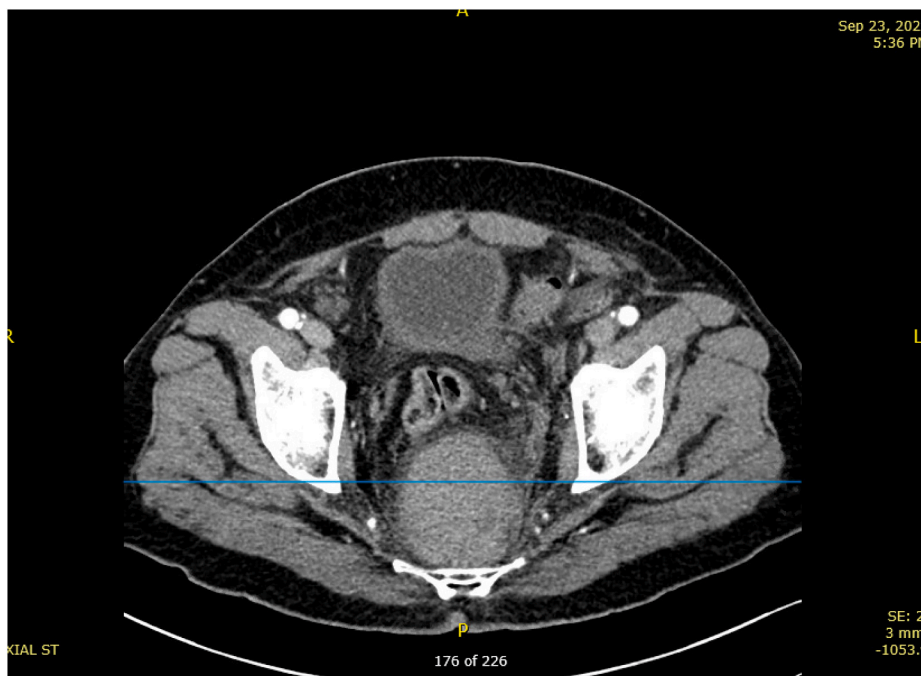


Fig. 2A. Axial CT view demonstrating the retroperitoneal hematoma displacing the rectum and the anal canal anteriorly.

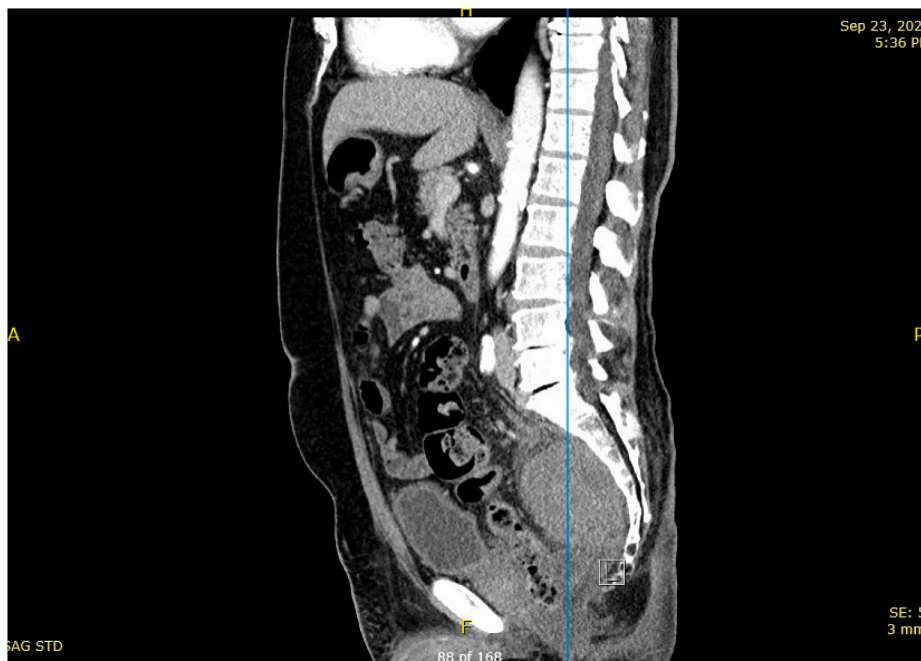

Fig. 2B. Sagittal view showing the hematoma in relation to S3.

put those vessels at risk of injury. It is unlikely to cause significant bleeding or hemorrhage in patients not on anticoagulants. There is a possibility that the anticoagulation therapy contributed to the development of this hematoma.

Retroperitoneal hematomas can be iatrogenic, traumatic, or spontaneous. It can be managed conservatively if it is small and the patient is hemodynamically stable.

If hematoma is significant with hemodynamic instability, appropriate resuscitation and angioembolization is first line.⁴ The American College of Chest Physicians guidelines recommend to stop Rivaroxaban 2–3 days before the elective procedure for low/moderate risk

procedures and can be resumed one day post-procedure. Rivaroxaban has rapid onset and requires no bridging except in rare cases. Warfarin is stopped 5 days pre-operatively and bridging is required.⁵

4. Conclusions

Retroperitoneal hematoma is a potential complication of PNE in patients receiving anticoagulation therapy. The possibility of this complication should be discussed with the patient during preoperative counseling. A multidisciplinary approach is critical for the management of large retroperitoneal hematomas in patients receiving

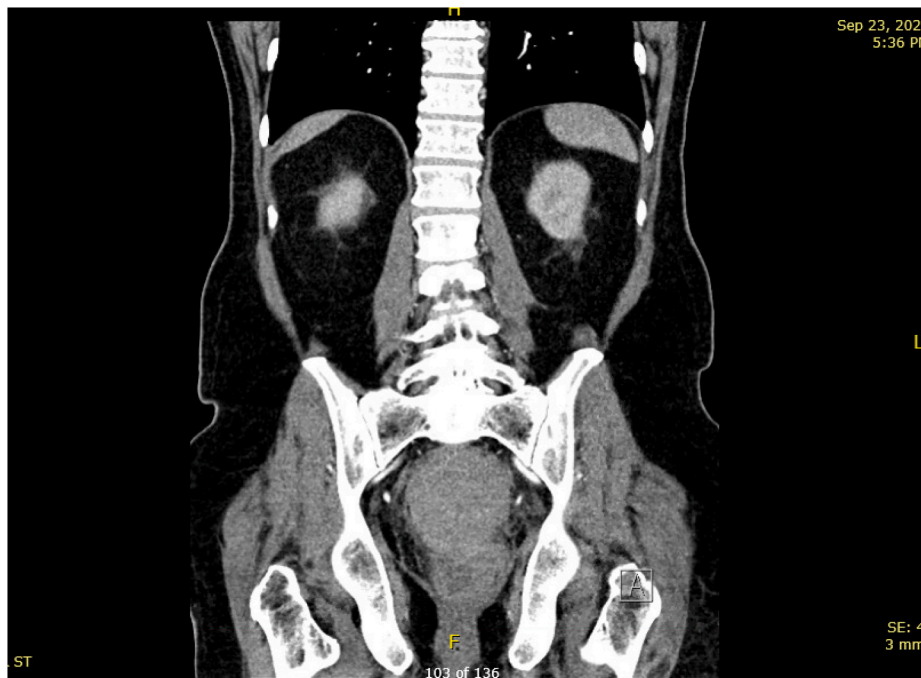

Fig. 2C. Coronal view shows no evidence of extravasation.

anticoagulation therapy. PNE is a low-risk procedure, but holding anticoagulants before PNE may be considered for patients at a high risk of bleeding. Retroperitoneal hematoma can be managed conservatively in hemodynamically stable patients. Appropriate resuscitation and angioembolization are the first-line treatments for patients who are hemodynamically unstable.

References

1. Hassouna MM, Siegel SW, Nycholt AA, et al. Sacral neuromodulation in the treatment of urgency-frequency symptoms: a multicenter study on efficacy and safety. *J Urol*. 2000 Jun;163(6):1849–1854.
2. Maeda Yasuko, Matzel Klaus, Lundby Lilli, Buntzen Steen, Laurberg Søren. Postoperative issues of sacral nerve stimulation for fecal incontinence and constipation: a systematic literature review and treatment guideline. *Dis Colon Rectum*. 2011 Nov;54(11):1443–1460.
3. Kinman CL, Hobson DTG, Agrawal A, Vyleta MS, Francis SL. Retroperitoneal hemorrhage after sacral neurostimulator placement for urgency urinary incontinence. *Female Pelvic Med Reconstr Surg*. 2017;23(4):e29–e31.
4. Salcedo ES, Brown IE, Corwin MT, et al. Pelvic angioembolization in trauma—indications and outcomes. *Int J Surg*. 2016;33:231–236.
5. Douketis JD, Spyropoulos AC, Spencer FA, et al. Perioperative management of antithrombotic therapy: antithrombotic therapy and prevention of thrombosis, 9th ed: American College of chest Physicians evidence-based clinical practice guidelines. *Chest*. 2012;141(2):e326S–e350S.