

Surgical management of acute type A aortic dissection in complicated cases: experience with branch-first aortic arch replacement technique

Cun-Hua Su, Wei Qin, Wen Chen, Jian Li, Michael Carmichael, Fu-Hua Huang, Xin Chen

Department of Thoracic and Cardiovascular Surgery, Nanjing First Hospital, Nanjing Medical University, Nanjing, Jiangsu 210006, China.

Type A dissection involving the aortic arch remains an inherently lethal condition. Sun *et al*^[1] recommended total arch replacement combined with stented elephant trunk implantation as a new “standard” therapy for type A dissection involving repair of the aortic arch. Cannulation of the right axillary artery is used for cardiopulmonary bypass (CPB) and selective cerebral perfusion in this procedure.^[1] However, this procedure may not be applied in some special cases, such as aberrant right subclavian arteries, serious involvement of the right subclavian artery, serious involvement of the right common carotid artery, and acute pericardial tamponade. The branch-first aortic arch replacement technique can adequately solve these problems. We analyzed the surgical data and midterm follow-up outcomes of this technique.

Between June 2017 and January 2019, 15 patients underwent the branch-first aortic arch replacement technique. Six patients had acute pericardial tamponade (systolic blood pressure was <80 mmHg with intravenous injection of norepinephrine pre-operation), four patients had an aberrant right subclavian artery, three patients had serious involvement of the right subclavian artery, and two patients had serious involvement of the right common carotid artery. Among all patients, three had acute left/right lower limb ischemia and two had acute bilateral lower limb ischemia. All patients underwent surgery within 24 h of onset.

The left side of the upper limb, left or right lower limb blood pressure, and nasopharyngeal and bladder temperatures were continuously monitored intra-operatively. A midline incision was made along the sternum. Then, the innominate artery, left common carotid artery, and left subclavian artery were extensively dissected 5 to 6 cm. At the same time, the right femoral artery was exposed. After heparinization, the femoral artery was intubated. If necessary (patients with acute pericardial tamponade), CPB was immediately established via the femoral artery and femoral venous

cannulation. Two extracorporeal circulation arterial pump tubes were separated through the “Y” joint: one was connected with femoral artery intubation, and the other was connected with the 10 mm perfusion branch of the four branches of the aortic graft.

The main branch and the other three branches of the artificial vessel were clamped and vented. The pericardium was incised, and venous intubation of the right atrium was performed to establish CPB. Then, the left subclavian artery, the left common carotid artery, and the innominate artery were reconstructed via an end-to-end anastomosis to the three branches of the artificial vessel, while the temperature was lowered. The proximal part of the arch branches was closed with a locking clip, and the distal part was end-to-end anastomosed with the branch of the artificial vessel. When the bladder temperature decreased to 28°C, the ascending aorta was cross clamped, and the heart was arrested using antegrade cold blood cardioplegia. After cardiac arrest, the arch of the aorta was cut open, and then the frozen elephant trunk stent was implanted and anastomosed with the distal main trunk of the four branches of the aortic graft. During this period, although lower body perfusion was stopped, the whole cerebral perfusion was continued. Cerebral oxygen saturation was also used to adjust cerebral perfusion flow intra-operatively (maintaining cerebral oxygen saturation $\geq 70\%$ of the base value before CPB). After the distal anastomosis was completed, systemic blood perfusion was restored, and the patient was gradually rewarmed. The proximal aortic anastomosis and other concomitant operations were carried out during the rewarming period, and then the coronary blood flow was restored [Figure 1A–1F].

Concomitant operations in this study of 15 patients included one (6.7%) valve-sparing root replacement, three (20%) composite valve-graft root replacements, three (20%) partial aortic sinus replacements, one (6.7%)

Access this article online

Quick Response Code:



Website:

www.cmj.org

DOI:

10.1097/CM9.0000000000001436

Correspondence to: Xin Chen and Fu-Hua Huang, Department of Thoracic and Cardiovascular Surgery, Nanjing First Hospital, Nanjing Medical University, Nanjing, Jiangsu 210006, China
E-Mail: stevecx@njmu.edu.cn; huangfuhua@sina.cn

Copyright © 2021 The Chinese Medical Association, produced by Wolters Kluwer, Inc. under the CC-BY-NC-ND license. This is an open access article distributed under the terms of the Creative Commons Attribution-Non Commercial-No Derivatives License 4.0 (CCBY-NC-ND), where it is permissible to download and share the work provided it is properly cited. The work cannot be changed in any way or used commercially without permission from the journal.

Chinese Medical Journal 2021;134(8)

Received: 15-10-2020 Edited by: Ning-Ning Wang

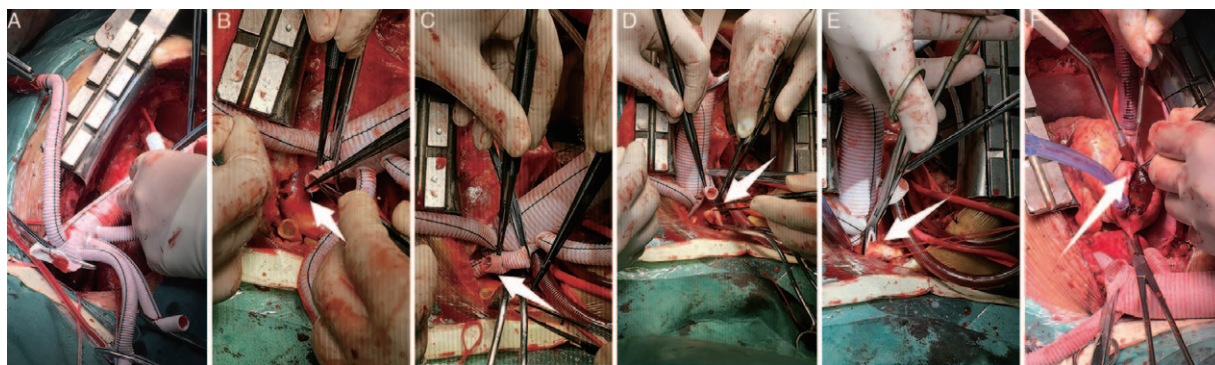


Figure 1: The main branch and the other three branches of the artificial vessel were clamped and vented (A); the left subclavian artery was reconstructed via an end-to-end anastomosis to the branch of the artificial vessel (B); the left common carotid artery was reconstructed via an end-to-end anastomosis to the branch of the artificial vessel (C); the proximal part of the arch branches was closed with a locking clip to reduce the operation time and simplify the surgery (E); the proximal aortic anastomosis and other concomitant operations were then carried out during the rewarming period (F).

external shunt placement from the aorta to the right femoral artery, one (6.7%) closure of a patent foramen ovale, and one (6.7%) CABG (aorta-saphenous vein-right coronary artery [AO-SV-RCA]). The mean CPB time was 133.4 ± 20.0 min, the mean aortic cross-clamp time was 68.1 ± 25.8 min, and the mean lower body circulatory arrest time was 18.3 ± 5.5 (range, 14–25) min. The mean bladder temperature of hypothermic circulatory arrest was $27.8 \pm 0.85^\circ\text{C}$ (range, 26–29).

In our study, all 15 patients recovered and were discharged smoothly without significant permanent neurological deficits. The mean consciousness recovery time was 6 to 22 h. One patient (6.7%) exhibited temporary neurologic dysfunction. He showed paroxysmal mood abnormalities and confusion 3 days after the operation and made a full recovery before discharge. 13 (86.7%) patients were weaned from ventilator-assisted ventilation within 48 h, with an intensive care unit stay of 2 to 5 days. The acute renal injury appeared in three patients after surgery. Two of them presented with a slight increase in serum creatinine, and the urine output was good in the short term after surgery. One of them was treated with hemodialysis, and renal function recovered before discharge.

For cases of type A dissection with severe involvement of the arch, total arch replacement combined with stented elephant trunk implantation demonstrates the superiority of the combination of surgical and interventional approaches while avoiding the weaknesses associated with individual methods.^[1] Additionally, for patients with total arch replacement, unilateral selective antegrade cerebral perfusion with moderate hypothermic circulatory arrest may represent an optimal strategy for cerebral protection, as it has been associated with significant reductions in death and stroke.^[2] Right axillary artery cannulation is superior to cannulation at other sites, as it can facilitate the administration of selective cerebral perfusion during the aortic arch repair.^[3] However, sometimes we may encounter a few complicated cases. As it has been indicated that supra-aortic branches are involved in the dissection process in up to 37% of patients presenting with acute type A dissection,^[4] we might face some patients with serious involvement of the right

subclavian artery or the right common carotid artery. In some patients with a right subclavian artery or right common carotid artery dissection, the true lumen was very small, and the intima was fragile. Severe iatrogenic injury occasionally occurred when we isolated the dissected right subclavian artery. In addition, there were some patients with entry located in the innominate artery. Unilateral selective antegrade cerebral perfusion via right axillary artery cannulation was very difficult and could lead to some fatal consequences in this situation. Among patients with acute type A aortic dissection, acute pericardial tamponade (systolic blood pressure was below 80 mmHg with norepinephrine intravenous injection pre-operation) was sometimes present, indicating that the aortic dissection had ruptured or was about to rupture. Therefore, we did not have plenty of time to carefully isolate and expose the right subclavian artery. Establishing CPB via the femoral artery and femoral venous cannulation as soon as possible and providing adequate cerebral perfusion as soon as possible were necessary. An aberrant right subclavian artery occurs in approximately 0.5% of the population.^[5] For these patients, right axillary artery cannulation cannot provide adequate cerebral perfusion. Several patients with acute type A aortic dissection suffered from severe lower limb ischemia. The onset-to-intervention time for suitable revascularization is considered to be within 6 h (otherwise known as the “golden time”). Restoration of lower limb perfusion as soon as possible can maximally recover lower limb function and avoid shunting from the aorta or contralateral femoral artery. Cannulation of the involved femoral artery via a Dacron graft anastomosed in an end-to-side fashion to the true lumen can provide adequate lower limb perfusion. Whether femoral arterial cannulation increases the risk of post-operative stroke is controversial. Some studies have shown no differences in the rate of stroke with femoral cannulation.^[6] In our study, for various reasons, right axillary artery cannulation was not the best option. Therefore, the femoral artery was the dominant cannulation strategy. Luckily, no post-operative stroke associated with femoral arterial cannulation was observed in our study. We speculated that this might be related to the lower age (50.5 ± 10.2 years) of patients, which might have reduced the risk of atherogenesis. We believe that further

large, prospective studies are required given the controversial findings.

Cerebral protection has always been a cornerstone of successful arch surgery. The results of the German Registry for Acute Aortic Dissection Type A indicated that surgery under antegrade cerebral perfusion with circulatory arrest <30 min resulted in a 15.4% mortality rate.^[7] Stroke is a common complication after type A aortic dissection repair.^[8] Mortality and morbidity are directly related to the circulatory arrest time. In our study, the mean lower body circulatory arrest time was 18.3 ± 5.5 min (range, 14–25). It was obviously shorter than the duration of the classic total aortic arch replacement technique. Instead of using the right axillary artery for unilateral antegrade cerebral perfusion, the bilateral common carotid arteries, bilateral vertebral arteries, and extracranial collaterals were also perfused via our branch-first aortic arch replacement technique. Whole cerebral perfusion was performed on all patients during the lower body circulatory arrest period in our study, and we obtained encouraging results. All patients survived with no serious neurological complications related to surgery. None of them presented with permanent neurological deficits. All patients regained consciousness within 24 h, and the minimum time was 6 h. Most of the patients were weaned from mechanical ventilation within 48 h.

It is known that the aortic cross-clamp time has a significant impact on in-hospital mortality and almost all major post-operative complications. In this study, we reconstructed the three supra-arch branches before aortic cross-clamping. Cardiac perfusion is maintained throughout the whole of the arch branch reconstruction phase, significantly reducing the period of time of reliance on cardioplegia. In our study, cold blood cardioplegia was intermittently perfused after ventricular fibrillation was demonstrated during the cooling phase. Aortic root reconstruction was performed during the rewarming period. Therefore, the mean aortic cross-clamp time was greatly reduced by the use of the branch-first aortic arch replacement technique. Our mean aortic cross-clamp time was only 68.1 ± 25.8 min. It was also obviously shorter than the duration of the classic total aortic arch replacement technique. Furthermore, all patients survived perioperatively and during the follow-up period. In addition, complications were rare and acceptable. Without permanent neurological deficits, only one patient presented with temporary mental abnormalities. One patient presented with acute kidney function insufficiency during the perioperative period and recovered 1 week later. The re-exploration rate for bleeding in this study was 0. The results are encouraging.

This report has the inherent limitations of any retrospective analysis of a small study and single surgeon bias. As more centers explore this technique and as a longer follow-up duration is obtained, we hope that confidence can be achieved in terms of the technical difficulty and that good survival and cerebral protection can be achieved with branch-first aortic arch replacement technique for aortic arch repair in patients with type A aortic dissection.

Our findings support using the branch-first aortic arch replacement technique for patients with complicated cases

of acute type A aortic dissection. This technique can improve neurological outcomes as well as reduce mortality and the incidence of cerebral and other complications. More consistent reporting of outcomes and higher levels of evidence are required to further corroborate this technique.

Declaration of patient consent

The authors certify that they have obtained all appropriate patient consent forms. In the form, the patient(s)/patient's guardians has/have given his/her/their consent for his/her/their images and other clinical information to be reported in the article. The patients/patient's guardians understand that their names and initials will not be published and due efforts will be made to conceal the identity of the patient, although anonymity cannot be guaranteed.

Funding

This work is supported by the grants from the Jiangsu Provincial Special Program of Medical Science (BE2017610) and the Jiangsu Provincial Key Medical Discipline (Laboratory) (ZDXKA2016021).

Conflicts of interest

None.

References

- Sun L, Qi R, Zhu J, Liu Y, Zheng J. Total arch replacement combined with stented elephant trunk implantation: a new "standard" therapy for type a dissection involving repair of the aortic arch? *Circulation* 2011;123:971–978. doi: 10.1161/CIRCULATIONAHA.110.015081.
- Wang X, Yang F, Zhu J, Liu Y, Sun L, Hou X. Aortic arch surgery with hypothermic circulatory arrest and unilateral antegrade cerebral perfusion: perioperative outcomes. *J Thorac Cardiovasc Surg* 2020;159:374–387.e4. doi: 10.1016/j.jtcvs.2019.01.127.
- Benedetto U, Mohamed H, Vitulli P, Petrou M. Axillary versus femoral arterial cannulation in type A acute aortic dissection: evidence from a meta-analysis of comparative studies and adjusted risk estimates. *Eur J Cardiothorac Surg* 2015;48:953–959. doi: 10.1093/ejcts/ezv035.
- Rylski B, Hoffmann I, Beyersdorf F, Suedkamp M, Siepe M, Nitsch B, *et al.* Acute aortic dissection type A: age-related management and outcomes reported in the German Registry for Acute Aortic Dissection Type A (GERAADA) of over 2000 patients. *Ann Surg* 2014;259:598–604. doi: 10.1097/SLA.0b013e3182902cca.
- Branscom JJ, Austin JH. Aberrant right subclavian artery. Findings seen on plain chest roentgenograms. *Am J Roentgenol Radium Ther Nucl Med* 1973;119:539–542. doi: 10.2214/ajr.119.3.539.
- Etz CD, von Aspern K, da Rocha ESJ, Grrbach FF, Leontyev S, Luehr M, *et al.* Impact of perfusion strategy on outcome after repair for acute type a aortic dissection. *Ann Thorac Surg* 2014;97:78–85. doi: 10.1016/j.athoracsur.2013.07.034.
- Kruger T, Weigang E, Hoffmann I, Blettner M, Aebert H. GERAADA Investigators. Cerebral protection during surgery for acute aortic dissection type A results of the German Registry for acute aortic dissection type A (GERAADA). *Circulation* 2011;124:434–443. doi: 10.1161/Circulationaha.110.009282.
- Ghoreishi M, Sundt TM, Cameron DE, Holmes SD, Roselli EE, Pasrija C, *et al.* Factors associated with acute stroke after type A aortic dissection repair: an analysis of the Society of Thoracic Surgeons National Adult Cardiac Surgery Database. *J Thorac Cardiovasc Surg* 2019;159:2143–2154.e3. doi: 10.1016/j.jtcvs.2019.06.016.

How to cite this article: Su CH, Qin W, Chen W, Li J, Carmichael M, Huang FH, Chen X. Surgical management of acute type A aortic dissection in complicated cases: experience with branch-first aortic arch replacement technique. *Chin Med J* 2021;134:978–980. doi: 10.1097/CM9.0000000000001436