



## Case report

# Combined pulmonary fibrosis and emphysema with myeloperoxidase-antineutrophil cytoplasmic antibody positivity that resolved upon smoking cessation

Masahiro Nemoto<sup>a</sup>, Satoshi Noma<sup>a,b,\*</sup>, Ayumu Otsuki<sup>a</sup>, Kei Nakashima<sup>a</sup>, Koichi Honma<sup>c</sup>, Takeshi Johkoh<sup>d</sup>, Junya Fukuoka<sup>c,e</sup>, Masahiro Aoshima<sup>a</sup>

<sup>a</sup> Department of Pulmonary Medicine, Kameda Medical Center, Japan

<sup>b</sup> Department of Pulmonary Medicine, Shonan Kamakura General Hospital, Japan

<sup>c</sup> Department of Pathology, Kameda Medical Center, Japan

<sup>d</sup> Department of Radiology, Kinki Central Hospital of Mutual Aid Association of Public School Teachers, Japan

<sup>e</sup> Department of Pathology, Nagasaki University Graduate School of Biomedical Sciences, Japan

## ARTICLE INFO

## Keywords:

Combined pulmonary fibrosis and emphysema  
Myeloperoxidase-antineutrophil cytoplasmic antibody

## ABSTRACT

Myeloperoxidase antineutrophil cytoplasmic autoantibody (MPO-ANCA) is well-known as a serological marker for small-vessel vasculitis. However, when a smoker with interstitial lung disease (ILD) exhibits serum ANCA positivity without systemic vasculitis, diagnosis is a matter of debate; the relationship between smoking and ANCA is unknown. We report a case of combined pulmonary fibrosis and emphysema (CPFE) with elevated MPO-ANCA. Surgical lung biopsy showed emphysema and fibrotic interstitial pneumonia without vasculitis. The MPO-ANCA level decreased after smoking cessation, and no vasculitis or progression was observed during 3 years of follow-up. This suggested that smoking cessation was related to normalization of MPO-ANCA and corresponding disease activity.

## 1. Introduction

Cigarette smoking has been related to various interstitial lung diseases, which are generally classified as smoking-related interstitial lung disease (SR-ILD) [1]. Combined pulmonary fibrosis and emphysema (CPFE) has also been reported as a subtype of SR-ILD [2].

Myeloperoxidase antineutrophil cytoplasmic autoantibody (MPO-ANCA) is a useful marker for the diagnosis of antineutrophil cytoplasmic antibody-associated vasculitis (AAV) and is known to be associated with pathogenesis and disease activity. One study reported that the positive and negative predictive value of ANCA for ANCA-associated systemic vasculitis is 79% and 63%, respectively [3]. In contrast, some studies have reported cases of IP with serum MPO-ANCA positivity and no vasculitis; most of these patients did not progress to AAV over the course of the disease [4,5]. These findings suggest that ANCA levels might be elevated in a non-specific manner.

Furthermore, elevated ANCA levels may be also observed as a result of various diseases, drug use, and occupational exposure; cigarette smoking has been a notable exception [6,7]. Although such reports have made clinicians attach less importance to serum ANCA, there have

been several reports of patients previously diagnosed with ILD, including CPFE, that later developed AAV [8,9]. Thus, the meaning of elevated ANCA is sometimes unclear, but it is not negligible. To our knowledge, there have been no case report regarding the complications of SR-ILD with elevated MPO-ANCA levels that resolved only with smoking cessation. We herein report a case of unclassifiable idiopathic interstitial pneumonia (unclassifiable IIP) with prominent feature of CPFE with elevated MPO-ANCA levels that showed normalization only with smoking cessation.

## 2. Case report

A 57-year-old Japanese man who showed a chest radiographic abnormality without any symptoms during a medical checkup visited our clinic. He worked as a newspaper deliverer and had smoked 40 cigarettes daily for the past 40 years. Dust and bird exposure and family history were unremarkable. The patient showed no abnormal vital signs or findings in physical examination, including lung auscultation, skin and musculoskeletal assessments, and vasculitis was not suspected. The modified British medical council scale score was zero, and the six-

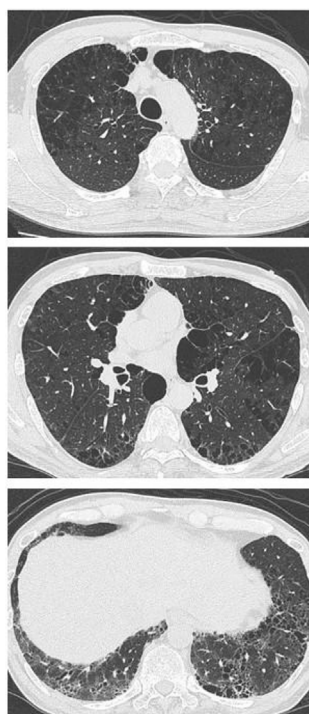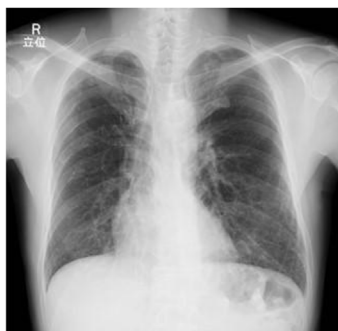\* Corresponding author. Department of Pulmonary Medicine, Kameda Medical Center, Japan.

E-mail address: [s.noma@shonankamakura.or.jp](mailto:s.noma@shonankamakura.or.jp) (S. Noma).

<https://doi.org/10.1016/j.rmcr.2018.08.022>

Received 16 August 2018; Received in revised form 25 August 2018; Accepted 25 August 2018

2213-0071/ © 2018 The Authors. Published by Elsevier Ltd. This is an open access article under the CC BY-NC-ND license (<http://creativecommons.org/licenses/by-nc-nd/4.0/>).



**Fig. 1.** Imaging findings at the initial examination. Chest radiography showed hyperlucency in both lungs and bilateral coarse reticular shadows in the lower lung field. On high-resolution CT, both centrilobular and paraseptal emphysema were seen in the upper lung zones on both sides and bilateral subpleural reticular and ground-glass opacities surrounding the emphysematous cysts were found in the lower lobes.

minute walk test showed normal distance of 520 m without desaturation. The pulmonary function test revealed normal values for VC (3.70 L; 102.5% of the predicted value), FEV1 (3.12 L; 105% of the predicted value), and FEV1/FVC (84%). We found moderate reduction in diffusing capacity for carbon monoxide (13.01 mmol/min/kPa—66.2% of the predicted value). Blood gas examination revealed normoxia (87.5 mmHg) and negative results for urine blood and protein. The other laboratory tests showed elevated levels of Krebs Von den Lungen-6 (KL-6) [825 U/ml] and MPO-ANCA [31.7 RU/mL] (Normal range; < 20 RU/mL). Chest radiography showed hyperlucency in both lungs and bilateral coarse reticular shadows in the lower lung field. (Fig. 1). On high-resolution CT, both centrilobular and paraseptal emphysema were seen in the upper lung zones on both sides, and bilateral subpleural reticular and ground-glass opacities surrounding the emphysematous cysts were found in the lower lobes. (Fig. 1). There was no obvious honeycombing. A month later, bronchoalveolar lavage (BAL) was performed. The total cell count in the BAL fluid was  $1.75 \times 10^5$ /ml. The cell fraction contained 72% lymphocytes and 28% macrophages. The lymphocyte CD4/CD8 ratio was 1.24. The patient was offered rheumatological consultation for the ANCA positivity, but the findings were negative for systemic vasculitis. In the differential diagnosis based on clinical and radiological information, we considered SR-ILDs, such as idiopathic pulmonary fibrosis (IPF), and CPFE, lung-limited AAV, and unclassifiable IIP. Video-assisted thoracoscopic lung biopsy at right segments 2, 5, and 8 was performed one month later. The histopathological examination showed emphysema and inflammatory cell infiltration with airway-centered respiratory bronchitis on segment 2. Some part of segment 8 showed a nonspecific interstitial pneumonia (NSIP) pattern, while others showed a usual interstitial pneumonia (UIP) pattern, such as few fibroblast foci with chronic fibrosis and abrupt changes in normal lesions with microscopic honeycombing (Fig. 2). There were no signs of vasculitis, granuloma, and other causes of ILD.

After multidisciplinary discussion (MDD) based on the clinical, radiological, and pathological findings, we diagnosed unclassifiable IIP with prominent feature of CPFE, based on the American Thoracic Society/European Respiratory Society 2013 statement of IIPs [10]. The patient received follow-up examinations without any medication, and

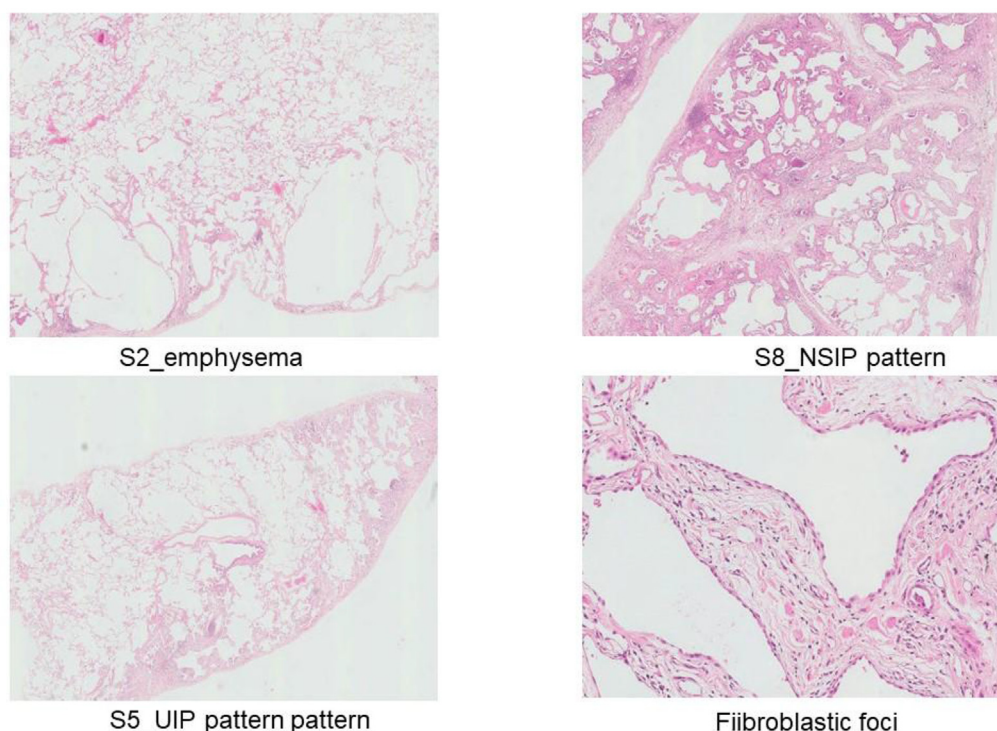
the MPO-ANCA positivity was resolved (15.2 RU/mL) only with smoking cessation for four months, with no progression of ILD noted over the 3-year follow-up period without re-elevation of MPO-ANCA. This finding suggests an association between smoking and MPO-ANCA positivity (see Table 1).

Treatment with an anti-fibrotic agent or lung transplantation was planned if the disease showed a progressive course, but the patient showed no change in the lung condition over 3 years of follow-up examinations after smoking cessation, and the MPO-ANCA status was within a normal range at 3 months after the VATS operation (Table 2 and Fig. 3).

### 3. Discussion

SR-ILD is a broad concept of ILD that includes IPF, CPFE, respiratory bronchiolitis-associated interstitial lung disease (RB-ILD), and desquamative interstitial pneumonia (DIP) [10]. CPFE is typically associated with a poor prognosis when it presents with IPF; however, the prognosis and disease behavior of CPFE without IPF have remained unknown [11].

ANCA was first described in patients with segmental necrotizing glomerulonephritis by Davies et al. [12]. Since then, many studies have presented measurement methods for this marker and described the high accuracy of its positive predictive value. However, the value of lung-limited AAV is obscure [3]. Notably, one study reported that 7.2% of patients with IPF tested positive for ANCA (4% MPO and 3.2% PR3) at the initial evaluation, without any signs of vasculitis; 11% of these patients later developed ANCA positivity (5.7% MPO, 5.3% PR3) [8]. A clinical diagnosis of microscopic polyangiitis (MPA) developed in 25% of those patients with a positive MPO-ANCA [8]. ILD was sometimes the initial manifestation of MPA [13]. In the differential diagnosis of this case, IPF, CPFE, and potential development of AAV, several choices were considered for treatment, including smoking cessation, lung transplant, anti-fibrotic medication, or immunosuppressant administration. Even if AAV does not develop in patients with ANCA positivity, one report stated that the presence of MPO-ANCA positivity itself was an unfavorable prognostic factor in patients with IP [14]. Thus, surgical biopsy and MDD was a reasonable diagnostic strategy.



**Fig. 2.** VATS lung biopsy showed emphysema and inflammatory cell infiltration with airway-centered respiratory bronchitis on segment 2, and some part of segment 8 showed non-specific interstitial pneumonia (NSIP)-like diffuse fibrotic changes, while others showed unusual interstitial pneumonia (UIP)-like peripheral chronic fibrosis adjacent with a normal lung, a few fibroblastic foci, and microscopic honeycombing. There were no signs of vasculitis, granuloma, and other causes of ILD.

The most common chest CT and pathological findings in ANCA-associated ILD generally demonstrate a UIP pattern [4,14]. Hosoda et al. reported that increased attenuation around honeycombing and cysts were frequently observed in the radiological and pathological features of UIP associated with MPO-ANCA [5]; another paper reported capillaritis as the most common vascular abnormality [15]. In this case, chest HRCT showed moderate paraseptal emphysema, reticular opacities with enlarged cysts and traction bronchiolectasis but no obvious honeycombing. Both UIP and NSIP patterns were present in the pathological findings of lung biopsy specimens. Although those findings did not rule out ANCA-associated ILD, negative capillaritis and positive airway-centered respiratory bronchitis make it less likely [15].

**4. Increased attenuation around honey-combing and cysts was significantly observed in ANCA/UIP**

A previous study reported that 7 of 40 CPFE patients were positive for MPO-ANCA and that MPA was diagnosed in three of these seven

**Table 2**

Follow-up data.

Follow-up time	Initial	1 year	2 years
Serum MPO-ANCA (RU/mL)	31.7	14.3	3.9
Serum PR3-ANCA (RU/mL)	2.0 >	2.0 >	2.0 >
Serum KL-6 (U/mL)	825	737	766
FVC (L)	3.70	3.74	3.64
predicted FVC (%)	102.5	104.2	102
DLCO (%)	66.2	66.8	86.0
DLCO/VA (%)	64.5	68.3	82.6

patients. The remaining 4 CPFE patients with positive p-ANCA findings had an asymptomatic microscopic hematuria with normal renal function [9]. That study also reported that smoking exposure causes chronic lung inflammation and lung injury that may increase circulating neutrophils and progress to the production of MPO-ANCA, and that this process may continue even after smoking cessation [9]. However, in our

**Table 1**

Initial laboratory data.

<b>Peripheral blood</b>		<b>KL-6</b>	825 ng/ml	<b>Pulmonary function test</b>	
WBC	6800/mm <sup>3</sup>	SP-A	91.7 ng/ml	VC	3.73 L
Neu	58.1%	SP-D	53.0 ng/ml	%VC	103.3%
Ly	29.6%	MPO-ANCA	31.7 RU/ml	FEV <sub>1</sub>	3.12 L
Mo	3.7%	PR3-ANCA	< 2.0 RU/ml	FEV <sub>1</sub> %	84.0%
Eo	8.0%	<b>Arterial blood gas</b>		%DLco	66.2%
Hb	15.1 g/dl	pH	7.37	%DLCO/VA	64.5%
Ht	43.9%	PaCO <sub>2</sub>	42.8 mmHg	<b>Bronchoalveolar lavage fluid</b>	
Plt	18.8 × 10 <sup>4</sup> /mm <sup>3</sup>	PaO <sub>2</sub>	87.5 mmHg	Total cell count	1.75 × 10 <sup>5</sup> /mm <sup>3</sup>
<b>Biochemistry</b>		HCO <sub>3</sub>	24.7 mmol/l	Lymphocyte	72%
TP	7.3 g/dl	SaO <sub>2</sub>	98.7%	Macrophage	28%
Alb	4.4 g/dl	<b>Urine</b>			
T-Bil	0.7 mg/dl	pH	6.0		
ALT	15 IU/l	Protein	(-)		
LDH	238 IU/l	Glucose	(-)		
γ-GTP	13 IU/l	Blood	(-)		
CPK	217 U/l				
BUN	14 mg/dl				
Cr	0.71 mg/dl				



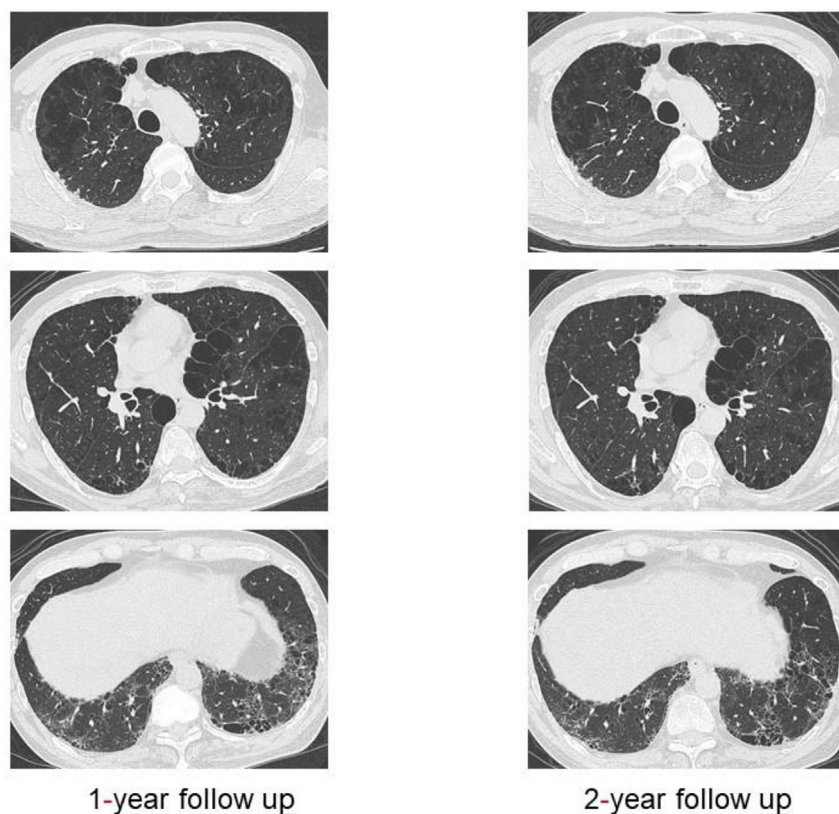


Fig. 3. No obvious change in chest CT after the 1- and 2-year follow-up examinations.

case, the patient did not develop any organ disorder other than pulmonary involvement, and MPO-ANCA status became negative upon smoking cessation; this status remained stable for at least 3 years. Thus, smoking might lead to production of MPO-ANCA and disease activity. However, it is unclear whether MPO-ANCA itself accelerated lung destruction without obvious findings of ANCA-associated ILD. This was a limitation, in that this case did not conclusively prove a correlation between cigarette smoking and ANCA elevation, or between ANCA and ILD progression without AAV. However, the current paper is a significant case report showing normalized MPO-ANCA status upon smoking cessation, which subsequently showed stable disease for an extended period. Thus, the findings of this case are valuable in this regard.

In summary, elevated ANCA levels are associated with various diseases and conditions, but are not significantly associated with cigarette smoking [6,7]. Given the previous data showing a correlation among CPFE, IPF, and ANCA, further studies are required to elucidate correlations among serum ANCA levels, interstitial pneumonia, and cigarette smoking.

#### Acknowledgements

Declarations of interest: none.

This research did not receive any specific grant from funding agencies in the public, commercial, or not-for-profit sectors.

#### Appendix A. Supplementary data

Supplementary data related to this article can be found at <https://doi.org/10.1016/j.rmcr.2018.08.022>.

#### References

- [1] G.A. Margaritopoulos, S. Harari, A. Caminati, K.M. Antoniou, Smoking-related idiopathic interstitial pneumonia: a review, *Respirology* 21 (2016) 57–64 <https://doi.org/10.1111/resp.12576>.
- [2] M.D. Jankowich, S.I. Rounds, Combined pulmonary fibrosis and emphysema syndrome: a review, *Chest* 141 (2012) 222–231 <https://doi.org/10.1378/chest.11-1062>.
- [3] J.S. McLaren, R.H. Stimson, E.R. McRorie, J.E. Coia, R.A. Luqmani, The diagnostic value of anti-neutrophil cytoplasmic antibody testing in a routine clinical setting, *QJM* 94 (2001) 615–621 <https://doi.org/10.1093/qjmed/94.11.615>.
- [4] T. Tanaka, K. Otani, R. Egashira, Y. Kashima, H. Taniguchi, Y. Kondoh, K. Kataoka, A. Shiraki, Y. Kitasato, K.O. Leslie, J. Fukuoka, Interstitial pneumonia associated with MPO-ANCA: clinicopathological features of nine patients, *Respir. Med.* 106 (2012) 1765–1770 <https://doi.org/10.1016/j.rm.2012.08.024>.
- [5] C. Hosoda, T. Baba, E. Hagiwara, H. Ito, N. Matsuo, H. Kitamura, T. Iwasawa, K. Okudela, T. Takemura, T. Ogura, Clinical features of usual interstitial pneumonia with anti-neutrophil cytoplasmic antibody in comparison with idiopathic pulmonary fibrosis, *Respirology* 21 (2016) 920–926 <https://doi.org/10.1111/resp.12763>.
- [6] X. Bosch, A. Guilbert, J. Font, Antineutrophil cytoplasmic antibodies, *Lancet* 368 (2006) 404–418 [https://doi.org/10.1016/s0140-6736\(06\)69114-9](https://doi.org/10.1016/s0140-6736(06)69114-9).
- [7] S. Beaudreuil, G. Lasfargues, L. Lauériere, Z. El Ghoul, F. Fourquet, C. Longuet, J.M. Halimi, H. Nivet, M. Büchler, Occupational exposure in ANCA-positive patients: a case-control study, *Kidney Int.* 67 (2005) 1961–1966 <https://doi.org/10.1111/j.1523-1755.2005.00295.x>.
- [8] N. Kagiya, N. Takayanagi, T. Kanauchi, T. Ishiguro, T. Yanagisawa, Y. Sugita, Antineutrophil cytoplasmic antibody-positive conversion and microscopic polyangiitis development in patients with idiopathic pulmonary fibrosis, *BMJ Open Respir. Res.* 2 (2015) e000058 <https://doi.org/10.1136/bmjresp-2014-000058>.
- [9] A. Tzouvelekis, G. Zacharis, A. Oikonomou, D. Mikroulis, G. Margaritopoulos, A. Koutsopoulos, A. Antoniadis, A. Koulelidis, P. Steiropoulos, P. Boglou, M. Bakali, Increased incidence of autoimmune markers in patients with combined pulmonary fibrosis and emphysema, *BMC Pulm. Med.* 13 (2013) 31 <https://doi.org/10.1186/1471-2466-13-31>.
- [10] W.D. Travis, U. Costabel, D.M. Hansell, T.E. King Jr., D.A. Lynch, A.G. Nicholson, C.J. Ryerson, J.H. Ryu, M. Selman, A.U. Wells, J. Behr, D. Bouros, K.K. Brown, T.V. Colby, H.R. Collard, C.R. Cordeiro, V. Cottin, B. Crestani, M. Drent, R.F. Dudden, J. Egan, K. Flaherty, C. Hogaboam, Y. Inoue, T. Johkoh, D.S. Kim, M. Kitaichi, J. Loyd, F.J. Martinez, J. Myers, S. Protzko, G. Raghu, L. Richeldi, N. Sverzellati, J. Swigris, D. Valeyre, ATS/ERS committee on idiopathic interstitial pneumonias. An official American thoracic society/European respiratory society statement: update of the international multidisciplinary classification of the idiopathic interstitial pneumonias, *Am. J. Respir. Crit. Care Med.* 188 (2013) 733–748 <https://doi.org/10.1164/rccm.201308-1483ST>.
- [11] A. Kumar, S.V. Cherian, R. Vassallo, S.Y. Eunhee, J.H. Ryu, Current concepts in pathogenesis, diagnosis, and management of smoking-related interstitial lung

- diseases, *Chest* 154 (2018) 394–408 <https://doi.org/10.1016/j.chest.2017.11.023>.
- [12] D.J. Davies, J.E. Moran, J.F. Niall, G.B. Ryan, Segmental necrotising glomerulonephritis with antineutrophil antibody: possible arbovirus aetiology? *Br. Med. J. (Clin. Res. Ed.)* 285 (1982) 606 <https://doi.org/10.1136/bmj.285.6342.606>.
- [13] G.M. Eschun, S.N. Mink, S. Sharma, Pulmonary interstitial fibrosis as a presenting manifestation in perinuclear antineutrophilic cytoplasmic antibody microscopic polyangiitis, *Chest* 123 (2003) 297–301 <https://doi.org/10.1378/chest.123.1.297>.
- [14] S. Homma, H. Matsushita, K. Nakata, Pulmonary fibrosis in myeloperoxidase anti-neutrophil cytoplasmic antibody-associated vasculitides, *Respirology* 9 (2004) 190–196 <https://doi.org/10.1111/j.1440-1843.2004.00581.x>.
- [15] P.B. Gaudin, F.B. Askin, R.J. Falk, J.C. Jennette, The pathologic spectrum of pulmonary lesions in patients with anti-neutrophil cytoplasmic autoantibodies specific for anti-proteinase 3 and anti-myeloperoxidase, *Am. J. Clin. Pathol.* 104 (1995) 7–16 <https://doi.org/10.1093/ajcp/104.1.7>.