




CASE REPORT

# Cutaneous Rosai-Dorfman Disease: A Treatment Challenge

Anna Gawdzik · Bogna Ziarkiewicz-Wróblewska · Iwona Chlebicka ·  
Alina Jankowska-Konsur · Jacek C. Szepietowski  · Joanna Maj

Received: March 1, 2021 / Accepted: May 24, 2021 / Published online: June 18, 2021  
© The Author(s) 2021

## ABSTRACT

Rosai-Dorfman disease (RDD) is a benign histiocytosis that rarely manifests as a purely cutaneous form. Its differential diagnosis and treatment can pose a challenge to both clinicians and pathomorphologists. We present the case of a 69-year-old woman with cutaneous RDD presenting as multiple nodules on the right thigh who was treated with low-dose methotrexate weekly for > 1 year with a partial response.

**Keywords:** Cutaneous Rosai-Dorfman disease; Histiocytosis; Methotrexate

## Key Summary Points

Rosai-Dorfman disease has to be taken into consideration in differential diagnosis of disseminated pink nodular skin lesions.

The treatment is not always effective, as there are no treatment guidelines.

In patients with disseminated lesions, prolonged treatment with methotrexate can lead to an improvement, but complete remission is difficult to obtain.

The effectiveness of the therapy may depend on the promptness of the diagnosis and fast initiation of the treatment.

## DIGITAL FEATURES

This article is published with digital features, including a summary slide, to facilitate understanding of the article. To view digital features for this article go to <https://doi.org/10.6084/m9.figshare.14627622>.

---

A. Gawdzik · I. Chlebicka · A. Jankowska-Konsur ·  
J. C. Szepietowski (✉) · J. Maj  
Department of Dermatology, Venereology and  
Allergology, Wrocław Medical University,  
Chalubinskiego 1 Str. 1, 50-368 Wrocław, Poland  
e-mail: jacek.szepietowski@umed.wroc.pl

B. Ziarkiewicz-Wróblewska  
Department of Pathology, Medical University of  
Warsaw, Zwirki i Wigury Str. 61, 02-091 Warsaw,  
Poland

## INTRODUCTION

Histiocytoses are a group of proliferative disorders of macrophage–monocyte origin. The current classification of histiocytoses consists of five groups (L, C, R, M, H), each presenting a different mutation in the mitogen-activated protein kinase pathway (MAPK) [1, 2]. Rosai-Dorfman disease (RDD) is an uncommon non-Langerhans histiocytosis of group R with a variable clinical presentation manifesting as a peripheral lymphadenopathy with or without other organ involvement. The purely cutaneous form is an extremely rare, distinct subtype of RDD that has been placed in group C due to significant differences from systemic RDD [3]. In terms of cutaneous manifestations, the first impression is often misleading, given the rare occurrence and non-distinctive clinical presentation [4]. Herein we present the case of a 69-year-old woman with disseminated nodules on the right thigh diagnosed with cutaneous RDD that partially responded to low-dose methotrexate.

## CASE REPORT

A 68-year-old Caucasian woman presented to the dermatology department with multiple erythematous nodules localized on the right thigh that had been slowly progressing for 9 months. The lesions were slightly tender on palpation, but no other general symptoms were reported. The patient's comorbidities included obesity, hypertension, hypercholesterolemia, superficial venous insufficiency and memory impairment of unknown duration. Laboratory tests revealed a slightly elevated erythrocyte sedimentation rate (ESR) and positivity for cytomegalovirus (CMV), Epstein-Barr virus (EBV) and *Borrelia burgdorferi* immunoglobulin G. An excision biopsy was performed. The epidermis was hypotrophic with an infiltration of lymphocytes B, T and plasma cells, but mostly histiocytes with immunohistochemistry markers, including protein S-100, CD163, CD68, and an absence of CD1a and HLA-DR. The image was indicative of Rosai-Dorfman disease (Fig. 1).

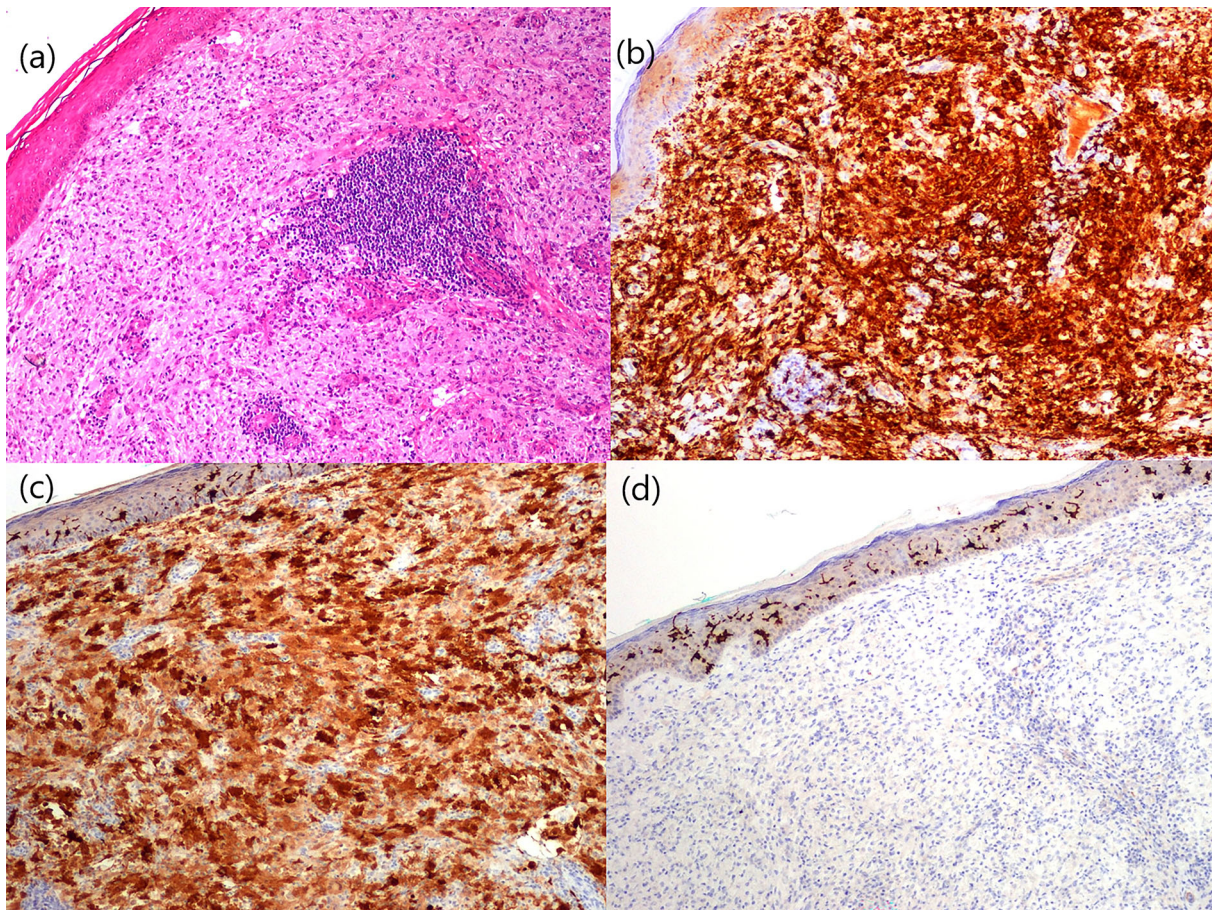
As no internal pathology was visible on the pan-computed tomography scan, on the lymph nodes and abdominal ultrasound and upon ophthalmological examination, we opted for the diagnosis of cutaneous form of Rosai-Dorfman disease.

The two most prominent nodules were surgically removed, and treatment with methotrexate (MTX) 10 mg subcutaneously (s.c.) per week with 10 mg of folic acid was started. On the first monthly follow-up we administered a total dose of 40 mg of methylprednisolone acetate suspension intralesionally. After 12 weeks, the MTX dose was increased to 15 mg s.c. once weekly, with the patient showing good tolerance; a visible flattening of the lesions was observed. After 11 months, 10 mg of prednisone once daily, taken by the oral route, was added to the treatment regimen. The lesions kept flattening and changed in color to violet-brown (Fig. 2). The patient was regularly monitored for possible side effects of the treatment.

This case report was written after receiving oral and written consent from the patient and is compliant the ethical guidelines of the University Hospital. Written consent was also obtained from the patient for the publication of the photographs.

## DISCUSSION

Rosai-Dorfman disease is a benign proliferative disorder of histiocytes with heterogeneous manifestations that include lymphadenopathy and, in 43% of cases, other organ involvement, such as skin. Skin lesions are present in 10% of systemic RDD cases and in 3% of cases without systemic involvement [4]. Systemic RDD has a predilection for the male sex and for younger persons, especially those of African descent [4], while the diagnosis of cutaneous RDD is typically specific to middle-aged females of Asian or Caucasian origin [4–6]. Cutaneous RDD is considered to be indolent with a possibility of a self-limiting course. However, there are cases of initially purely cutaneous disease that preceded multisystemic involvement [3].



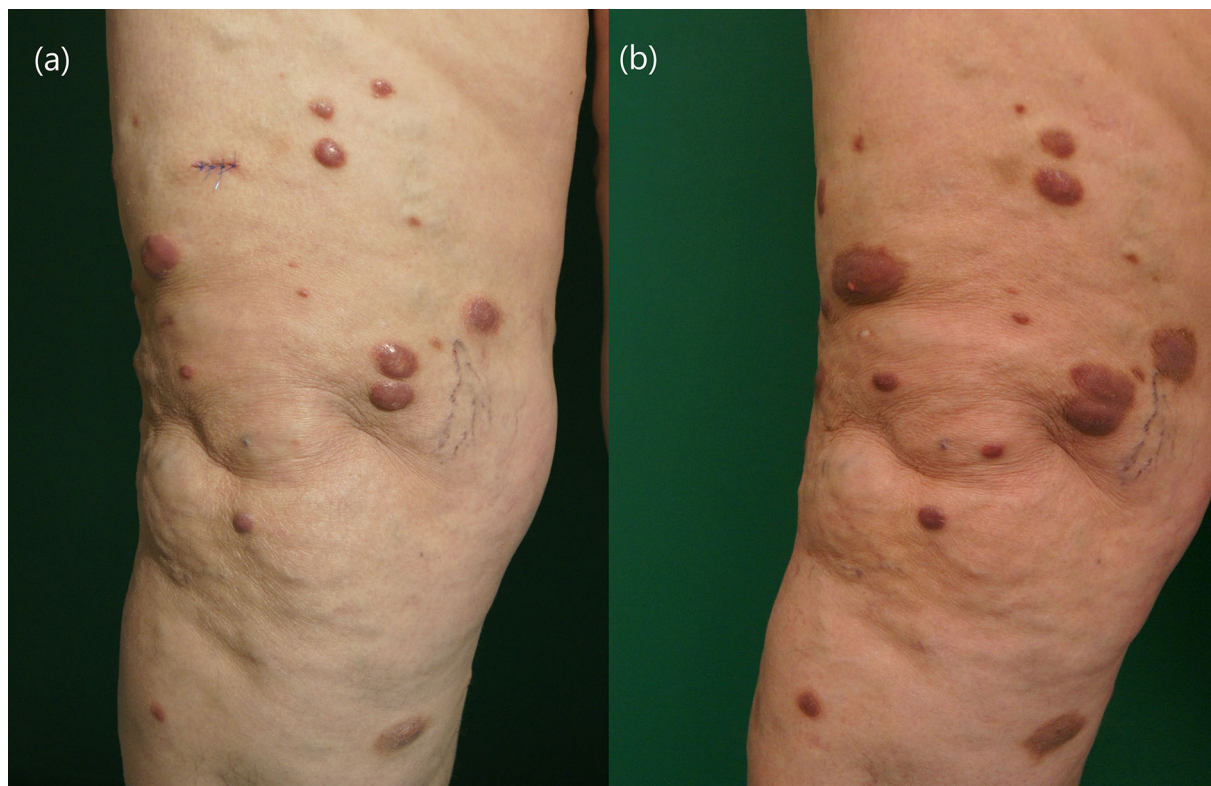
**Fig. 1** Histopathology and immunohistochemistry in cutaneous Rosai-Dorfman disease: **a** Under the epidermis are densely packed large histiocytic cells with pale cytoplasm; the aggregate of lymphocytes can be seen in the middle. Hematoxylin and eosin stain; magnification 100×.

**b** Positive immunohistochemical stain with CD163. Magnification 100×. **c** Positive immunohistochemical stain with S100. Magnification 100×. **d** Negative immunohistochemical stain with CD1a. Magnification 100×

In terms of its pathogenesis, RDD is considered to have an autoimmune origin due to its possible association with Crohn's disease, lupus erythematosus or rheumatoid arthritis [4, 5]. The disease can also coexist with lymphoproliferative diseases, including mycosis fungoides and non-Hodgkin or Hodgkin lymphoma [3, 7]. A connection with viral (EBV, parvovirus B19, human herpesvirus 6 [HHV6], human immunodeficiency virus [HIV]) or bacterial (*Borrelia* spp.) infection has not been confirmed [1, 3].

Advances in molecular research on histiocytoses have allowed the presence of several underlying recurrent mutations in tissue samples and blood to be established when there is a

systemic involvement. In RDD, the BRAFV600E mutation is generally absent (as it is characteristic to Langerhans cell histiocytosis and Erdheim-Chester syndrome); however, it can be expressed in an overlap [1, 3]. Other kinase mutations, such as KRAS, NRAS, ARAF and MAP2K1, have been reported in nodal and extranodal RDD; however, to the best of our knowledge, at the time of writing they have not been reported in purely cutaneous RDD [3, 8]. A recent study, published in May 2021, involving a small group of patients with cutaneous RDD confirmed the prevalence of the NRAS mutation in four out of seven cases (51.7%) [8]. Clonal mutations presenting in some cases of RDD suggest that the disease can be



**Fig. 2** Multiple violaceous nodules disseminated on the right thigh before the treatment (a) and after 55 weeks on 15 mg methotrexate subcutaneously once weekly with additional 10 mg of prednisone once daily for 12 weeks (b)

considered to be more neoplastic than primarily inflammatory [1, 3].

Skin lesions in RDD manifest as erythematous nodules or plaques with a yellowish or violaceous hue, isolated or confluent, predominantly located on the head and neck and rarely on the trunk or the limbs and possibly tender on palpation [4]. The presentation of cutaneous RDD can imitate eruptive xanthoma, acneiform eruptions, sarcoma Kaposi, cutaneous lymphoma, disseminated tuberculosis and Langerhans cell histiocytosis [5, 6, 9–11].

Ultrasound examination or magnetic resonance imaging has to be performed when the subcutaneous nodules or masses are palpable [12]. However, these examinations were not performed in our patient due to the superficial character of the lesions.

Diagnosis is based on the histological results, which include histiocytic infiltration with emperipolesis (i.e., intact cells such as

lymphocytes, plasma cells or erythrocytes visible in a histiocyte cytoplasm) and immunohistochemistry positive for S-100 protein, lysozyme,  $\alpha$ 1-antitrypsin, CD68 and CD163 with negative Langerhans cell markers (CD1a and langerin) [1–3, 6]. The histology may vary at every stage of evolution and is more conspicuous in newly developed lesions. The absence of emperipolesis in our case can be explained by the longer duration (9 months) of the disease at the time of the diagnostic biopsy. Compared to nodal RDD, extranodal RDD is characterized by more fibrosis, infrequent typical histiocytes and less emperipolesis [2, 6]. The authors of the 2018 consensus recommendations for the diagnosis and clinical management of RDD suggest that targeted next-generation sequencing for MAPK mutations should be performed in severe or refractory disease [13]. Although most of the mutations found in RDD are absent in cutaneous RDD, there are reports

of NRAS mutations that need to be further investigated—especially the possibility of progression to extracutaneous disease. We are aware that the lack of molecular profile in our case is a limitation; however histological and immunohistochemical examinations strongly supported the diagnosis.

Several successful therapies have been reported for cutaneous RDD; however, there is also a possibility of spontaneous resolution [3]. For localized disease, clinicians can attempt cryotherapy or surgery [14]. Topical and intralesional corticosteroids and topical imiquimod have been used to treat cutaneous RDD, with the effects varying from mild to total improvement [4, 6]. For the treatment of refractory or extensive disease, there is some evidence of thalidomide [6], dapsone [9], imatinib [5] and low-dose weekly MTX as monotherapy or combined with steroids being efficacious [15, 16]. A successful, total remission of cutaneous RDD after 11 months of treatment with 15 mg of MTX per week and triamcinolone injections prompted the introduction of this treatment [16]. In our patient, we achieved only partial remission, attributed to the late start of the treatment, which was initiated after about 11 months following onset of the lesions.

In conclusion, given the benign character of cutaneous RDD and the chance of spontaneous resolution, the differential diagnosis is a favorable one. There is a need for effective treatment to improve the patient's quality of life and reduce stigmatization as well as for regular follow-up due to rare, but possible development of extracutaneous manifestations. In the light of recent findings, it is reasonable to perform molecular tests and enable access to a rapid diagnosis and target treatment [13]; nevertheless, cutaneous RDD remains a diagnostic and therapeutic challenge.

## ACKNOWLEDGEMENTS

**Funding.** No funding or sponsorship was received for this study or publication of this article.

**Authorship.** All named authors meet the International Committee of Medical Journal Editors (ICMJE) criteria for authorship for this article, take responsibility for the integrity of the work as a whole, and have given their approval for this version to be published.

**Authorship Contributions.** Anna Gawdzik wrote the manuscript. Joanna Maj, Alina Janowska-Konsur and Jacek C. Szepietowski contributed to medical care and interpretation of the results. Iwona Chlebicka performed a surgical biopsy. Bogna Ziarkiewicz-Wróblewska was responsible for histological assessment. All authors commented and approved the final manuscript.

**Disclosures.** Anna Gawdzik, Bogna Ziarkiewicz-Wróblewska, Iwona Chlebicka, Alina Janowska-Konsur and Joanna Maj have nothing to disclose. Jacek C. Szepietowski is a member of the journal's Editorial Board.

**Compliance with Ethics Guidelines.** This case report was written after receiving oral and written consent from the patient and is compliant with the ethical guidelines of the University Hospital. Written consent was also obtained from the patient and for the publication of the patient's clinical pictures.

**Data Availability.** Data sharing is not applicable to this article as no datasets were generated or analyzed during the current study.

**Open Access.** This article is licensed under a Creative Commons Attribution-NonCommercial 4.0 International License, which permits any non-commercial use, sharing, adaptation, distribution and reproduction in any medium or format, as long as you give appropriate credit to the original author(s) and the source, provide a link to the Creative Commons licence, and indicate if changes were made. The images or other third party material in this article are included in the article's Creative Commons licence, unless indicated otherwise in a credit line to the material. If material is not included in the article's Creative Commons licence and your intended use is not permitted by statutory

regulation or exceeds the permitted use, you will need to obtain permission directly from the copyright holder. To view a copy of this licence, visit <http://creativecommons.org/licenses/by-nc/4.0/>.

## REFERENCES

- Haroche J, Cohen-Aubart F, Rollins BJ, et al. Histiocytoses: emerging neoplasia behind inflammation. *Lancet Oncol*. 2017;18(2):113–25.
- Emile JF, Ablu O, Fraïtag S, et al. Revised classification of histiocytoses and neoplasms of the macrophage-dendritic cell lineages. *Blood*. 2016;127:2672–81.
- Bruce-Brand C, Schneider JW, Schubert P. Rosai-Dorfman disease: an overview. *J Clin Pathol*. 2020;73(11):697–705.
- Gaul M, Chang T. Cutaneous Rosai-Dorfman disease. *Cutis*. 2019;103(3):171–3.
- Salva KA, Stenstrom M, Breadon JY, et al. Possible association of cutaneous Rosai-Dorfman disease and chronic Crohn disease a case series report. *JAMA Dermatol*. 2014;150(2):177–81.
- Gameiro A, Gouveia M, Cardoso JC, Tellechea O. Histological variability and the importance of clinicopathological correlation in cutaneous Rosai-Dorfman disease. *An Bras Dermatol*. 2016;91(5):634–7.
- Shelley AJ, Kanigsberg N. A unique combination of Rosai-Dorfman disease and mycosis fungoides: a case report. *SAGE Open Med Case Rep*. 2018;6:2050313X18772195.
- Wu KJ, Li SH, Liao JB, Chiou CC, Wu CS, Chen CC. NRAS mutations may be involved in the pathogenesis of cutaneous Rosai-Dorfman disease: a pilot study. *Biology*. 2021;10(5):396.
- Lee YI, Kim SK, Oh SH, Kim DY. Cutaneous Rosai-Dorfman disease of the face with a leonine appearance: successful response to dapsone. *Eur J Dermatol*. 2018;28(2):255–6.
- Zhang Y, Chen H. Image Gallery: generalized cutaneous Rosai-Dorfman disease presenting as acneiform lesions. *Br J Dermatol*. 2019;180(2):36.
- El-Kamel MF, Selim MK, Gawad MMA. A new presentation of isolated cutaneous Rosai-Dorfman disease: eruptive xanthoma-like lesions. *Indian J Dermatol Venereol Leprol*. 2020;86(2):158–61.
- Badlissi F, Pihan GA, Corominas H. Rosai-Dorfman disease: ultrasonography and histopathology study of a soft tissue mass in the forearm. *Reumatol Clin*. 2020;16(2 Pt 2):174–6.
- Ablu O, Jacobsen E, Picarsic J, Krenova Z, Jaffe R, Emile JF, et al. Consensus recommendations for the diagnosis and clinical management of Rosai-Dorfman–Destombes disease. *Blood*. 2018;131(26):2877–90.
- Fumerton R, Ball N, Zhou Y. Refractory cutaneous Rosai-Dorfman disease responsive to cryotherapy. *Cutis*. 2011;87(6):296–9.
- Subash JJ, Kesty C, Kesty KR, Asgari M, Jorizzo J. Low-dose weekly methotrexate used to treat cutaneous Rosai-Dorfman disease. *Clin Exp Dermatol*. 2018;43(7):849–51.
- Sun NZ, Galvin J, Cooper KD. Cutaneous Rosai-Dorfman disease successfully treated with low-dose methotrexate. *JAMA Dermatol*. 2014;150(7):787–8.