

Pressure-induced necrosis can mimic retiform purpura



Ellen Melrose, MD,^a Leah Laageide, BA,^b Krishna Mutgi, MD,^c Mary S. Stone, MD,^d and Karolyn A. Wanat, MD^d
Marshfield, Wisconsin, and Iowa City, Iowa

Key words: coma blisters; pressure-induced necrosis; retiform purpura.

INTRODUCTION

Retiform purpura most often represents pathology of medium vessels and is commonly an important sign of systemic disease. Identifying the underlying etiology is important to help prevent morbidity and mortality. We present a case in which pressure-induced necrosis (coma blister) occurred in a stellate pattern, mimicking more typical retiform purpura.

REPORT

An 80-year-old man presented with purpura of the left thigh after cardiac catheterization. The patient underwent a left femoral approach with placement of a drug-eluting stent for an ST segment elevation myocardial infarction. His medications during hospitalization included amiodarone, aspirin, clopidogrel, hydralazine, isosorbide dinitrate, and warfarin. Four days after catheterization, purpura developed over the left thigh. Physical examination found large ecchymosis on the left lateral thigh and angulated retiform purpura on the left medial thigh with background livedo reticularis (Fig 1). He also had a creatinine level increase from 1.7 to 2.2 over 24 hours. There was no peripheral eosinophilia or urine eosinophils.

A punch biopsy of the left thigh (Figs 2 and 3) found partial- to full-thickness epidermal necrosis with subepidermal vesiculation and a sparse superficial perivascular lymphocytic infiltrate with pauci-inflammatory necrosis of the eccrine coils (Fig 2). Multiple step sections were performed and found intact vessels without any inflammation or

emboli. The patient's renal function normalized within 24 hours, and his livedo reticularis slowly resolved. Supportive measures including pressure offloading and topical white petrolatum to areas of necrosis were used. The lesions rapidly resolved within 1 week with resultant postinflammatory hyperpigmentation.

DISCUSSION

Retiform purpura and livedo racemosa occur when there is vessel occlusion or inflammation with resultant extravasation of blood into the dermis, which is in contrast to livedo reticularis in which the netlike pattern of vessels is usually caused by slow flow states. Primary causes of retiform purpura may be divided into inflammatory and noninflammatory.¹ Polyarteritis nodosa, microscopic polyangiitis, and IgA vasculitis are important causes of inflammatory retiform purpura. Microvascular occlusion syndromes are associated with noninflammatory retiform purpura and include thrombotic, infectious, and embolic causes. Major etiologies include heparin necrosis, myeloproliferative disorders, thrombotic thrombocytopenic purpura, cryoglobulinemia, antiphospholipid antibody syndrome, warfarin necrosis, cholesterol emboli syndrome, and cutaneous calciphylaxis. Uncommon causes have been reported, including oxalate crystal deposition, marantic endocarditis, and medications.¹

Pressure-induced necrosis or coma blisters are induced changes from prolonged pressure occurring on an area. These may present as tense bullae or vesicles, violaceous plaques, or macular erythema.^{2,3}

From the Department of Dermatology, Marshfield Clinic/St. Joseph's Hospital^a; Carver College of Medicine, University of Iowa Hospitals and Clinics^b; the Department of Dermatology, University of Iowa Hospitals and Clinics^c; and the Department of Dermatology and Pathology; University of Iowa Hospitals and Clinics and VA Medical Center.^d

Funding sources: None.

Conflicts of interest: None declared.

Correspondence to: Karolyn A. Wanat, MD, The Department of Dermatology and Pathology; University of Iowa Hospitals and

Clinics and VA Medical Center, 200 Hawkins Drive, Iowa City, Iowa, 52242. E-mail: Karolyn-Wanat@uiowa.edu.

JAAD Case Reports 2018;4:365-7.

2352-5126

© 2017 by the American Academy of Dermatology, Inc. Published by Elsevier, Inc. This is an open access article under the CC BY-NC-ND license (<http://creativecommons.org/licenses/by-nc-nd/4.0/>).

<https://doi.org/10.1016/j.jidcr.2017.10.002>

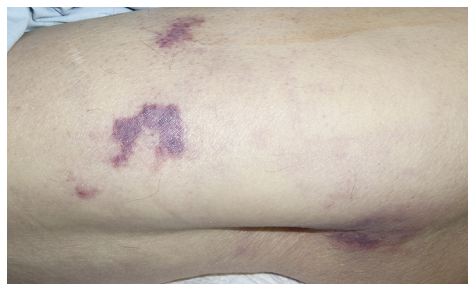

Fig 1. Retiform purpura of the left thigh with background livedo reticularis.

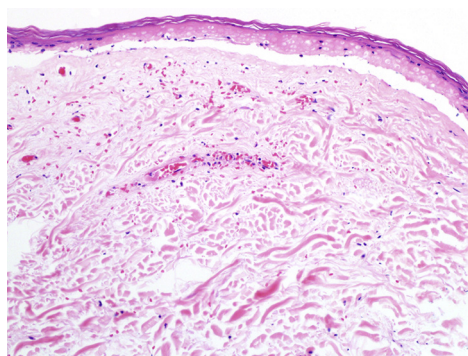


Fig 2. Punch biopsy specimen shows superficial necrosis with subepidermal separation. (Hematoxylin-eosin stain; original magnification: $\times 200$.)

Although tense bullae are the classic presentation, coma blisters may also present as erythematous-to-violaceous patches and plaques, vesicles, ecchymoses, or erosions.³⁻⁵ Barbiturate-induced coma is the most classic context associated with coma blisters, but other medications such as opiates, antipsychotics, and benzodiazepines as well as neurologic disorders, diabetic ketoacidosis, chronic renal failure, and hypercalcemia have been identified as associated factors.^{2,3,5-7} Prolonged immobilization, such as coma or postoperative states, is another setting in which these types of changes may occur.^{2,3}

Pressure-induced blisters most commonly occur over pressure-dependent sites but they also may occur over non-weight bearing areas.^{3,8} Although the exact pathophysiology is not known, it is hypothesized that tissue hypoxia from pressure-induced local ischemia or direct drug toxicity leads to tissue injury and necrosis.^{2,6} Slow flow states, such as those resulting in livedo reticularis, may amplify the intensity of the insult.² Lesions generally appear 24 to 72 hours after the initial injury but are self-limited and resolve in approximately 1 to 3 weeks without scarring.^{3,8} Removal of direct pressure over the area is necessary to prevent further skin damage.

The differential diagnosis of retiform purpura in a patient with recent cardiac catheterization includes

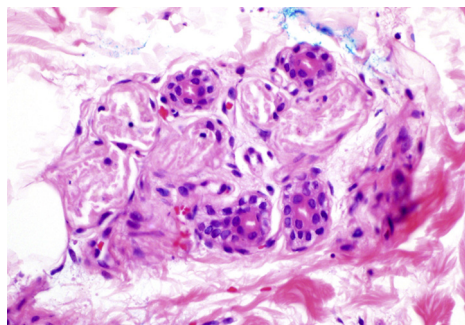


Fig 3. Pauci-inflammatory necrosis of eccrine coils. (Hematoxylin-eosin stain; original magnification: $\times 400$.)

cholesterol emboli secondary to the recent procedure and potential dislodging of cholesterol to the skin and warfarin necrosis, as this medication was recently started. Vasculitis also can present as retiform purpura and be related to new medications. Histopathology was essential in this case to make the diagnosis, and the epidermal necrosis with secondary bullae formation and eccrine necrosis as a specific pathologic finding suggested pressure necrosis (or coma blister) as the cause of the retiform purpura. In this case, the multiple purpuric lesions most likely resulted from use of an anticoagulant and antiplatelet around his procedure with bleeding into the sites of pressure. The lack of peripheral eosinophilia or cholesterol clefts on histopathology would not support cholesterol emboli syndrome, and there was an absence of vasculitis or vasculopathy on histopathology.

Pressure-induced necrosis (coma blisters) should be included on the differential diagnosis of retiform purpura. We hypothesize that the patient's left decubitus positioning during catheterization and low-flow state, as evidenced by his livedo reticularis, resulted in local hypoxia. Cessation of the procedure generated a reperfusion injury, oxidative stress, and subsequent pressure-induced necrosis. The use of multiple blood thinners including recent-onset clopidogrel and warfarin resulted in bleeding into the damaged skin, mimicking retiform purpura.

REFERENCES

1. Wysong A, Venkatesan P. An approach to the patient with retiform purpura. *Dermatol Ther*. 2011;24:151-172.
2. Arndt KA, Mihm MC, Parrish JA. Bullae: a cutaneous sign of a variety of neurologic diseases. *J Invest Dermatol*. 1973;66:312-320.
3. Chacon AH, Farooq U, Choudhary S, et al. Coma blisters in two postoperative patients. *Am J Dermatopathol*. 2013;35:381-384.
4. Kakurai M, Umemoto N, Yokokura H, et al. Unusual clinical features of coma blister mimicking contact dermatitis in

- rhabdomyolysis: report of a case. *J Eur Acad Dermatol Venereol*. 2006;20:761-763.
5. Piede J, Wallace E. Coma bullae: associations beyond medications. *Mayo Clin Proc*. 2011;86:e5.
 6. Rocha J, Pereira T, Ventura F, et al. Coma blisters. *Case Rep Dermatol*. 2009;1:66-70.
 7. Branco MM, De Capitani EM, Cintra ML, et al. Coma blisters after poisoning caused by central nervous system depressants: case report including histopathological findings. *An Bras Dermatol*. 2012;87(4):615-617.
 8. Waring WS, Sandilands EA. Coma blisters. *Clin Toxicol*. 2007;45:808-809.