

Teaching Point (Section Editor: F.P. Schena)

A transplant patient with a swollen leg

Vijay Thanaraj, Alex Woywodt and John Anderton

Department of Renal Medicine, Lancashire Teaching Hospitals NHS Foundation Trust, Royal Preston Hospital, Preston, Lancashire, UK

Correspondence and offprint requests to: John Anderton; E-mail: John.Anderton@lthtr.nhs.uk

Keywords: lymphoedema; renal transplant; sirolimus

Introduction

Some degree of peripheral oedema is not uncommon following renal transplantation. Bilateral peripheral oedema is seen in the context of congestive heart failure, delayed graft function with extracellular volume expansion or nephrotic syndrome due to glomerular disease. Mild unilateral peripheral oedema is also often seen, typically early after surgery and on the transplanted side. In these cases, it is usually assumed that some form of damage to the lymphatic ducts has occurred during transplant surgery. The swelling is usually mild and often settles over time. However, severe peripheral oedema on the contralateral side is uncommon, especially if deep venous thrombosis has already been excluded. We report such a case, which led to an unusual diagnosis. We also provide a brief review of the relevant literature and discuss recent insight into possible mechanisms and pathways.

Case

A 52-year-old woman with adult polycystic kidney disease received a first deceased renal transplant into the right iliac fossa in December 2008. Her medical history included bilateral native nephrectomy of her large polycystic kidneys as well as excision of a malignant melanoma *in situ* from the anterior chest in 2006. She had remained free of recurrence since then and remained under regular surveillance with a dermatologist. Following transplantation in 2008, her initial immunosuppression had been with tacrolimus, mycophenolate mofetil and prednisolone. There was a period of delayed graft function and renal biopsy showed acute tubular necrosis. Eventually, she was converted to sirolimus. Transplant function improved greatly, and serum creatinine when discharged was 150 $\mu\text{mol/L}$.

In March 2010, the patient presented to the outpatient clinic with a very swollen left leg. On examination, the patient was essentially well and afebrile. There were no signs of infection and no palpable lymph nodes in either groin. There were no clinical signs of deep venous

thrombosis or of phlebitis. The remainder of the clinical examination was essentially unremarkable. There was no history of surgery, trauma or infection in the left leg, nor had she ever had a femoral dialysis access. The general practitioner had started compression bandages but the affected leg remained grossly oedematous (Figure 1). Doppler studies revealed no deep vein thrombosis and left leg venogram confirmed patent veins up to the inferior vena cava. Diuretics were administered, but without any clinical benefit. The patient was seen at the regional referral centre for lymphoedema and a complex regime of bandaging and lymphatic drainage exercises was begun. Computed tomogram of the chest, abdomen and pelvis showed minor lymphadenopathy in the left groin. Around spring, 2010, the cause of her leg swelling was still essentially unclear. Cytomegalovirus and the Epstein–Barr virus polymerase chain reaction were negative, and serum lactate dehydrogenase was normal. Given her previous history of melanoma, we proceeded to a left inguinal lymph node biopsy, which showed no significant abnormality and no tumour cells. Eventually, the possibility of sirolimus-associated lymphoedema was considered. Sirolimus levels throughout this period of follow-up were within the target range (6.3–10.5 $\mu\text{g/L}$). Lymphoscintigraphy demonstrated the complete absence of tracer drainage from the left lower limb (Figure 2). A tentative diagnosis of unilateral lymphoedema due to a mammalian target of rapamycin (mTOR) inhibitor was made and sirolimus was withdrawn. Within 2 weeks, the swelling improved dramatically. When last seen in May 2012, she was very well with no discernible leg swelling (Figure 3) and good transplant function (creatinine 156 $\mu\text{mol/L}$).

Discussion

Sirolimus is an inhibitor of the mTOR with immunosuppressant and anti-proliferative properties [1]. A macrolide, sirolimus was first discovered in a soil sample from Easter Island—an island also known as Rapa Nui, hence the name rapamycin. Inhibitors of the mTOR, such as sirolimus and everolimus, have a unique role in immunosuppression after solid-organ transplantation. This is mainly due to

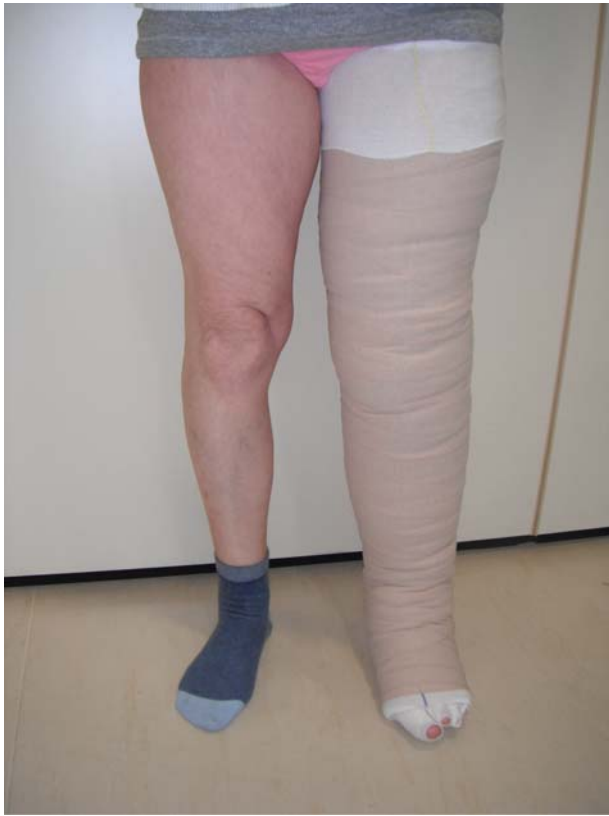

Fig. 1. Swollen left leg when the patient first presented.

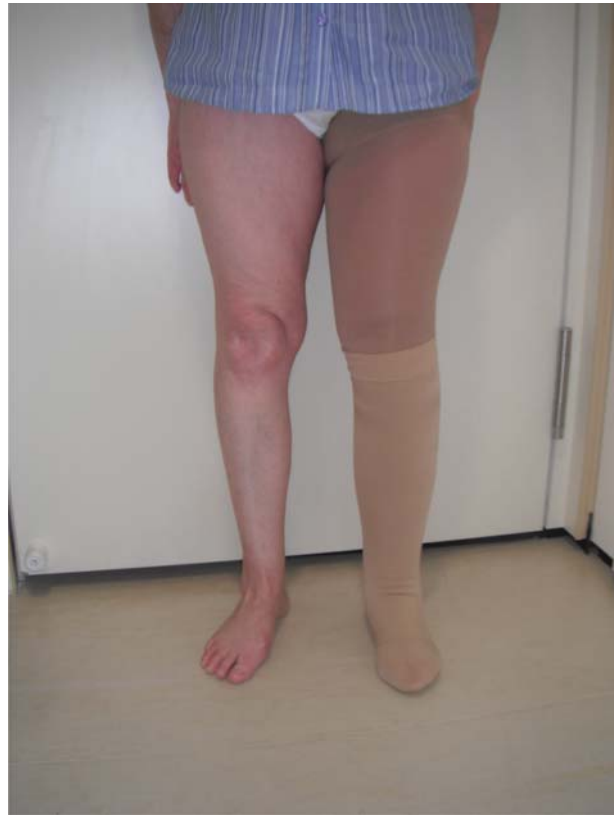

Fig. 3. Resolution of left swelling following withdrawal of sirolimus.

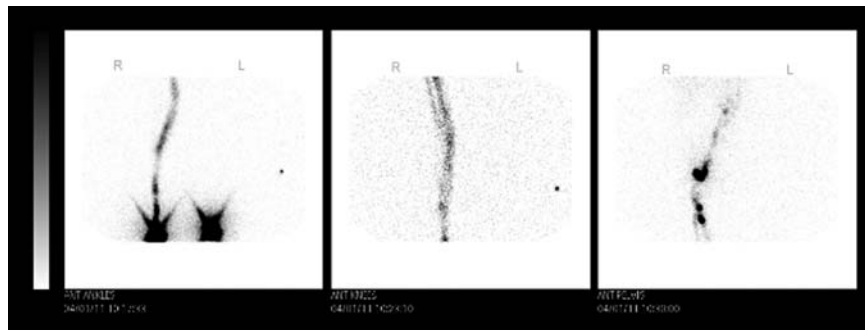


Fig. 2. Lymphoscintigraphy of the patient. Note the almost complete absence of lymphatic transport in the left leg.

their anti-proliferative properties [2] and also because they lack the tubular and vascular toxicity associated with calcineurin inhibitors. The use of mTOR inhibitors for routine maintenance immunosuppression, however, remains controversial and some recent studies did not demonstrate a survival benefit for mTOR-based regimes when compared with those relying on calcineurin inhibitors.

More recently, two more mTOR inhibitors have become available clinically, everolimus and temsirolimus. mTOR inhibitors are currently also being evaluated for treating, among others, lymphangiomyomatosis, polycystic kidney disease, renal cell carcinoma and tuberous sclerosis [3]. More and more mTOR inhibitors are emerging and the term 'rapalogues' has now been coined [3]. Some of these new drugs are more specific than traditional mTOR inhibitors, in that they target the active

site of mTOR systems to exert more prominent effects on mTOR functional outputs than rapamycin itself [4].

Our understanding of mTOR pathways has also improved substantially in recent years. These mechanisms are obviously beyond the scope of our little teaching point and are reviewed in great details elsewhere [4]. Briefly, mTOR itself is a system of serine/threonine kinases. We now know that mTOR is present in two distinct protein complexes commonly referred to as mTOR complex 1 (mTORC1) and mTOR complex 2 (mTORC2). mTORC1 features a companion protein with the interesting name of Raptor (regulatory-associated protein of mTOR). The corresponding protein in mTORC2 has been dubbed Rictor (rapamycin-insensitive companion of mTOR). mTORC1 and mTORC2 phosphorylate different substrates to regulate distinct cellular functions. For

instance, mTORC2 phosphorylates proteins associated with cell survival and cytoskeletal organization, whereas mTORC1 stimulates cell growth and proliferation [4].

The spectrum of side effects reported with mTOR inhibitors is as unique as their mode of action [1, 5] and there is a reason to believe that most of these effects are associated with the entire drug class and not with individual substances. Most nephrologists will be familiar with aphthous ulcers, diarrhoea, hyperlipidaemia and bone marrow suppression as common side effects of these drugs and perhaps recall the fact that these drugs impair wound healing. However, the spectrum of side effects is much wider (Table 1).

Cases of lymphoedema attributed to mTOR inhibitors have been reported time and again in the transplant [6–9] and dermatology [10] literature. Desai *et al.* reported a series of eight cases from a single institution and reviewed eleven cases described elsewhere in the literature [10]. We report a case of unilateral lower limb lymphoedema associated with sirolimus. The fact that the oedema occurred unilaterally and not on the transplanted side is remarkable, but similar cases have been reported before [10]. Comprehensive evaluation, including imaging and lymph node biopsy, did not reveal any other cause of the swelling. Lymphoscintigraphy confirmed the complete absence of tracer drainage from the left lower limb. Others have reported very similar imaging findings in lymphoedema associated with mTOR inhibitors [10]. The fact that the oedema resolved to a large degree after discontinuation of the drug gives us further confidence in the interpretation. Lymphoedema associated with mTOR inhibitors can affect the lower limbs only but may also involve atypical locations, such as the eyelid [11]. Pericardial and pleural effusion and ascites are also seen.

Lymph drainage involves several steps: first, interstitial fluid is absorbed into initial lymphatics and then transported to the main collecting lymphatics. Transport is via contraction of smooth muscle cells in the vessel wall and also due to contraction of the adjacent skeletal muscle and arterial pulsation. Lymphatic vessels also feature valves, which prevent backflow of lymphatic fluid. Lymphatic survival, proliferation and migration are mediated by the vascular endothelial growth factor (VEGF) system [12]. Mutations in VEGF receptor 3 cause lymphoedema [13]. Recent studies have demonstrated that mTOR is a downstream signal in the VEGF C/D pathway and that mTOR inhibitors such as sirolimus are capable of inhibiting lymphangiogenesis *in vitro* [14, 15]. Those findings

provide a possible mechanism for lymphoedema associated with mTOR inhibitors. The fact that these drugs are also associated with increased incidence of lymphocele underscores their unique propensity to affect the lymphatic system. However, it remains unclear as to why some patients develop this complication whereas many others, who are similarly exposed to these drugs, do not [10]. Predisposing factors such as previous trauma, surgery or inflammation have been invoked but our patient had none of these. In particular, the lymphoedema occurred on the non-transplanted side. The time frame seen in our case is in keeping with that reported in the literature whereby lymphoedema occurred between 11 weeks to 36 months from the commencement of sirolimus. Most of the patients responded to either conversion of sirolimus to alternative immunosuppressive regime or to dose reduction in sirolimus along with supportive management.

Conclusion

Lymphoedema is a recognized adverse effect of mTOR inhibitors, which is surprisingly well described in the dermatology [2] and transplant [1] literature. In hindsight, we feel that the diagnosis could have been made earlier, which would have avoided unnecessary investigations and delay. We take some consolation from the fact that a number of highly experienced colleagues, including the regional lymphoedema referral centre, were equally unaware of this rare cause of lymphoedema. Our encounter with a mysteriously swollen leg eventually provided an interesting detour into the mechanisms of mTOR inhibition and into rare side effects of mTOR inhibitors. We also took the opportunity to revise our knowledge of the somewhat neglected lymphatic system.

Teaching points

- (i) Inhibitors of the mTOR have a unique mode of action in preventing rejection in recipients of solid-organ transplants. Their use is also under investigation for a variety of other disorders.
- (ii) mTOR inhibitors also feature a unique profile of side effects.
- (iii) Lymphoedema is a well-described side effect of mTOR inhibitors that is reversible on discontinuation of these drugs.
- (iv) Awareness and early recognition of this side effect may avoid unnecessary investigations.

Acknowledgements. We are indebted to the regional lymphoedema service for clinical advice. We are also grateful to the patient for allowing us to publish her case.

Conflict of interest statement. None declared.

References

1. Paghdal KV, Schwartz RA Sirolimus (rapamycin): from the soil of Easter Island to a bright future. *J Am Acad Dermatol* 2007; 57: 1046–1050
2. Leblanc KG Jr, Hughes MP, Sheehan DJ The role of sirolimus in the prevention of cutaneous squamous cell carcinoma in organ transplant recipients. *Dermatol Surg* 2011; 37: 744–749

Table 1. Side effects of mTOR inhibitors [1, 5]

Angioedema (usually when administered with ACE-inhibitors)
Arthralgia
Bone marrow depression
Diarrhoea and other gastrointestinal symptoms
Hyperlipidaemia
Oral ulcers (typically dose-related)
Hypokalaemia
Hypophosphataemia
Lymphocele
Interstitial pneumonitis (resembling bronchiolitis obliterans-organizing pneumonia with lymphocytic alveolitis on bronchio-alveolar lavage)
Oedema (peripheral oedema incl. anasarca, pericardial and pleural effusion, ascites, unusual locations such as eyelid)
Proteinuria (usually focal and segmental glomerulosclerosis)
Skin disorders (acneiform, folliculitis, hidradenitis suppurativa)
Thrombotic microangiopathy (usually when administered in combination with cyclosporine)
Disturbed wound healing

3. Benjamin D, Colombi M, Moroni C et al. Rapamycin passes the torch: a new generation of mTOR inhibitors. *Nat Rev Drug Discov* 2011; 10: 868–880
4. Dowling RJ, Topisirovic I, Fonseca BD et al. Dissecting the role of mTOR: lessons from mTOR inhibitors. *Biochim Biophys Acta* 2010; 1804: 433–439
5. Watson CJE Sirolimus (rapamycin) in clinical transplantation. *Transplant Rev* 2001; 15: 165–177
6. De Bartolomeis C, Collini A, Rumberger B et al. Generalized lymphedema in a sirolimus-treated renal transplant patient. *Clin Transplant* 2008; 22: 254–257
7. Al-Otaibi T, Ahamed N, Nampoory MR et al. Lymphedema: an unusual complication of sirolimus therapy. *Transplant Proc* 2007; 39: 1207–1210
8. Aboujaoude W, Milgrom ML, Govani MV Lymphedema associated with sirolimus in renal transplant recipients. *Transplantation* 2004; 77: 1094–1096
9. Romagnoli J, Citterio F, Nanni G et al. Severe limb lymphedema in sirolimus-treated patients. *Transplant Proc* 2005; 37: 834–836
10. Desai N, Heenan S, Mortimer PS Sirolimus-associated lymphoedema: eight new cases and a proposed mechanism. *Br J Dermatol* 2009; 160: 1322–1326
11. Mohaupt MG, Vogt B, Frey FJ Sirolimus-associated eyelid edema in kidney transplant recipients. *Transplantation* 2001; 72: 162–164
12. Kreuger J, Nilsson I, Kerjaschki D et al. Early lymph vessel development from embryonic stem cells. *Arterioscler Thromb Vasc Biol* 2006; 26: 1073–1078
13. Karkkainen MJ, Ferrell RE, Lawrence EC et al. Missense mutations interfere with VEGFR-3 signalling in primary lymphoedema. *Nat Genet* 2000; 25: 153–159
14. Huber S, Bruns CJ, Schmid G et al. Inhibition of the mammalian target of rapamycin impedes lymphangiogenesis. *Kidney Int* 2007; 71: 771–777
15. Kobayashi S, Kishimoto T, Kamata S et al. Rapamycin, a specific inhibitor of the mammalian target of rapamycin, suppresses lymphangiogenesis and lymphatic metastasis. *Cancer Sci* 2007; 98: 726–733

Received for publication: 17.7.12; Accepted in revised form: 18.7.12