

Cutaneous malignant melanoma with rarest combination of prostatic and splenic metastases on fluorodeoxyglucose (FDG) positron emission tomography-computed tomography scan

ABSTRACT

Cutaneous malignant melanoma (MM) metastases to prostate and spleen are very rarely experienced in clinical setting. As per our knowledge, coexistence of prostate and splenic metastatic MM is not reported worldwide. We are presenting a case of 70-year-old male patients with biopsy and clinically proven case of multifocal cutaneous malignant melanomatous lesions having multiple metastatic lymph nodes and systemic metastases, including prostate and spleen. This is the first case reported worldwide having a combination of prostate and splenic metastases.

Keywords: Fluorodeoxyglucose (FDG), malignant melanoma, positron emission tomography-computed tomography, prostatic-splenic metastasis

INTRODUCTION

Secondary malignancy in prostate and spleen are usually seen as metastasis or direct tumoral extension. Metastasis of malignant melanoma (MM) to prostate or spleen rarely causes symptoms of lower urinary tract (LUT) or abdomen. Although the rate of prostate or splenic metastasis of MM is very low in clinical setting but higher during autopsy, with few cases reported for splenic metastasis and only six cases reported for prostate metastasis of MM in the past few years in world literature but very rare in Indian and Asian literature. We report a case of simultaneously detected MM metastases into the prostate and spleen, and to the best of our knowledge, this is the first reported case of such metastatic MM.

CASE REPORT

A 70-year-old male patient had complaints of blackish pigmented lesions over left heel and increasing in size since few months and became ulcerated followed by the development of large nodular masses over left thigh and left proximal leg progressing in size and becoming black in color. Biopsy from thigh lesion was diagnosed as MM and patient was referred for FDG PET-CT scan for staging purpose. The patient was taken

for PET-CT scan on SIEMENS Biograph TruePoint 16-slice CT scanner after 60 min of 370 MBq 18F-FDG intravenous injection.

Scan revealed FDG avid two small sized ulcerative cutaneous lesions in left heel with cutaneous-Subcutaneous large conglomerated mass in anteromedial aspect of left upper mid-thigh and medial aspect of proximal left leg and low grade FDG avid few left inguinal and bilateral external iliac lymph nodes [Figures 1 and 2]. Few non-FDG avid centimetric-sized subcutaneous nodules were also in right upper thigh and left mid-thigh. High-grade FDG avid lesion was seen in prostate and two lesions in spleen [Figure 3].

DIGISH SHAH, PRAKASH ODEDARA

Department of Nuclear Medicine and PET-CT, HCG Cancer Hospital, Department of Radiology, HCG Cancer Centre, Ahmedabad, Gujarat, India


Address for correspondence: Dr. Digish Shah, Department of Nuclear Medicine and PET-CT, HCG Cancer Hospital, Sola Science City Road, Ahmedabad - 380 060, Gujarat, India. E-mail: digish86pet@gmail.com

Submission: 25-Jun-19, **Accepted:** 22-Jul-19, **Published:** 17-Jan-20

This is an open access journal, and articles are distributed under the terms of the Creative Commons Attribution-NonCommercial-ShareAlike 4.0 License, which allows others to remix, tweak, and build upon the work non-commercially, as long as appropriate credit is given and the new creations are licensed under the identical terms.

For reprints contact: WKHLRPMedknow_reprints@wolterskluwer.com

How to cite this article: Shah D, Odedara P. Cutaneous malignant melanoma with rarest combination of prostatic and splenic metastases on fluorodeoxyglucose (FDG) positron emission tomography-computed tomography scan. World J Nucl Med 2020;19:273-6.

Access this article online	
Website: www.wjnm.org	Quick Response Code 
DOI: 10.4103/wjnm.WJNM_49_19	

DISCUSSION

Among all skin cancer, MM is the most dangerous. Even though it accounts for only 5% of skin cancer worldwide but is responsible for >75% of mortality related to skin cancer.^[1] The highest incidence is seen in Australia. Lower incidence rate of <0.5/100,000 patients

years is seen in India, may be due to under-reporting or delayed diagnosis. Higher incidence and mortality rates are seen in older age group than younger group. The most common location is lower limb in female and over back in male. Important risk factors are sun exposure, white races, albinism, positive family history of skin cancer, socioeconomic factors, and other benign nevus. Even though it is a deadly disease, early diagnosis, and complete surgical removal give a better prognosis.

Initially, melanoma cells proliferate within epidermis and adjacent adnexal structure and once its horizontal growth is restricted along epidermis, it invades dermis and deeper layers where it gains potentiality of distant metastasis by access to lymphatics and blood vessels. There are three types of metastases – local extension (satellite or in-transit), regional extension to the regional node, and distant metastasis to visceral or nonvisceral organs. Most frequent site of metastases is regional and nonregional lymph nodes, lung, liver, brain, bone, and gastrointestinal tract (GIT), especially small intestine. About 20% of patients have visceral metastasis as the first site of spread.^[2]

Tumor depth, ulceration, and distant metastasis are important prognostic factors. Presentation with distant metastasis at initial diagnosis is very uncommon, and presentation as lymph node or distant site without primary cutaneous melanoma is even more uncommon.

FDG PET-CT scan is indicated for staging, restaging, treatment response evaluation, and follow-up of MM due to its proven high sensitivity (83%–100% in metastases), specificity and accuracy for the detection of nodal or visceral metastases

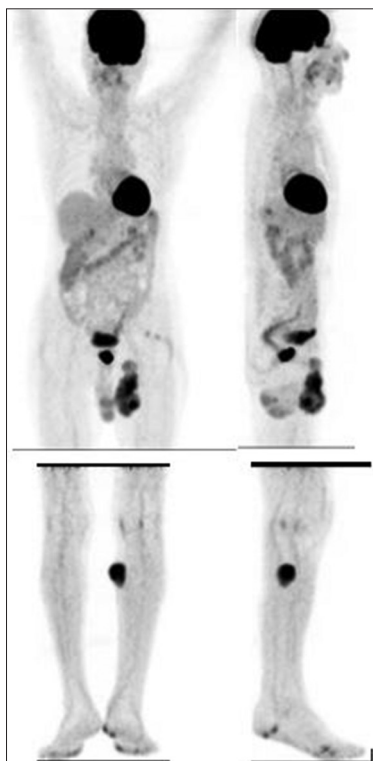


Figure 1: Maximum Intensity Projection (MIP) images of fludeoxyguose positron emission tomography scan shows multiple cutaneous lesions of malignant melanoma in the left lower limb with pelvic lymph nodes, prostatic and splenic fludeoxyguose avid lesions

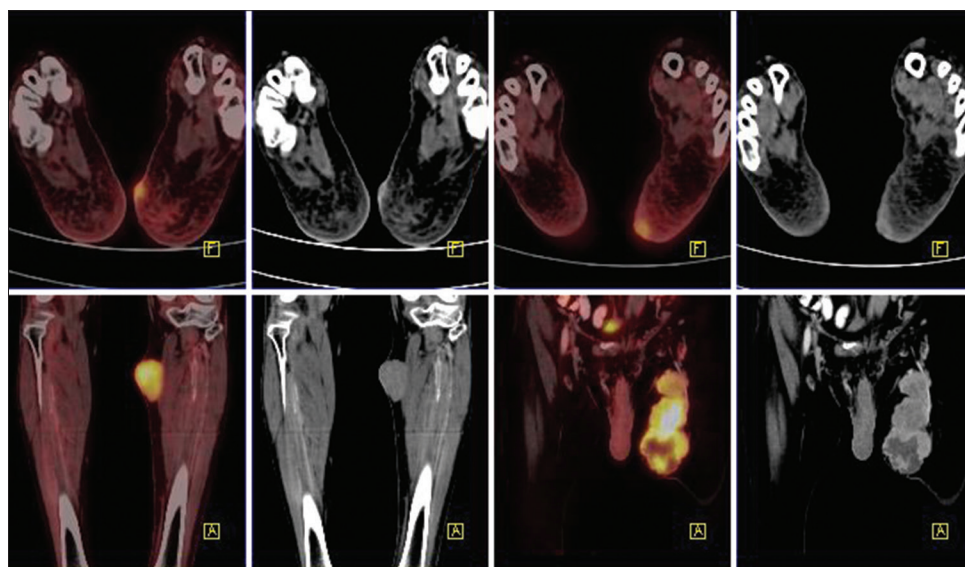


Figure 2: Positron emission tomography-computed tomography images: Axial (upper row) and coronal (lower row) images, few cutaneous lesions in left foot, subcutaneous mass lesion in left upper leg, and conglomerated mass lesions in left thigh

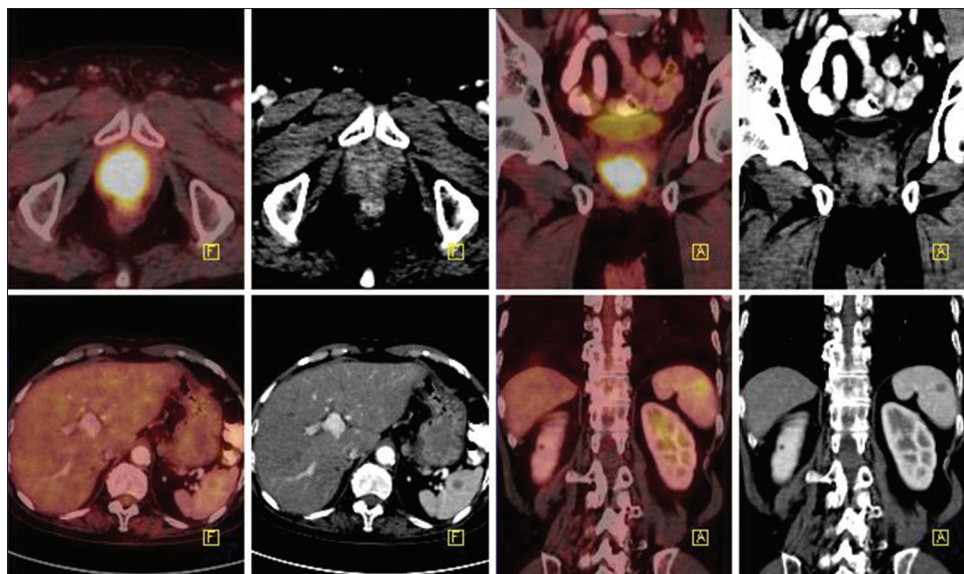


Figure 3: A means coronal view (anterior to posterior), F means axial view (feet to head) positron emission tomography-computed tomography fused and contrast-enhanced computed tomography images: upper axial (left) and coronal (right) images show fludeoxyguucose avid enhancing lesion in prostate gland. Lower axial (left) and coronal (right) images show fludeoxyguucose avid hypodense lesion in spleen

or recurrences which are otherwise inaccessible by clinical examination and/or undetectable morphological changes on conventional imaging.^[3]

Approximately 60% of patients with locoregional nodal metastasis will develop distant metastases. Timely detection can significantly impact therapeutic management and survival. FDG PET-CT is frequently used as staging tool in Stage III of melanoma to unmask asymptomatic or occult synchronous distant metastasis and change the management in 15%–64% cases in Stage III or IV.^[4] Furthermore, helpful as initial staging tool in AJCC Stage I or II in high-risk patients such as Breslow tumor thickness of >3 mm, ulceration, high mitotic rate, and location at trunk and upper limb. Our case was of clinical Stage III and had no symptoms of systemic disease, including those of LUT or abdominal disease.

The metastatic prostatic lesion is very rare and is seen in 2.1% of all prostate cancer. The most common primary sites of prostate metastases are lung and pancreas with few isolated cases from urinary bladder, rectum, skin (MM), breast, eye (MM), adrenal cortex, and gall bladder.^[5] It has been reported that advanced MM has prostate metastasis in about 3% of autopsies.^[6] Primary melanoma of prostate is extremely rare and only six cases have been reported^[6] either as prostatic urethral origin or as a metastatic lesion.^[7,8] In our case, we have ruled out possibility of primary prostatic malignancy due to (1) primary prostatic adenocarcinoma is generally low-grade FDG avid unlike this case, (2) normal prostate specific antigen (PSA) level and absence of LUT symptoms, (3) if

cutaneous lesion is present, it has to be considered as primary and rest as metastatic lesions. As in our case, the presence of cutaneous lesions and nonregional nodal metastases exclude the possibility of primary prostatic malignancy and thus obviate need for unnecessary intervention for histopathological confirmation. The use of multidisciplinary approach or imaging modality to search for possible primary reason is advisable.

Splenic metastatic melanoma is seen only in 4.1%–5% of cases but higher rate (36%) is seen in autopsies.^[9] Splenic metastasis is usually a part of disseminated disease and is asymptomatic and incidentally found.^[10] Isolated metastases are rare.^[11] Disseminated melanoma is considered as AJCC Stage IV disease with poor prognosis and average life span of 4–8 months.^[12]

CONCLUSION

Due to high sensitivity of whole-body FDG PET-CT scan, accurate staging is possible, and we could report rare finding of prostatic metastatic and rare finding of its combination with splenic metastasis in a case of cutaneous MM.

Declaration of patient consent

The authors certify that they have obtained all appropriate patient consent forms. In the form, the patient has given his consent for his images and other clinical information to be reported in the journal. The patient understands that name and initials will not be published and due efforts will be made to conceal identity, but anonymity cannot be guaranteed.

Financial support and sponsorship

Nil.

Conflicts of interest

There are no conflicts of interest.

REFERENCES

1. Anand S, Verma R, Vaja C, Bade R, Shah A, Gaikwad K. Metastatic malignant melanoma: A case study. *Int J Sci Stud* 2016;4:188-90.
2. Showalter SL, Hager E, Yeo CJ. Metastatic Disease to the Pancreas and Spleen. *Semin oncol* 2008;35:160-171.
3. Belhocine TZ, Scott AM, Even-Sapir E, Urbain JL, Essner R. Role of nuclear medicine in the management of cutaneous malignant melanoma. *J Nucl Med* 2006;47:957-67.
4. Krug B, Crott R, Lonneux M, Baurain JF, Pirson AS, Vander Borgh T. Role of PET in the initial staging of cutaneous malignant melanoma: Systematic review. *Radiology* 2008;249:836-44.
5. Bates AW, Baithun SI. Secondary solid neoplasms of the prostate: A clinico-pathological series of 51 cases. *Virchows Arch* 2002;440:392-6.
6. Tosev G, Kuru TH, Huber J, Freier G, Bergmann F, Hassel JC, *et al.* Primary melanoma of the prostate: Case report and review of the literature. *BMC Urol* 2015;15:68.
7. Clark WH Jr., Ainsworth AM, Bernardino EA, Yang CH, Mihm CM Jr., Reed RJ. The developmental biology of primary human malignant melanomas. *Semin Oncol* 1975;2:83-103.
8. Stein BS, Kendall AR. Malignant melanoma of the genitourinary tract. *J Urol* 1984;132:859-68.
9. Dasgupta T, Brasfield R. Metastatic melanoma. A clinicopathological study. *Cancer* 1964;17:1323-39.
10. Giovagnoni A, Giorgi C, Goteri G. Tumours of the spleen. *Cancer Imaging* 2005;5:73-7.
11. Lam KY, Tang V. Metastatic tumors to the spleen: A 25-year clinicopathologic study. *Arch Pathol Lab Med* 2000;124:526-30.
12. Trindade MM, Blaya R, Trindade EN. Melanoma metastasis to the spleen: Laparoscopic approach. *J Min Access Surg* 2009;5:17-9.