

Solitary Necrotic Nodules of the Liver Mimicking Hepatic Metastasis: Report of Two Cases

Kwon-Ha Yoon, MD¹
Ki Jung Yun, MD²
Jung-Min Lee, MD³
Chang Guhn Kim, MD¹

We present two cases of solitary necrotic nodules of the liver which on radiologic images mimicked hepatic metastasis. Solitary necrotic nodule of the liver is a rare but benign entity which histopathologically consists of an outer fibrotic capsule with inflammatory cells and a central core of amorphous necrotic material. The lesion was seen on contrast-enhanced CT as an ovoid-shaped hypoattenuating nodule; on CT during hepatic arteriography as enhancing nodule; on intraoperative US as a target-appearing hypoechoic nodule; on T2WI as a hyperintensity nodule, and on dynamic MR as a subtle peripheral enhancing nodule. Although the radiologic features are not specific, solitary necrotic nodule of the liver should be included in the differential diagnosis of hepatic metastasis.

Solitary necrotic nodule of the liver is an uncommon non-malignant lesion first described by Shepherd and Lee in 1983 (1) and comprising a central necrotic core enclosed by a hyalinized fibrotic capsule containing elastic fibers. Several pathogenic mechanisms including the possibility that the condition has a traumatic etiology, or is a consequence of previous parasite infection or sclerosing hemangiomas have been suggested (2, 3). Such lesions are frequently found in a subcapsular location, protruding slightly from the surface of the liver and with a sharply defined border, and may be mistaken for metastasis. In the published literature, the histopathologic features and pathogenesis of the solitary necrotic nodule have been discussed (1–4), but as far as we are aware no reports have emphasized the radiologic findings.

The purpose of this report is to describe the radiologic findings of two cases of solitary necrotic nodule of the liver mimicking hepatic metastasis.

Index words :
Liver, CT
Liver, diseases
Liver, infection

Korean J Radiol 2000;1:165-168

Received January 21, 2000; accepted after revision June 7, 2000.

Departments of ¹Radiology and ²Pathology, Wonkwang University School of Medicine; Department of ³Radiology, Chunbuk National University Medical School

Address reprint requests to :

Kwon-Ha Yoon, MD, Department of Radiology, Wonkwang University School of Medicine, 344-2 Sinyong-dong, Iksan, Chunbuk 570-711, Korea.
Telephone: (8263) 850-1510
Fax: (8263) 851-4749
e-mail: yoonkh@wmc.wonkwang.ac.kr

CASE REPORTS

Case 1

A 54-year-old woman was admitted for evaluation of a polypoid gallbladder mass measuring 2.0 cm in diameter and a hepatic low-echoic nodule discovered by US examination during a check-up. Serum CEA, CA 19–9, and alpha-fetoprotein levels were normal. Arterial- and portal-phase spiral CT revealed focal wall thickening with enhancement in the fundus of the gallbladder and a poorly-defined, ovoid hypoattenuating nodule with peripheral rim enhancement measuring 1.0 cm in diameter in the right lobe of the liver. These findings suggested gallbladder cancer with hepatic metastasis. For evaluation of metastasis prior to surgery, the patients underwent CT during arteriography (CTAP) and during hepatic arteriography (CTHA). An ovoid portal perfusion defect area was demonstrated by CTAP (Fig. 1A), and a highly enhancing

nodular lesion in the same area of the right lobe of the liver by CTHA (Fig. 1B). One week later, surgery was performed. Intraoperative US showed that the lesion was a target-appearing hypoechoic nodule measuring 1.0 cm in diameter. In addition, two other nodules each with a diameter of 0.5 cm, were present in the same segment of the liver (Fig. 1C). The patient underwent right hepatic lobectomy and cholecystectomy. Histopathologic examination indicated that the gallbladder lesion was an adenocarcinoma

with tubular, well-differentiated characteristics and had invaded the perimuscular connective tissue. The hepatic nodules were diagnosed as a solitary necrotic nodule composed of a central necrotic core and a peripheral fibrotic capsule with inflammatory cells (Fig. 1D).

Case 2

A 72-year-old man was admitted for vomiting and poor oral intake, which had lasted for six days. Six years earlier,

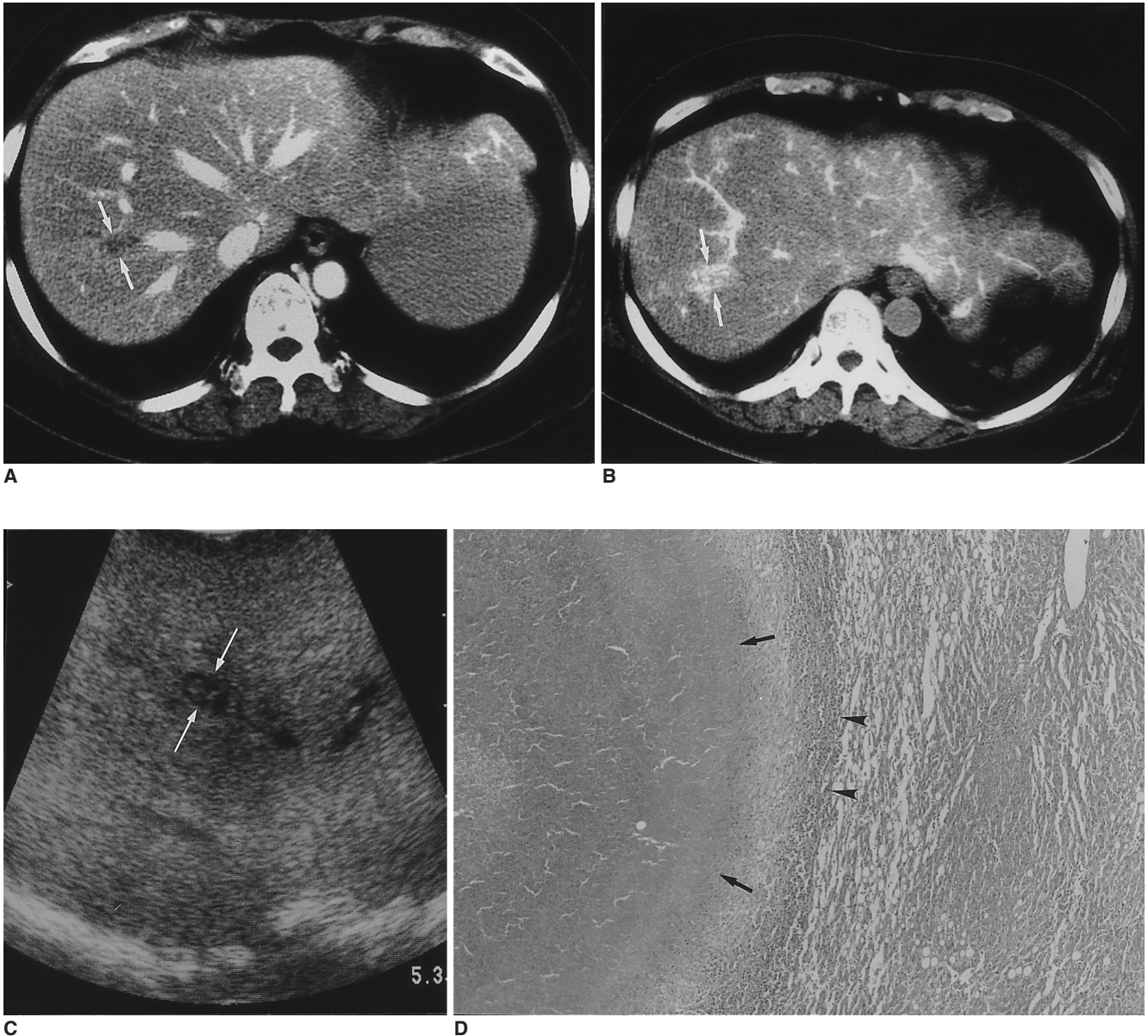


Fig. 1. A 54-year-old woman with gallbladder cancer and solitary necrotic nodule of the liver.
A. CTAP shows an ovoid-shaped area of portal perfusion defect (arrows), 1.0 cm in diameter, in the right hepatic lobe.
B. CTHA shows a highly enhancing nodular lesion (arrows) in the same area.
C. Intraoperative US shows an additional target-appearing hypoechoic nodule (arrows), 0.5 cm in diameter, in the same segment of the liver.
D. Photomicrograph shows central amorphous necrosis (arrows) surrounded by a fibrotic capsule, with infiltration by inflammatory cells (arrowheads) (hematoxylin-eosin stain, $\times 13$).

Hepatic Solitary Necrotic Nodules Mimicking Hepatic Metastasis

due to gastric cancer, he had undergone a subtotal gastrectomy with Billroth II anastomosis. On plain radiographs of the abdomen, diffuse dilatation of the proximal jejunal loop, with collapsed distal loop, suggesting jejunal obstruction, was seen. Abdominal CT showed a dilated proximal jejunal loop, with an abrupt transitional zone and bowel wall thickening. In addition, an elliptical, hypoattenuating nodule measuring 1.0 x 0.3 cm in diameter was observed in the lateral segment of the left lobe of the liver (Fig. 2A). T2-weighted MR imaging (T2WI) indicated that a nodule at the same site was hyperintense, and T1WI that it was isointense, while Gadolinium-enhanced study suggested the presence of a subtle, peripheral enhancing nodule (Fig. 2B). We regarded these imaging findings as indicative of small bowel obstruction due to tumor recurrence, with hepatic metastasis, and later, as adhesive ileus and nontumorous lesion of liver. The patient underwent surgery and this indicated that the proximal jejunum, about 10 cm from the Treitz ligament, had adhered to the operative wound. In addition, a hard, whitish mass 1.0 cm in diameter, was found in the liver. The patient underwent adhesiolysis of the jejunal loop and wedge resection of the liver lesion. On histopathologic examination, the liver mass was diagnosed as solitary necrotic nodule.

DISCUSSION

Solitary necrotic nodule of the liver is an uncommon lesion on the basis of US or CT examination, which has often been diagnosed as necrotic metastasis (1–4). A solitary necrotic nodule, despite its name, may be multiple (5), and in a large number of cases, may represent the end-stage of a

variety of benign lesions such as larval infestation, sclerosed hemangioma or trauma (2–4). Histologically, the lesion consists of an outer fibrotic capsule with inflammatory cells and a central core of amorphous necrotic material, and occurs in a subcapsular location or in deep liver parenchyma (3).

Recent advances in hepatic surgery have led to an increase in the number of candidates for partial hepatic resection due to metastatic diseases. The major roles of imaging are to provide a clear and detailed map of hepatic metastasis and to make a careful preoperative selection of patients, thus avoiding unnecessary surgical exploration. Noninvasive imaging techniques, including US, CT, and MR imaging, have recently improved the detection of hepatic metastasis. Among these modalities, CTAP is known to be most sensitive for the detection of focal hepatic lesions, though its high false-positive rate is considered a disadvantage (6). Intraoperative US has also been used to detect small metastases not identified by direct palpation or by other preoperative imaging techniques (7). However, the radiologic features of these modalities are not sufficiently specific for the accurate characterization of liver tumors.

On contrast-enhanced CT, hepatic metastases usually present as focal hypoattenuating areas relative to normal hepatic parenchyma, on CTAP as oval or round areas of perfusion defect, and on US as target-appearing hypochoic nodules. In patients with primary malignancy, the focal hepatic lesion mimicking hepatic metastasis include liver abscess, inflammatory pseudotumor (8), and focal eosinophilic infiltration (9, 10). In our cases, the radiological findings of solitary necrotic nodule of the liver on each

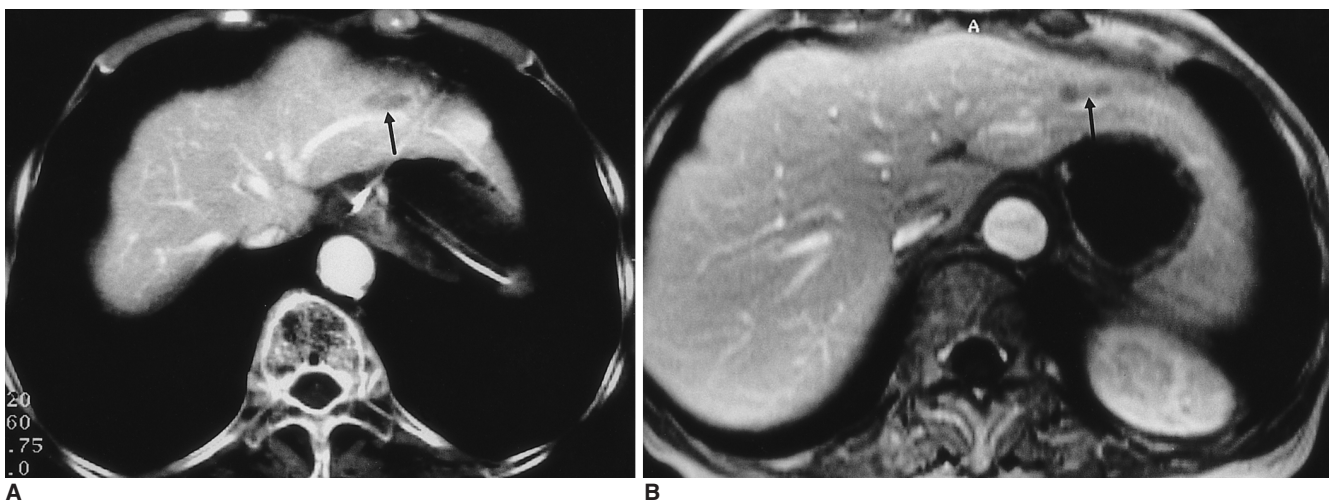


Fig. 2. A 72-year-old man who six years earlier had undergone subtotal gastrectomy due to gastric cancer.
A. Contrast-enhanced CT shows an elliptical hypoattenuating nodule (arrow) in the lateral segment of the liver.
B. Contrast-enhanced T1-weighted MR image shows a subtle peripheral enhancing nodule (arrow) at the same site.

modality were similar to those of hepatic metastasis. Because solitary necrotic nodule of the liver exhibits central hypoattenuation of the necrotic area and peripheral hyperattenuation due to the presence of fibrosis, differentiation by means of CT between this nodule and hepatic metastasis is very difficult or impossible. The intraoperative US findings of the lesion also simulated hepatic metastasis, even though lesion multiplicity had been elucidated. A hepatic metastatic tumor usually appears as a well-defined, round mass, but in our cases, a solitary necrotic nodule of the liver seen as a relatively ovoid or elliptical mass. Such a finding is not specific for this condition, however, and for correct diagnosis, needle biopsy may therefore be necessary.

In conclusion, solitary necrotic nodule of the liver may be revealed by on radiologic imaging as single or multiple lesions of the liver, a finding which may be misinterpreted as metastatic hepatic tumor.

References

1. Shepherd NA, Lee G. Solitary necrotic nodules of the liver stimulating hepatic metastases. *J Clin Pathol* 1983;36:1181-1183
2. Alfieri S, Carriero C, Doglietto GB, Pacelli F, Crucitti F. Solitary necrotic nodule of the liver: diagnosis and treatment. *Hepato-gastroenterology* 1997;44:1210-1211
3. Tsui WMS, Yuen RWS, Chow LTC, Tse CCH. Solitary necrotic nodule of the liver: parasitic origin? *J Clin Pathol* 1992;45:975-978
4. Berry CL. Solitary necrotic nodule of the liver: a probable pathogenesis. *J Clin Pathol* 1985;38:1278-1280
5. Sundaresan M, Lyons B, Akosa AB. 'Solitary' necrotic nodules of the liver: an etiology reaffirmed. *Gut* 1991;32:1378-1380
6. Soyer P, Levesque M, Elias D, Zeitoun G, Roche A. Preoperative assessment of resectability of hepatic metastases from colon carcinoma: CT portography vs sonography and dynamic CT. *AJR* 1992;159:741-744
7. Hagspiel KD, Neidl KFW, Eichenberger AC, Weder W, Marincek B. Detection of liver metastases: comparison of superparamagnetic iron oxide-enhanced and unenhanced MR imaging at 1.5 T with dynamic CT, intraoperative US, and percutaneous US. *Radiology* 1995;196:471-478
8. Yoon K-H, Ha HK, Lee JS, et al. Inflammatory pseudotumor of the liver in patients with recurrent pyogenic cholangitis: CT-histopathologic correlation. *Radiology* 1999;211:373-379
9. Won JH, Kim M-J, Kim BM, et al. Focal eosinophilic infiltration of the liver: a mimick of hepatic metastasis. *Abdom Imaging* 1999;24:369-372
10. Lee WJ, Lim HK, Lim JH, Kim SH, Choi SH, Lee SJ. Foci of eosinophil-related necrosis in the liver: imaging findings and correlation with eosinophilia. *AJR* 1999;172: 1255-1261