

# Nuclear Investigative Techniques and their Interpretation in the Heart and Vascular Disease

## Abstract

Over the last several decades, myocardial perfusion imaging with single photon emission tomography and positron emission tomography has been a mainstay for the evaluation of patients with known or suspected coronary artery disease non-invasively. Technical advances in imaging modalities and radiopharmaceutical have revolutionaries the understanding of pathogenesis and management of various diseases. In this article, we shall discuss the various available imaging nuclear medicine techniques, radiopharmaceutical, and common indications. In the era of “precision medicine,” imaging has to be patient centered. We will briefly review the upcoming areas of nuclear medicine imaging apart from perfusion imaging, such as advances in myocardial blood flow quantitation and molecular imaging.

**Keywords:** Coronary artery disease, coronary flow reserve, ischemic heart disease, myocardial perfusion imaging, positron emission tomography, single-photon emission computed tomography, viability

## Introduction

Nuclear medicine imaging consists of imaging modalities examining a physiological and functional aspect of various diseases in non-invasively. It includes imaging perfusion, function, metabolism, receptors expression, inflammation, and neoplasm. Myocardial perfusion imaging (MPI) was developed more than 30 years ago as planar two-dimensional technique using a thallium-201. New radiopharmaceutical development leads to superior imaging qualities. Multi-detector gamma cameras with 3-dimensional topographic imaging capability single-photon emission computed tomography (SPECT) were developed.<sup>[1]</sup> Another very important advancement is the fusion of functional and anatomical images; hybrid SPECT/CT, positron emission tomography (PET)/CT, and PET/MRI systems.<sup>[2]</sup>

Nuclear cardiology provides functional inside of cardiovascular diseases (CVD), whereas other imaging modalities (ECHO, angiography, CT, and MRI) provide predominant morphological or anatomical information. It has been known that anatomical stenosis severity may not

correlate absolutely with its physiological severity.<sup>[3]</sup> Hence, emphasis is being put on the dysfunctional aspect of the disease. It has been extensively investigated in known or suspected coronary artery diseases (CAD), to know the presence of stress-induced ischemia and for assessment of the viability of myocardium after myocardial infarction (MI). It is useful in the diagnosis of occult CAD in a special population such as obese, female, diabetes, and patients unable to exercise. PET technology has opened a new domain in nuclear cardiology and research as it can absolutely measure myocardial blood flow (MBF) and myocardial flow reserve (MFR) non-invasively.

## Nuclear Medicine Techniques

Radiopharmaceutical is pharmaceutical agent labeled with radioactive elements. After administration, they emit radiation and are detected by special cameras.

## Single-Photon Emission Computed Tomography Systems

Conventional SPECT cameras comprise of sodium iodide detectors and large photomultiplier tubes that yield suboptimal photon detection and processing. It has several difficulties of decreased sensitivity and compromised image quality.<sup>[4]</sup>

**How to cite this article:** Ora M, Gambhir S. Nuclear investigative techniques and their interpretation in the heart and vascular disease. *Ann Card Anaesth* 2020;23:262-71.

**Manish Ora,  
Sanjay Gambhir**

*Department of Nuclear  
Medicine, SGPGIMS, Lucknow,  
Uttar Pradesh, India*

**Submitted:** 26-Mar-2019

**Accepted:** 27-Mar-2019

**Published:** 17-Jul-2020

### Address for correspondence:

*Prof. Sanjay Gambhir,  
Department of Nuclear  
Medicine, SGPGIMS,  
Lucknow - 226 014,  
Uttar Pradesh, India.  
E-mail: gaambhir@yahoo.com*

### Access this article online

**Website:** www.annals.in

**DOI:** 10.4103/aca.ACA\_54\_19

### Quick Response Code:



This is an open access journal, and articles are distributed under the terms of the Creative Commons Attribution-NonCommercial-ShareAlike 4.0 License, which allows others to remix, tweak, and build upon the work non-commercially, as long as appropriate credit is given and the new creations are licensed under the identical terms.

**For reprints contact:** reprints@medknow.com

*Gamma camera advancement and reconstruction techniques*

Development of faster computer system changes the medical imaging system. Multiple head gamma camera led to an increase in overall sensitivity and decreased acquisition time. Shorter imaging times lead to reduced patient motion during scans and increasing patient comfort.<sup>[5]</sup> Advanced iterative reconstruction algorithms improved image resolution and contrast.<sup>[6]</sup>

*Dedicated Cardiac Cadmium-Zinc-Telluride scanners*

In cadmium-zinc-telluride (CZT) based cameras, gamma-photon energy is directly converted into an electrical signal through solid-state technology. This gives an overall better energy resolution, intrinsic resolution, decreased scatter, compact camera design, and decreased acquisition time.<sup>[2]</sup> Einstein *et al.* compared image quality, interpretation, total perfusion deficit, and ejection fraction on ultra-low-dose imaging with a CZD camera and standard SPECT imaging and found improved image quality, with dose reduction to 1 mSv.<sup>[7]</sup>

*Single-Photon Emission Computed Tomography/Computed Tomography*

The integration of SPECT and CT provides a significant advance in technology. First commercial SPECT/CT system, introduced by General Electric as the Hawkeye, used a low-dose CT and thick single slice acquisition.<sup>[8]</sup> The purpose of it was attenuation correction and general localization only, whereas recent cameras are using full diagnostic CT

**Positron Emission Tomography System/Computed Tomography**

PET instrumentation has undergone a steady multifaceted evolution with 3-dimensional mode operation, newer detector crystals, larger axial Field of View, time-of-flight

technique, new reconstruction methods, and diagnostic CT component. Efforts have been undertaken to compensate for respiratory and cardiac motion (4-dimensional PET/CT), which further improves image quality.<sup>[9]</sup> Digital PET designs use silicon digital photomultipliers or avalanche photodiode have lead to improvements in sensitivity and image resolution.

**Positron Emission Tomography/Magnetic Resonance Imaging system**

Magnetic resonance imaging (MRI) provides accurate anatomy, soft tissue contrast, allowing improved discrimination of lesions, and pathological changes. Combining MRI and PET into a single scanner was a major technological challenge, primarily because of the difficulties in developing PET detectors that will operate within a strong magnetic field. Current hybrid PET/MRI scanners offer simultaneous, spatially co-registered imaging, precisely combining the molecular specificity of PET imaging with the anatomy, tissue characterization, and functional information provided by MRI.<sup>[10]</sup>

**Imaging tracers**

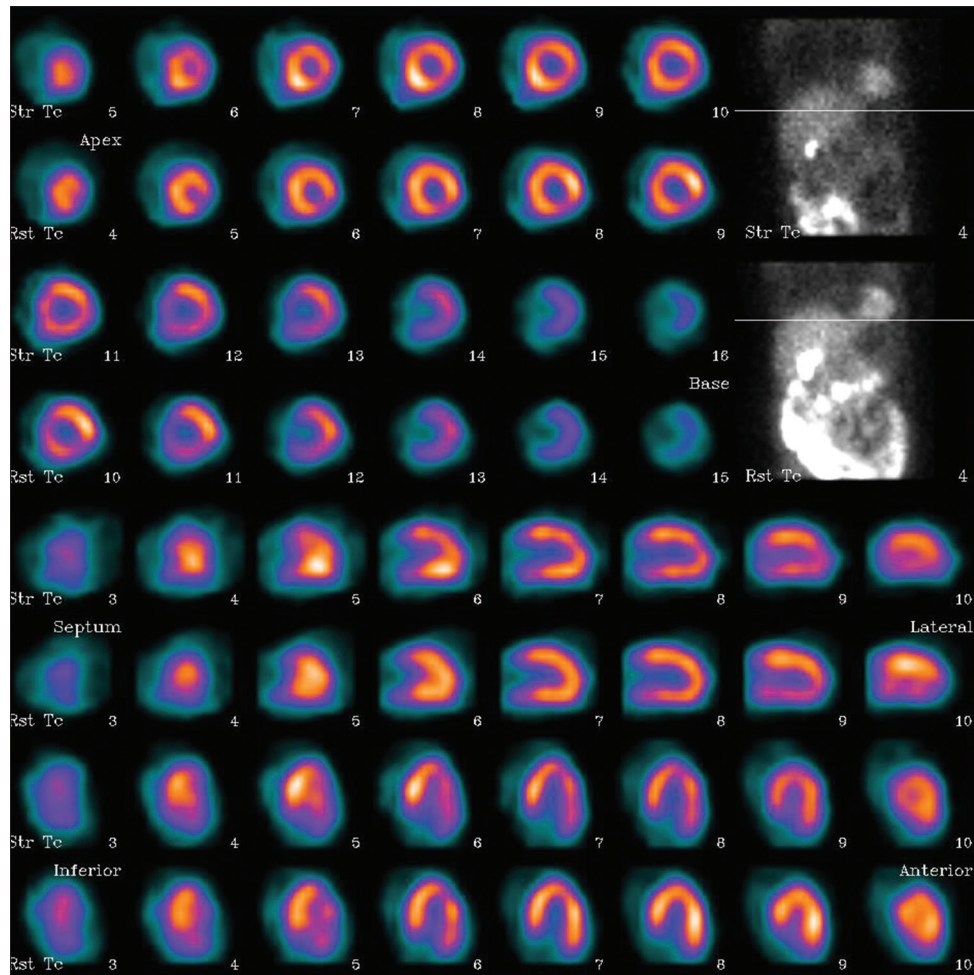
A remarkable development has been noted in the field of radiopharmacy. Previously used tracer was mostly non-specific perfusion agent depositing in the heart depending upon the blood flow. These tracers give functional information of CAD and ischemic heart disease (IHD). With the PET era, new and novel molecular probes were invented and used for preclinical and clinical imaging giving non-invasive molecular insight of different pathologies.<sup>[11,12]</sup> [Table 1].

*Imaging protocol*

Guidelines have standardized indication for MPI, patient preparations, methods of stresses; their indications, acquisition protocols, post-acquisition processing, and structured reporting.<sup>[13]</sup> For MPI, standard stress- rest protocol is followed. [Figure 1] Exercise stress is given

**Table 1: Summarizing few radiopharmaceutical used in nuclear myocardial imaging, their target, and pathology**

Tracer	Modality	Target	Disease/Pathology
Thallium-201	SPECT	Potassium analogue	Perfusion
<sup>99m</sup> Tc-sestamibi	SPECT	Passive diffusion and appears in the cytosol and intra mitochondria	Perfusion
<sup>99m</sup> Tc-tetrofosmin	SPECT	Intracellular	Perfusion
<sup>99m</sup> Tc-HYNIC-annexin V	SPECT	Phosphatidylserine	Apoptosis
Fluorine-18-deoxyglucose (FDG)	PET	Glucose analogue	Viability/inflammation
Rubidium (82Rb) chloride	PET	Analogue of potassium	Perfusion
Ammonia (13N)	PET	Diffusion	Perfusion
Water (15O)	PET	Diffusion	Perfusion
Flurpiridaz F-18	PET	Bind to mitochondrial complex	Perfusion
<sup>11</sup> C-hydroxyephedrine	PET	Denervation	IHD/heart failure
<sup>11</sup> C-PiB/ <sup>18</sup> F-florbetapir	PET	Amyloid	Amyloidosis
<sup>64</sup> Cu/ <sup>68</sup> Ga –DOTATATE	PET	Activated macrophages	Atherosclerosis
<sup>18</sup> F-sodium fluoride	PET	Micro-calcification	Atherosclerosis
<sup>11</sup> C-choline	PET	Lipid metabolism	Atherosclerosis
<sup>68</sup> Ga-NOTA-RGD	PET	Angiogenesis	Atherosclerosis



**Figure 1:** Pharmacological stress myocardial perfusion imaging in a 56-year-old female presented with atypical chest pain. Upper four rows are transaxial images, 5<sup>th</sup>-6<sup>th</sup> rows are vertical long axis (VLA) and lower two rows are horizontal long axis (HLA). Each consecutive rows are of stress (Str Tc) and rest (Rst Tc) images. Scan finding is suggestive of normal myocardial perfusion scan

by treadmill or bicycle ergometers. In the presence of contraindication for physical stress, various pharmacological agents such as vasodilator agents (adenosine, regadenoson, or dipyridamole) and dobutamine may be used.

### Interpretation in the Heart and Vascular Disease

The role of all imaging procedure is to add information to the overall clinical scenario of the patient and should improve the clinician’s decision-making process with a goal of ameliorating patient symptoms and/or bettering clinical outcomes. Interpretation of radionuclide MPI studies is based upon sequential Bayesian analysis of disease probability. Patients with very low or high pretest probabilities of CAD are unlikely to benefit from the addition of noninvasive imaging.<sup>[14]</sup> We shall be discussing few common indications of nuclear cardiology procedures and their clinical interpretation.

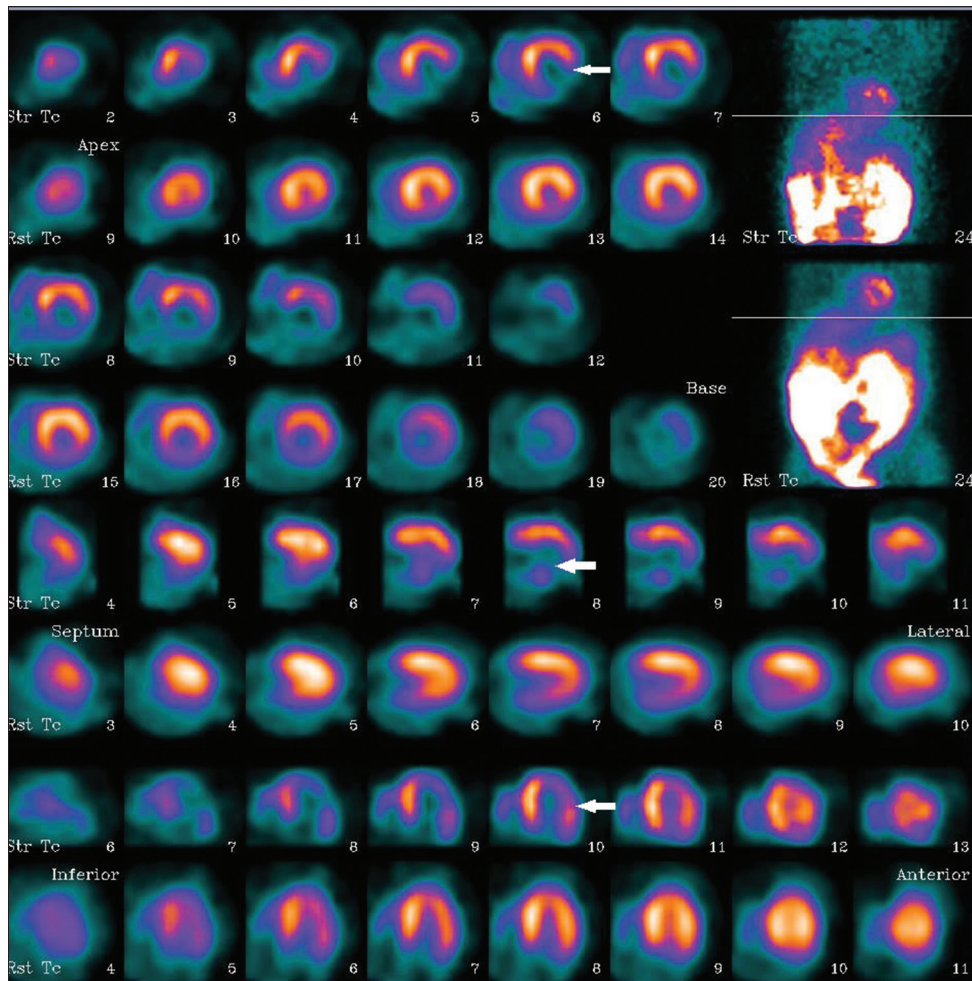
### Evaluation of patients with known or suspected CAD

CAD is the leading cause of morbidity and mortality worldwide. Invasive coronary angiography is

considered gold standard in establishing the diagnosis of CAD, however, it indirectly measures ischemic heart disease (IHD). In the setting of chest pain, the prevalence or pretest probability of CAD depends on characteristics including age, gender, coronary risk factors, and nature of the presenting symptoms. MPI with physical exercise or pharmacological stress determines regional differences in coronary blood flow and provides insight of flow limiting epicardial CAD and endothelial dysfunction non-invasively. SPECT MPI studies provide a qualitative or semi-quantitative assessment of regional perfusion defects, whereas PET can provide absolute quantitation of MBF and coronary flow reserve (CFR).

MPI tracers show the linear relationship of between peak stress MBF and myocardial tracer concentration. SPECT MPI will detect ischemia when stenosis is capable of producing a reduction in flow if the diameter of stenosis is ~50–70%. [Figure 2] Early published literature (according to a pooled analysis of 79 studies of approximately 9,000 patients) with SPECT reported sensitivity and specificity of 86% and 74%, respectively for





**Figure 2: Pharmacological stress myocardial perfusion imaging in a 64-year-old male with no risk factor and presented with increasing dyspnoea on exertion since 3 months. TMT was mild positive in inferior leads. MPI revealed large area of moderate to severe stress induced ischemia in the LCx and RCA territories. LAD territory shows mild ischemia. Coronary angiography revealed triple-vessel disease**

detecting >50% angiographic stenosis.<sup>[15]</sup> A meta-analysis of approximately 12,000 patients in 177 studies (108 SPECT MPI, 4 PET MPI, and 5 PET and SPECT MPI) confirmed higher sensitivity of PET relative to SPECT MPI (92.6% vs. 88.3%) with comparable specificity.<sup>[16]</sup> In contrast to angiography, MPI predominantly identifies coronary territories supplied by the most severe stenosis, and therefore, may be a less sensitive technique in the setting of multivessel disease. This is an area where PET MPI holds great potential.<sup>[17]</sup> PET MPI directly measure MBF and CFR and considered as the gold standard. CFR is the ratio of hyperemic to rest absolute MBF and is an integrated measure of coronary vasomotor dysfunction. It measures hemodynamic effects of focal, diffuse, and small-vessel CAD on myocardial perfusion.<sup>[3]</sup>

Hybrid CT angiography-SPECT demonstrates improved diagnostic specificity for detection of CAD compared with stand-alone coronary CTA.<sup>[18]</sup> Physiologic severity defined by coronary pressure and/or flow has resurged into clinical prominence as a potential, fundamental change from anatomically to physiologically guided management.

<sup>[3]</sup> The measurement of fractional flow reserve (FFR) has shown that the physiological index of stenosis severity may be superior to anatomical assessment in guiding the decision for coronary revascularization and result in improved clinical outcomes.<sup>[19]</sup> Deferral versus performance of percutaneous coronary intervention (PCI) of functionally non-significant coronary stenosis study demonstrated the importance of functional assessment of CAD. Authors show that percutaneous intervention of lesion with  $FFR \geq 0.75$  failed to improve clinical outcomes i.e. event-free survival, cardiac mortality, and myocardial infarction or percent free of angina. They even demonstrated that percutaneous coronary intervention in reference group (i.e.  $FFR < 0.75$ ) failed to prevent cardiac death or acute MI and was associated with a five times incidence of these outcomes compared to medical therapy alone.<sup>[20]</sup> Importance of functional imaging is to identify culprit lesion and guiding revascularization vs. medical management.

#### Assessment of prognosis and risk stratification

Radionuclide MPI provides incremental value for risk assessment in patients with known or suspected

CAD. There is a linear risk of cardiac death and MI associated with increasing extent and severity of perfusion abnormalities. A normal or low-risk SPECT study is associated with a low major adverse CV event rate of 0.6% per year, as reported in a meta-analysis of 19 studies of approximately 40,000 patients evaluated over 10 years and comparable to event rates in the general population without CAD.<sup>[21]</sup> An abnormal SPECT MPI predicts a multifold increase in the rates of death (9.2% vs. 2.6%), death or MI (11.8% vs. 3.3%), and revascularization (24.7% vs. 2.7%).<sup>[22]</sup> Hachamovitch *et al.* showed that increase in extent and severity of stress perfusion abnormality, predicted higher rates of MI, and death; a summed stress score of >13 was associated with annual MI risk of 4.2%.<sup>[23]</sup> Although in the presence of angiographically documented CAD, normal stress MPI is associated with a low risk of CV events (~1% per year).<sup>[21]</sup> A significant increase in annual cardiac mortality is noted in patients without relative perfusion defects if CFR was reduced (0.4% vs. 3.5%). Diabetic patients without known CAD with impaired MFR show similar rate of cardiac death to nondiabetics with CAD (2.8%/year and 2.0%/year, respectively). Diabetic patients without CAD and preserved MFR show similar death rates similar to patients without CAD.<sup>[24]</sup> PET provides incremental risk stratification that leads to significant and meaningful risk-reclassification (of approximately 35%) of intermediate risk patients. CFR of <2 and <1.5 has been associated with a 3.4- and 5.6-fold increased risk of cardiac death, respectively.<sup>[25]</sup> CFR measurements by PET can distinguish patients at low or high risk

for serious adverse events, including CVD, beyond comprehensive clinical assessment, LV ejection fraction, or traditional semi-quantitative measures of stress-induced ischemia [Figure 3].

### Myocardial perfusion imaging to guide revascularization in chronic coronary artery diseases

In a large observational study of 10,627 patients with suspected CAD, SPECT MPI demonstrated that patients with no or a mild amount of inducible ischemia have survival advantage with medical therapy. Conversely, patients with extensive ischemic myocardium >10% show survival benefit with revascularization.<sup>[26]</sup> Another large observational study with 13,555 patients show that patients with >12.5% ischemic myocardium had improved survival with early revascularization.<sup>[27]</sup> [Figure 4] There is an association between the extent and severity of hibernating myocardium, post-test treatment, and subsequent patient survival. Patients with limited hibernating myocardium may benefit from medical therapy and those with extensive hibernating myocardium (>10%) may benefit from the early revascularization.<sup>[28]</sup>

### Assessment of myocardial viability

“Hibernating myocardium” is defined as the presence of severe systolic dysfunction with evidence of hypoperfusion at rest. It describes dysfunction without tissue necrosis, which enables possible functional recovery after the restoration of blood supply.<sup>[29]</sup> Viability testing may help to predict response to revascularization in patients with CAD and left ventricular dysfunction.

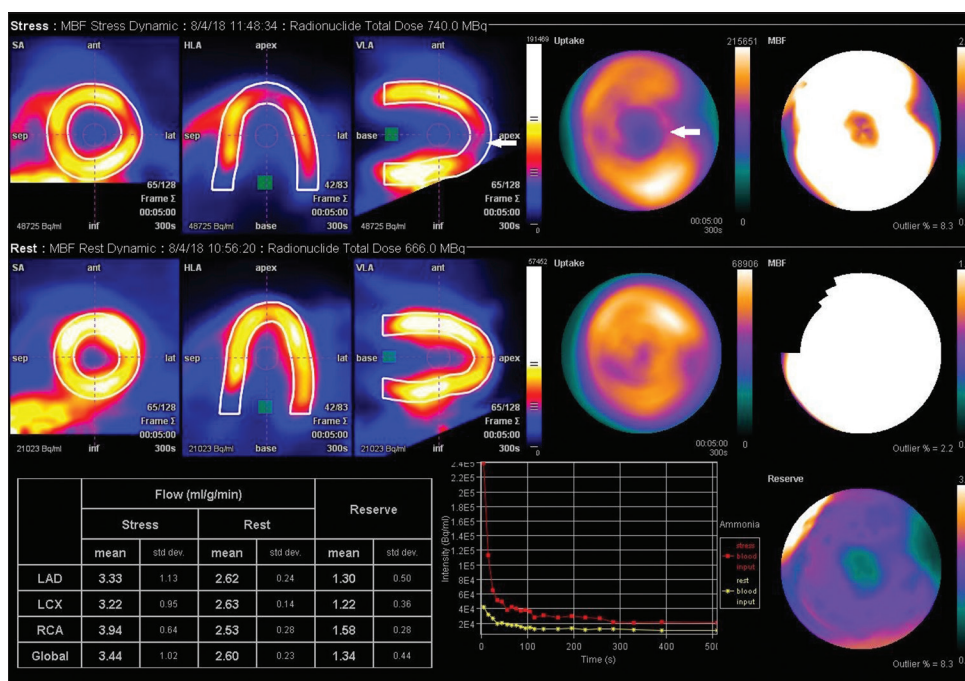
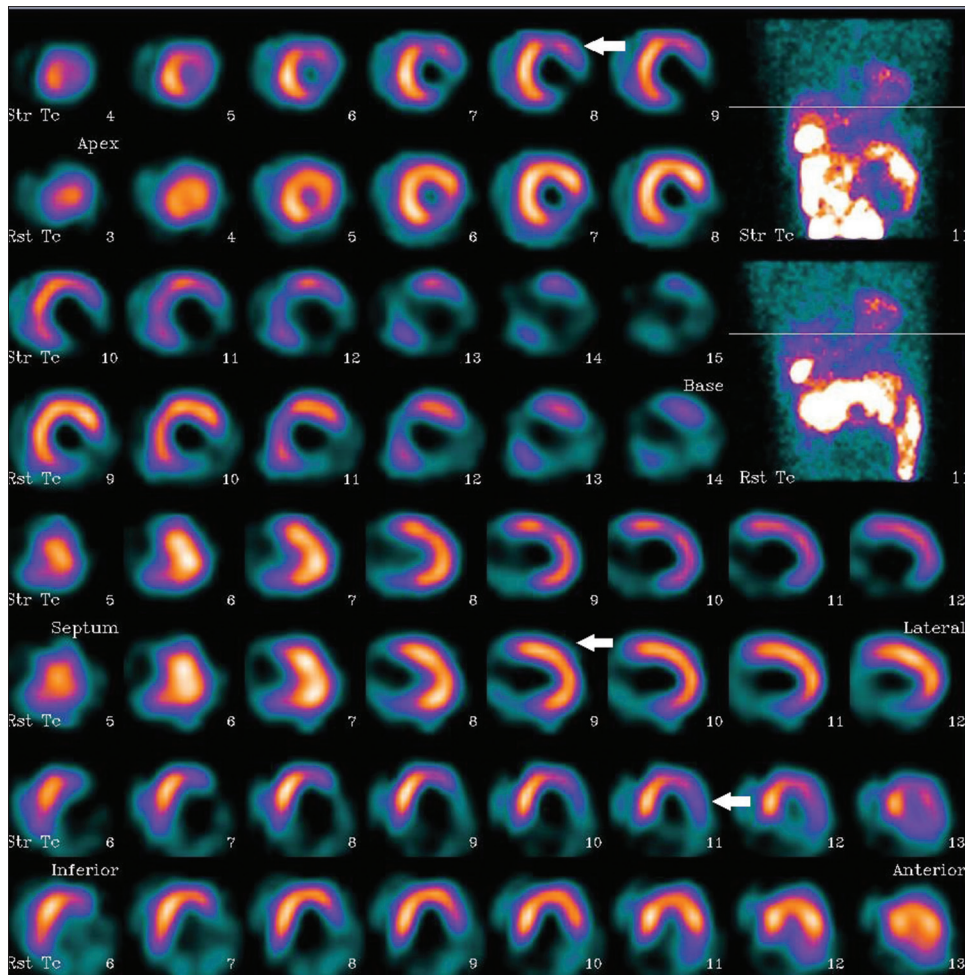


Figure 3: Pharmacological stress and rest 13-Ammonia myocardial perfusion imaging in a 57-year-old diabetic male presenting with angina on exertion. TMT could not be done because of obesity. MPI revealed small area of severe stress induced ischemia in the apical region (LAD territory). CFR is also decreased for all three vessels suggestive of coexisting endothelial dysfunction





**Figure 4: Pharmacological stress myocardial perfusion imaging in a 71-year-old male with diabetes, hypertension, CAD, and post inferior wall MI. MPI revealed large areas of moderate stress induced ischemia in the LAD and LCX territories, severe fixed perfusion defect (scarred myocardium) in the basal inferior- inferolateral walls with mild peri-infarct ischemia**

Sestamibi and tetrofosmin are retained in the mitochondria and reflect intact mitochondrial membranes and function, thus are markers of cellular viability. Technetium-99m tracers may underestimate viability but are widely available, and nitrate administration before injection further improve sensitivity of test.

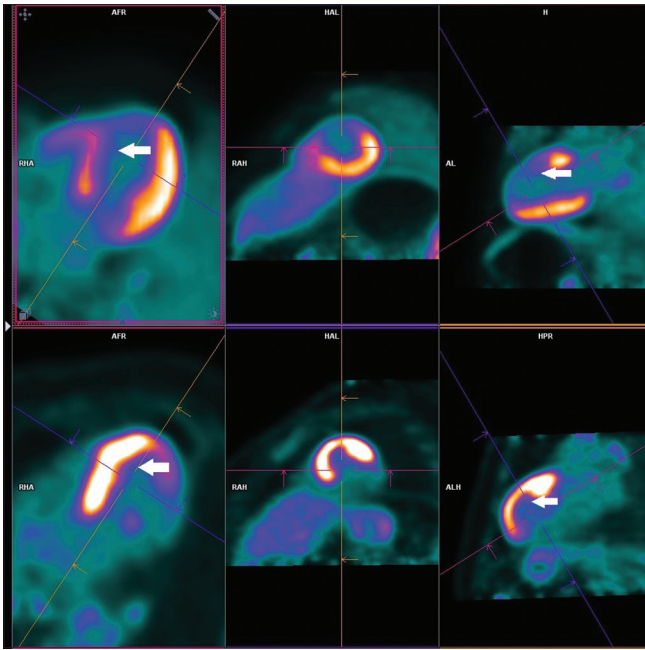
Under normal circumstances, the myocardium utilizes fatty acids as energy source; however, alterations imposed by chronic ischemia favor substrate switch to glucose. <sup>18</sup>F-FDG PET utilizes same principle. The PET imaging protocol consists of two parts: myocardial perfusion and metabolism. Radionuclides used in perfusion imaging include rubidium 82 and N-13 ammonia and their uptake is proportional to MBF. In FDG- PET viability imaging, three patterns are seen. The most important is “perfusion-metabolism mismatch” i.e. reduced perfusion and preserved FDG uptake, suggestive of viable, and hibernating myocardium. [Figure 5] A second pattern includes normal perfusion and metabolism in dysfunctional segments. In this setting, the myocardium may be normal or stunned, and in the setting of a dilated ventricle, the pattern

represents a remodeled heart. A third pattern comprises of matched perfusion and metabolism defect, indicate scar.<sup>[30]</sup>

In patients with severe LV dysfunction, amount of scarring is an independent predictor of LV function recovery after revascularization.<sup>[30]</sup> A substudy of the PARR-2 trial demonstrated that patients with ischemic cardiomyopathy and larger amounts of perfusion-metabolism mismatch have improved outcomes with revascularization.<sup>[31]</sup> The Ottawa-FIVE substudy of the PARR-2 trial utilizes PET-assisted management of patients with severe LV dysfunction and suspected CAD showed a significant benefit of the FDG-PET assisted approach.<sup>[32]</sup>

#### Preoperative risk stratification of non-cardiac surgery

Perioperative morbidity and mortality due to CAD is an important complication of non-cardiac surgery. The Perioperative Ischemic Evaluation (POISE) trial reported perioperative mortality for non-cardiac surgery to be 2.7% (226/8351) with 1.6% having a CV cause.<sup>[33]</sup> In addition to underlying cardiac pathology, systemic factors, such as pain, catecholamines,



**Figure 5: Viability assessment with perfusion - metabolism protocol using  $^{13}\text{N}$ - ammonia (upper row) and  $^{18}\text{F}$ -FDG (lower row). Severe perfusion defect is noted in the LAD territory (apex, peri-apical, apical to mid anterior- antero-septal walls showing preserved metabolism (mismatch)- suggestive of viable hibernating myocardium**

and hypercoagulability, contribute to perioperative risk because they can influence oxygen supply and demand.<sup>[34]</sup> Mukherjee *et al.* identified eight steps for preoperative cardiac risk stratification clinical evaluation, surgery-specific risk, functional capacity, non-invasive and invasive testing, medical therapy, perioperative care and surveillance, and long-term therapy.<sup>[35]</sup> Revised cardiac risk index includes six independent predictors high-risk surgery, history of IHD, history of CHF, history of cerebrovascular disease, treatment with insulin, and serum creatinine  $>2.0$  mg/dL.<sup>[36]</sup>

Functional capacity is an important perioperative and a long-term prognostic indicator of cardiac events.<sup>[35]</sup> Less than four metabolic equivalent of tasks (METs) is poor functional capacity, and hence, high risk and  $\sim 10$  METs are good functional capacity with low risk. However, it is not feasible to evaluate the functional capacity of non-ambulatory patients. Preoperative MPI has a high negative predictive value and a normal preoperative MPS result incurs a low perioperative risk and low long-term risk. [Figure 6] The benefit of MPI is unproven in low-risk patients and is probably not cost-effective. MPI has the greatest utility in the management of intermediate to high-risk patients with limited exercise tolerance whose signs or symptoms suggestive of CAD. Recent guidelines also support these findings.<sup>[37]</sup> A large retrospective, observational study (322,688 patients) who underwent non-cardiac surgery showed that abnormal myocardial perfusion appeared to be an important risk factor for adverse post-operative events in patients undergoing

non-cardiac surgery. However, preoperative coronary revascularization triggered by the abnormal MPI was not clearly associated with better patient outcomes.<sup>[38]</sup>

### Restrictive heart disease and cardiac inflammation

PET represents valuable diagnostic, prognostic, and monitoring non-invasive tools in this group of patient management. Increased glucose metabolism is a hallmark of inflammation; glucose analog [ $^{18}\text{F}$ ]- FDG is the mainstay diagnostic test for imaging of cardiac inflammation. It has proven its value in inflammatory conditions such as myocarditis, endocarditis, sarcoidosis, pericarditis, amyloidosis, and implantable electronic device infections.<sup>[39]</sup> In suspicion of endocarditis on a prosthetic valve, abnormal activity around the site of implantation detected by  $^{18}\text{F}$ -FDG PET/CT (If prosthesis was implanted for  $>3$  months) or radiolabeled leucocyte SPECT/CT is considered a major criterion in recent guideline.<sup>[40]</sup>

### Vulnerable plaque imaging

The plaques that are vulnerable to rupture have large lipid cores, attenuated fibrous cap, and intense infiltration of macrophages, which release metalloproteinases that digest matrix and induce fibrous cap rupture. Plaque rupture exposes thrombogenic lipid core leading to thrombotic luminal obstruction. The presence of vulnerable plaque is a risk factor for plaque rupture and subsequent acute thrombosis, leading to MI. Radionuclides targeting activated macrophages, microcalcification, lipid metabolism, and angiogenesis have been investigated as research molecules to identify vulnerable plaque.<sup>[11,12]</sup> F-18 sodium fluoride (NaF) PET is employed as a bone-seeking agent. High-risk vulnerable plaque appeared to be F-18 NaF-uptake-positive in patients with acute MI.<sup>[41]</sup>

### Vasculitis

It is a group of heterogeneous disorders, characterized by inflammation of blood vessels causing end-organ damage from ischemia, aneurysm, or dissection. They present with non-specific symptoms, raised inflammatory markers. The biopsy is difficult and anatomical imaging lack specificity; FDG PET/CT scanning is increasingly used in large vessel vasculitis; giant cell arteritis (GCA) and Takayasu arteritis. FDG-PET has a limited role in medium and small vessel vasculitis. FDG-PET/CT give information about active inflammation as structural abnormalities. [Figure 7] In patients with GCA, FDG-PET has acceptable sensitivity and specificity for diagnosis in non-cranial GCA, assessment of response to treatment, predicting prognosis but has limited value in serial follow-up and prediction of relapses. It may be useful for early diagnosis and probably for serial assessment of disease activity.<sup>[42,43]</sup>

### Conclusion

Nuclear medicine imaging examine a physiological and functional aspect of various CVDs non-invasively. It can



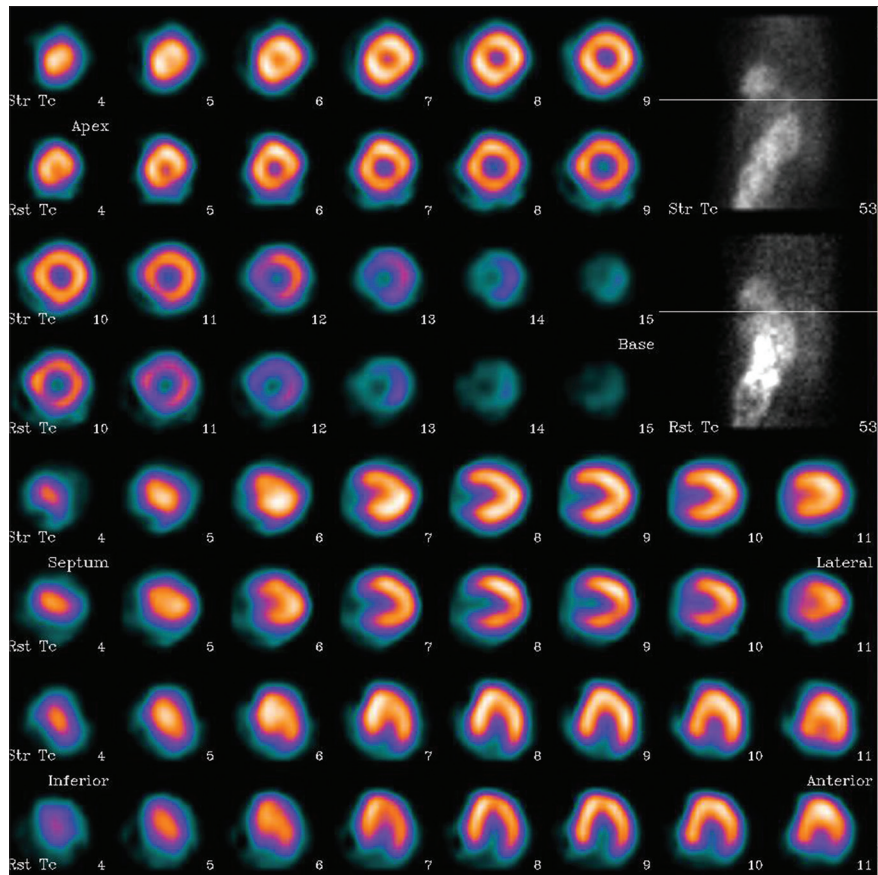


Figure 6: Pharmacological stress myocardial perfusion imaging in a 74-year-old female presented with atypical chest pain. She was a known case of hypertension, diabetes, hypothyroidism, CAD, and post CABG 7 years back. Scan was done for preoperative evaluation for knee replacement. Scan findings are suggestive of normal myocardial perfusion scan. Her perioperative period was unremarkable

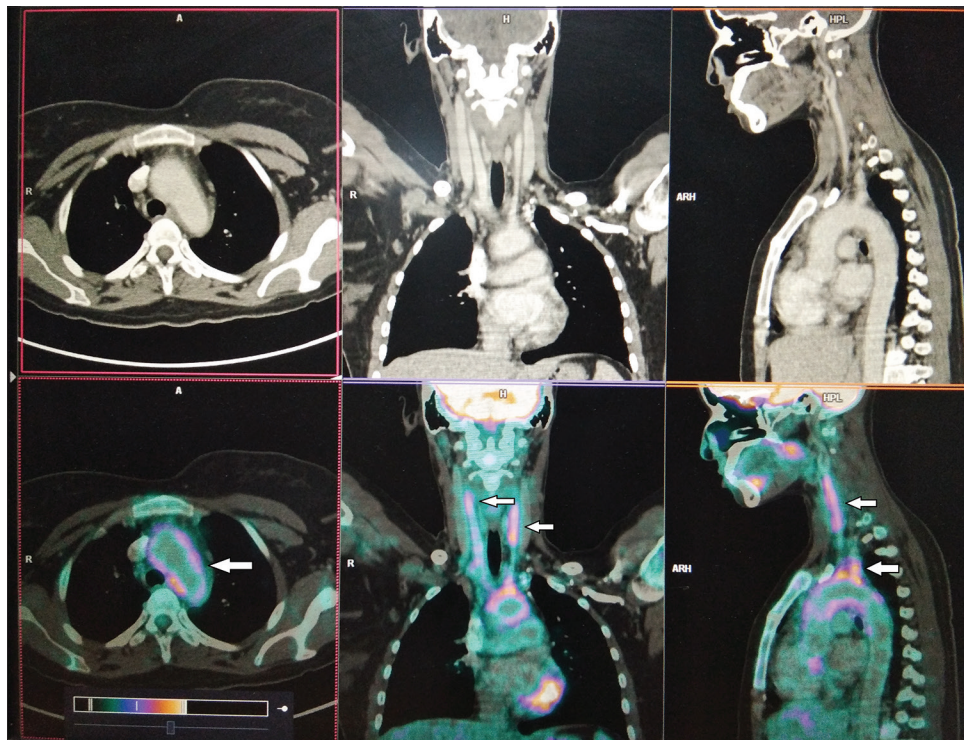


Figure 7: FDG PET CT scan of a patient with large vessel vasculitis. Diffuse FDG uptake is noted in the arch of aorta, bilateral carotid arteries, and the subclavian arteries



image many aspects of physiology such as perfusion, function, metabolism, receptors imaging, and pathological conditions such as inflammation and neoplasm. Rapid development in the field of radiopharmaceutical, gamma cameras, and hybrid imaging has opened a new era in imaging. MPI is a standard of care in the diagnosis of CAD, risk stratification in high-risk population, viability assessment, guiding management, and prognosticating disease. With the potential of molecular imaging, PET has revolutionized our understanding of atherosclerosis vulnerable plaque imaging, infection, and inflammation. Imaging need to be utilized judiciously, should be patient-specific coupled with interdisciplinary clinical judgment, and to be evaluated for their contributions to clinical outcomes.

### Financial support and sponsorship

Nil.

### Conflicts of interest

There are no conflicts of interest.

### References

- Sharir T, Ben-haim S, Merzon K, Prochovov V, Dickman D, Ben-Haim S, *et al.* High-speed myocardial perfusion imaging initial clinical comparison with conventional dual detector angier camera imaging. *JACC Cardiovasc Imaging* 2008;1:156-63.
- Esteves FP, Raggi P, Folks RD, Keidar Z, Askew JW, Rispler S, *et al.* Novel solid-state-detector dedicated cardiac camera for fast myocardial perfusion imaging: Multicenter comparison with standard dual detector cameras. *J Nucl Cardiol* 2009;16:927-34.
- Gould KL, Johnson NP, Bateman TM, Beanlands RS, Bengel FM, Bober R, *et al.* Anatomic versus physiologic assessment of coronary artery disease. Role of coronary flow reserve, fractional flow reserve, and positron emission tomography imaging in revascularization decision-making. *J Am Coll Cardiol* 2013;62:1639-53.
- Lee JS, Kovalski G, Sharir T, Lee DS. Advances in imaging instrumentation for nuclear cardiology. *J Nucl Cardiol* 2019;26:543-56.
- Slomka P, Hung GU, Germano G, Berman DS. Novel SPECT technologies and approaches in cardiac imaging. *Cardiovasc Innov Appl* 2016;2:31-46.
- Knoll P, Kotalova D, Köchle G, Kuzelka I, Minear G, Mirzaei S, *et al.* Comparison of advanced iterative reconstruction methods for SPECT/CT. *Z Med Phys* 2012;22:58-69.
- Einstein AJ, Blankstein R, Andrews H, Fish M, Padgett R, Hayes SW, *et al.* Comparison of image quality, myocardial perfusion, and left ventricular function between standard imaging and single-injection ultra-low-dose imaging using a high-efficiency SPECT camera: The MILLISIEVERT study. *J Nucl Med* 2014;55:1430-7.
- Patton JA, Delbecke D, Sandler MP. Image fusion using an integrated, dual-head coincidence camera with x-ray tube-based attenuation maps. *J Nucl Med* 2000;41:1364-8.
- Slomka PJ, Pan T, Germano G. Recent advances and future progress in PET instrumentation. *Semin Nucl Med* 2016;46:5-19.
- Robson PM, Dey D, Newby DE, Berman D, Li D, Fayad ZA, *et al.* MR/PET imaging of the cardiovascular system. *JACC Cardiovasc Imaging* 2017;10:1165-79.
- Mikołajczak R, Garnuszek P. Radiopharmaceuticals in cardiology. *Nucl Med Rev Cent East Eur* 2012;15:39-45.
- Sogbein OO, Pelletier-galarneau M, Schindler TH, Wei L, Wells RG, Ruddy TD. New SPECT and PET radiopharmaceuticals for imaging cardiovascular disease. *Biomed Res Int* 2014;2014:942960.
- Tilkemeier PL, Bourque J, Doukky R, Sanghani R, Weinberg RL. ASNC imaging guidelines for nuclear cardiology procedures: Standardized reporting of nuclear cardiology procedures. *J Nucl Cardiol* 2017;24:2064-128.
- Patterson RE, Horowitz SF, Eisner RL. Comparison of modalities to diagnose coronary artery disease. *Semin Nucl Med* 1994;24:286-310.
- Schuijff JD, Poldermans D, Shaw LJ, Jukema JW, Lamb HJ, de Roos A, *et al.* Diagnostic and prognostic value of non-invasive imaging in known or suspected coronary artery disease. *Eur J Nucl Med Mol Imaging* 2006;33:93-104.
- Parker MW, Iskandar A, Limone B, Perugini A, Kim H, Jones C, *et al.* Diagnostic accuracy of cardiac positron emission tomography versus single photon emission computed tomography for coronary artery disease: Abivariate meta-analysis. *Circ Cardiovasc Imaging* 2012;5:700-7.
- Taqueti VR, Di carli MF. Radionuclide myocardial perfusion imaging for the evaluation of patients with known or suspected coronary artery disease in the era of multimodality cardiovascular imaging. *Prog Cardiovasc Dis* 2015;57:644-53.
- Rizvi A, Han D, Danad I, Ó Hartaigh B, Lee JH, Gransar H, Stuijzand WJ, *et al.* Diagnostic performance of hybrid cardiac imaging methods for assessment of obstructive coronary artery disease compared with stand-alone coronary computed tomography angiography: A meta-analysis. *JACC Cardiovasc Imaging* 2018;11:589-99.
- Pijls NH, De Bruyne B, Peels K, Van Der Voort PH, Bonnier HJ, Bartunek JKKJ, *et al.* Measurement of fractional flow reserve to assess the functional severity of coronary-artery stenoses. *N Engl J Med* 1996;334:1703-8.
- Pijls NH, van Schaardenburgh P, Manoharan G, Boersma E, Bech JW, van't Veer M, *et al.* Percutaneous coronary intervention of functionally nonsignificant stenosis: 5-year follow-up of the DEFER Study. *J Am Coll Cardiol* 2007;49:2105-11.
- Shaw LJ, Iskandrian AE. Prognostic value of gated myocardial perfusion SPECT. *J Nucl Cardiol* 2004;11:171-85.
- Doukky R, Hayes K, Frogge N, Balakrishnan G, Dontaraju VS, Rangel MO, *et al.* The impact of appropriate use on the prognostic value of SPECT myocardial perfusion imaging. *Circulation* 2013;128:1634-43.
- Hachamovitch R, Berman DS, Shaw LJ, Kiat H, Cohen I, Cabico JA, *et al.* Incremental prognostic value of myocardial perfusion single photon emission computed tomography for the prediction of cardiac death: Differential stratification for risk of cardiac death and myocardial infarction. *Circulation* 1998;97:535-43.
- Murthy VL, Naya M, Foster CR, Gaber M, Hainer J, Klein J, *et al.* Association between coronary vascular dysfunction and cardiac mortality in patients with and without diabetes mellitus. *Circulation* 2012;126:1858-68.
- Murthy VL, Naya M, Foster CR, Hainer J, Gaber M, Di Carli G, *et al.* Improved cardiac risk assessment with noninvasive measures of coronary flow reserve. *Circulation* 2011;124:2215-24.
- Hachamovitch R, Hayes SW, Friedman JD, Cohen I, Berman DS. Comparison of the short-term survival benefit associated with revascularization compared with medical therapy in patients with no prior coronary artery disease undergoing stress myocardial perfusion single photon emission computed tomography. *Circulation* 2003;107:2900-7.
- Hachamovitch R, Rozanski A, Shaw LJ, Stone GW, Thomson LE, Friedman JD, *et al.* Impact of ischaemia and scar on the therapeutic benefit derived from myocardial revascularization vs medical therapy among patients undergoing stress-rest myocardial perfusion scintigraphy. *Eur Heart J* 2011;32:1012-24.
- Ling LF, Marwick TH, Flores DR, Jaber WA, Brunken RC, Cerqueira MD, *et al.* Identification of therapeutic benefit from revascularization in patients with left ventricular systolic dysfunction:

- Inducible ischemia versus hibernating myocardium. *Circ Cardiovasc Imaging* 2013;6:363-72.
29. Narula J, Dawson MS, Singh BK, Amanullah A, Acio ER, Chaudhry FA, *et al.* Noninvasive characterization of stunned, hibernating, remodeled and nonviable myocardium in ischemic cardiomyopathy. *J Am Coll Cardiol* 2000;36:1913-9.
  30. Beanlands RS, Ruddy TD, Dekemp RA, Iwanochko RM, Coates G, Freeman M, *et al.* Positron emission tomography and recovery following revascularization (PARR-1): The importance of scar and the development of a prediction rule for the degree of recovery of left ventricular function. *J Am Coll Cardiol* 2002;40:1735-43.
  31. D'Egidio G, Nichol G, Williams KA, Guo A, Garrard L, deKemp R, *et al.* Increasing benefit from revascularization is associated with increasing amounts myocardial hibernation: A substudy of the PARR-2 trial. *JACC Cardiovasc Imaging* 2009;2:1060-8.
  32. Abraham A, Nichol G, Williams KA, Guo A, deKemp RA, Garrard L, *et al.* 18F-FDG PET imaging of myocardial viability in an experienced center with access to 18F-FDG and integration with clinical management teams: The Ottawa-FIVE substudy of the PARR 2 trial. *J Nucl Med* 2010;51:567-74.
  33. Devereaux PJ, Yang H, Yusuf S, Guyatt G, Leslie K, Villar JC, *et al.* Effects of extended-release metoprolol succinate in patients undergoing non-cardiac surgery (POISE trial): A randomised controlled trial. *Lancet* 2008;371:1839-47.
  34. Palda VA, Detsky AS. Perioperative assessment and management of risk from coronary artery disease. *Ann Intern Med* 1997;127:313-28.
  35. Mukherjee D, Eagle KA. Perioperative cardiac assessment for noncardiac surgery: Eight steps to the best possible outcome. *Circulation* 2003;107:2771-4.
  36. Lee TH, Marcantonio ER, Mangione CM, Thomas EJ, Polanczyk CA, Cook EF, *et al.* Derivation and prospective validation of a simple index for prediction of cardiac risk of major noncardiac surgery. *Circulation* 1999;100:1043-9.
  37. Velasco A, Reyes E, Hage FG. Guidelines in review: Comparison of the 2014 ACC/AHA guidelines on perioperative cardiovascular evaluation and management of patients undergoing noncardiac surgery and the 2014 ESC/ESA guidelines on noncardiac surgery: Cardiovascular assessment and management. *J Nucl Cardiol* 2017;24:165-170.
  38. Lee CH, Yoon Y-H, Om SY, Kim M, Park H, Cho S-C, *et al.* Association of pre-operative myocardial perfusion imaging and revascularization with post-operative cardiac events in patients undergoing elective non-cardiac surgery. *JACC* 2017;70. Available from: [http://www.onlinejacc.org/content/70/18\\_Supplement/B308.1](http://www.onlinejacc.org/content/70/18_Supplement/B308.1). [Last accessed on 2019 Mar 27].
  39. Kircher M, Lapa C. Novel noninvasive nuclear medicine imaging techniques for cardiac inflammation. *Curr Cardiovasc Imaging Rep* 2017;10:6.
  40. Habib G, Lancellotti P, Antunes MJ, Bongiorni MG, Casalta JP, Del Zotti F, *et al.* 2015 ESC Guidelines for the management of infective endocarditis: The Task Force for the Management of Infective Endocarditis of the European Society of Cardiology (ESC). Endorsed by: European Association for Cardio-Thoracic Surgery (EACTS), the European Association of Nuclear Medicine (EANM). *Eur Heart J* 2015;36:3075-128.
  41. Joshi NV, Vesey AT, Williams MC, Shah AS, Calvert PA, Craighead FH, *et al.* 18F-fluoride positron emission tomography for identification of ruptured and high-risk coronary atherosclerotic plaques: A prospective clinical trial. *Lancet* 2014;383:705-13.
  42. Danve A, O'dell J. The role of 18F fluorodeoxyglucose positron emission tomography scanning in the diagnosis and management of systemic vasculitis. *Int J Rheum Dis* 2015;18:714-24.
  43. Schmidt WA, Blockmans D. Investigations in systemic vasculitis-The role of imaging. *Best Pract Res Clin Rheumatol* 2018;32:63-82.