

OPEN

Sciatic Nerve Palsy After Distal Femoral Traction for Vertically Unstable Pelvic Fracture in a Neurologically Intact Patient

Brenton G. Albracht, MD

Mark D. Jenkins, MD

From the Texas Tech University Health Science Center, Lubbock, Texas.

Correspondence to Dr. Albracht: brenton.albracht@ttuhsc.edu

Dr. Jenkins or an immediate family member serves as a paid consultant to and has received research or institutional support from DePuy. Neither Dr. Albracht nor any immediate family member has received anything of value from or has stock or stock options held in a commercial company or institution related directly or indirectly to the subject of this article.

JAAOS Glob Res Rev ;3:e045

DOI: 10.5435/JAAOSGlobal-D-19-00045

Copyright © 2019 The Authors. Published by Wolters Kluwer Health, Inc. on behalf of the American Academy of Orthopaedic Surgeons. This is an open access article distributed under the Creative Commons Attribution-NoDerivatives License 4.0 (CC BY-ND) which allows for redistribution, commercial and non-commercial, as long as it is passed along unchanged and in whole, with credit to the author.

Abstract

Vertically unstable fractures of the pelvis require a notable amount of energy to cause disruption of the posterior elements of the pelvic ring. Superior migration of the hemipelvis demonstrates the inherent instability of this fracture pattern. Surgical fixation is required in most cases, but while resuscitation efforts are underway, placing the patient in skeletal traction to reduce the hemipelvis is often recommended. Although skeletal traction has been described in many sources, no consensus exists on the amount of weight that should be used. This has led to anecdotal recommendations that vary between institutions. Without clear guidelines for treatment, a vertically translated hemipelvis was overreduced and subsequently sustained a sciatic nerve palsy in a patient who was neurologically intact on presentation. We aim to describe a rare complication of skeletal traction and propose a treatment algorithm to reduce the incidence of future complications.

The Tile classification has been used to describe the stability of pelvic ring injuries. Fractures with greater than 1 cm of displacement of the hemipelvis or fifth lumbar transverse process fractures are signs of vertical instability and are classified as Tile C fractures.¹ Pelvic ring injuries are also highly associated with sacral fractures. Sacral fractures are most commonly divided into zones and described by the Denis classification. These fractures historically have a rate of nerve root injury ranging from 5.9% with zone I fractures, 28.4% with zone II, and up to 56.7% with zone III injuries.² Although open reduction with inter-

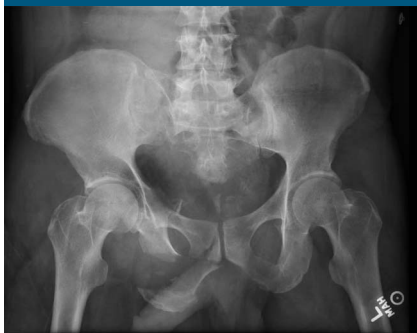nal fixation and external fixation are both standard treatment options, skeletal traction can be used for temporary stabilization of the posterior pelvis in a polytrauma patient. Use of skeletal traction has been described for many years of modern orthopaedics, but weight recommendations are either absent or vary widely among major articles and textbooks (Table 1).

Case

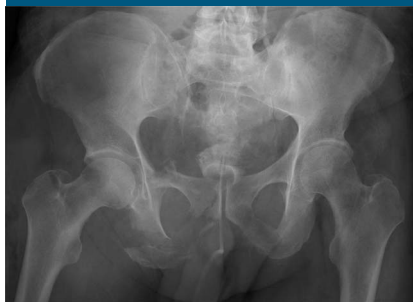A 56-year-old male construction worker was painting lines on a street when he was struck by a vehicle at

Table 1**Results of a literature review of weight recommendations for distal femoral skeletal traction for vertically unstable pelvic fractures.**

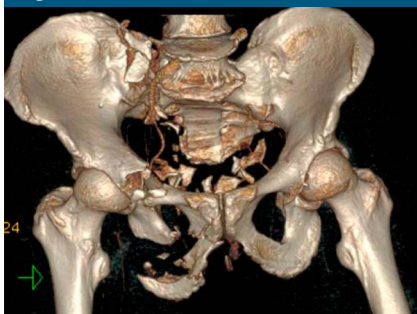
Year	Source	Weight Recommendation, kg (lbs)
1961	Sullivan; <i>Instructional Course Lectures</i> ³	9.1-13.6 (20-30)
1973	Holm; <i>CORR</i> ⁴	11.3-15.9 (25-35)
1988	Tile; <i>JBJS</i> ¹	20.0 (44.1)
1988	Webb, Caldwell; <i>South Med J</i> ⁵	No weight recommendations
1990	Burgess, et al; <i>JOT</i> ⁶	No weight recommendations
1996	Tile; <i>JAAOS</i> ⁷	13.6 (30)
1999	Tile; <i>JBJS</i> ⁸	No weight recommendations
2015 (8th ed.)	Rockwood and Green's <i>Fractures in Adults</i> ⁹	No weight recommendations
2015 (5th ed.)	<i>Skeletal Trauma</i> ¹⁰	11.3-15.9 (25-35)
2017 (13th ed.)	<i>Cambell's Operative Orthopaedics</i> ¹¹	No weight recommendations

Figure 1

AP pelvic radiograph demonstrating right hemipelvis superior migration.

Figure 3

AP pelvic radiograph following 18.1 kg of distal femoral skeletal traction. The radiograph demonstrates overreduction of the right hemipelvis.

Figure 2

3D CT reconstruction of comminuted vertically unstable pelvic fracture.

approximately 35 mph. Witnessed loss of consciousness was noticed. He was transferred to the local level 1 trauma center where he was evalu-

ated in the trauma bay. On initial evaluation, the patient was alert with a Glasgow Coma Scale of 15 and found to be hypotensive. The massive transfusion protocol was initiated. A primary survey of the patient revealed a 1 cm wound to the right buttock, and the patient had five out of five strength grading of all muscle groups of bilateral lower legs. He had no sensory deficits found on initial examination. An AP radiograph (Figure 1) of the pelvis showed right-sided hemipelvis translation with a comminuted right inferior rami fracture and associated high pubic root fracture. Cefazolin and gentamicin were given intravenously per institution protocol for open frac-

tures. Chest, abdominal, and pelvis CT (Figure 2) confirmed the finding of the plain radiograph of the pelvis and revealed a flexion-distraction (Chance fracture) injury to the T12 spinous process and L1 vertebral body. A type III aortic arch tear was also discovered. The patient was transferred to the surgical intensive care unit for critical management of his injuries. Owing to his open pelvis injury, thorough intraoperative irrigation and débridement of the buttock wound was planned, but because of his unstable spinal fractures, the patient was unable to be placed in the prone position without spinal stabilization. The patient's weight was 115 kg and 39.6 body mass index. To temporize the pelvic ring, distal supracondylar femoral traction was planned on the right extremity with 18.1 kg (40 lbs) of weight. Before traction placement, a detailed neurovascular examination was performed. Strong palpable pulses of the dorsalis pedis were found along with intact sensation to light touch throughout the right foot. The patient had full strength of his gastrocnemius and soleus complex as well as dorsiflexion with his tibialis anterior. Strength testing of the extensor hallucis longus and flexor hallucis longus was weak, but the patient was able to push against resistance.

After skeletal traction was placed, repeat radiographs of the pelvis including AP (Figure 3), inlet, outlet, and Judet views were obtained. The right hemipelvis appeared over-reduced, but the skeletal traction weight was not adjusted. Nursing staff notified the orthopaedic team that the patient had complete numbness and paralysis of the right foot approximately 4 hours after traction was placed. A physical examination confirmed the nurse's finding, and strong palpable pulses remained in the foot during this time. In an attempt to maintain reduction, but alleviate symptoms, the weight was decreased to 9.1 kg (20 lbs). Sensation of the right foot was re-evaluated, and the patient had minor sensation return throughout the foot, without a specific dermatomal distribution. Motor testing showed complete paralysis of the foot, except for a voluntary muscle twitch of the tibialis anterior. Skeletal traction was then discontinued.

The patient was taken to surgery later that day for open reduction and internal fixation of the anterior pelvic ring with a posterior percutaneous sacroiliac screw. The following day, his vertebral fractures were stabilized with posterior spinal fusion from T11 to L3. He was unable to be extubated for several weeks. After extubation, his neurovascular status of the right lower extremity did not change. He continued to have vague, nonspecific decrease in sensation and no motor activity below the right knee.

Multiple attempts were made to have the patient follow-up with our clinic, but he preferred his orthopaedic care closer in proximity to his

home. He is 1 year from his injury, and telephone contact only indicates that he has had continued foot problems. He has refused further contact from our clinic despite attempts to obtain outpatient clinic notes and electromyography results.

Summary

Many documented neurologic injuries are associated with vertically unstable pelvic ring and sacral fractures; however, sciatic nerve palsy after distal femoral traction in a patient who was neurovascularly intact at presentation could not be found in the literature. Several clinical scenarios could have been sole causes or contributing factors to his neurologic complication. These scenarios include but are not limited to: possible hematoma causing mass effect on the nerve, systemic hypotension, under resuscitation, or underlying spinal fractures. Although the patient's neurologic complication cannot definitively be attributed to the use of 18.1 kg of skeletal traction, it is the opinion of the authors that the complication could have been avoided by starting with a lighter amount of traction followed by a gradual increase in traction weight. Serial radiographs could have been used to evaluate the posterior ring reduction to use the lightest weight necessary to maintain adequate reduction. Owing to the complications of this case, the strategy stated above has become our department's protocol for skeletal traction used on vertically unstable fractures. A more detailed patient

follow-up would be preferred to help determine whether the complication was due to traction or another factor. The deficit is more likely to be a result of traction as opposed to his underlying spinal fracture because the neurologic injury was unilateral in nature and ipsilateral to the pelvic ring fractures.

References

1. Tile M: Pelvic ring fractures: Should they be fixed? *J Bone Joint Surg* 1988;70-B:1.
2. Denis F, Davis S, Comfort T: Sacral fractures: An important problem. *Clin Orthop Relat Res* 1988;227:67-81.
3. Sullivan C: Fractures of the pelvis. *Instructional Course Lectures* 1961: 92-101.
4. Holm C: Treatment of pelvic fractures and dislocations. Skeletal traction and the dual pelvic traction sling. *Clin Orthop Relat Res* 1973;97-107.
5. Webb LX, Caldwell K: Disruption of the posterior pelvic ring caused by vertical shear. *South Med J* 1988;81:1217-1221.
6. Burgess AR, Eastridge BJ, Young JW, et al: Pelvic ring disruptions: Effective classification system and treatment protocols. *J Trauma* 1990;30:848-856.
7. Tile M: Acute pelvic fractures: II. Principles of management. *J Am Acad Orthop Surg* 1996;4:152-161.
8. Tile M: The management of unstable injuries of the pelvic ring. *J Bone Joint Surg* 1999;81-B:941.
9. Court-Brown C, Heckman J, McQueen M, Ricci W, Tornetta P III: *Rockwood and Green's fractures in adults*, ed 8. Philadelphia, PA, Lippincott Williams & Wilkins, 2015.
10. Browner B, Jupiter J, Krettek C, Anderson P: Pelvic Ring injuries: Percutaneous posterior pelvic fixation, in: *Skeletal Trauma: Basic Science Management, and Reconstruction*. ed 5, Philadelphia, PA: Elsevier Saunders, 2015, pp 1021-1105.
11. Azar F, Beatty J, Canale ST: *Campbell's Operative Orthopaedics*, ed 13, Philadelphia, PA, Elsevier, 2017.