

OUTCOMES OF RETROPUPILLARY IRIS CLAW INTRAOCULAR LENS IMPLANTATION COMBINED WITH PARS PLANA VITRECTOMY

MARTA ZALESKI, MD, MARC STAHEL, MD, ROMAN EBERHARD, MD,
ROBERT ALEXANDER BLUM, MD, DANIEL BARTHELMES, MD, PhD

Purpose: To report 12-month visual outcomes, incidence of intraocular pressure (IOP) changes and postoperative complications after pars plana vitrectomy with retropupillary implantation of an iris claw intraocular lens (IOL) in aphakic eyes after complicated cataract surgery and eyes with a dislocation of the IOL.

Methods: This is a retrospective analysis of eyes undergoing implantation of an iris claw IOL combined with pars plana vitrectomy from 1st of January 2009 until 30th of June 2018 after complicated cataract extraction with capsular loss (Group A) or dislocation of an IOL (Group B). Corrected distance visual acuity was analyzed in logarithm of the minimum angle of resolution (logMAR) units, IOP was recorded in mmHg.

Results: Eyes in Group A ($n = 49$) improved from a preoperative median visual acuity of 0.523 logMAR (Snellen 20/65) to 0.201 logMAR (Snellen 20/30), $P < 0.01$. Eyes in Group B ($n = 126$) showed stable median visual acuity, preoperative 0.301 logMAR (Snellen 20/40) versus postoperative 0.222 logMAR (Snellen 20/30), $P > 0.05$. During 12 months in Group A, IOP >21 mmHg occurred in 9 (18.4%) eyes; no eye had an IOP <6 mmHg. In Group B, IOP >21 mmHg occurred in 15 (11.9%) eyes, IOP <6 mmHg in 5 (4%) cases. None of the eyes in Group A and B had IOP >21 mmHg or <6 mmHg at 12 months follow-up.

Conclusion: The retropupillary implantation of an iris claw IOL with pars plana vitrectomy provides adequate visual rehabilitation and seems to be safe in IOP changes.

RETINA 42:1284–1291, 2022

Cataract surgery is the most common surgical procedure in Europe¹ and one of the most common surgeries in economically developed countries.² About four million cataract operations are performed annually within the European Union¹ and a similar number in the United States,³ totaling nearly eight Million surgeries per year in these two parts of the world only.

From the Department of Ophthalmology, University Hospital and University of Zurich, Zurich, Switzerland.

None of the authors has any financial/conflicting interests to disclose.

This is an open access article distributed under the terms of the Creative Commons Attribution-Non Commercial-No Derivatives License 4.0 (CCBY-NC-ND), where it is permissible to download and share the work provided it is properly cited. The work cannot be changed in any way or used commercially without permission from the journal.

Reprint requests: Daniel Barthelmes, MD, PhD, Department of Ophthalmology, University Hospital of Zurich, Frauenklinikstr 24, 8091 Zurich, Switzerland; e-mail: daniel.barthelmes@usz.ch

In most cases, cataract surgery is very successful and patient satisfaction is generally high.⁴ As with every surgical procedure, several complications can occur. Short-term or immediate complications that may occur during surgery, are capsular tears or loss of capsular support, preventing the implantation of an intraocular lens (IOL) at the time of the surgery, leaving the patient's eye aphakic.⁵ Long-term, instability of zonular fibers may occur, leading to dislocation of the implanted IOL with the possibility of a complete dislocation into the vitreous cavity.

Secondary IOL implantation can be challenging, owing to the already altered anatomical situation as a result of previous intraocular surgery. There are several surgical methods for treating aphakia without capsular support, among them: placement of trans-scleral sutured IOLs,^{6,7} a glued IOL technique,^{8,9} angle supported, sulcus,¹⁰ or iridal fixation.^{5,11,12}

These implantation methods have been associated with a varying degree of complications including corneal edema, cystoid macular edema (CME), glaucoma, IOL instability, lens decentration, pupil distortion, and retinal detachment (RD) and conjunctival erosion by transscleral sutures with associated endophthalmitis risk for sclerally sutured lens implantation.^{5,6,11–14} All these complications can significantly affect visual performance, some leading to blindness.

A well-established approach for the treatment of aphakia is the implantation of an iris claw IOL.^{5,12} The IOL, fixed to the mid-peripheral iris, does not interfere with the normal iris vasculature and does not cause mydriasis or affect angle structures.¹¹ In cases where the lens is not fixed in the periphery, but rather close to the pupil margin or close to the peripheral iris, a distortion of the normally round shape of the pupil may result. A modern version of the original lens developed by Worst et al in 1972¹² is known as Artisan (Ophtec BV, Europe) or Verisyse (Abbott Medical Optics, Inc, Santa Ana, CA).

In cases of phakic iris claw lens implantations for refractive errors, fixed to the anterior surface of the iris, several reports showed continuous destructive impact on corneal endothelium.^{15,16} Because of the damage to the corneal endothelium, most surgeons switched to a retropupillary fixation. Reports suggest that it is safer for the corneal endothelium.¹⁴

We report outcomes of eyes undergoing vitrectomy and retropupillary fixated Artisan IOL in cases of aphakia after complicated cataract surgery or dislocation of an IOL into the vitreous cavity.

Materials and Methods

Study Design and Setting

This is a retrospective cohort study of eyes undergoing combined pars plana vitrectomy (PPV) and retropupillary iris claw lens implantation. Data were retrieved from patient records of the Department of Ophthalmology at the University Hospital Zurich, and from private ophthalmology practices in the region.

Visual acuity and IOP (preoperative, 1 month/3 months/6 months and 12 months postoperatively) and presence of CME and RD were recorded. Corrected distance visual acuity was tested using Snellen charts or the logarithm of the minimum angle of resolution (logMAR) chart. For statistical analysis, all visual acuity readings were converted to logMAR. The IOP was measured in mmHg using Goldman applanation tonometry or air tonometry. We also obtained data on the incidence of CME, RD, vitreous hemorrhage, iris claw IOL dislocation, and corneal decompensation.

The study was conducted in compliance with the current version of the tenets of the Declaration of Helsinki and all national legal and regulatory requirements, the study protocol was approved by the human ethics committee of the canton of Zurich, Switzerland.

Study Population

We included eyes of patients aged 18 years and older who underwent a retropupillary implantation of the iris claw Artisan IOL combined with PPV between January 1, 2009 and June 30, 2018 at the Department of Ophthalmology at University Hospital Zurich. All patients gave informed consent for participation (Figure 1). The indications were previous complicated cataract surgery with posterior capsular rent or capsular loss (Group A) or dislocation of a previously implanted IOL (Group B).

Surgical Technique

The iris claw Artisan (Ophtec BV, Groningen, The Netherlands) is a single-piece nonfoldable IOL made of Perspex CQ-UV, a polymethyl methacrylate filtering UV-light. Our patients received the biconvex aphakia model 205 with a 5.0 mm optic and 8.5 mm total length. The calculations of optic power were made using SRK/T formula, aiming emmetropia in most cases. The A-constant used for estimation was 116.9 for retropupillary implantation following the Manufacturer's recommendations. The procedures were conducted under general or regional anesthesia. The 23-gauge trocars were placed in an inferotemporally, superotemporally, and superonasally. This was followed by removal of core and peripheral vitrectomy. Care was taken to detach the posterior vitreous cortex from the retina if still attached. Peripheral retinal pathologies were treated with laser retinopexy. After creating a superior conjunctival opening, a sclerocorneal tunnel 4 mm behind the limbus was created and the anterior chamber was opened, followed by two side ports. In Group B, the IOL was removed through the sclerocorneal tunnel using forceps. Miosis was achieved through the injection of acetylcholine chloride into the anterior chamber. The Artisan IOL was inserted upside-down into the anterior chamber. When finally placed retropupillary, this upside-down position allows for adequate flow of aqueous humor through the pupil and avoids a pupillary block that may otherwise occur because of the slightly curved geometry of the Artisan lens. After insertion into the anterior chamber, the IOL was rotated to place the haptics in a 3 and 9 o'clock position using a Sinskey hook introduced via a side port. After correct placement, the IOL was held with a forceps and one side of the haptic part of the

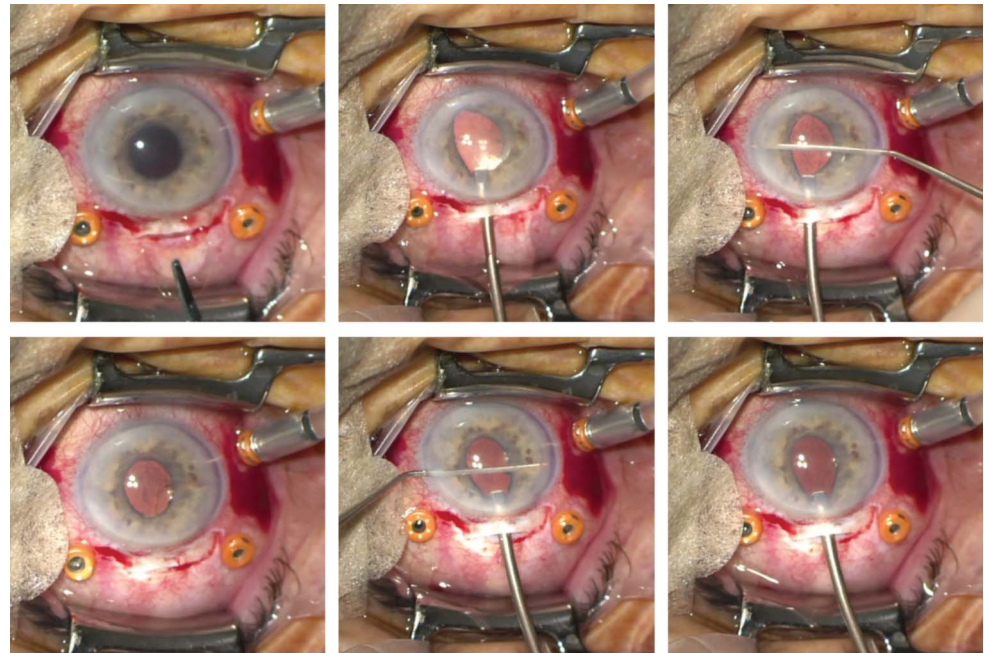


Fig. 1. Study population and recruitment flowchart.

IOL moved retro pupillary, whereas the other haptic part remained prepupillary, thus avoiding a loss of the IOL into the vitreous cavity in case the grip on the IOL with the forceps is lost. The enclavation was performed by pushing the iris tissue just above the haptic through the opening of the haptic using a straight iris spatula while still holding the IOL with a forceps. Once well-fixed on one side, the process was then repeated for the other haptic (Figure 2). In most cases, the tunnel was closed with a single 10 to 0 Nylon cross-suture. The conjunctival openings and scleromies were closed with 8 to 0 Vicryl sutures. In select cases (e.g., posttrabeculectomy or scarred superior sclera) the Artisan IOL was implanted through a temporal incision and fixated to the iris in a vertical or oblique orientation. No iridectomy was performed. Finally, cefazolin and dexamethasone were injected subconjunctivally and an ointment eye dressing with tobramycin and dexamethasone was placed. Intraoperatively, methylprednisolone and acetazolamide were administered intravenously. Postoperatively, all patients received topical antibiotics and steroids for 4 weeks, in combination with oral steroids for 9 days. In case of a postoperative CME, a therapy of prednisolone acetate 1% and nepafenac 1% eyedrops, both four times daily, was started. Upon resolution of the CME, the local therapy was tapered off.

Data and Outcome Measures

The primary outcome was visual acuity at 12 months, postoperatively. The secondary outcome was

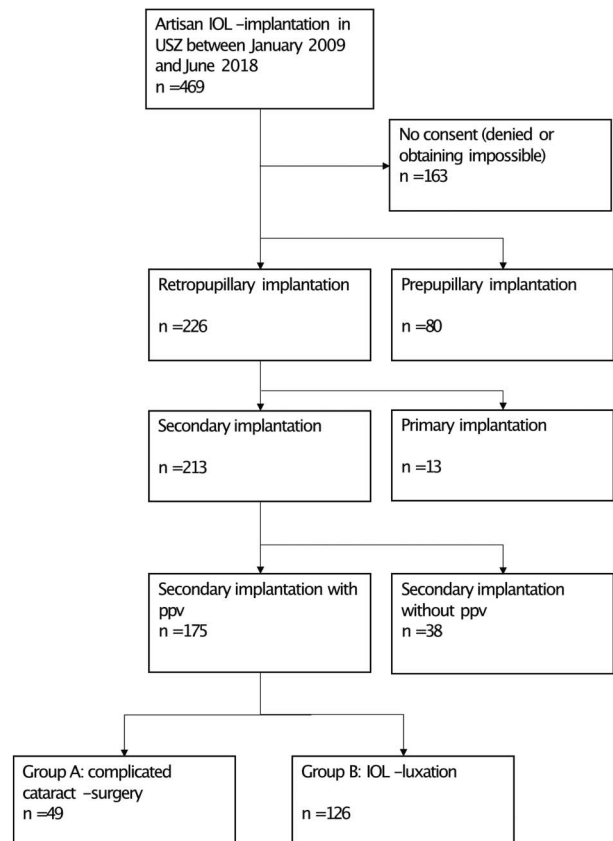


Fig. 2. Retropupillary Artisan IOL implantation: (clockwise from upper left) 1. Insertion of the Artisan lens upside down through a sclerocorneal tunnel; 2. Positioning of the nasal part of the lens retroiridally through the pupil and 3. Retroiridal enclavation of the haptics; 4. and 5. Analogous maneuver on the contralateral side; 6. A well-centered Artisan IOL enclavated retro pupillary.

a complication rate during the 12 months follow-up period, including intraocular pressure (IOP) increase >21 mmHg or decrease <6 mmHg, the incidence of CME, and the incidence of RD.

Statistical Analysis

Statistical calculations were performed using commercially available software packages (MS Excel v16.0, IBM SPSS Statistics v25.0, R v3.6.1). Data are presented as a median and interquartile range (IQR) for nonnormal distribution and as mean and SD for normal distribution. Locally estimated scatterplot smoothing regression curve¹⁷ was used to present visual outcome data. Nonparametric Wilcoxon test was used to analyze changes between preoperative and postoperative quantitative values. Mann-Whitney *U* test was used to determine differences between variables in relation to diverse dichotomous characteristics. Pearson bivariate correlation was proved for the relationships between nonnormally distributed data. Statistical significance was defined as $P < 0.05$, two-sided.

Results

There were 175 eyes of 163 patients who underwent a retropupillary implantation of the iris claw Artisan IOL combined with PPV between January 1, 2009 until June 30, 2018 (Figure 2). In Group A ($n = 49$), the indication for the surgery was aphakia after complicated cataract surgery with capsular loss, with a median time interval between cataract surgery and Artisan implantation of 11 days (IQR 3–46 days). In Group B ($n = 126$), the indication for the surgery was a dislocation of a previously implanted IOL. Mean (95% CI) patient age was 72 (69–76) years in Group A and 77 (75–79) years in Group B. There were 45% female eyes in Group A and 44% in Group B.

Primary Outcome

In aphakic eyes after complicated cataract surgery (Group A) median (IQR) visual acuity improved from 0.523 logMAR (counting fingers—0.301; Snellen 20/65 [counting fingers to 20/40]) to 0.201 logMAR (0.222–0.046; Snellen 20/30 [20/30–20/20]; $P < 0.05$). In eyes with a dislocated IOL, median (IQR) visual acuity was at baseline 0.301 logMAR (0.699–0.097; Snellen 20/65 [20/100–20/25]) slightly increased to 0.222 logMAR (0.523–0.011; Snellen 20/30 [20/65–20/20]; $P = 0.1$). Visual acuity changes over time for the Groups A and B are presented as a locally estimated scatterplot smoothing curve (Figure 3).

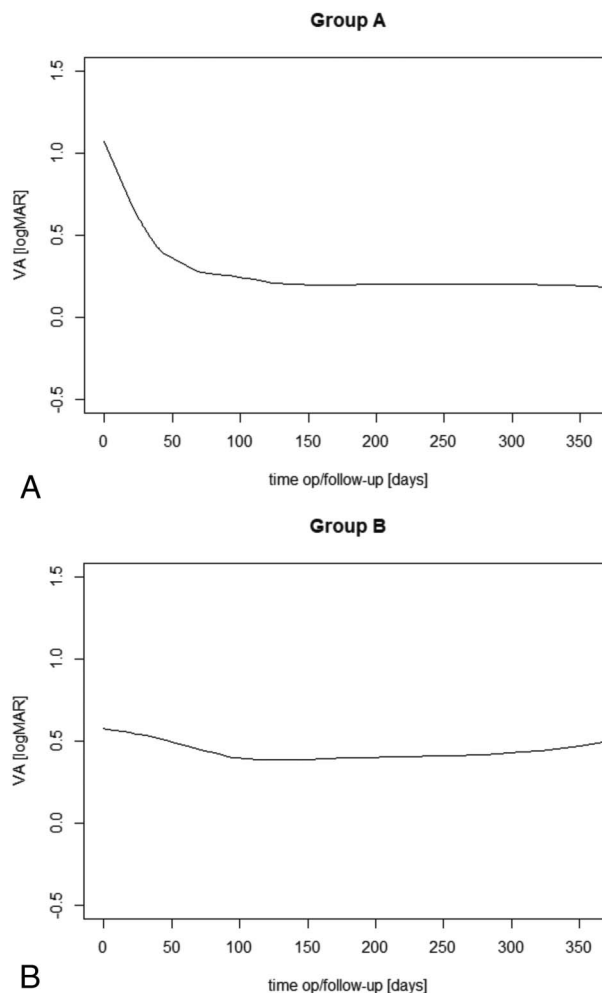


Fig. 3. Locally estimated scatterplot smoothing curve¹⁷ for visual outcome in Group A (above) and B (below) during 12 months post-operatively.

Preoperatively, 76.7% of eyes in Group A and 47% in Group B had visual acuity of less than 20/40. In the first follow-up month, 44.4% of eyes from Group A and 54.7% from Group B achieved visual acuity of at least 20/40. At 12-month follow-up, 85.2% of eyes in Group A and 60.3% in Group B achieved visual acuity of at least 20/40.

After 12 months follow-up, at least 49% of eyes from Group A and at least 35% from Group B reached or exceeded their baseline visual acuity. Only 4% of eyes in Group A and 15% in Group B performed worse than preoperatively. In patients from Group A, there was no correlation between visual outcome and time interval between complicated cataract surgery and Artisan IOL implantation ($r = 0.099$, $P = 0.637$).

Secondary Outcomes

At baseline, the median (IQR) IOP (mmHg) was 17.7 (14–21.2) in Group A and 16 (13–19) in Group

B. At 12 months postoperatively, IOP was 15 (12–17) and 14 (12–16) for Groups A and B, respectively. Postoperative IOP increase defined as at least one IOP measurement > 21 mmHg occurred in 9 (18.4%) eyes from Group A and 15 (11.9%) eyes from Group B. Most cases were observed on the first month follow-up visit, with a median time for Group A being 36 days (31–111), for Group B 33 days (31–142). There were no cases of postoperative hypotension defined as at least one IOP measurement < 6 mmHg in Group A and 5 (4%) cases in Group B with a median occurrence time point of 88 (46–198) postoperative days. At 12 months, none of the eyes in Group A or B had IOP measurements of > 21 or < 6 mmHg.

There were 7 (14.3%) eyes in Group A and 9 (7.1%) in Group B, which developed CME during the 12 months follow-up time. A median time interval between Artisan lens implantation and the diagnosis was 93 (IQR 51–135) days in Group A and 173 (104–241) days in Group B. In 5 of 7 eyes of Group A and in four of 9 eyes in Group B, CME was resolved at the 12-month follow-up visit.

RD during the 12 months follow-up period was diagnosed in 5 (4%) eyes in Group B with a median time interval between the implantation and the diagnosis of 10 (5–185) days. This complication did not occur in Group A.

Other complications included vitreous hemorrhage (Group A: $n = 1$, 2.04%; Group B: $n = 1$, 0.79%), Artisan lens dislocation (Group A $n = 0$; Group B: $n = 2$; 1.59%), and corneal decompensation (Group A: $n = 0$; Group B: $n = 1$, 0.79%). The latter has been observed in an eye with preexistent bullous keratopathy.

Discussion

This retrospective analysis of eyes undergoing implantation of an iris claw IOL combined with PPV after complicated cataract extraction with capsular loss or dislocation of an IOL shows benefits regarding the visual outcome up to 12 months. Aphakic patients achieved a good visual acuity, which remained stable during the 12-month follow-up time. Patients with IOL exchange returned to their best visual acuity rapidly and retained good visual acuity during the follow-up period. During the 12-month follow-up period, there were very few cases of IOP increase > 21 mmHg or decrease < 6 mmHg in previously normotensive eyes from both study subgroups, and none of these normotensive eyes had IOP > 21 mmHg or < 6 mmHg at the end of the 12 months follow-up period.

Visual Acuity

In eyes that underwent complicated cataract surgery (Group A), there was a remarkable improvement in visual acuity during the first follow-up month, that was maintained until the end of the 12-month follow-up period, where over 85% of patients achieved very good visual acuity (20/40 or better). In Group B, the visual acuity did not significantly increase within the follow-up period, but showed a slight tendency toward improvement.

All eyes included in our study received PPV in addition to the IOL implantation as part of a planned procedure. Pars plana vitrectomy was performed to remove small lens fragments or the dislocated IOL. The number of studies in which the retropupillary iris claw implantation was combined with PPV is limited. A report by Labeille et al¹⁸ published in 2014, presents visual acuity outcomes after the 12-month follow-up of 0.53 ± 0.84 logMAR (Snellen $\sim 20/65$). It is however difficult to compare the current visual acuity outcomes with the findings from Labeille et al, owing to the differences in number of eyes, study groups, follow-up time, and differences in vitrectomy technique. Other studies on retropupillary implantation combined with pars plana vitrectomy report visual outcomes of 0.3–0.64 logMAR (Snellen 20/40–20/85).¹²

In the present study, 85.2% of eyes in Group A and 60.3% of eyes in Group B achieved visual acuity of at least 20/40. It is comparable (73%.6%),¹⁹ and potentially superior (45%.3%)^{5,20,21} to outcomes of prepupillary implantation in similar conditions. Notably, other authors excluded high-risk patients, e.g., with preexistent glaucoma, uveitis, history of RD, or diabetic retinopathy. In our study, coexisting ocular pathologies, mostly glaucoma (Group A 49%, Group B 40%), diabetic retinopathy (Group A 11%, Group B 12%), and retinal pathologies such as an epiretinal membrane or RD history (Group A 12%, Group B 11%) were frequent. Our visual outcome of retropupillary iris claw IOL are better than reported in other implantation methods in the absence of capsular support, including transscleral glued anterior chamber IOL,⁹ iris-sutured IOL,²² and sulcus sutured IOL.^{22,23} It is comparable to visual outcomes described for transscleral sutured IOL^{6,23} and open-loop anterior chamber IOL.²²

Important factors that have an impact on the visual acuity outcome in patients after complicated cataract surgery are timing of the secondary implantation, comorbidities, and surgical technique. Regarding timing, according to the literature, the best visual acuity can be obtained in a two-step approach with a small time interval between complicated cataract surgery and PPV.²⁴

The surgical technique also has an impact on visual acuity. It was reported that 23-gauge vitrectomy causes less inflammation and a lower rate of iatrogenic tears than 20 gauge.²⁵ In addition, the procedure of PPV allows for meticulous cleaning of the vitreous base, detection and removal of small lens fragments, and treatment of retinal tears. This approach may explain the low incidence of CME and the relatively low incidence of RD. The latter was observed only after IOL exchange. It may be hypothesized that vitreous base shaving and identification of small retinal breaks was performed more meticulously after complicated cataract surgery, potentially explaining the difference in the two groups.

The Artisan aphakia iris claw IOL, currently being introduced (Phase 3) for the FDA approval, was originally designed for prepupillary implantation. However, according to studies published to this day, the method, although successful in visual acuity outcomes, has a detrimental effect on the corneal endothelial cell count (ECC).^{11,19,26} Hence, the need for finding a safer but equally effective alternative. Several studies have reported mild corneal endothelial cell loss with retropupillary placement of the Artisan aphakia lens^{12–14,27}; this is comparable with the endothelial cell loss after phacoemulsification,²⁸ likely because of respecting the anterior chamber anatomy, which has been shown in postoperative anterior segment imaging.²⁷ Because no data on ECC were collected in this study, we cannot compare retropupillary and prepupillary implantation method in this context; moreover, the follow-up time of 12 months may be too short to observe large differences and long-term effects. However, given the excellent visual acuity outcomes at 12 months, it seems unlikely that the retropupillary approach induces a significant change in ECC, and based on individual long-term observations with good visual acuity up to 5 years, significant damage to the corneal endothelium is unlikely. Further studies are planned to address this issue.

Intraocular Pressure

Some authors indicate that the incidence of pupillary block or IOP elevation is significantly higher in the case of prepupillary implantation compared with retropupillary implantation of the Artisan aphakia lens.²⁶ In our study, a postoperative IOP decompensation due to a pupillary block was not observed, probably because of the removal of the vitreous, especially the anterior hyaloid, so that a free flow of aqueous humor between posterior and anterior segment was established. No iridectomies were performed. At the 12-month follow-up, elevated IOP (>21 mmHg) was

seen in 2 (4%.1%) eyes in Group A and 2 (1%.6%) eyes in Group B, which is comparable with^{12,13,20} or better^{14,21,26} than other studies on retropupillary Artisan IOL implantation. In these four cases, there was a preoperative IOP elevation diagnosed before the surgery. In the available literature, there were reports on the negative influence of preexistent glaucoma on visual outcome after cataract surgery.²⁹ In our study, the patients with preexistent glaucoma did not present statistically significant differences in visual acuity compared with other patients ($P = 0.261$). A separate analysis of IOP changes in glaucoma patients during the follow-up period showed that postoperatively, IOP could be well controlled, similarly to the study population as a whole. Therefore, the retropupillary procedure itself does not lead to IOP elevation and can be safely used in patients with preexistent glaucoma or IOP elevation. Of course, there were some IOP elevations 1 month postoperatively, independent of preexistent IOP problems (2 eyes in Group A and four eyes in Group B). This may be explained by a response to inflammation and corticosteroid treatment in the 4-week postoperative period as suggested in some other studies,^{5,16,21} and preexisting pseudoexfoliation (PEX) observed in many individuals with IOL luxation. All these eyes returned to normal IOP during the 12-month follow-up and eventually did not need long-term antihypertensive therapy.

Regarding postoperative intraocular hypotension, the 3 (2%.4%) eyes from Group B which developed this complication, had additional risk factors. Two of the three eyes were previously treated with glaucoma medication. During the first postoperative week and first month, a hyphema with RD was observed in both cases. In the third case, hyphema occurred perioperatively and, 3 days after implantation, the Artisan lens dislocated and had to be reencavated. These findings correspond with another study reporting cases of postoperative hypotony associated with bleeding or a lens dislocation after retropupillary Artisan implantation, and 1 self-limited case of hypotony in a study regarding retropupillary Artisan lens implantation in cases of aphakia.²¹ The hypotony cases in our cohort were iatrogenic because of antihypertensive treatment or in association with an uneventful follow-up and were not directly connected with the Artisan IOL implantation itself.

There are very few reports on retropupillary Artisan IOL implantation in relation to pigment dispersion and the occurrence of the phenomenon after the procedure. Forlini et al¹³ with variable follow-up time reaching 8 years, described some pigment dispersion cases with follow-up upto 8 years. Baykara et al³⁰ described pigment erosion due to the posterior iris fixation of the

Artisan IOL. It is well established that pigment can alter the physiological function of trabecular meshwork by blocking aqueous outflow and causing ocular hypertension. Güell et al, however, did not find a specific link between these pigment dispersion and IOP problems, postoperatively. However, they did not recommend iris claw IOL implantation in patients with PEX or pigment dispersion syndrome.⁵ At the time of writing, to the best of our knowledge, there are no studies focused on systematically documenting pigment dispersion over a long postoperative period and differentiating the etiology between secondary to trauma at the time of surgery or secondary to chronic abrasion of the posterior face of the iris by the IOL.

The incidence of PEX in our population was relatively high in both groups (Group A: 30.6%, Group B: 36.5%). Among patients with IOP decompensation in our study, PEX was present in 44.4% of Group A and 26.7% of Group B. The higher percentage of IOP decompensation in Group A, was likely due to inflammation and steroid therapy following complicated cataract surgery. Based on our study, retropupillary Artisan iris claw IOL lens implantation with PPV in eyes with PEX syndrome is a reasonable treatment option.

Complications

In our study, there were 7 (14.3%) eyes in Group A and 9 (7.1%) eyes in Group B in which CME was diagnosed postoperatively. The mechanism of CME development in this fixation method could be irritation of the iris by the IOL haptics during enclavation. The findings are comparable to the outcome in similarly designed studies (7.9%–25%)^{20,21} for retropupillary implantation of the Artisan Aphakia iris claw lens, although one author reported the incidence of CME in retropupillary Artisan implantation of 0.3% in patients with IOL luxation as an indication to the procedure. The percentage of eyes affected in Group A was greater than in Group B, which is not surprising, because the residual lens matter in postcomplicated cataract eyes constituted an additional risk factor for CME in these eyes. Among patients with other risk factors in which CME occurred as a complication, one suffered from central retinal vein occlusion postoperatively, two were preoperatively treated with prostaglandin derivatives, two had coexistent epiretinal fibroplasia, and one had preexistent AMD. Eyes with uveitis did not develop CME postoperatively. The incidence of CME in prepupillary implantation of the iris claw Artisan Aphakia IOL vary from 3.12% to 33%.^{5,20,21}

In five patients (2.3%), RD was observed postoperatively. All patients were operated for complete luxation of a previously implanted IOL. The patients

received miotics postoperatively. There was a history of previous glaucoma surgery (1 eye), RD (1 eye), and retinal hemorrhage (1 eye) before the Artisan lens implantation. In one case, anterior chamber hemorrhage occurred postoperatively. In other studies, the incidence of this complication following retropupillary iris claw implantation is reported between 0.3% and 3% of cases.^{13,20,21}

A later dislocation of retropupillary fixated iris claw lens occurs less frequently compared with other lens implantation methods, as described in the literature.³¹ During the study period we noted two eyes (1.1%), both in Group B, which required reenclavation. The incidence is similarly low in other studies (0%–0.9%).^{13,18,20}

Strengths and Weaknesses

The strength of this study may be the large number of eyes treated, relatively long follow-up time, and good quality of available documentation. However, there is no control group and no information on ECC. Another weakness is the retrospective nature of the study resulting in irregular examination intervals following surgery. Direct comparison with other surgical methods for treating aphakia without capsular support is difficult because of differences in study populations, surgical technique, timing of surgery, and pharmacological treatment.

Summary and Conclusions

In both study groups, patients who presented with poor preoperative visual acuity achieved equally good visual acuity at the end of the follow-up period as did patients with good baseline visual acuity.

Based on visual acuity, OP outcomes, and potential side effects, we conclude that in cases of aphakia, after complicated cataract surgery or IOL dislocation, retropupillary implantation of the Artisan IOL combined with PPV is a safe and viable surgical approach. Further research is needed to verify whether the retropupillary implantation is superior prepupillary in maintaining the ECC and regarding long-term outcomes.

Key words: iris claw IOL, cataract surgery, secondary aphakia, pars plana vitrectomy, visual acuity.

References

1. Surgical Operations and Procedures Statistics. eurostat, 2016. Available at: https://ec.europa.eu/eurostat/statistics-explained/index.php?title=Surgical_operations_and_procedures_statistics.
2. Wang W, Yan W, Fotis K, et al Cataract surgical rate and socioeconomics: a global study. Invest Ophthalmol Vis Sci 2016;57:5872–5881.

3. Wang SY, Stem MS, Oren G, et al Patient-centered and visual quality outcomes of premium cataract surgery: a systematic review. *Eur J Ophthalmol* 2017;27:387–401.
4. Brown GC, Brown MM, Menezes A, et al Cataract surgery cost utility revisited in 2012: a new economic paradigm. *Ophthalmology* 2013;120:2367–2376.
5. Güell JL, Verdaguer P, Elies D, et al Secondary iris-claw anterior chamber lens implantation in patients with aphakia without capsular support. *Br J Ophthalmol* 2014;98:658–663.
6. Hara S, Borkenstein AF, Ehmer A, Auffarth GU. Retropupillary fixation of iris-claw intraocular lens versus transscleral suturing fixation for aphakic eyes without capsular support. *J Refract Surg* 2011;27:729–735.
7. Kokame GT, Yanagihara RT, Shantha JG, Kaneko KN. Long-term outcome of pars plana vitrectomy and sutured scleral-fixated posterior chamber intraocular lens implantation or repositioning. *Am J Ophthalmol* 2018;189:10–16.
8. Kang JJ, Ritterband DC, Toles SS, Seedor JA. Outcomes of glued foldable intraocular lens implantation in eyes with pre-existing complications and combined surgical procedures. *J Cataract Refract Surg* 2015;41:1839–1844.
9. Kumar DA, Agarwal A, Jacob S, Agarwal A. Glued transscleral intraocular lens exchange for anterior chamber lenses in complicated eyes: analysis of indications and results. *Am J Ophthalmol* 2013;156:1125–1133.e2.
10. Menezo JL, Martinez MC, Cisneros AL. Iris-fixated Worst claw versus sulcus-fixated posterior chamber lenses in the absence of capsular support. *J Cataract Refract Surg* 1996;22:1476–1484.
11. Güell JL, Velasco F, Malecaze F, et al Secondary Artisan-Verysise aphakic lens implantation. *J Cataract Refract Surg* 2005;31:2266–2271.
12. Schallenberg M, Dekowski D, Hahn A, et al Aphakia correction with retropupillary fixated iris-claw lens (Artisan)—long-term results. *Clin Ophthalmol* 2014;8:137–141.
13. Forlini M, Soliman W, Bratu A, et al Long-term follow-up of retropupillary iris-claw intraocular lens implantation: a retrospective analysis. *BMC Ophthalmol* 2015;15:143.
14. Gonnermann J, Amiri S, Klamann M, et al [Endothelial cell loss after retropupillary iris-claw intraocular lens implantation]. *Klin Monbl Augenheilkd* 2014;231:784–787.
15. Jonker SMR, Berendschot TTJM, Ronden AE, et al Long-term endothelial cell loss in patients with artisan myopia and artisan toric phakic intraocular lenses: 5- and 10-year results. *Ophthalmology* 2018;125:486–494.
16. Menezo JL, Cisneros AL, Rodriguez-Salvador V. Endothelial study of iris-claw phakic lens: four year follow-up. *J Cataract Refract Surg* 1998;24:1039–1049.
17. Austin PC, Steyerberg EW. Graphical assessment of internal and external calibration of logistic regression models by using loess smoothers. *Stat Med* 2014;33:517–535.
18. Labeille E, Burillon C, Cornut PL. Pars plana vitrectomy combined with iris-claw intraocular lens implantation for lens nucleus and intraocular lens dislocation. *J Cataract Refract Surg* 2014;40:1488–1497.
19. Chen Y, Liu Q, Xue C, et al Three-year follow-up of secondary anterior iris fixation of an aphakic intraocular lens to correct aphakia. *J Cataract Refract Surg* 2012;38:1595–1601.
20. Mora P, Calzetti G, Favilla S, et al Comparative analysis of the safety and functional outcomes of anterior versus retropupillary iris-claw IOL fixation. *J Ophthalmol* 2018;2018:8463569.
21. Tourino Peralba R, Lamas-Francis D, Sarandeses-Diez T, et al Iris-claw intraocular lens for aphakia: can location influence the final outcomes?. *J Cataract Refract Surg* 2018;44:818–826.
22. Wagoner MD, Cox TA, Ariyasu RG, et al Intraocular lens implantation in the absence of capsular support: a report by the American Academy of Ophthalmology. *Ophthalmology* 2003;110:840–859.
23. Vounotrypdis E, Schuster I, Mackert MJ, et al Secondary intraocular lens implantation: a large retrospective analysis. *Graefes Arch Clin Exp Ophthalmol* 2019;257:125–134.
24. Vanner EA, Stewart MW. Vitrectomy timing for retained lens fragments after surgery for age-related cataracts: a systematic review and meta-analysis. *Am J Ophthalmol* 2011;152:345–357.e3.
25. Misra A, Ho-Yen G, Burton RL. 23-gauge sutureless vitrectomy and 20-gauge vitrectomy: a case series comparison. *Eye (Lond)* 2009;23:1187–1191.
26. Gonnermann J, Klamann MK, Maier AK, et al Visual outcome and complications after posterior iris-claw aphakic intraocular lens implantation. *J Cataract Refract Surg* 2012;38:2139–2143.
27. Gicquel JJ, Langman ME, Dua HS. Iris claw lenses in aphakia. *Br J Ophthalmol* 2009;93:1273–1275.
28. Kodjikian L, Beby F, Spire M, et al Combined pars plana phacofragmentation, vitrectomy, and Artisan lens implantation for traumatic subluxated cataracts. *Retina* 2006;26:909–916.
29. Kugelberg M, Lundström M. Factors related to the degree of success in achieving target refraction in cataract surgery: swedish National Cataract Register study. *J Cataract Refract Surg* 2008;34:1935–1939.
30. Baykara M, Ozcetin H, Yilmaz S, Timuçin OB. Posterior iris fixation of the iris-claw intraocular lens implantation through a scleral tunnel incision. *Am J Ophthalmol* 2007;144:586–591.
31. Davies EC, Pineda R II. Intraocular lens exchange surgery at a tertiary referral center: indications, complications, and visual outcomes. *J Cataract Refract Surg* 2016;42:1262–1267.