



ELSEVIER

Contents lists available at [ScienceDirect](https://www.sciencedirect.com)

Respiratory Medicine Case Reports

journal homepage: www.elsevier.com/locate/rmcr

Case report

Recurrent Silicone Embolism Syndrome requiring VA ECMO

Nikhil Madan^{a,*}, Umair Khan^e, Anthony Martins^f, Gabriela Andries^c,
John Matthews^b, Vipul Patel^d, Gautam Visveswaran^c^a Division of Pulmonary and Critical Care Medicine, Department of Medicine, Newark Beth Israel Medical Center, Newark, NJ, 07112, USA^b Department of Neuroradiology, Newark Beth Israel Medical Center, Newark, NJ, 07112, USA^c Division of Cardiology, Department of Medicine, Newark Beth Israel Medical Center, Newark, NJ, 07112, USA^d Division of Lung Transplant, Department of Medicine, University of Maryland, Baltimore, MD, USA^e Department of Medicine, Newark Beth Israel Medical Center, Newark, NJ, 07112, USA^f St George Univeristy Medical School, Great River NY, 11739, USA

ARTICLE INFO

MeSH keywords:

Silicone embolism syndrome

ECMO

Case report

ABSTRACT

The illegal use of liquid silicone in injectable procedures has been on the rise for the last few years. While originally thought to be an inert material, today, silicone is associated with several inflammatory complications-including Silicone Embolism Syndrome (SES). SES is the most dreaded complication of unlicensed liquid silicone injections. It is characterized by pneumonitis, diffuse alveolar and silicone pulmonary emboli leading to acute respiratory distress syndrome and cardiopulmonary failure. We present a case of a patient who was diagnosed with SES after she received unlicensed liquid silicone injections for gluteal augmentation. Her disease necessitated treatment with veno-arterial extracorporeal membrane oxygenation. Her neurological status remained poor. Our patient was also treated for SES status-post illicit silicone injections several years prior to the current episode. To our knowledge, this is the only reported instance of the same patient experiencing SES status-post illicit silicone injections on two separate occasions.

Our patient's case suggests that robust education is needed for patients and the general public regarding the dangers of illicit body modifications. Given the widespread availability of counterfeit "medical grade" silicone, it is likely that the number of SES cases will continue to increase. Physicians must be able to recognize the symptoms of SES, and not discount the possibility that patients will continue to receive illicit injections-even if they experienced devastating consequences the first time.

1. Introduction

The word silicone was first coined by F.S Kipling in 1901 to describe polydiphenylsiloxane [1]. Silicone has properties like low thermal conductivity, low chemical reactivity, low toxicity and does not support microbiological growth and has little change over time which makes it highly desirable in the cosmetic industry. They have been used for the last several decades for soft tissue augmentation. The use of liquid silicone injections as an alternative to implants is cost effective and is on the rise. Due to its ease in availability, unlicensed body-sculpting procedures that involve subcutaneous injections of silicone are a rising concern [2]. These procedures are offered at dramatically reduced prices compared to licensed plastic surgery interventions [3]. Silicone, initially thought to be inert, is associated with several inflammatory complications. Silicone embolism syndrome (SES) is one of the most dreaded

* Corresponding author. Newark Beth Israel Medical Center, 201 Lyons Avenue, Newark, NJ, 07112, USA.

E-mail address: nikhil.madan@rwjbh.org (N. Madan).

<https://doi.org/10.1016/j.rmcr.2021.101576>

Received 23 November 2021; Received in revised form 30 December 2021; Accepted 30 December 2021

Available online 22 January 2022

2213-0071/© 2022 The Authors. Published by Elsevier Ltd. This is an open access article under the CC BY-NC-ND license

(<http://creativecommons.org/licenses/by-nc-nd/4.0/>).

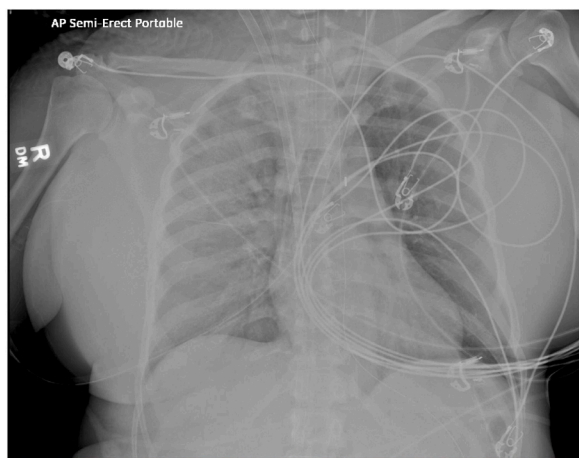

Image 1. Chest radiograph Day 2: Diffuse bilateral infiltrates and pulmonary edema.

complications characterized by venous embolism of silicone leading to pneumonitis, diffuse alveolar hemorrhage, and silicone embolism with severe cardiopulmonary failure.

Here, we present the only known instance of a patient experiencing SES status-post illicit liquid silicone injections on two separate occasions. This case emphasizes the importance of recognizing patients at-risk for SES, in addition to highlighting the severity of SES' disease course.

1.1. Case presentation

Our patient, a 49-year-old African American female, presented to the emergency department with shortness of breath and altered mental status. Her past medical history includes major depressive disorder, mitral valve prolapse, and purtscher retinopathy. For surgical history, she received bilateral breast augmentation in 2018 and multiple rounds of gluteal injections, including gluteal liquid silicone injection performed at an unlicensed facility the day prior to admission.

The patient was hypotensive (systolic pressures in the 90's) when EMS arrived at the scene. She received 500 mL's of 0.9% normal saline in the field.

On exam she was awake, able to follow some commands and was able to say that she received gluteal injections at "some lady's house". Immediately after the procedure, she reports that she experienced dizziness and shortness of breath.

In the ED, her vital signs were: blood pressure: 98/63 mmHg, heart rate: 111 beats/min, respiratory rate: 18 breaths/minute. She was noted to be tachypneic but her exam was otherwise unremarkable. She was also noted to be hypoxic with oxygen saturation around 75%. Her initial arterial blood gas (ABG) showed a pH of 7.34, pCO₂ of 41 and pO₂ 19 on room air. Her initial labs showed a white count of 8.1×10^3 /mL, hemoglobin of 13.2 g/dL and a platelet count of 159×10^3 /mL. Her serum chemistries were normal and the troponin was 3 ng/mL. She was started on high flow oxygen and underwent a computerized tomography (CT) of the chest with contrast due to concerns for silicone embolism. It showed an enlarged right ventricle, but negative for pulmonary embolism and parenchymal lung disease. CT abdomen/pelvis showed diffuse fat stranding over the lower abdomen and pelvis. CT of the head showed aerosolized secretions in the maxillary sinuses and was otherwise negative. Echocardiogram showed right ventricular enlargement with reduced function, with a normal left ventricular function. There was hyper dense debris in the inferior vena cava. She was also noted to have an intra-cardiac shunt.

She was treated with empiric vancomycin (15 mg/kg Q12) and zosyn 3.375g after blood cultures were sent.

Early the next morning, the patient was noted to be lethargic and intermittently nauseous. She became increasingly agitated, confused and tachypneic. She was emergently intubated for persistent oxygen desaturation while on 100% inspired oxygen and increased work of breathing. Her ABG on 100% supplemental oxygen on the ventilator showed a pH of 7.4, pCO₂ of 29 and pO₂ of 57 mmHg. She was also noted to become progressively hypotensive requiring multiple vasopressors and ionotrope support.

Our hospital was consulted for transfer for extracorporeal membrane oxygenation (ECMO). In the interim patient was treated with high dose steroids for alveolitis. When our ECMO team evaluated the patient, a decision was made to start her on V-AV ECMO due to increased oxygenation needs and poor cardiac function.

Upon transfer to our ECMO-capable hospital, she was noted to have diffuse bilateral infiltrates on her chest X-ray (Image 1). Her echocardiogram showed an enlarged right ventricle with depressed function and hypertrophied left ventricle with normal function. Due to increasing inotropic support and intra-aortic balloon pump (IABP) was placed. She remained on antibiotics and steroids. 2 days into transfer patient developed worsening kidney function and was started on continuous renal replacement therapy.

She continued to improve and was changed over to V-V ECMO on day 3. She was then weaned off all vasopressors and ionotropes. She was weaned off IABP and underwent ECMO decannulation on hospital day 5. Due to poor mental status patient underwent a tracheostomy. Magnetic resonance imaging (MRI) of the brain showed nonspecific severe white matter signal abnormality and extensive microhemorrhages throughout the bilateral cerebral and cerebellar hemispheres likely related severe posterior reversible

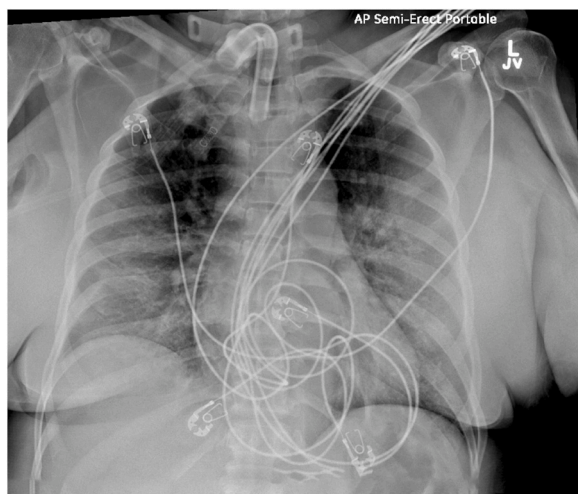


Image 2. Chest radiograph Day 12: Diffuse bilateral infiltrates.

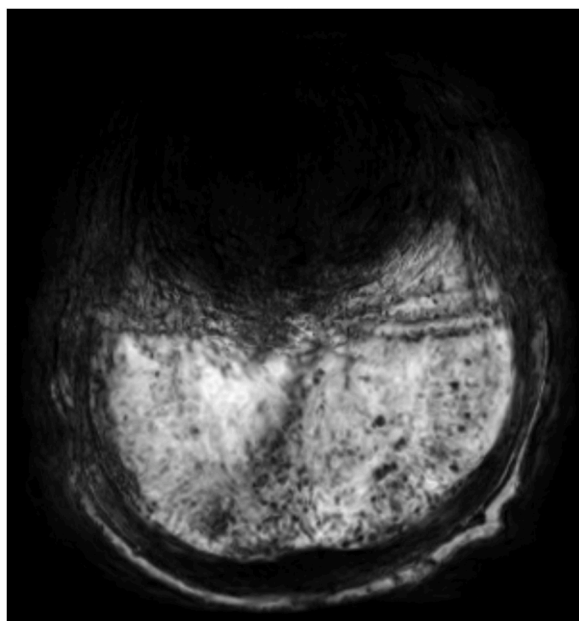


Image 3. Magnetic resonance imaging study (MRI) of brain showing multiple microhemorrhages.

encephalopathy syndrome (PRES), possibly in the setting of the neurologic sequela of silicone embolism ([image 3](#)). Her neurological status remains poor. She is in the process of being liberated from the ventilator with improvement in her pulmonary status ([image 2](#)).

In August 2018, approximately 2.5 years before the current episode, the patient visited a neighboring hospital's emergency department after receiving gluteal injections with similar complaints of respiratory distress and dizziness. A CT angiogram was negative for pulmonary embolism. She was admitted to the general medicine floor, where she subsequently became severely hypoxic and developed acute hypoxic respiratory failure with hemoptysis. She was then transferred to the intensive care unit (ICU) with the preliminary diagnosis of foreign body reaction secondary to silicone injections.

Since her cardiac catheterization was negative for coronary artery disease, the patient underwent a transthoracic echocardiogram and a transesophageal echocardiogram. These studies showed severely dilated right-sided chambers; raising the possibility of pulmonary embolization from the silicone injections. Additionally, she had severe tricuspid regurgitation, and signs of pulmonary hypertension-presumed secondary to the silicone injections.

Past medical interventions to achieve the survival included 4 weeks of ICU care and intubation for one week. A repeat echocardiogram did not show any sign of severe tricuspid regurgitation or a dilated right atrium and right ventricle.

She was liberated from the ventilator and discharged to a rehab facility. She was seen in clinic 2 months after her discharge and noted to have significant recovery in her mental status with some improvement in the MRI.

Table 1
Case reports of Silicone Embolism.

Author	Age	Gender	Comorbidities	Insertion Site	Volume	Presentation	Onset of symptom	Vent Need	Steroid use	ECMO	Result
Singarajah et al.[16]	59	M	None	Penis and scrotum for penile enlargement	80 ml	Shortness of breath, fatigue	2–3 hours post injection	Yes	60 mg q6hrs	No	Tracheostomy – discharged LTAC
Schmid et al. [4]	22	M (transsexual)	HIV	Bilateral breast augmentation (700 ml)	700 ml	Dyspnea, chest tightness and fever	4 days post injection	No	120 mg/day	No	Discharged home on HOD 6
Nebel et al. [17]	32	M	None	Penile & scrotum	300 ml in penile, 700 ml in scrotum	Chest and pleuritic chest pain		Yes	unknown	Yes	Died after 7 months on ECMO
Bejarano et al.[18]	25	M	Esthetic surgical procedures (rhinoplasty & mammoplasty)	Gluteal & trochanteric area	Unknown	Dyspnea, fever, cough, chest tightness	2 days	Yes	Yes – dosage unknown	No	Discharged to rehab post extubation
Wills et al. [19]	62	M	HIV	Penile & scrotum	Unknown	Deceased	N/A	N/A	N/A	N/A	Deceased on admission

Table 2
Case reports of silicone embolism.

Author	Age	Gender	Comorbidities	Insertion Site	Volume	Presentation	Onset of symptom	Vent Need	Steroid use	ECMO	Result
Blanco et al.[20]	23	F	Chlamydia infection, ectopic pregnancy	Gluteal	Unknown	Abdominal pain	Unknown	Yes	60 mg q6hrs	No	Discharged to rehab on steroid taper
Bartsich et al. [21]	29	F	None	Gluteal	Unknown	Dyspnea	Unknown	No	60 mg q6hrs	No	Discharged home
Purdy-Payne et al.[22]	47	F	None	Gluteal		Epigastric pain, nausea, vomiting, diarrhea.		Yes	No	No	Discharged home
Ng et al.[15]	30	F	Breast augmentation with silicone implant 2 years ago	Gluteal	500 ml each	Dyspnea, cough, fever		Yes	Unknown	No	Discharged home
Adegunsoye et al. [8]	20	F	None	Gluteal & thigh	3000 ml	Chest tightness, dyspnea	4 hours	Yes	No	No	Deceased
Mongero et al. [13]	27	F	None	Gluteal	Unknown	Dyspnea, pleuritic chest pain, cough	1 day	Yes	Yes	Yes	Discharged home

2. Discussion

SES is a well-known complication of liquid silicone injections. The exact incidence of SES is unknown, Schmid et al. reported 33 cases from 1965 to 2004, of respiratory symptoms after silicone injections [4]. Lyapichev et al reported 19 cases in their literature review from 2004 to 2012 and concluded that, over the last 12 years, the number of published articles per year describing silicone embolism increased by almost threefold from that reported in the preceding 40 years [5]. See Tables 1 and 2 for list of case report and series in current literature. Local complications like infection, bleeding and foreign body reaction can occur. Systemic complications like lymphadenopathy [6], granulomatosis [7], and SES have been reported. The most common signs and symptoms are dyspnea with hypoxia, fever, hemoptysis with diffuse alveolar hemorrhage and cough [2–5]. End organ damage with renal failure, altered mental status and coma have been reported [4,8]. The pathophysiology of SES is similar to fat embolism in the lung. The silicone embolic cause occlusions in the microvasculature which leads to an inflammatory response [4]. This leads to edema, bleeding and an acute respiratory distress syndrome with pneumonitis. SES occurs usually within the first two days following a silicone injection, but can rarely happen after a few months [5,9]. High local tissue pressure induced by Injection of large volumes of silicone and post-injection massage can cause significant embolization of the material leading to acute cor pulmonale. Chest X-ray can be normal or show bilateral infiltrates. CT scans commonly shows peripherally distributed ground-glass opacities associated with interlobular septal thickening [10]. Bronchoscopy may show a neutrophil predominant bloody alveolar lavage consistent with diffuse alveolar hemorrhage. Silicone globules in the alveolar space, inter-alveolar walls, pulmonary capillaries, and macrophages can be seen. Microscopic examination of the lungs can show edema, hemorrhage and inflammation [11]. When the history of silicone injections is not available using modified Oil Red O stain in formalin-fixed, paraffin-embedded tissue sections may reveal the presence of silicone embolus [12]. Treatment for SES is mostly supportive with oxygen therapy and rest. Steroids have been historically used, but their benefit in SES is not proven. High dose steroids have been used in diffuse alveolar hemorrhage from SES. Mechanical ventilatory support may be needed for worsening respiratory failure. There are case reports describing the need for V–V ECMO in severe cases of cardiopulmonary failure [13–15]. To our knowledge this is the first case of VAV ECMO used as salvage therapy for SES with acute hypoxic respiratory failure and acute cor pulmonale. The majority of patients with SES have good survival, but mortality increases with neurologic and multi-organ failure [4].

To our knowledge this is the first case of patient developing SES for a second time after gluteal silicone injections. Her neurological findings were possibly related to paradoxical silicone embolization. The intriguing question posed by this case is: what would compel an individual to undergo a non-Food and Drug administration (FDA) approved, elective procedure that had resulted in such poor outcomes the first time? Given our patient's psychiatric history, is possible the complex dynamics of body dysmorphism secondary to major depressive disorder were a factor in her decision to receive these injections at least two times. Non-regulated, non-FDA approved "medical grade silicone," is available on the internet. Given the ease of access to such products, we may continue to see an increase in such cases. Continued patient and general population education is needed regarding these potentially fatal complications.

3. Footnotes

All authors have completed the ICMJE uniform disclosure form. The authors have no conflicts of interest to declare. None of the authors serve as a current Editorial Team member.

Ethical Statement: The authors are accountable for all aspects of the work in ensuring that questions related to the accuracy or integrity of any part of the work are appropriately investigated and resolved.

Written informed consent was obtained from the patient for publication of this study and any accompanying images. A copy of the written consent is available for review by the Editor-in-Chief of this journal.

Declaration of competing interest

The authors have no conflict of interest to declare.

References

- [1] L.L.L. Frederic Kipping, XLVII.-Organic derivatives of silicon. Triphenylsilicic acid and alkyloxysilicic acid chlorides, *J. Chem. Soc. Trans.* 79 (1901) 449–459.
- [2] E.A.S.H. Price, J.A. Perper, Massive systemic silicone embolism: a case report and review of literature, *Am. J. Forensic Med. Pathol.* 27 (2) (2006 Jun 1) 97–102.
- [3] C.A.R. Bertin, V. Andrieu, et al., Illicit massive silicone injections always induce chronic and definitive silicone blood diffusion with dermatologic complications, *Medicine* 98 (4) (2019 Jan).
- [4] A.T.A. Schmid, L. Leshko, et al., Silicone embolism syndrome: a case report, review of the literature, and comparison with fat embolism syndrome, *Chest* 127 (6) (2005 Jun 1) 2276–2281.
- [5] K.C.F. Lyapichev, J. Poveda, et al., Pulmonary Empty Spaces: Silicone Embolism—A Decade of Increased Incidence and its Histological Diagnosis, *Case reports in pathology*, 2016.
- [6] Y.S.S. Lee, E.S. Yoon, et al., Extensive silicone lymphadenopathy after breast implant insertion mimicking malignant lymphadenopathy, *Ann. Surg. Treatment Res.* 93 (6) (2017 Dec 1) 331–335.
- [7] N.S.J. Jilani, E. Nemytova, Liquid silicone-induced extensive and debilitating granulomatosis responding to hydroxychloroquine, *Case Rep. Rheumatol.* (2019).
- [8] A.O.M.S. Adegunsoye, D.J. Valentino, A 20-year-old woman with rapidly progressive dyspnea and diffuse pulmonary infiltrates, *Respir. Med. Case Rep.* 5 (2012 Jan 1) 34–36.
- [9] L.P.G.H. Hariri, R. Brown, et al., Progressive granulomatous pneumonitis in response to cosmetic subcutaneous silicone injections in a patient with HIV-1 infection: case report and review of the literature, *Arch. Pathol. Lab Med.* 136 (2012 Feb) 204–207.
- [10] C.S.A.M. Restrepo, J.A. Carrillo, et al., Silicone pulmonary embolism: report of 10 cases and review of the literature, *J. Comput. Assist. Tomogr.* 33 (2) (2009 Mar 1) 233–237.
- [11] K.Y.K.S. Chung, I.H. Kwon, et al., Clinicopathologic review of pulmonary silicone embolism with special emphasis on the resultant histologic diversity in the lung—a review of five cases, *Yonsei Med. J.* 43 (2) (2002 Apr 1) 152–159.
- [12] M.K.V. Lewin-Smith, K. Shilo, et al., Detection of silicone in lung tissue, *Arch. Pathol. Lab Med.* 136 (10) (2012 Oct) 1179–1180.

- [13] L.B.B.D. Mongero, J. Cunningham, et al., Extracorporeal membrane oxygenation for diffuse alveolar hemorrhage and severe hypoxemic respiratory failure from silicone embolism, *Perfusion* 24 (4) (2010 Jul) 249–252.
- [14] S.B.D. Vijaykumar, A. Nwosu-Iheme, et al., Successful use of extracorporeal membrane oxygenation for silicone embolism syndrome and pulmonary hemorrhage, *Chest* 150 (4) (2016 Oct 1) 369A.
- [15] A.F.E.E. Ng, VV ECMO rescue of silicone syndrome, *Ann. Clin. Case Rep. Cardiovascular Med.* (2018).
- [16] Singarajah, et al., *Clin. Pract. Cases Emerg. Med.* 4 (4) (2020 Nov) 595–598, <https://doi.org/10.5811/cpcem.2020.9.48838>.
- [17] Nebel, et al., *Forensic Sci. Int.* 325 (2021 Aug) 110872, <https://doi.org/10.1016/j.forsciint.2021.110872>.
- [18] Bejarano, et al., *Medicine (Baltim.)* 99 (24) (2020 Jun 12), e20578.
- [19] Wills, et al., *Forensic Sci. Med. Pathol.* 15 (2) (2019 Jun) 304–308.
- [20] Blanco et al, *Am. J. Emerg. Med.*, Volume [36], Issue 12, December 2018, Pages 2340.e3-2340.e4.
- [21] Bartsich, et al., *J. Plast. Reconstr. Aesthetic Surg.* 63 (1) (2010 Jan) e1–3, <https://doi.org/10.1016/j.bjps.2009.04.004>.
- [22] Purdy-Payne, et al., *Surg. Infect.* 16 (4) (2015 Aug) 473–477, <https://doi.org/10.1089/sur.2014.225>.