

case report

Inflammatory myofibroblastic tumor of the pancreatic head - a case report of a 6 months old child and review of the literature

Ales Tomazic¹, Diana Gvardijancic¹, Joze Maucec¹, Matjaz Homan²

¹ Department of Abdominal Surgery, University Medical Center Ljubljana, Ljubljana, Slovenia

² Department of Gastroenterology, Hepatology and Nutrition, University Children's Hospital, Ljubljana, University Medical Center Ljubljana, Ljubljana, Slovenia

Radiol Oncol 2015; 49(3): 265-270.

Received 14 March 2013
Accepted 22 March 2014

Correspondence to: Assist. Prof. Aleš Tomažič, M.D., Ph.D., Department of Abdominal Surgery, University Medical Center Ljubljana, Zaloška cesta 7, SI-1000 Ljubljana, Slovenia. E-mail: ales.tomazic@kclj.si

Disclosure: The authors have no conflict of interest to disclose.

Tomazic A and Homan M contributed equally in preparation of the manuscript

Background. Inflammatory myofibroblastic tumors are rare in the pediatric population. Most common localizations were reported in the lungs. A localization in the pancreas needs differentiation from other tumors and chronic pancreatitis. Treatment is surgical resection, although there are reports of treatment with oral steroids and radiation therapy. **Case report.** A 6-month-old child was treated due to a tumor in the head of the pancreas. On admission he was jaundiced with pruritus. US and MRI confirmed pancreatic tumor. Preoperative biopsy wasn't conclusive regarding the nature of the tumor. Duodenopancreatectomy was performed. Postoperative course was uneventful. Histologic examination confirmed the diagnosis of inflammatory myofibroblastic tumor. On follow up, he remained with no evidence of recurrence.

Conclusions. A literature review revealed 10 cases of pancreatic inflammatory myofibroblastic tumors in the pediatric age group. Our patient is the youngest reported. Despite major resection, there were no complications. However, management of this child might be possible with steroids, but conservative treatment might be insufficient, especially in aggressive forms of tumors.

Key words: child; inflammatory myofibroblastic tumor; duodenopancreatectomy

Introduction

Inflammatory myofibroblastic tumors (IMT's) are rare solid lesions that occur primarily in visceral and soft tissue. Most frequently they occur in the first two decades of life. The most common localizations of IMTs have been reported in lung, mesentery and omentum.¹ These lesions have also been termed inflammatory pseudotumors, fibroxanthomas, fibrous histiocytomas, postinflammatory tumors and plasma cell granulomas. There are few hypotheses of the etiological factors responsible for development of the IMT. IMT can develop as a consequence of an inflammatory reaction to an underlying low grade malignancy. *Human herpes viruses*

3 and 8, *Eikenella corrodens* and *Epstein Barr virus* have been also proposed as possible infectious triggers of the IMT.^{2,3,4} It is speculated that the disease is provoked by deregulation of cytokine production caused by infection.

Clinically and radiologically, an IMT can be confused with malignancy. A localization of IMT in the pancreas is very rare and needs differentiation from other tumors and chronic pancreatitis.

The macroscopic appearance of IMT is usually well-circumscribed or multinodular, white, firm mass. Histological, IMT is composed of spindle-shaped myofibroblasts or fibroblasts accompanied by a mixed inflammatory infiltrate of eosinophils, plasma cells, and lymphocytes.^{1,5} Treatment is

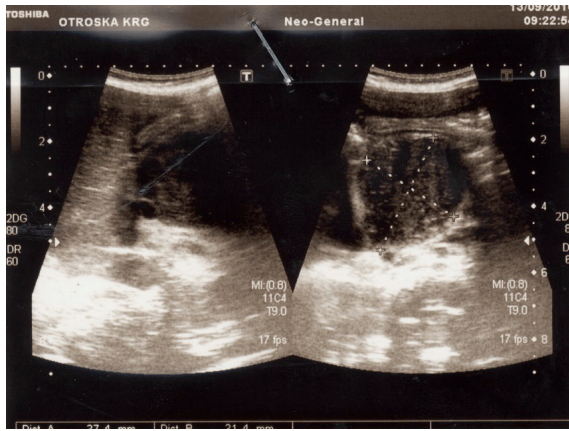
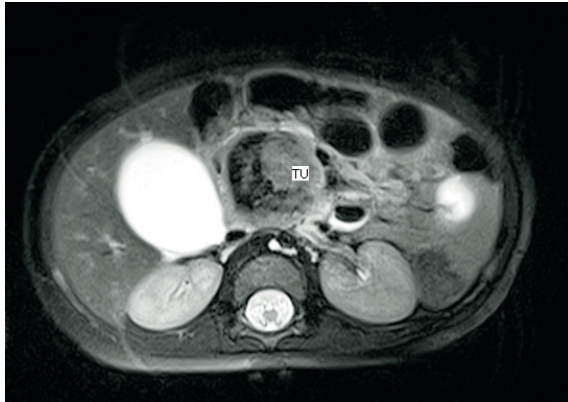
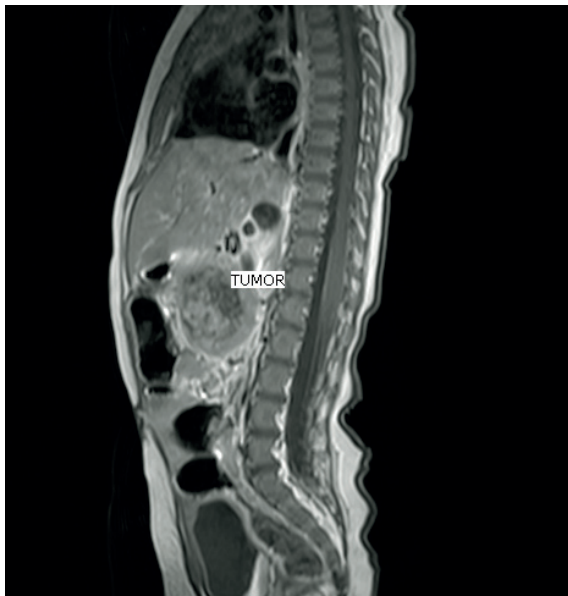

FIGURE 1. Ultrasound has identified 40 mm large mass in the region of the head of the pancreas.



(A)



(B)

FIGURE 2. MRI confirmed well circumscribed tumor mass, with a diameter of 37 mm. The origin of the mass was in the head of the pancreas and in the uncinate process. There was no infiltration of the surrounding tissue. Tumor impressed the caval vein and pushed the superior mesenteric artery and vein ventrally and laterally. (A) Coronal plane. (B) Sagittal plane.

usually in the form of surgical resection, although there are recent reports of treatment with oral steroids.⁶ Some authors report also palliative treatment with radiation therapy.⁷

We present a case of 6 months old male, who was referred to our department due to an IMT of the pancreatic head, which caused jaundice and pruritus. To the best of our knowledge, this is the youngest child with this type of tumor published so far in the literature.

Case report

A 6-months old boy was transferred to our hospital with a 4-days history of jaundice and pruritus. On examination he was jaundiced with no organomegaly. There was a rash on the trunk and extremities. Liver function tests revealed a direct bilirubin level of 109 $\mu\text{mol/L}$ (normal below 17), alkaline phosphatas level of 11.62 $\mu\text{kat/L}$ (normal up to 1.74) and γGT level of 3.23 $\mu\text{kat/L}$ (normal up to 0.63).

An ultrasound scan (US) of his abdomen identified a 40 mm large mass in the head of the pancreas. The common bile duct was dilated, the gallbladder was extremely enlarged, but there was no dilatation of intrahepatic bile ducts and pancreatic duct (Figure 1). The results of US-guided fine needle aspiration biopsy wasn't conclusive regarding the nature of the tumor. MRI confirmed well circumscribed tumor mass, with a diameter of 37 mm. The tumor originated from the head of the pancreas and uncinate process. 3D reconstruction showed no infiltration in the surrounding tissue, including major vessels (Figure 2). However, there was evidence, that the tumor impressed on the caval vein

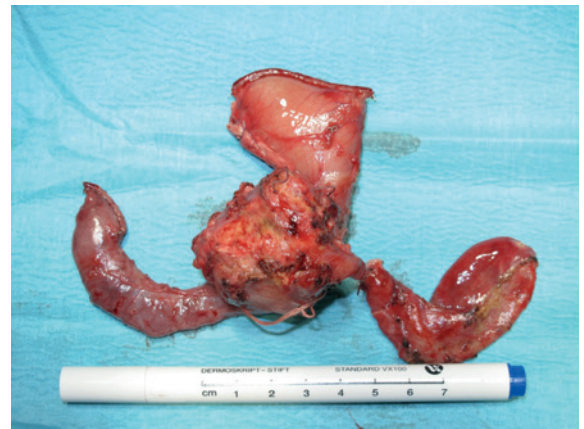

FIGURE 3. Surgical specimen of the duodenopancreatectomy. Left is duodenum, right gallbladder, up stomach and in the middle head of the pancreas with tumor.

and pushed the superior mesenteric artery and vein ventrally and laterally.

Whipple's procedure was performed due to biliary obstruction and possible malignancy (Figure 3).

Histological examination revealed an infiltrative growth in the pancreatic head, mainly surrounding and destroying pancreatic acini (Figure 4), but also encroaching on papila of Vater and duodenal wall. The lesion was composed of bland spindle cells forming a storiform (Figure 5) and vague fascicular growth pattern, admixed with areas displaying more epithelioid morphology (Figure 6) and variably prominent inflammatory cell infiltrate (Figure 7), composed of lymphocytes, plasma cells and eosinophilic granulocytes (Figure 8).

By immunohistochemistry, the lesional cells were smooth muscle actin positive proliferation of bland spindle cells forming a storiform and vague fascicular growth pattern, admixed with areas displaying more epithelioid morphology and variably prominent inflammatory cell infiltrate, composed of lymphocytes, plasma cells and eosinophilic granulocytes, while stainings for cytokeratins, S100, desmin, H-caldesmon and ALK were negative, confirming myofibroblastic differentiation of the lesional cells. Although the histological and immunohistochemical features were suggestive of inflammatory myofibroblastic tumour, an unusual form of chronic pancreatitis could not be reliably excluded.

The postoperative course was uneventful. The boy was discharged on the 14th postoperative day. Over the next 3.5 years of follow up, he remains well and with no clinical or radiological evidence of recurrence.

Discussion and review of literature

Pancreatic tumors are rare in childhood, accounting for only 0.2% of childhood malignancies.⁸ Inflammatory myofibroblastic tumors are usually benign solid lesions of unclear etiology, commonly found in the lungs. The term inflammatory myofibroblastic tumor, commonly referred to as inflammatory pseudotumor in the previous literature, was initially proposed in 1990 in the study of inflammatory lesions of the pulmonary system.⁹ The majority of the cases that were reported in the literature as »inflammatory pseudotumor« of the pancreas, would probably now be classified as autoimmune pancreatitis and in rare cases they represent

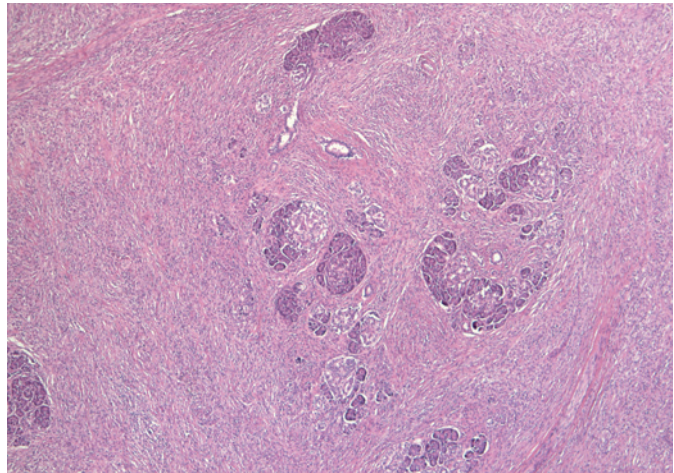


FIGURE 4. Spindle cell proliferation in the pancreatic head, growing in between and into the pancreatic acini.

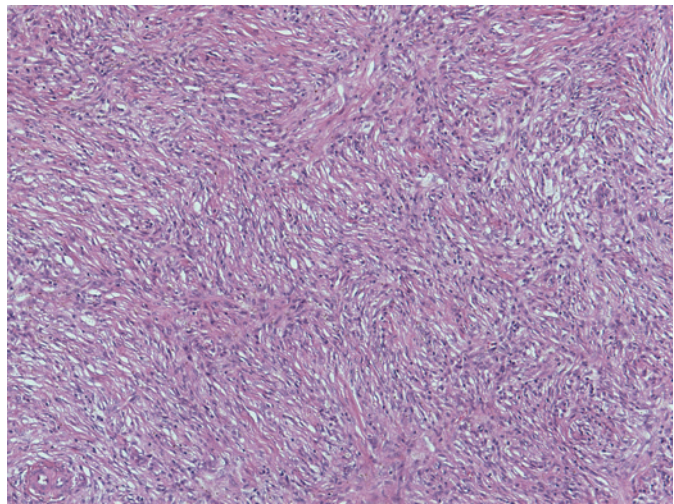


FIGURE 5. Bland spindle cell proliferation with vague storiform growth pattern.

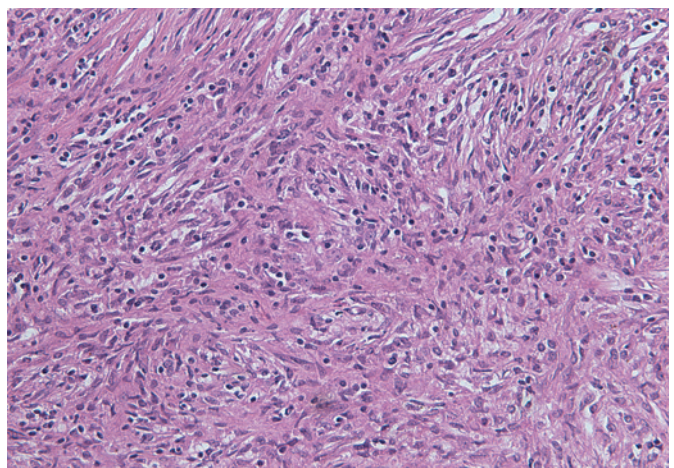


FIGURE 6. An admixture of spindled and more epithelioid lesional cells admixed with inflammatory cell infiltrate.

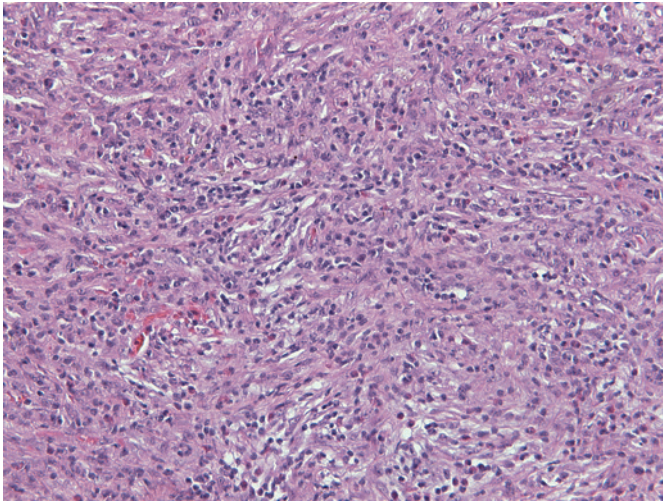


FIGURE 7. Prominent inflammatory cell infiltrate was present in several areas within the lesional cell proliferation.

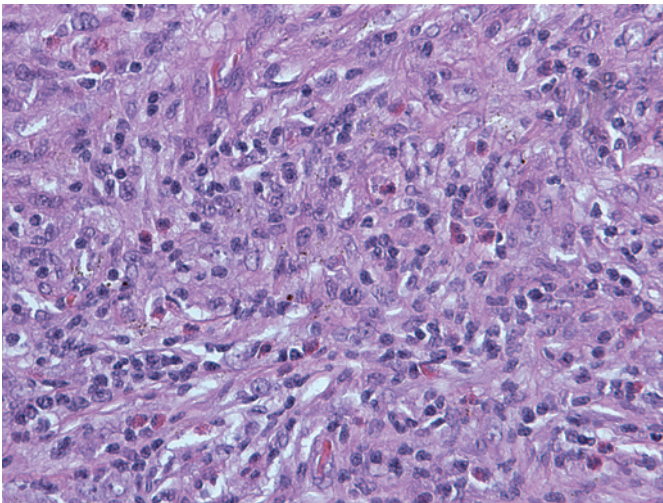


FIGURE 8. Note numerous eosinophilic granuloctes within the inflammatory cell component.

true »inflammatory myofibroblastic tumors«. ^{10,11} Another nosological problem with inflammatory myofibroblastic tumor is differentiation from inflammatory fibrosarcoma, which was first reported as an invasive tumor with greater atypia of constituent fibroblasts or myofibroblasts than seen in inflammatory myofibroblastic tumor. ¹² According to Coffin, inflammatory myofibroblastic tumors are characterized with local invasion, vascular invasion and multifocal onset. ¹³ Invasion of retroperitoneal connective tissue, duodenal wall and Vater's papilla was also seen in our case. This indicated, that the lesion was neoplastic. However in inflam-

matory fibrosarcoma, more aggressive behaviour is seen, including higher incidence of recurrence and death. ¹² Inflammatory myofibroblastic tumor and inflammatory fibrosarcoma have been speculated to be two lesions occupying the same spectrum, with reported cases of inflammatory myofibroblastic tumors probably including some low-grade examples of inflammatory fibrosarcoma. ¹⁴

Histologically, inflammatory myofibroblastic tumors are characterized by irregular proliferation of myofibroblasts intermixed with inflammatory cells, mainly lymphocytes and plasmacytes. They are subcategorized into fibrohistiocytic type, plasma cell granuloma type, largely sclerosed or fibrosed type, hypocellular fibrous type and myxoid/vascular type. ¹⁵ Discovery of cytogenetic aberrations in inflammatory myofibroblastic tumors and the recognition of ALK gene rearrangements solidified the concept of inflammatory myofibroblastic tumor as a neoplastic lesion. It most frequently occurs in the lung or the mesenterium of children or young adults and rarely metastasizes (<5%). ¹⁶ The liver is also relatively frequently involved ¹⁷, but other sites such as the stomach ¹⁸, spleen ¹⁹, bladder ²⁰, kidney ²¹, maxillary sinuses ²², heart ²³, parapharyngeal space ²⁴, retrorectal space ²⁵ and peripheral nerve ²⁶ have also been recorded.

Only 28 cases of pancreatic inflammatory myofibroblastic tumors have been reported so far, 60% being located in the pancreatic head. ⁷ Inflammatory fibroblastic tumor equally affects males and females. The age distribution resembled that of in pulmonary system ranging 2.5 to 70 years. ²⁷ A literature review revealed 10 documented cases of pancreatic inflammatory myofibroblastic tumor in the pediatric age group (Table 1).

Compared to this data, our patient is the youngest child with inflammatory myofibroblastic tumor of the pancreas reported in the literature. The main features at presentation were pruritus, jaundice, abdominal mass, lethargy, vomiting, fever and anemia. ⁶ Curative resection is treatment of choice for inflammatory myofibroblastic tumors. Whipple's procedure or distal pancreatectomy is performed, according to the site of the tumor. The prognosis of inflammatory myofibroblastic tumors is generally good, with rare incidence of malignant transformation. ²⁸ However, a significant recurrence rate of 25% was reported. ²⁹ It was suggested that the presence of atypia, ganglion-like cells and p53 expression may suggest more aggressive behaviour. ^{30,31} These lesions may be indistinguishable from inflammatory fibrosarcoma due to a high degree of clinical and morphological overlap. ²⁸

TABLE 1. Reported cases of pediatric pancreatic inflammatory myofibroblastic tumors in the literature

Age	Sex	Location	Presentation	Treatment	Reference
10	F	body	Abdominal mass	Distal pancreatectomy	Abrebanel et al. 1984
2.5	F	body	Anemia, fever, abdominal mass	Distal pancreatectomy	Scott et al. 1988
5	F	head	vomiting	Whipple	Stringer et al. 1992
8	F	head	Jaundice, anemia, weight loss	Whipple	Uzoaru et al. 1993
8	F	body	Abdominal mass	Distal pancreatectomy	Shankar et al. 1998
11	F	head	Jaundice, pruritus, anorexia, pain	Whipple	McLain et al. 2000
4	F	head	Malaise, lethargy	Whipple	Slavotinek et al. 2000
11	M	body	Lethargy, anemia, abdominal mass	Distal pancreatectomy	Morris-Stiff et al. 1998
13	F	head	Jaundice, vomiting, weight loss	Whipple	Dagash et al. 2009
10	M	head	Jaundice, pain	Steroids	Dagash et al. 2009

Besides surgical resection, alternative therapeutic regimens are still lacking. While systemic immunosuppressive treatment with steroids, chemotherapy and radiation therapy have been reported for unresected or recurrent cases of extrapancreatic inflammatory myofibroblastic tumors,^{28,32,33}

In the literature there are only two reported cases of pancreatic inflammatory myofibroblastic tumors that were not treated with resection.^{6,7} The first reported case was a child treated with high dose steroids. The mass gradually resolved and the patient remains disease free 6 years after treatment.⁶ The second case was an adult treated with palliative radiation and corticoid therapy because of unresectable mass in the head of the pancreas.⁷ In this case, long term results were not published.

Chronic pancreatitis could not be completely excluded according to histological examination. Anyway, specific causative factor for chronic pancreatitis was not identified. In addition, pediatric patients present with chronic pancreatitis much later (average age 6 ± 4 years) than it developed in our patient (6 months).³⁴ Therefore, chronic pancreatitis was very unlikely the reason for pancreatic head mass in our patient.

Conclusions

We report a case of pancreatic inflammatory myofibroblastic tumors in a six month old male child treated with surgical resection. This is the first case report of an infant with IMT. In addition, the tumor is rarely described in the pancreas. Despite major surgery no complications evolved in long term follow up.

References

- Coffin CM, Humphrey PA, Dehner LP. Extrapulmonary inflammatory myofibroblastic tumor: a clinical and pathological survey. *Semin Diagn Pathol* 1998; **15**: 85-101.
- Slavotinek JP, Bourne AJ, Sage MR, Freeman JK. Inflammatory pseudotumor of the pancreas in a child. *Pediatr Radiol* 2000; **30**: 801-3.
- Gomez-Roman JJ, Sanchez-Velasco P, Ocejo-Vinyals G, Hernandez-Nieto E, Leyva-Cobian F, Val-Bernal JF. Human herpesvirus-8 genes are expressed in pulmonary inflammatory myofibroblastic tumor (inflammatory pseudotumor). *Am J Surg Pathol* 2001; **25**: 624-9.
- Lewis JT, Gaffney RL, Casey MB, Farrell MA, Morice WG, Macon WR. Inflammatory pseudotumor of the spleen associated with a clonal Epstein-Barr virus genome. Case report and review of the literature. *Am J Clin Pathol* 2003; **120**: 56-61.
- Gomez-Roman JJ, Ocejo-Vinyals G, Sanchez-Velasco P, Nieto EH, Leyva-Cobian F, Val-Bernal JF. Presence of human herpesvirus-8 DNA sequences and overexpression of human IL-6 and cyclin D1 in inflammatory myofibroblastic tumor. *Lab Invest* 2000; **80**: 1121-6.
- Dagash H, Koh C, Cohen M, Sprigg A, Walker J. Inflammatory myofibroblastic tumor of the pancreas: a case report of 2 pediatric cases-steroids or surgery? *J Ped Surg* 2009; **44**: 1839-41.
- Schutte K, Kandulski A, Kuester D, Meyer F, Wieners G, Schulz HU, et al. Inflammatory myofibroblastic tumor of the pancreatic head: An unusual cause of recurrent acute pancreatitis- case presentation of a palliative approach after failed resection and review of the literature. *Case Rep Gastroenterol* 2010; **4**: 443-51.
- Mammen A, Kalisadan V, Beasley SW. Rare pancreatic tumors in children (other than nesidioblastosis). *Aust N Z J Surg* 1997; **67**: 720-1.
- Petinato G, Manivel JC, De Rosa N, Dehner LP. Inflammatory myofibroblastic tumor (plasma cell granuloma). Clinicopathologic study of 20 cases with immunohistochemical and structural observations. *Am J Clin Pathol* 1990; **94**: 538-46.
- Volkan Adsay N, Bastruk O, Klimstra DS, Kloppel G. Pancreatic pseudotumors: non-neoplastic solid lesions of the pancreas that clinically mimic pancreas cancer. *Semin Diagn Pathol* 2004; **21**: 260-7.
- Petter LM, Martin JK, Menke DM. Localized lymphoplasmacellular pancreatitis forming a pancreatic inflammatory pseudotumor. *Mayo Clin Proc* 1998; **73**: 447-50.
- Meis JM, Enzinger FM. Inflammatory fibrosarcoma of the mesentery and retroperitoneum; A tumor closely simulating inflammatory pseudotumor. *Am J Surg Pathol* 1991; **15**: 1146-56.
- Coffin CM, Waterson J, Priest JR, Dehner LP. Extrapulmonary inflammatory myofibroblastic tumor (inflammatory pseudotumor): A clinicopathologic and immunohistochemical study of 84 cases. *Am J Surg Pathol* 1995; **19**: 859-72.

14. Nakamura Y, Inui K, Yoshino J, Tokoro T, Sabater L, Takeda S, et al. Inflammatory myofibroblastic tumor (inflammatory fibrosarcoma) of the pancreas: A case report. *Hepato-Gastroenterology* 2005; **52**: 625-8.
15. Travis WD, Colby TV, Koss MN, Rosado-de-Christenson ML, Muller NL, King TE. Miscellaneous disease of uncertain etiology. In: Atlas of Nontumor Pathology. Non-neoplastic Disorders of the Lower Respiratory Tract. 1st ed. King DW, ed. American Registry of Pathology and Armed Forces Institute of Pathology, Washington DC, 2002. p. 857-900.
16. Coffin CM, Hornick JL, Fletcher CDM. Inflammatory myofibroblastic tumor: comparison of clinicopathologic, histologic, and immunohistochemical features including ALK expression in atypical and aggressive cases. *Am J Surg Pathol* 2007; **31**: 509-20.
17. Krech RH, Erhardt-Domagalsky M, Neumann H. Inflammatory pseudotumor of the liver. Morphologic and cytophotometry studies and differential diagnosis. *Pathologie* 1995; **16**: 415-20.
18. Taratuta E, Krinsky G, Genega E, Roche K, Geneisier N. Pediatric inflammatory pseudotumor of the stomach: contrast-enhanced CT and MR imaging findings. *Am J Radiol* 1996; **167**: 919-20.
19. Glazer M, Sagar V. SPECT imaging of the spleen in inflammatory pseudotumor. Correlation with ultrasound, CT, and MRI. *Clin Nucl Med* 1993; **18**: 527-9.
20. Foschini MP, Scarpellini F, Rinaldi P, Mancini AF, Accinelli G, Eusebi V. Inflammatory pseudotumor of the urinary bladder. Study of 4 cases and review of the literature. *Pathologica* 1995; **87**: 653-8.
21. Vujanic GM, Berry PJ, Frank JD. Inflammatory pseudotumor of the kidney with extensive metaplastic bone. *Pediatr Pathol* 1992; **12**: 557-61.
22. Som PM, Brandwein MS, Maldijan C, Reino AJ, Lawson W. Inflammatory pseudotumor of the maxillary sinus: CT and MR findings in six cases. *Am J Radiol* 1994; **163**: 689-92.
23. Jenkins PC, Dickinson AE, Flanagan MF. Cardiac inflammatory pseudotumor: rapid appearance in an infant with congenital heart disease. *Pediatr Cardiol* 1996; **17**: 399-401.
24. Hytioglou P, Brandwein MS, Strauchen JA, Mirante JP, Urken ML, Biller HF. Inflammatory pseudotumor of the parapharyngeal space: Case report and review of the literature. *Head Neck* 1992; **14**: 230-4.
25. Georgia JD, Lawrence DP, DeNobile JW. Case report. Inflammatory pseudotumor in the retrorectal space: CT and MR appearance. *J Comput Assist Tom* 1996; **20**: 410-2.
26. Weiland TL, Scheithauer BW, Rock MG, Sargent JM. Inflammatory pseudotumor of nerve. *Am J Surg Pathol* 1996; **20**: 1212-8.
27. Hassan KS, Cohen HI, Hassan FK, Hassan SK. Unusual case of inflammatory myofibroblastic tumor associated with spontaneous splenic rupture. *World J Emerg Surg* 2010; **5**: 28.
28. DiFiore LW, Goldblum JR. Inflammatory myofibroblastic tumor of the small intestine. *J Am Coll Surg* 2002; **194**: 502-6.
29. Wreesmann V, van Eijck CH, Naus DC, van Velthuysen ML, Jeekel J, Mooi WJ. Inflammatory pseudotumor (inflammatory myofibroblastic tumor) of the pancreas: a case report of six cases associated with obliterative phlebitis. *Histopathology* 2001; **38**: 105-10.
30. Biselli R, Ferlini C, Fattorossi A, Boldrini R, Bosman C. Inflammatory myofibroblastic tumor (inflammatory pseudotumor): DNA flow cytometric analysis of nine pediatric cases. *Cancer* 1996; **77**: 778-84.
31. Hussong JW, Brown M, Perkins SL, Dehner LP, Coffin CM. Comparison of DNA ploidy, histologic and clinical outcome in inflammatory myofibroblastic tumors. *Mod Pathol* 1999; **12**: 279-86.
32. Tang TT, Segura AD, Oechler HW, Harb JM, Adair SE, Gregg DC, et al. Inflammatory myofibrohistiocytic proliferation simulating sarcoma in children. *Cancer* 1990; **65**: 1626-34.
33. Doski JJ, Priebe CJ, Driessnack M, Smith T, Kane P, Romero J. Corticosteroids in the management of unresected plasma cell granuloma (inflammatory pseudotumor) of the lung. *J Pediatr Surg* 1991; **26**: 1064-6.
34. Clifton MS, Pelayo JC, Cortes RA, Grethel EJ, Wagner AJ, Lee H, et al. Surgical treatment of childhood recurrent pancreatitis. *J Pediatr Surg* 2007; **42**: 1203-7.