

Metachronous Pancreatic Cancer Originating From Disseminated Founder Pancreatic Intraductal Neoplasias (PanINs)

Koji Imai,^{1‡} Hidenori Karasaki,^{2‡} Yusuke Ono,² Junpei Sasajima,³ Shin-ichi Chiba,⁴ Hiroshi Funakoshi,⁴ Miho Muraki,⁵ Hideki Hanaoka,⁵ Takahisa Furukawa,⁵ Hiroyuki Furukawa,¹ Toru Kono,² Kazuo Nagashima² and Yusuke Mizukami^{2,6*}

¹ Department of Surgery, Asahikawa Medical University, Asahikawa, Japan

² Laboratory of Clinical Bioinformatics, Center for Clinical and Biomedical Research, Sapporo Higashi Tokushukai Hospital, Sapporo, Japan

³ Department of Medicine, Asahikawa Medical University, Asahikawa, Japan

⁴ Center for Advanced Research and Education, Asahikawa Medical University, Asahikawa, Japan

⁵ Life Technologies Japan, Tokyo, Japan

⁶ Center for Cancer Research, Massachusetts General Hospital and Harvard Medical School, Boston, MA, USA

*Correspondence to: Yusuke Mizukami, Center for Clinical and Biomedical Research, Sapporo Higashi Tokushukai Hospital, 3-1, North-33, East-14, Higashi-Ku, Sapporo, Hokkaido, 065-0033, Japan, e-mail: ymizu.cabr@tohtoku.jp

Abstract

Clonal populations originated from benign-looking 'founder cells' may spread widely within pancreas instead of being localized *in situ* before frank pancreatic ductal adenocarcinoma (PDA) can be detected. Metachronous PDA is not common event, and we here sought to define potent origin of multiple PDAs developed in a woman using advanced genetics technologies. Curative resection of pancreatic head tumour was performed; however, 'recurrent' lesions in the remnant pancreas were found 3.5 years later and total pancreatectomy was subsequently performed. The metachronous lesions were morphologically similar to the primary PDA. Using a next-generation sequencing and digital PCR, all three PDAs were shown to possess rare somatic mutations in *KRAS* (p.T58I & p.Q61H). Curiously, identical *KRAS* mutations were found in low-grade 'intraepithelial' lesions, which localized in normal area of the pancreas and one of them possessed p53 mutation, which was also found in the PDAs. The footprint of the tumour evolution marked by mutational profiling supports a human correlate to the mouse models of 'dissemination' occurring at the earliest stages of pancreatic neoplasia.

Keywords: metachronous pancreatic cancer; pancreatic intraepithelial neoplasia; early dissemination; next-generation sequencing

Received 28 July 2014; accepted 22 October 2014

Conflict of interest: Several authors (MM, HH and TF) on this manuscript are employees of Life Technologies Japan, Inc., whose technology is used in this study.

[‡]These authors contributed equally to this work.

Introduction

Pancreatic ductal adenocarcinoma (PDA) has been a devastating disease with extremely poor survival even in patients undergoing potentially curative resections. Among the long-term survivor of PDAs, metachronous occurrence of invasive PDA in the remnant pancreas have recently been described [1–3]. It has been challenging to fully discriminate metachronous PDAs from 'intrapancreatic metastasis' [4]. Because of the limited number of cases and reliable

genetic markers, one could speculate if the multiple lesions were multicentric versus metastasis based on the clinical course and limited histological findings [5]. Previous studies demonstrate that given metachronous PDAs were 'metastasis' based on the sequence results showing identical *KRAS* mutation [1], still leaving the possibility of accidental concordance.

When multiple cancers located in the same or distant organ(s) are defined as 'monoclonal', those are generally considered as 'metastasis', whereas polyclonal lesions can develop from 'field defect'.

Here, we report a case with metachronous PDAs developed in remnant pancreas after the first resection of the primary tumour. In addition to precise pathological assessment, genetic approach indicated the high likelihood of 'early dissemination' as a unique pathogenesis of intra-pancreatic multiple cancers.

Methods

Samples and DNA extraction

PDAs as well as normal tissue (spleen) were manually dissected from 10 µm formalin-fixed paraffin-embedded (FFPE) sections (1–2 sections/tumour; supplementary material, Figure 1). Tumour cells from pancreatic intraepithelial neoplasia (PanIN), a precursor lesion of PDA, were microdissected using laser-capture microdissection system (PALM MB-III, ZEISS) to ensure that each tumour sample contained at least 90% neoplastic cells. The PanIN lesions were carefully selected to prevent contamination of the PDA cells and intraductal spreading lesions. DNA from the PanINs from each section was mixed together as pool sample (1–5 PanIN lesions per section and totally 12 PanINs; 4 PanIN-1a and 8 PanIN-1b lesions; see supplementary material, Figure 2 and Figure 2A). DNA was isolated using the QIAmp DNA FFPE tissue kit (Qiagen) and quantified and qualified using NanoDrop (Thermo) and Qubit2.0 (Life Technologies). Those samples were sufficient to obtain next-generation sequencing (NGS) data (supplementary material, Table 1).

DNA Sequencing

A detailed protocol for Sanger sequencing, Targeted Amplicon Sequencing using NGS and digital PCR assay is provided in the Supplementary Methods.

Result

A 58-year-old woman with complaint about obstructive jaundice was referred to Asahikawa Medical University Hospital in November 2005. The patient had no family history of PDA and pancreatitis. Computed tomography (CT) revealed a tumour in the head of the pancreas, 26-mm in diameter, directly invading the superior mesenteric vein (SMV; supplementary material, Figure 3). In December 2005, we performed a pylorus-preserving pancreaticoduodenectomy with resection of the SMV, in combination

with an intraoperative radiation therapy targeting retroperitoneal cavity adjacent to the tumour (20 Gy). Pathological diagnosis was moderately differentiated adenocarcinoma (UICC; T3N1M0 Stage IIB) and no viable tumour cell was evident on the resection margin (Figure 1 and supplementary material, Figure 1). Adjuvant chemotherapy using gemcitabine was performed for 6 months.

In May 2009, CT scan demonstrated 'recurrent' lesions in the body and tail of the remnant pancreas (supplementary material, Figure 4). Retrospectively, these tumours could be pointed out by the serial CT scans performed after the surgery; emergence of the mass in the body of the pancreas in August 2008 was preceded by tumour in the pancreatic tail, which was first recognized in May 2008.

Total pancreatectomy was then performed in June 2009 without radiographic evidence of distant metastasis. The second (in the pancreatic tail) and third lesion (in the body of the pancreas) were histologically similar to the primary lesion developed in the head of the pancreas (Figure 2 and supplementary material, Figures 1 and 2). S-1 was administered for the second adjuvant chemotherapy; however, lung metastasis and peritoneal dissemination were evident 17 months after the second resection. The patient died from the metastatic disease in 66 months and 24 months after initial and second resection, respectively.

We sought to characterize the three PDAs developed in the current case, since metachronous PDA is not a common event and only limited cases were previously reported [1,2]. First, Sanger sequencing was performed for genotyping *KRAS*, a major driver for PanIN/PDA and intraductal papillary mucinous neoplasm (IPMN) of the pancreas, and *GNAS*, which is frequently mutated in IPMNs [6]. Neither mutations in *KRAS* (codon 12&13) nor *GNAS* (codon 201&227) was identified in the tumours (data not shown). To further define the genetic profile of larger number of tumour-associated mutations, NGS was then used. Sequencing of PCR-amplified fragments-containing multiple mutation sites on known tumour-related genes was conducted to detect and quantitate mutated alleles using a multigene NGS panel (Supplementary Table 1).

All three PDAs possessed exactly identical *KRAS* mutations in codon 58 (COSM87288; p.T58I) and codon 61 (COSM554; p.Q61H) (Figure 1 and supplementary material, Table 2). The double mutation in *KRAS* was also demonstrated in the primary PDA by Sanger sequence (supplementary material, Figure 5). Curiously, the double mutations in *KRAS* p.T58I and p.Q61H were found in a single allele and considered

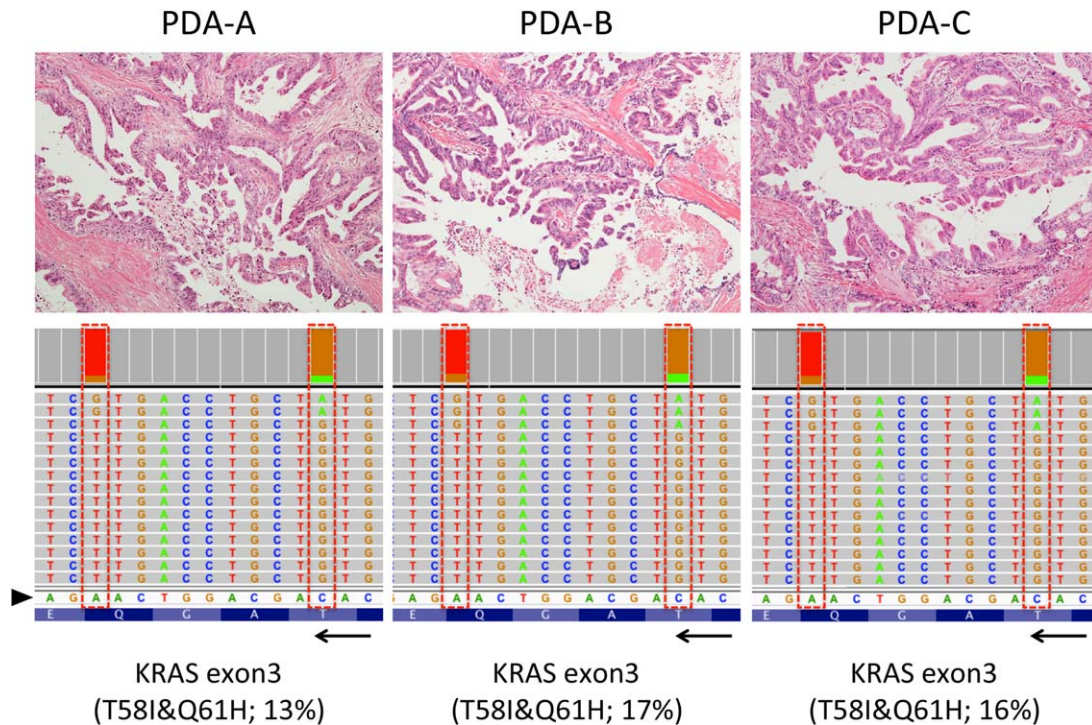


Figure 1. Representative histology and *KRAS* mutation pattern in three metachronous PDAs. Histologies of the three PDAs are shown (top panels; original magnifications, $\times 10$ objective). All three tumours were moderately differentiated adenocarcinoma with papillary proliferation of cancer cells. Each sample shows the representation of the reads aligned to the reference genome in the *KRAS* genes (displayed as reverse-complement of Exon 3; bottom panels). Arrowhead and arrow indicate of forward sequences of *KRAS* gene and its direction ($3' < 5'$). Those histologically similar lesions possessed unique haplotype in *KRAS* (p.T58I&p.Q61H) analysed separately using NGS.

as haplotype. The presence of mutant *KRAS* allele was detected by digital PCR using specific probe targeting p.T58I and p.Q61H (supplementary material, Figure 6), confirming that a single allele possessed both mutations.

Additional somatic mutation in *p53* at codon 175 (COSM10648; p.R175H) was shared by all PDAs and secondly developed lesion in the pancreatic tail was shown to possess mutation in *VHL* and *Smad4* albeit at low frequency. Other unique mutations including tumour suppressor genes associated with PDA/IPMN such as *SMARCA4* [7] and *RNF43* [8] were not identified (data not shown).

Finally, we thought to determine if the precursor lesions pathologically identified in the 'normal' pancreas surrounding primary PDA resected in 2005 also have the unique mutations in *KRAS* (Figure 2 and supplementary material, Figure 2). As summarized in supplementary material, Table 2, the double *KRAS* mutation in codon 58&61 was found in PanIN samples from 2 of 5 sections analyzed (PanIN-D and -E). Although their variant frequency was very small (3–11%), the haplotype in *KRAS* was verified

by digital PCR (supplementary material, Figure 6). One of the two samples also have mutation in *p53* (p.R175H), whereas others were shown to possess wild-type *p53*.

Discussion

It has been reported that intraglandular metastasis of PDA was found in about 5% of cases in the study using over 300 cases and overall survival and disease-free survival for patients with the 'synchronous' PDA were significantly shorter than for those with single lesion [9]. Despite of the histological imitation observed in the three PDAs in the current case, we hesitated to consider that the recurrent lesions directly metastasized from the first primary tumour because of the following reasons; recurrent lesions were evident more than 3 years after the resection of the primary tumour, surgical margin on the pancreas was negative for viable cancer cells at the time of first resection, and the second tumour developed in a

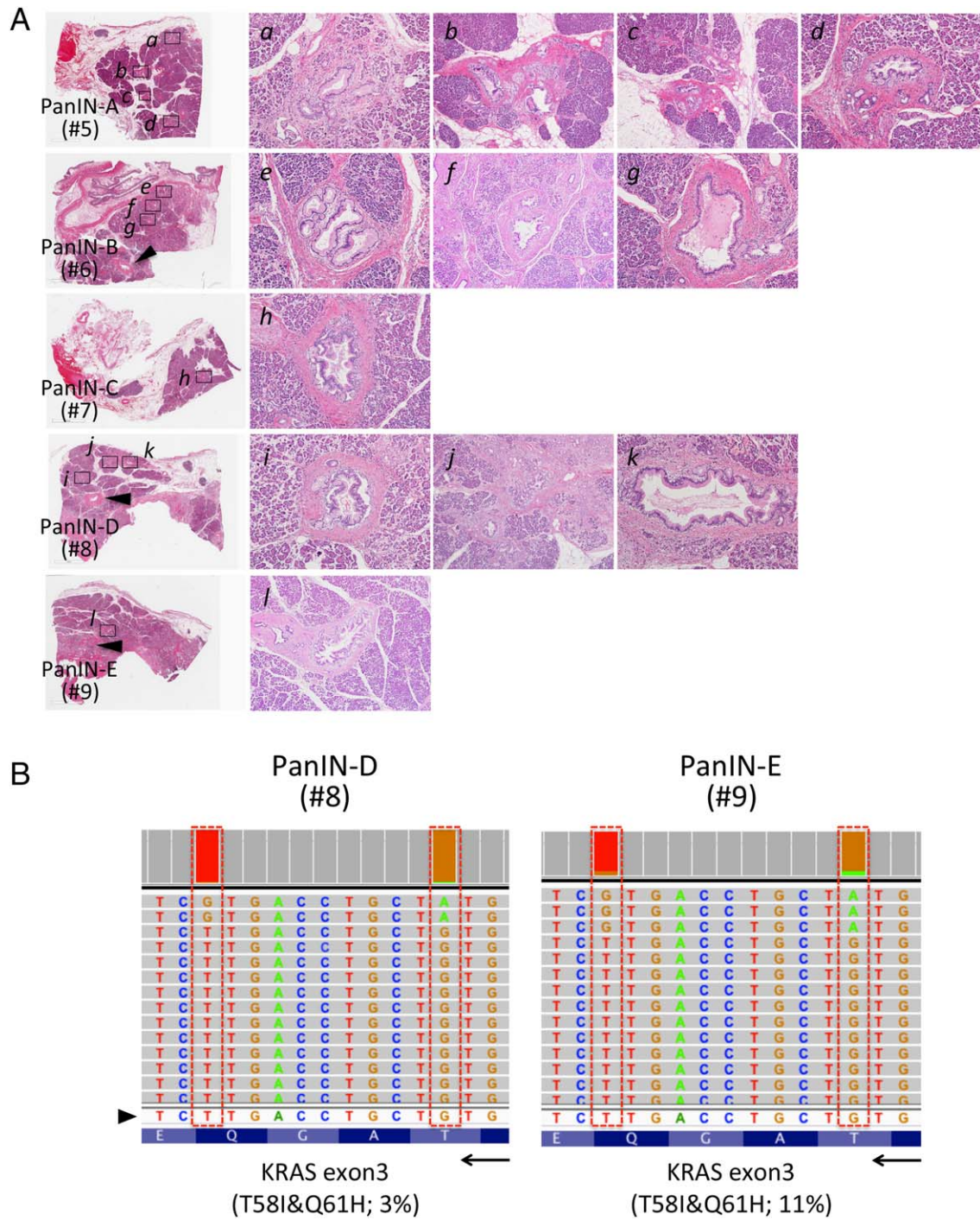


Figure 2. Assessment of intraductal atypical lesions pathologically identified in the 'normal' pancreas surrounding first primary tumour. (A) Normal areas of the resected specimen apart from PDA were used to seek low-grade PanINs surrounding the invasive PDA in the head of the pancreas and five sections were selected (A–E; given numbers indicate sample IDs for the NGS-targeted sequencing; see supplementary material, Table 1 and supplementary material, Figure 2). Pool DNA samples were isolated using laser-captured microdissected PanIN lesions from five sections (PanIN-A–E) covering normal pancreas. Sufficient amount of DNA could be isolated from 1 to 5 PanIN lesions per slide (*a*–*l*; 4 PanIN-1a and 8 PanIN-1b lesions). Arrowheads in H&E staining (PanIN-D and E) indicate main-pancreatic duct. Original magnifications are $\times 10$ objective for *a*, *c*, *e*, *g*, *h*, *i*, *k* and $\times 4$ for *b*, *f*, *j*, *l*. (B) Representative of the reads aligned to the reference genome in the *KRAS* genes (displayed as reverse-complement of Exon 3) are shown. Arrowhead and arrow indicate of forward sequences of *KRAS* gene and its direction ($3' < 5'$). Pool DNA samples from PanIN-D and -E possessed the double mutation in *KRAS* (p.T58I&p.Q61H).

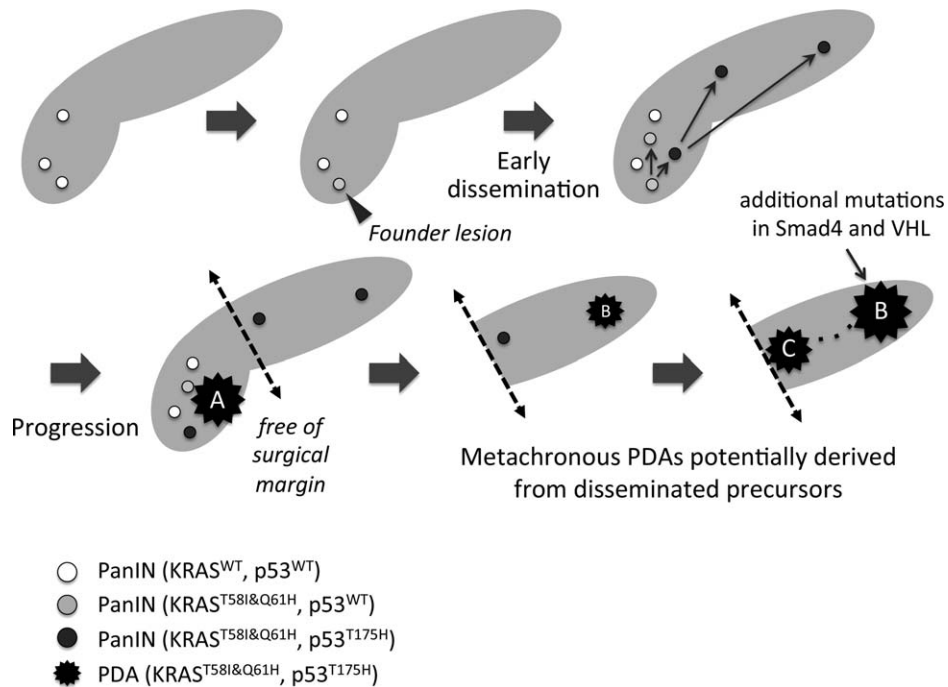


Figure 3. Proposed progression model from multiple PanINs. Early precursor lesions (PanINs) with wild-type *KRAS* emerged to create field of cancer, and some of them acquired oncogenic *KRAS*, p.T58I and p.Q61H (Founder lesion). Additional somatic mutation in *p53* p.T175H occurred in part of the PanINs with the unique *KRAS* haplotype, which may in turn spread into other area of the pancreas ('early dissemination' indicated by arrows). One of them progressed into invasive PDA (PDA-A), which was resected by the Whipple's procedure with negative surgical margin. However, other disseminated precursors independently progressed to form other PDAs in the tail (PDA-B) and body (PDA-C) of the pancreas, finally connecting each other through main pancreatic duct (dotted line). In addition to the typical mutations in *KRAS* and *p53*, PDA-B has other somatic mutations in *Smad4* and *VHL*.

geographically distant site from the primary tumour. Therefore, 'local recurrence' due to microscopic residual tumour cells during the first resection was unlikely. Actually, larger number of mutations was found in the second lesion; however, newer third lesion possessed no more mutation relative to the primary tumour implying that these recurrent lesions independently developed. In addition, careful pathological assessment identified the multiple PanINs in the 'normal' pancreas adjacent to the primary tumour (Figure 1), suggesting that multiple precursors could be widely distributed to the entire pancreas.

KRAS mutation is a major 'driver' for PanIN/PDA and IPMN [10]. Different pattern of *KRAS* mutation would strongly support multicentric occurrence of the three PDAs. However, we found that all PDAs developed in the current case has identical mutations in *KRAS* (p.T58I&p.Q61H), both of which have been shown to act as driver and play a role in drug resistance [11,12]. Because of extreme rarity of identical combination of double *KRAS* mutations in a single allele, it is reasonable to speculate that the metachronous PDAs may be derived from a common 'founder

lesion' [13] rather than independently initiated within a 'field defect'. In addition to the intrapancreatic lesions, metastatic disease in other organs developed in the current case and targeted sequencing of these samples could determine if the rare *KRAS* alleles (or other mutations) are present and support the model of clonal relationship to a founder cell [14,15].

Among the genetically heterogeneous PanIN populations marked by NGS-assay in the current case, we specifically focused on the 'precursors' with unique mutation in *KRAS* (p.T58I&p.Q61H) (Figure 2). One of the PanINs also possessed *p53* mutation (p.R175H), which is again shared by the PDAs. *p53*^{R175H} provides tumour cells gain-of-function that inactivates ATM-dependent DNA damage responses, which facilitates to overcome *KRAS*-induced senescence and ultimately promote metastasis [16]. It should be noted that those PanINs were apart from the invasive front of the primary PDA and intraductal extension was excluded because of their low-grade of atypia (PanIN1a-1b). Therefore, the PanIN with the unique *KRAS* mutations and *p53*^{R175H} could be the 'founder lesion' of given metachronous PDAs (proposed model is shown in

Figure 3). The progression model supports the notion that the three PDAs potentially originated from the precursors disseminated during earlier stages rather than metastasized from the established PDA.

A model of 'early dissemination' in which epithelial-to-mesenchymal transition (EMT) and dissemination can precede frank tumour formation was demonstrated by lineage-labelling system using genetically engineered mouse [17]. Earlier study showed that tumour cells can leave the primary tumour before mutations of the *p53* gene occur, supporting haematogenous dissemination of neoplastic cells can occur even without losing tumour suppressors [18]. Additionally, recent human study also demonstrated that naive pancreatic tumour cells, which do not have invasive property, can spread into circulation [19]. In the current report, we presented precise pathological and genetic assessments strongly implying migration/dissemination of such 'benign-looking' PDA precursor cells within pancreas in human. Focal immunostaining of EMT factors such as Snail and integrin-linked kinase was demonstrated in low-grade PanINs albeit at low frequency relative to PDA [20], supporting the ability of these precursors to migrate into circulation and ultimately form metastatic foci. In addition, a longitudinal monitoring of EMT and mesenchymal-to-epithelial transition (MET) features has been demonstrated in circulating tumor cells (CTCs) [21]. Therefore, naive circulating 'precursor' cells may represent MET during migration process from circulation to the duct epithelial lining.

Prevalence of high-grade PanINs in patients underwent surgical resection of PDA is considered as risk for the post-operative recurrence [22], and patients underwent pancreatectomy for chronic pancreatitis sometimes developed disseminated PDA although only PanINs and no tumours were found on histologic analysis [23]. Therefore, the incidental PanINs can generally be observed in classic PDA; however, the significance on their outcome is still controversial [24] and further studies are required. In the current case, we identified 'low-grade PanIN' with *KRAS* and *p53* mutation, and presence of such a microscopic lesion with two genetic hits may potentially be a factor predicting recurrence caused by development of metachronous cancer(s).

In conclusion, unique *KRAS* mutations (p.T58I&p.Q61H) were identified in the metachronous PDAs in the current case. Surprisingly, the identical mutations were also found in independent low-grade 'intraepithelial' lesions with and without additional mutation in *p53*, highlighting an alternative mode of tumour progression through 'early disseminations'. Since PDAs

are occasionally accompanied with multiple microscopic lesions in radiographically normal pancreas, precise genetic profiling of these incidental lesions will be demanded.

Acknowledgements

The authors are thankful to the late Dr. Yoshihiko Tokusashi who was outstanding pathologist in Asahikawa Medical University and supported precise pathological assessment of the resected specimens. The authors also thank Eiko Aoyanagi and Yuji Fukuda for tissue section preparation; Munehiko Ogata for nucleic acid purification; and Manish K. Gala and Tomoki Yokochi for helpful discussion.

Grant support

Supported by grants from the Ministry of Education, Science, Sports, and Culture of Japan (25461029 to Y.M.), Pancreas Research Foundation in Japan (to Y.M.), Akiyama Life Science Foundation (to Y.M.) and Andrew Warshaw Institute for Pancreatic Cancer Research (to Y.M.).

Author contributions

KI, acquisition of data; HK, study concept and design, and drafting of the manuscript; YO, analysis and interpretation of data; JS, critical revision of the manuscript for important intellectual content; SC, acquisition of data; HF, study supervision; MM, acquisition of data; HH, administrative, technical, or material support; TF, study supervision; HF, study supervision; TK, analysis and interpretation of data; KN, study supervision; YM, study concept and design, and critical revision of the manuscript for important intellectual content.

References

1. Wada K, Takada T, Yasuda H, *et al.* A repeated pancreatectomy in the remnant pancreas 22 months after pylorus-preserving pancreatoduodenectomy for pancreatic adenocarcinoma. *J Hepatobiliary Pancreat Surg* 2001; **8**: 174–178.
2. Kleeff J, Reiser C, Hinz U, *et al.* Surgery for recurrent pancreatic ductal adenocarcinoma. *Ann Surg* 2007; **245**: 566–572.
3. Miyazaki M, Yoshitomi H, Shimizu H, *et al.* Repeat pancreatectomy for pancreatic ductal cancer recurrence in the remnant pancreas after initial pancreatectomy: is it worthwhile? *Surgery* 2014; **155**: 58–66.

4. Izumi S, Nakamura S, Mano S, et al. Resection of four synchronous invasive ductal carcinomas in the pancreas head and body associated with pancreatic intraepithelial neoplasia: report of a case. *Surg Today* 2009; **39**: 1091–1097.
5. Dalla Valle R, Mancini C, Crafa P, et al. Pancreatic carcinoma recurrence in the remnant pancreas after a pancreaticoduodenectomy. *JOP* 2006; **7**: 473–477.
6. Wu J, Matthaei H, Maitra A, et al. Recurrent GNAS Mutations Define an Unexpected Pathway for Pancreatic Cyst Development. *Sci Transl Med* 2011; **3**: 92ra66.
7. Shain AH, Giacomini CP, Matsukuma K, et al. Convergent structural alterations define SWI/SNF chromatin remodeler as a central tumor suppressive complex in pancreatic cancer. *Proc Natl Acad Sci USA* 2012; **109**: E252–E259.
8. Wu J, Jiao Y, Dal Molin M, et al. Whole-exome sequencing of neoplastic cysts of the pancreas reveals recurrent mutations in components of ubiquitin-dependent pathways. *Proc Natl Acad Sci USA* 2011; **108**: 21188–21193.
9. Oguro S, Shimada K, Ino Y, et al. Pancreatic intraglandular metastasis predicts poorer outcome in postoperative patients with pancreatic ductal carcinoma. *Am J Surg Pathol* 2013; **37**: 1030–1038.
10. Izawa T, Obara T, Tanno S, et al. Clonality and field cancerization in intraductal papillary-mucinous tumors of the pancreas. *Cancer* 2001; **92**: 1807–1817.
11. Agarwal A, Eide CA, Harlow A, et al. An activating KRAS mutation in imatinib-resistant chronic myeloid leukemia. *Leukemia* 2008; **22**: 2269–2272.
12. Bettegowda C, Sausen M, Leary RJ, et al. Detection of circulating tumor DNA in early- and late-stage human malignancies. *Sci Transl Med* 2014; **6**: 224ra224.
13. Yachida S, Jones S, Bozic I, et al. Distant metastasis occurs late during the genetic evolution of pancreatic cancer. *Nature* 2010; **467**: 1114–1117.
14. Forshew T, Murtaza M, Parkinson C, et al. Noninvasive identification and monitoring of cancer mutations by targeted deep sequencing of plasma DNA. *Sci Transl Med* 2012; **4**: 136ra168.
15. Gerlinger M, Rowan AJ, Horswell S, et al. Intratumor heterogeneity and branched evolution revealed by multiregion sequencing. *N Engl J Med* 2012; **366**: 883–892.
16. Liu DP, Song H, Xu Y. A common gain of function of p53 cancer mutants in inducing genetic instability. *Oncogene* 2010; **29**: 949–956.
17. Rhim AD, Mirek ET, Aiello NM, et al. EMT and dissemination precede pancreatic tumor formation. *Cell* 2012; **148**: 349–361.
18. Offner S, Schmaus W, Witter K, et al. p53 gene mutations are not required for early dissemination of cancer cells. *Proc Natl Acad Sci USA* 1999; **96**: 6942–6946.
19. Rhim AD, Thege FI, Santana SM, et al. Detection of circulating pancreas epithelial cells in patients with pancreatic cystic lesions. *Gastroenterology* 2014; **146**: 647–651.
20. Schaeffer DF, Assi K, Chan K, et al. Tumor expression of integrin-linked kinase (ILK) correlates with the expression of the E-cadherin repressor snail: an immunohistochemical study in ductal pancreatic adenocarcinoma. *Virchows Arch* 2010; **456**: 261–268.
21. Yu M, Bardia A, Wittner BS, et al. Circulating breast tumor cells exhibit dynamic changes in epithelial and mesenchymal composition. *Science* 2013; **339**: 580–584.
22. Frankel TL, LaFemina J, Bamboat ZM, et al. Dysplasia at the surgical margin is associated with recurrence after resection of non-invasive intraductal papillary mucinous neoplasms. *HPB* 2013; **15**: 814–821.
23. Sakorafas GH, Sarr MG. Pancreatic cancer after surgery for chronic pancreatitis. *Dig Liver Dis* 2003; **35**: 482–485.
24. Hassid BG, Lucas AL, Salomao M, et al. Absence of pancreatic intraepithelial neoplasia predicts poor survival after resection of pancreatic cancer. *Pancreas* 2014; **43**: 1073–1077.

SUPPLEMENTARY MATERIAL ON THE INTERNET

Additional Supporting Information may be found in the online version of this article.

Supplementary Figure 1. Gross appearance of the resected pancreas.

Supplementary Figure 2. Assessment of intraductal atypical lesions pathologically identified in the “normal” pancreas surrounding first primary tumour resected.

Supplementary Figure 3. Imaging diagnosis of the primary pancreatic ductal adenocarcinoma (PDA).

Supplementary Figure 4. Serial CT images during post-operative follow up.

Supplementary Figure 5. DNA Sanger Sequencing confirming *KRAS* mutations in codon 58 and 61.

Supplementary Figure 6. Droplet digital PCR confirming haplotype mutation in *KRAS* p.T58I and p.Q61H.