

Scapular stress fracture initially masquerading as tumor or infection

Michael J. J. Kim, MD; Lawrence A. Rinsky, MD; and John D. MacKenzie, MD

We present a case of a scapular stress fracture in a 17-year-old athletic male that was initially thought to be a neoplasm. Radiographs showed a lesion at the neck of the glenoid with aggressive features. A subsequent MRI and bone scan supported a diagnosis of either tumor or infection. However, before a scheduled bone biopsy, a screening chest CT for pulmonary metastases revealed features of a healing stress fracture. The patient ceased intense athletic activity and four weeks later experienced a continued decrease in shoulder symptoms. A followup shoulder CT confirmed a healing fracture. This case illustrates how a stress fracture at an uncommon location may mimic a neoplasm. CT provides complementary information to radiography and MRI and helps establish a definitive diagnosis.

Introduction

Scapular stress fractures are rare (approximately 1% of all fractures) and occur much less frequently than stress fractures involving the lower extremity. Because scapular fractures are usually the result of high-energy trauma, acute scapular fractures are often associated with other osseous and soft-tissue injuries in the chest (1). Scapular *stress* fractures, on the other hand, typically occur as a result of chronic repetitive activities involving the shoulder (2). Stress fractures and neoplastic processes may sometimes appear similarly on radiographs, particularly during the healing phase of a fracture or avulsion injury (3). As histologic specimens of healing stress fractures may be misinterpreted as bone tumors, a multimodality approach is important in order to avoid false-positive bone biopsies. We present a case of a scapular stress fracture that was initially thought to represent a neoplasm or infection based on ra-

diographic, nuclear medicine, and MRI findings. Subsequent CT exam, as well as improving clinical symptoms, obviated a potentially confounding bone biopsy.

Case report

A 17-year-old high-school football player fell on his shoulder during practice. When the pain continued for several weeks, the boy saw his primary-care physician, who obtained radiographs that showed a mixed lytic and sclerotic lesion at the inferior border of the body of the scapula with adjacent, disorganized, new bone formation (Fig. 1). These aggressive features prompted further evaluation with MR imaging, which showed a large region of bone-marrow edema and adjacent periostitis that was suspicious for Ewing sarcoma, lymphoma, or infection (Figs. 2A and 2B). The only abnormal activity on bone scan was increased uptake in the body of the scapula.

The youth continued to lift weights and participate in football despite the persistent shoulder pain that was somewhat decreased by the time of his scheduled bone biopsy one week following the MRI. One hour before the biopsy, a screening chest CT for pulmonary metastasis showed smooth periosteal reaction around the inner and outer surfaces of the scapula (Fig. 3A), which would be atypical for an aggressive bone neoplasm. Reformatted coronal oblique images of the scapula also showed a fracture line as an oblique linear lucency through the neck of the scapula (Fig. 3B).

Given the chest CT findings and the patient's slight symptomatic improvement, the biopsy was deferred. The

Citation: Kim MJJ, Rinsky LA, MacKenzie JD. Scapular stress fracture initially masquerading as tumor or infection. *Radiology Case Reports*. (Online) 2011;6:510.

Copyright: © 2011 The Authors. This is an open-access article distributed under the terms of the Creative Commons Attribution-NonCommercial-NoDerivs 2.5 License, which permits reproduction and distribution, provided the original work is properly cited. Commercial use and derivative works are not permitted.

Dr. Kim is in the Department of Radiology at Stanford Hospital, Stanford CA. Dr. Rinsky is Chief of Pediatric Orthopedic Surgery at Lucile Packard Children's Hospital, Palo Alto CA. Dr. MacKenzie is Chief of Pediatric Radiology at the University of California San Francisco. Contact Dr. Kim at mjjkim@gmail.com.

Competing Interests: The authors have declared that no competing interests exist.

DOI: 10.2484/rcr.v6i4.510

Scapular stress fracture initially masquerading as tumor or infection

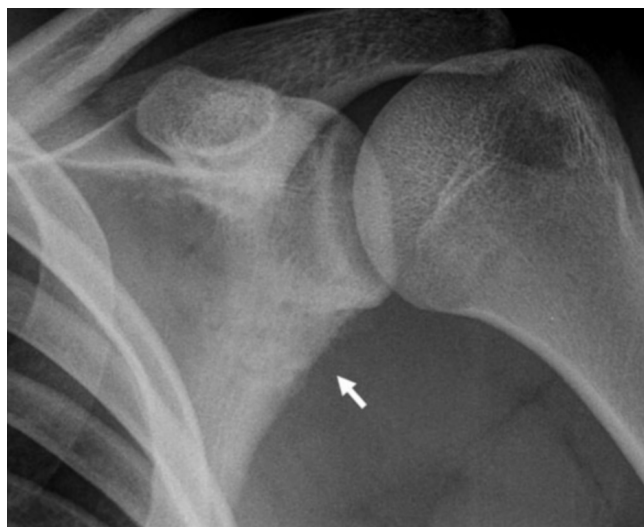

Figure 1. 17-year-old male with scapular stress fracture. Radiograph of the shoulder shows lesion in the scapula with aggressive features including lysis of the inferior border of the body of the scapula and adjacent new bone formation (arrow).

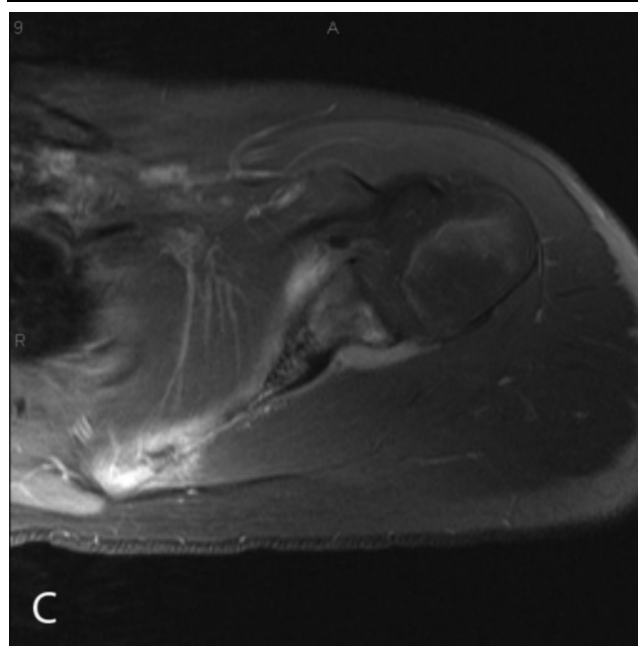
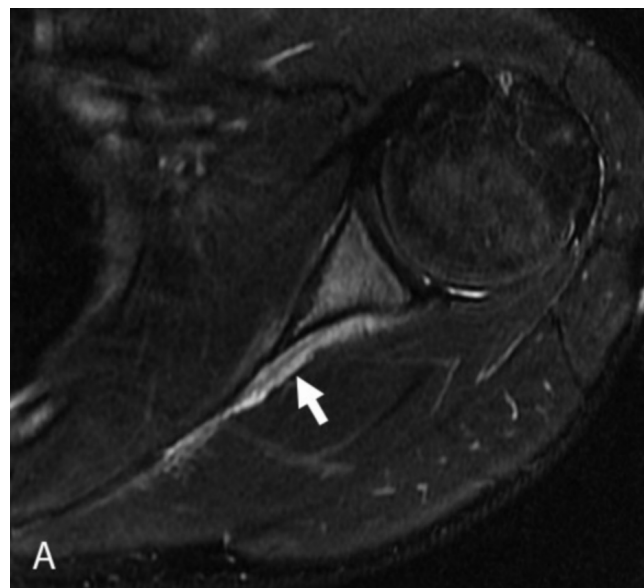
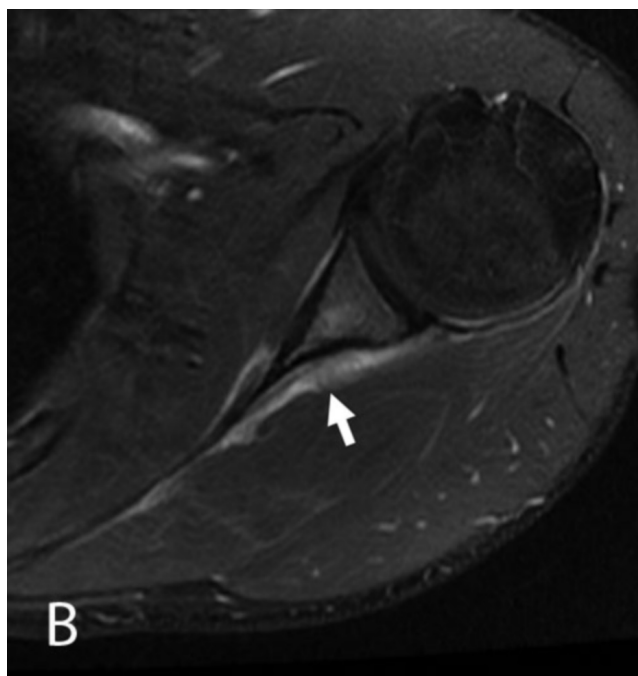


Figure 2. 17-year-old male with scapular stress fracture. Comparison of a healing fracture (A and B) and lymphoma of the scapula (C) both in two separate 17-year-old-males. Axial imaging through the scapula in the youth with the healing fracture shows marrow edema and enhancement with periosteal reaction throughout the scapula. (A) T2-weighted, fat-saturated image shows increased signal intensity in the marrow cavity and periosteal reaction (arrow). (B) T1-weighted, fat-saturated imaging shows enhancement of the marrow and periosteum. A second male with lymphoma of the scapula shows similar findings on enhanced T1-weighted, fat-saturated imaging (C).

Scapular stress fracture initially masquerading as tumor or infection

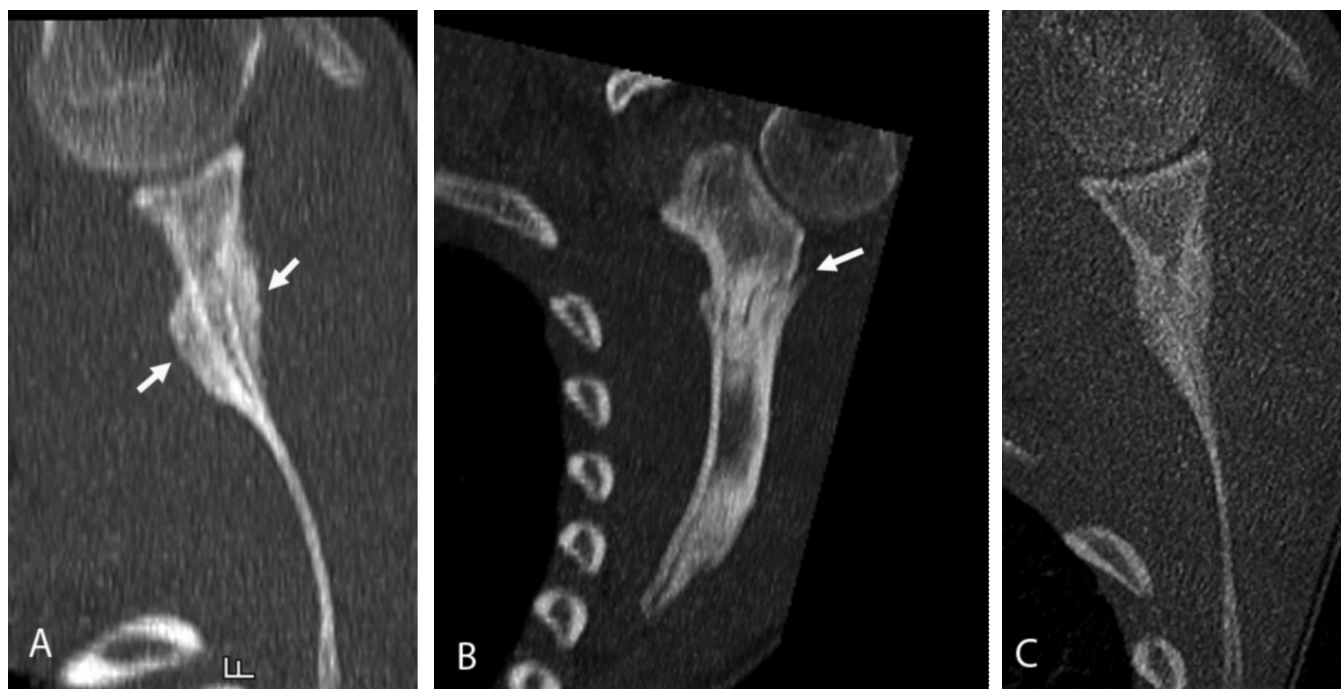


Figure 3. 17-year-old male with scapular stress fracture. CT with bone-reconstruction algorithm shows a nonaggressive lesion with smooth periosteal reaction along the margins of the fracture (arrows in A). An oblique reformatted image reveals the fracture line as an oblique lucency through the neck of the scapula (arrow in B). A followup shoulder CT four weeks later shows interval healing of the stress fracture (C).

patient was instructed to cease all athletic activity for four weeks and then return for a repeat chest CT, which confirmed healing of the fracture.

Discussion

In contrast to acute scapular fractures that occur secondary to high-energy trauma (for example, motor vehicle accidents) (4), scapular stress fractures usually result from repetitive activities. The stress fracture often coincides with the initiation of a new exercise program and is usually seen in athletes. Scapular stress fractures are rare, with 12 reported cases found in a recent review of the literature.

These reported cases of scapular stress fractures either involved repetitive activity of high intensity (for example, professional football or cricket) or occurred with the new onset of lower-level repetitive activity (for example, a jogger using hand weights or a pre-operative hip-replacement patient ambulating with a cane). None of the previously reported cases in the literature presented as diagnostic dilemmas. All of these patients either had diagnostic radiographs or clinical histories highly suggestive of stress fracture, and in those with clinical followup, symptoms resolved after several weeks to several months.

The scapular stress fracture in our patient was associated with the beginning of the high-school football season. During summer training camp, he participated in intense daily practices and a heavy weightlifting regimen. Children and young adults may not recall the initial injury or attempt to

play through their pain. This contributes to a more complex clinical presentation and complicates the imaging appearance of fractures due to delayed healing.

The clinical presentation in this case was compatible with both stress fracture and neoplasm. Although the initial radiograph and MRI suggested an aggressive process, fractures (particularly during the early phases of healing) may be mistaken for more aggressive processes such as tumor or infection (3). The aggressive appearance of the healing fracture on the initial radiographs was consistent with the clinical history of insidious and persistent pain, coupled with the possibility that the initial injury was a “red herring” for an underlying tumor. A biopsy of this fracture may have further contributed to a misdiagnosis, since biopsies of healing fractures may yield pathological results that are difficult to distinguish from a primary bone tumor (5).

This case illustrates how serial and multimodality imaging may help distinguish between a healing fracture and malignancy. Radiographic and CT imaging features that support a diagnosis of an aggressive bone lesion include evidence of cortical destruction, adjacent soft-tissue mass, indistinct margins, wide zone of transition, and a disorganized intralesional matrix (6). In this case, radiographs, MRI, and bone scan suggested an aggressive process. The CT was clearly the most specific of the four modalities in this case. These imaging modalities are complementary and may at times provide discordant information in the evaluation of stress fractures. When clinical history is ambiguous,

Scapular stress fracture initially masquerading as tumor or infection

and neoplasm is on the differential diagnosis, conservative management and serial and/or multimodality imaging may help pinpoint the diagnosis and avoid a potentially confounding bone biopsy.

References

1. Goss TP, Owens BD (2009) Fractures of the scapula. In: Rockwood CA, Matsen RA (eds) *The shoulder*. Saunders, pp 333-380.
2. Brukner P (1998) Stress fractures of the upper limb. *Sports Med* 26:415-424. [[PubMed](#)]
3. Horev G, Korenreich L, Ziv N, et al. (1990) The enigma of stress fractures in the pediatric age: clarification or confusion through the new imaging modalities. *Pediatr Radiol* 20:469-471. [[PubMed](#)]
4. McGahan JP, Rab GT, Dublin A (1980) Fractures of the scapula. *J Trauma* 20:880-883. [[PubMed](#)]
5. Resnick JM, Carrasco CH, Edeiken J, et al. (1996) Avulsion fracture of the anterior inferior iliac spine with abundant reactive ossification in the soft tissue. *Skeletal Radiol* 25:580-584. [[PubMed](#)]
6. Madewell JE, Ragsdale BD, Sweet DE (1981) Radiologic and pathologic analysis of solitary bone lesions. Part I: internal margins. *Radiol Clin North Am* 19:715-748. [[PubMed](#)]