


Intertrochanteric Fracture of the Femur in an Ankylosed Hip: A Case Report*

Fratura intertrocantérica do fêmur em um quadril anquilosado: Relato de caso

Pramod Devkota¹  Shiraz Ahmad¹ Ketan C. Pande²

¹Department of Orthopedics and Trauma Surgery, Suri Seri Begawan Hospital, Kuala Belait, Brunei Darussalam

²Department of Orthopedics and Trauma Surgery, RIPAS Hospital, Bandar Seri Begawan, Brunei Darussalam

Address for correspondence Pramod Devkota, MBBS, MS, Department of Orthopaedics and Trauma Surgery, Suri Seri Begawan Hospital Kuala Belait, Belait District, Brunei Darussalam (e-mail: devkotap@gmail.com).

Rev Bras Ortop 2019;54:736–738.

Abstract

Keywords

- ▶ ankylosis
- ▶ femoral fractures
- ▶ fracture fixation
- ▶ hip joint
- ▶ bone screws

Resumo

Palavras-chave

- ▶ anquilose
- ▶ fraturas do fêmur
- ▶ fixação de fratura
- ▶ articulação do quadril
- ▶ parafusos ósseos

Intertrochanteric fractures of the femur in ankylosed hips are extremely rare. The aims of the operative management for elderly patients with intertrochanteric fractures are to prevent general complications, to maintain mobility, and to relieve pain. The optimal management to achieve these goals is not clear. The authors present a case of a 74-year-old man with an intertrochanteric fracture of the femur in an ankylosed hip. The fracture was managed surgically with dynamic hip screws and cannulated screws. Two years after the surgery, good union was observed at the fracture, and the patient was ambulating independently.

A fratura intertrocantérica do fêmur em um quadril anquilosado é extremamente rara. O objetivo do manejo operatório em idosos com fraturas intertrocantéricas é prevenir complicações gerais, manter a mobilidade, e aliviar a dor. O manejo ideal para atingir tal objetivo não é claro. Os autores apresentam o caso de um paciente do sexo masculino de 74 anos com fratura intertrocantérica do fêmur em um quadril anquilosado. A fratura foi tratada cirurgicamente com parafuso de quadril dinâmico e parafuso canulado. Dois anos após a cirurgia, observou-se boa união na fratura, e o paciente deambula de forma independente.

Introduction

The incidence of hip fracture has been increasing as the population ages, and about 50% of hip fractures are intertrochanteric fractures.¹ Surgical management is generally the ideal treatment for elderly patients with intertrochanteric fractures, and the aims of it are to prevent general complications, to maintain mobility, and to relieve pain.²

Only a few cases have been reported in the literature regarding intertrochanteric fractures of the femur with an ankylosed hip,^{2,3} therefore, there is little available information in the literature regarding these fractures in ankylosed hip joints.

We report a case of intertrochanteric fracture of the femur in an ankylosed hip treated by dynamic hip screws (DHSs).

* Paper developed at the Department of Orthopedics and Trauma Surgery, Suri Seri Begawan Hospital, Kuala Belait, Brunei Darussalam. Originally published by Elsevier.

received
October 1, 2017
accepted
November 23, 2017

DOI <https://doi.org/10.1016/j.jrboe.2017.11.016>
ISSN 0102-3616.

Copyright © 2019 by Sociedade Brasileira de Ortopedia e Traumatologia. Published by Thieme Revinter Publicações Ltda, Rio de Janeiro, Brazil

License terms



Case Report

A 74-year-old man presented to the accident and emergency department with pain on the right hip since one day after a fall. Upon examination, there was tenderness on the right greater trochanteric region and inability to actively raise the right lower limb. Mild swelling was present on the right intertrochanteric region with some ecchymosis. No radiating pain and numbness were present, and the patient was not able to walk or to bear weight due to pain.

He had been operated on the right hip about 20 years before, and had since then been walking with the aid of a walker and limping. The patient was being treated for hypertension and hyperlipidemia. He had also been submitted to treatment for a colon cancer a few years back.

The muscles around the hip region were atrophic. The radiograph of the pelvis showed avascular necrosis with doubtful infective features on the femoral head, with the presence of an ankylosed hip. A small plate was observed in

situ on the acetabular region with a non-displaced fracture of the intertrochanteric region of the femur (► Fig. 1).

The fracture was treated with dynamic hip screws (DHSs) and one cannulated screw fixing the acetabulum. The patient was discharged home on the 21st post-operative day, and he was advised not to bear weight for six weeks postoperatively. Partial weight-bearing was allowed after the seventh week, and the patient started to walk bearing his full weight three months after the surgery. The patient was on regular follow-up, and 18 months after the operation, the fracture had united, and he was satisfied with the outcome (► Fig. 2).

Discussion

Intertrochanteric fractures of the femur in ankylosed hips are extremely rare, and there are only a few cases reported in the literature. The non-operative management is associated

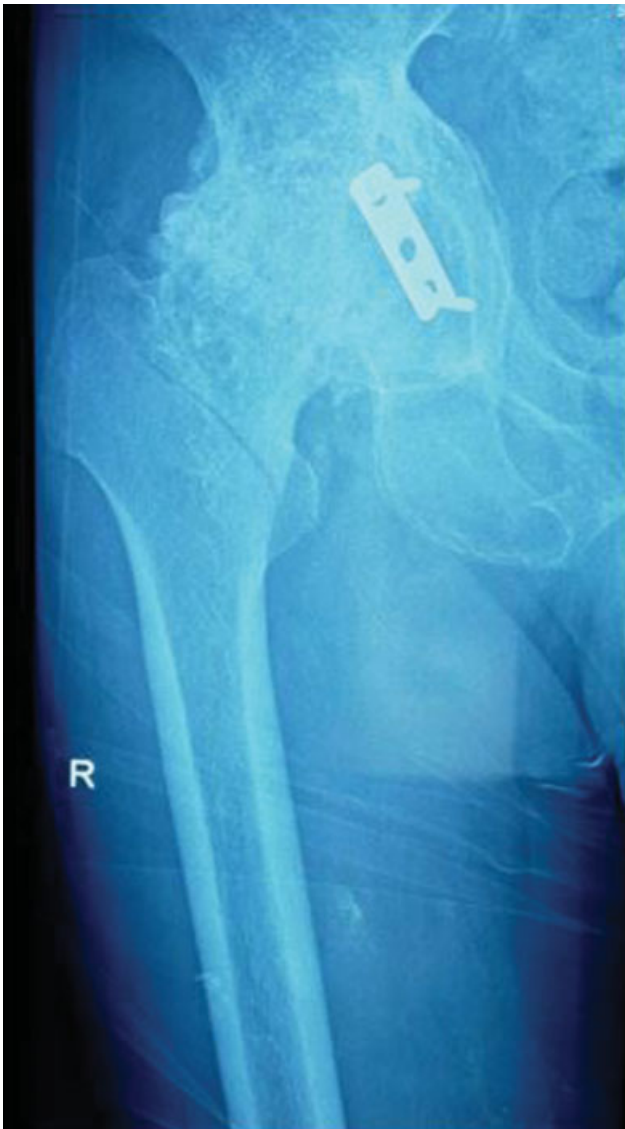

Fig. 1 Non-displaced fracture of the intertrochanteric region of the femur in an ankylosed hip.

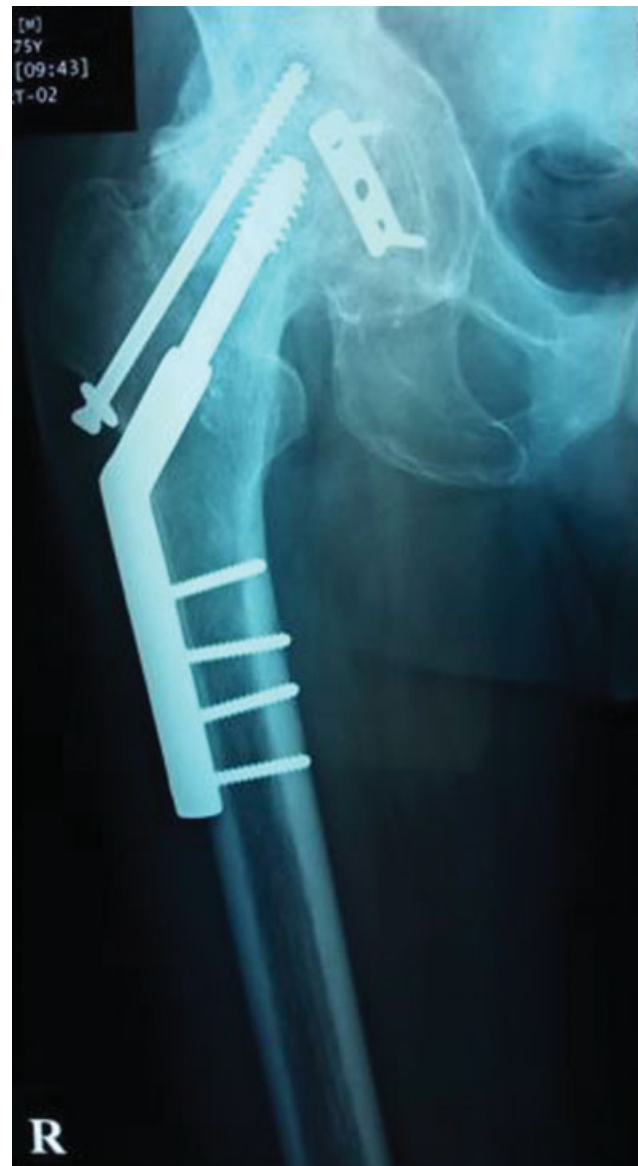

Fig. 2 After one and a half year of the operation: the fracture is united, and the implants are in situ.

with many complications related to prolonged immobilization, and surgery is the best option if the patient is physiologically fine.

The fracture was unstable because of the fusion of the hip joint proximal to the fracture site and the presence of the long distal lever arm of the lower extremity.² The case was not easy, and there are several options of fixation. We used DHSs and one cannulated screw piercing the acetabulum so that adequate stability would be obtained. We thought that DHSs alone were not enough, as the fusion of the hip and the distal lever arm of the lower extremity put strain on the fracture site, which could lead to implant failure.

Total hip arthroplasty (THA) is commonly used for fused hip joints, but it is technically demanding because of the lack of surgical landmarks.⁴ But, in this case, considering the poor muscle conditions around the hip, thigh and recent history of treatment for colon cancer, we chose the DHSs. There are reported cases of the application of intramedullary nails^{2,3} and cannulated screws only with good outcomes.⁵ In this case, the intramedullary nail option was not considered due to the poor muscle status around the hip and the non-displaced nature of the intertrochanteric fracture. Although the weight bearing walk was started later than the aforementioned intramedul-

lary cases, the healing of the fracture and the rest of the rehabilitation of this patient went uneventful. We think DHSs are also an option for intertrochanteric fractures in ankylosed hips.

Conflicts of interest

The authors declare no conflict of interest.

References

- 1 Bhandari M, Schemitsch E, Jönsson A, Zlowodzki M, Haidukewych GJ. Gamma nails revisited: gamma nails versus compression hip screws in the management of intertrochanteric fractures of the hip: a meta-analysis. *J Orthop Trauma* 2009;23(06):460–464
- 2 Ishimaru D, Nozawa S, Maeda M, Shimizu K. Intertrochanteric fracture of the ankylosed hip joint treated by a gamma nail: a case report. *Case Rep Orthop* 2012;2012:278156
- 3 Manzotti A, Confalonieri N, Pullen C. Intertrochanteric fracture of an arthrodesed hip. *J Bone Joint Surg Br* 2007;89(03):390–392
- 4 Kilgus DJ, Amstutz HC, Wolgin MA, Dorey FJ. Joint replacement for ankylosed hips. *J Bone Joint Surg Am* 1990;72(01):45–54
- 5 Font-Vizcarra L, Carreño AM, Prat S, Muñoz-Mahamud E, Camacho P, Casanova L. Less invasive fixation of an interthrocanteric fracture in an ankylosed hip with cannulated screws: a case report. *Hip Int* 2010;20(04):565–567