

Access this article online

Quick Response Code:



Website:

www.jorthodsci.org

DOI:

10.4103/jos.JOS_59_17

Severe skeletal Class II Division 1 malocclusion in postpubertal girl treated using Forsus with miniplate anchorage

Harshal Ashok Patil, Veerendra V Kerudi¹, BM Rudagi², Jitendra S Sharan³ and Pawankumar Dnyandeo Tekale⁴

Abstract:

This case report outlines the treatment of a 17-year-old female with Class II Division 1 malocclusion with mandibular retrusion, deep bite, and convex facial profile. The Forsus fatigue resistance device with miniplate was used for this patient and it was very affecting tool in correcting both skeletal and dental parameters. The total active treatment time was 19 months. This method can serve as an alternate choice of treatment, especially those who refuse orthognathic surgery. Hence, Forsus with miniplate might be useful in both growing and postpubertal patients.

Keywords:

Class II correctors, fixed functional appliance, miniplate

Introduction

Among all malocclusion, Class II malocclusion presents a constant challenge to the orthodontist.^[1] The treatment options for the correction of Class II malocclusion in growing age include early phase of functional appliance with growth modification and later the fixed orthodontic treatment. Unlike removable functional appliances, fixed functional devices have the advantage of not requiring patient compliance, and they can also be used concurrently with brackets.^[2] Fixed functional appliances are considered to be noncompliant Class II correctors; these are herbst, juser jumper, twin force bite corrector, Forsus, etc. Among all Class II correctors, the Forsus™ has proven to be most comfortable to a patient, right from installation itself. The Forsus corrector, not being as forceful as Herbst, allows gradual overpowering of the patient's

oral musculature.^[3,4] The Forsus™ fatigue resistance device (FFRD)* is a three-piece, telescoping system, which incorporates a super-elastic nickel-titanium coil spring. The FRD attaches at the maxillary first molar and on the mandibular archwire, distal to either the canine or first premolar bracket. As the coil is compressed, continuous opposing forces are transmitted to the sites of attachment without the possibility of fatigue, thereby correcting Class II malocclusions. Although previously performed studies have proved the efficiency of Forsus, the protrusion of the mandibular incisor was the most common problem which further limits the skeletal effect of the functional appliance.^[4-6] Aslan *et al.*^[7] used a FFRD appliance combined with a miniscrew, it was concluded that the mandibular incisor protruded significantly. The overjet and molar corrections were dentoalveolar and no skeletal improvement was concluded. Recently, Celikoglu *et al.*^[8] successfully treated a case of pubertal phase girl having skeletal Class II malocclusion

This is an open access article distributed under the terms of the Creative Commons Attribution-NonCommercial-ShareAlike 3.0 License, which allows others to remix, tweak, and build upon the work non-commercially, as long as the author is credited and the new creations are licensed under the identical terms.

For reprints contact: reprints@medknow.com

How to cite this article: Patil HA, Kerudi VV, Rudagi BM, Sharan JS, Tekale PD. Severe skeletal Class II Division 1 malocclusion in postpubertal girl treated using Forsus with miniplate anchorage. J Orthodont Sci 2017;6:147-51.

Private Orthodontic Practice, Aditya Chambers, Housing Society, Jalgaon, Departments of ¹Orthodontics and ²Oral and Maxillofacial Surgery, ACPM Dental College, Dhule, ⁴Department of Orthodontics, Dr. Rajesh Ramdasji Kambe Dental College and Hospital, Akola, Maharashtra, ³Department of Orthodontics and Dentofacial Deformities, Centre for Dental Education and Research AIIMS, New Delhi, India

Address for correspondence:

Dr. Harshal Ashok Patil, Private Orthodontic Practice, Aditya Chambers, Housing Society, Jalgaon, Maharashtra -425001, India. E-mail: drharshalortho@gmail.com

due to mandibular retrusion using a FFRD appliance with miniplate anchorage inserted on the mandibular symphysis. However, no one can use of miniplate anchorage with FFRD in postpubertal patient has not yet been reported.

In adult patient, the options for Class II corrections include the camouflage or the surgical orthodontics. Previous studies suggested that mandibular growth can extend beyond puberty, and minimal residual growth can only be stimulated with fixed functional appliances.^[9-11] The present case report shows the treatment of postpubertal girl with severe skeletal Class II malocclusion with mandibular retrusion using FFRD with miniplate anchorage which resulted in Optimal occlusion and facial profile.

Case Report

A 17-year-old female patient presented with the chief complaint of her retrusive lower jaw. Patient past medical and dental history was unremarkable. Extraoral examinations showed convex profile with recessive chin, increased lower anterior facial height with 100% incisor exposure while smiling. Intraoral examination revealed Class II molar and canine relation, crowding in lower arch with an overjet of 6 mm and an overbite of 4 mm [Figure 1]. Cephalometric examination [Figure 2 and Table 1] showed a skeletal Class II jaw base relationship with retrognathic mandible (SNA, 76°; SNB, 70°; ANB, 6°), hyperdivergent growth pattern (Go-Gn-Sn-35° and FMA-30°), and proclined lower incisor (IMPA-107). Panoramic radiograph revealed the presence of only lower both third molars and missing upper both third molars. The diagnosis was skeletal Class II with retrusive mandible.

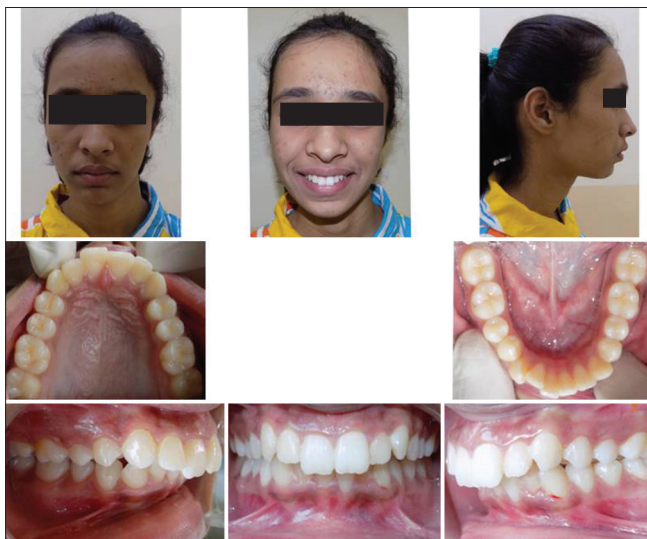

Figure 1: Pretreatment photographs

Treatment objective

- Correction of convex profile to orthognathic profile
- Correction of Class II molar and canine relationship
- To relieve the crowding in lower anterior teeth
- Correction of overjet and overbite
- Improve facial appearance by inhibiting forward vertical growth of the maxilla and stimulating growth of the mandible.

Treatment plan

The first treatment option was bilateral sagittal osteotomy with mandibular advancement after the extraction of the right and left mandibular first premolars for crowding and surgical compensation. The patient was not willing for surgical treatment. Second treatment option was extraction treatment with the

Table 1: Cephalometric analysis

Cephalometric parameter	Pretreatment	Posttreatment
SNA (°)	76	75
SNB (°)	70	72
ANB (°)	6	3
Wits appraisal (mm)	7	1
Go-Gn-SN (°)	35	35
Basal plane angle (°)	26	26
Jaraback ratio (%)	60	60
FMA (°)	30	29
Maxillary length (harvold analysis) (°)	85	83
Mandibular length (harvold analysis) (°)	104	106
U1-NA (°)	30	23
U1-NA (mm)	6	4
U1-SN (°)	105	98
U1-palatal plane (°)	113	108
IMPA (°)	107	109
L1-NB (°)	32	33
L1-NB (NN) (mm)	9	9
Interincisal angle (°)	111	114
Nasolabial angle (°)	82	110

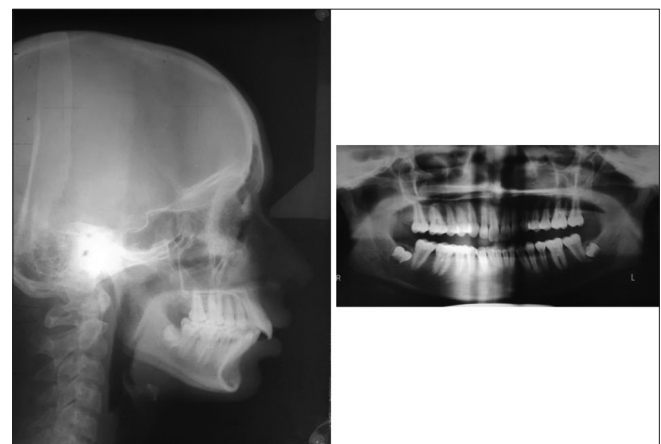


Figure 2: Pretreatment panoramic radiograph and lateral cephalogram

extraction of upper first premolar and lower second premolar. In such case correction of crowding and Class II molar canine relationship would be easier but profile of patient will not improve. After deciding the merits of various treatment options, another treatment protocol was designed for this case to harness the optimal balance between facial esthetics and dental corrections. It was planned to advance the mandible using flexible fixed functional appliance, such as the FFRD (FFRD; 3M Unitek, Monrovia, California, USA) with miniplate anchorage to prevent lower anterior proclination.

Treatment progress

The molars were banded, and the remaining teeth were bonded with 0.022° preadjusted edgewise appliance (MBT prescription, American Orthodontics mini master series). A transpalatal arch was placed on the upper first molars to counter the buccal flaring of the molars.

Treatment was started using 0.016" NiTi in both arches, which was followed by 0.018" NiTi 0.019 × 0.025" NiTi. Finally, a 0.019" × 0.025" stainless steel wire was placed as a working arch wire. Leveling and alignment were completed in 5 months. The miniplates (S. K. Surgicals, Pune, India) were placed bilaterally at the symphysis of the mandible under local anesthesia [Figure 3]. The miniplates were adjusted to fit the contour of the symphysis and fixed by three bone screws made of titanium (length, 7.0 mm; diameter, 2.0 mm). Three weeks after the surgery, FFRD was adjusted to the miniplates with a 29 mm length of rod chosen as per manufacturer instructions [Figure 4]. The FFRD is an inter-arch push spring device. It produces close to 200 g of force when springs are fully compressed.^[12] The patient was observed at 4-week intervals, and activation was performed by crimping stoppers onto the pushrod if needed. Eleven months after the skeletal anchored Forsus worn, Class I molar and canine relation with optimum overbite and overjet was achieved. Settling of the occlusion was carried out on 0.016" stainless steel in the upper and lower arches with settling elastics over 3 months. The total active treatment time was 19 months.

Before debonding, miniplates were removed under local anesthesia. Treatment objectives which were outlined for this patient have been achieved. The posttreatment facial profile of the patient demonstrated noticeable improvement with good facial esthetics, straight facial profile [Figures 5 and 6]. A good Class I molar relationship was achieved along with Class I canine relationship with 1 mm overjet and overbite. A maxillary removable Begg's wrap-around retainer with anterior inclined plane to hold the corrected jaw relation was

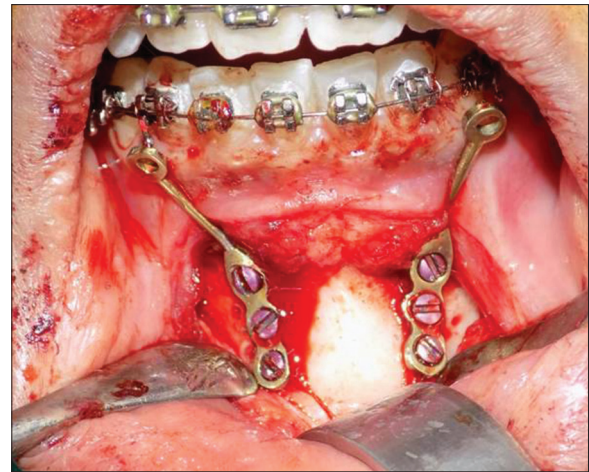


Figure 3: Surgical placement of miniplates in mandibular symphysis

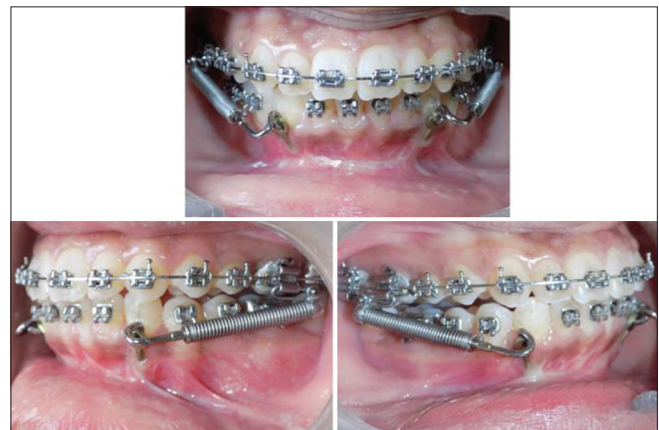

Figure 4: Intraoral photographs with Forsus fatigue resistance device Appliance with miniplate anchorage

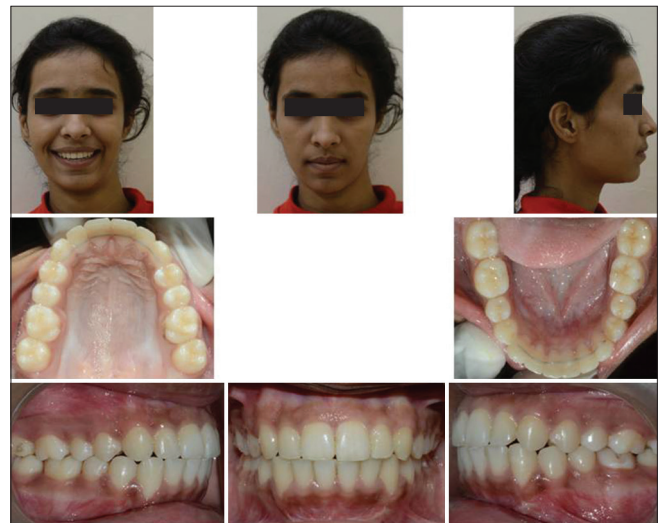

Figure 5: Posttreatment photographs

used for 24 h a day for 6 months, along with permanent bonded maxillary and mandibular canine to canine lingual retainer.

Discussion

FFRD was introduced to correct the Class II skeletal and dental problems in pre- and post-adolescent patients.^[13] It was also used widely in the growing Class II patients where cooperation from the patients remains a challenge. FFRD has given promising outcome as far correction of skeletal and dental components of Class II growing patients was concern. Mandibular retrognathia when treated with fixed functional appliances have more dentoalveolar effects than skeletal effects.^[14] The labial tipping of mandibular incisors limits the amount of skeletal correction and hinders the improvement in the facial profile. In literature, several attempts were performed using miniscrew anchorages to restrain the proclination of mandibular incisors and to improve the skeletal contribution of Class II correction, they were successful to decrease the lower incisor protrusion but unsuccessful for the improvement of skeletal contribution.^[7,15] However, miniplate anchored FFRD was to eliminate lower incisor protrusion.^[16,17]

The present case, is a postpubertal girl, with severe skeletal Class II malocclusion due to mandibular retrusion. Mostly, dental changes are encountered for the patient at postpubertal period. In this case report, the dentoalveolar changes were evident in maxilla because of FFRD attachment directly on maxillary molar. Hence, bodily distalization of whole maxillary arch occurs without extrusion of molars in maxilla hence vertical proportions of the face not affected. In mandible, SNB angle showed increase from 70° to 72° which shows skeletal changes in mandible. IMPA changes, in very small amount, from 107° to 109° due to arch length deficiencies in lower arch. All results were confirmed by superimposition of pretreatment and posttreatment cephalogram tracings [Figure 7].

Various techniques were used in literature to prevent lower anterior proclination including the use of negative torque lower incisors brackets, sectional arches, and miniscrews.^[7,15,18] Utilization of mini-implant anchorage effectively reduced the unfavorable proclination and intrusion of mandibular incisors but did not produce additional skeletal effects.^[7,15] In the present case report, significant retrusion of the upper lip was observed. This was due to heavy distalizing forces acting on the upper arch in opposite in mandible skeletal changes occurs. It is concluded FFRD with miniplate anchorage in postpubertal girl with severe skeletal Class II malocclusion with mandibular retrusion combined effect was seen that is bodily distalization in maxilla and mandibular advancement. The postretention photograph after 9 months shows stable results [Figure 8]. The disadvantages of this technique are two minor surgical operations are needed to insert miniplates and remove miniplates in mandibular symphysis region.

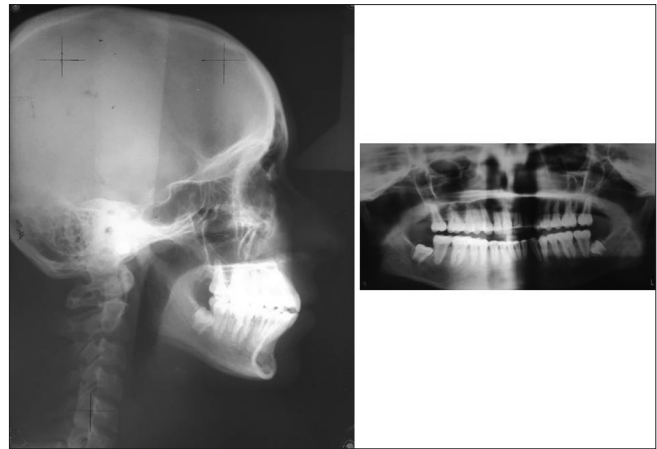


Figure 6: Posttreatment panoramic radiograph and lateral cephalogram

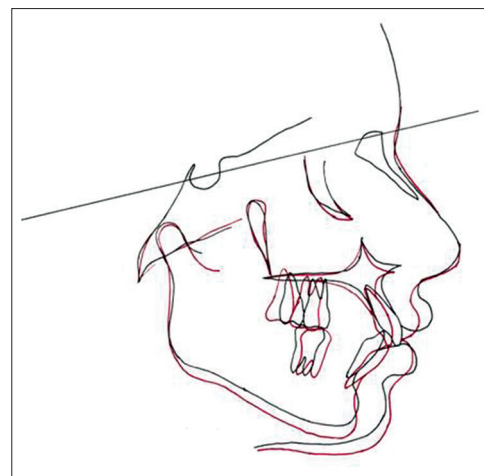


Figure 7: Superimposition of pretreatment, and posttreatment cephalometric tracings (black line: Before treatment and red line: posttreatment)

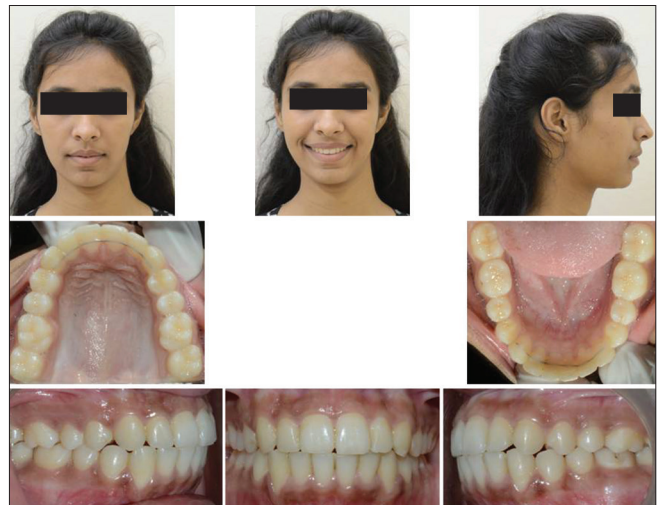

Figure 8: Postretention photograph after 9 months

Conclusion

Mandibular growth can extend beyond puberty, and this method can serve as an alternate choice of treatment,

especially those who refuse orthognathic surgery. Hence, Forsus with miniplate might be useful in both growing and postpubertal patients.

Declaration of patient consent

The authors certify that they have obtained all appropriate patient consent forms. In the form the patient(s) has/have given his/her/their consent for his/her/their images and other clinical information to be reported in the journal. The patients understand that their names and initials will not be published and due efforts will be made to conceal their identity, but anonymity cannot be guaranteed.

Financial support and sponsorship

Nil.

Conflicts of interest

There are no conflicts of interest.

References

- Cetlin NM, Ten Hove A. Nonextraction treatment. *J Clin Orthod* 1983;17:396-413.
- O'Brien K, Wright J, Conboy F, Sanjie Y, Mandall N, Chadwick S, et al. Effectiveness of treatment for class II malocclusion with the Herbst or twin-block appliances: A randomized, controlled trial. *Am J Orthod Dentofacial Orthop* 2003;124:128-37.
- Kucukkeles N, Ilhan I, Orgun IA. Treatment efficiency in skeletal class II patients treated with the Jasper Jumper. *Angle Orthod* 2007;77:449-56.
- Franchi L, Alvetro L, Giuntini V, Masucci C, Defraia E, Baccetti T. Effectiveness of comprehensive fixed appliance treatment used with the Forsus Fatigue Resistant Device in class II patients. *Angle Orthod* 2011;81:678-83.
- Jones G, Buschang PH, Kim KB, Oliver DR. Class II non-extraction patients treated with the Forsus Fatigue Resistant Device versus intermaxillary elastics. *Angle Orthod* 2008;78:332-8.
- Oztoprak MO, Nalbantgil D, Uyanlar A, Arun T. A cephalometric comparative study of class II correction with Sabbagh Universal Spring (SUS(2)) and Forsus FRD appliances. *Eur J Dent* 2012;6:302-10.
- Aslan BI, Kucukkaraca E, Turkoz C, Dincer M. Treatment effects of the Forsus Fatigue Resistant Device used with miniscrew anchorage. *Angle Orthod* 2014;84:76-87.
- Celikoglu M, Unal T, Bayram M, Candirli C. Treatment of a skeletal class II malocclusion using fixed functional appliance with miniplate anchorage. *Eur J Dent* 2014;8:276-80.
- Ruf S, Pancherz H. Dentoskeletal effects and facial profile changes in young adults treated with the Herbst appliance. *Angle Orthod* 1999;69:239-46.
- Ruf S, Pancherz H. Herbst/multibracket appliance treatment of class II division 1 malocclusions in early and late adulthood. A prospective cephalometric study of consecutively treated subjects. *Eur J Orthod* 2006;28:352-60.
- Konik M, Pancherz H, Hansen K. The mechanism of class II correction in late Herbst treatment. *Am J Orthod Dentofacial Orthop* 1997;112:87-91.
- Panigrahi P, Vineeth V. Biomechanical effects of fixed functional appliance on craniofacial structures. *Angle Orthod* 2009;79:668-75.
- Patil HA, Kerudi VV, Maheshwari A, Patil N, Sharan JS, Tekale PD. Treatment of skeletal class II malocclusion in growing young patient using Forsus appliance. *Eur J Clin Orthod* doi:10.12889/2016_C00261.
- Heinrichs DA, Shammaa I, Martin C, Razmus T, Gunel E, Ngan P. Treatment effects of a fixed intermaxillary device to correct class II malocclusions in growing patients. *Prog Orthod* 2014;15:45.
- Manni A, Pasini M, Mauro C. Comparison between Herbst appliances with or without miniscrew anchorage. *Dent Res J (Isfahan)* 2012;9 Suppl 2:S216-21.
- Turkkahraman H, Eliacik SK, Findik Y. Effects of miniplate anchored and conventional Forsus Fatigue Resistant Devices in the treatment of class II malocclusion. *Angle Orthod* 2016;86:1026-32.
- Unal T, Celikoglu M, Candirli C. Evaluation of the effects of skeletal anchored Forsus FRD using miniplates inserted on mandibular symphysis: A new approach for the treatment of class II malocclusion. *Angle Orthod* 2015;85:413-9.
- Karacay S, Akin E, Olmez H, Gurton AU, Sagdic D. Forsus Nitinol Flat Spring and Jasper Jumper corrections of class II division 1 malocclusions. *Angle Orthod* 2006;76:666-72.

Staying in touch with the journal

1) Table of Contents (TOC) email alert

Receive an email alert containing the TOC when a new complete issue of the journal is made available online. To register for TOC alerts go to www.jorthodsci.org/signup.asp.

2) RSS feeds

Really Simple Syndication (RSS) helps you to get alerts on new publication right on your desktop without going to the journal's website. You need a software (e.g. RSSReader, Feed Demon, FeedReader, My Yahoo!, NewsGator and NewzCrawler) to get advantage of this tool. RSS feeds can also be read through FireFox or Microsoft Outlook 2007. Once any of these small (and mostly free) software is installed, add www.jorthodsci.org/rssfeed.asp as one of the feeds.