

Turner syndrome and neurofibromatosis type 1: the unusual combination of two common genetic disorders

Inês Vieira¹, Sofia Lopes¹, Margarida Bastos¹, Luísa Ruas¹, Dírcea Rodrigues² and Isabel Paiva¹

¹Endocrinology Diabetes and Metabolism Department of Coimbra Hospital and University Centre, Coimbra, Portugal and ²Endocrinology Diabetes and Metabolism Department of Coimbra Hospital and University Centre, Faculty of Medicine of the University of Coimbra, Coimbra, Portugal

Correspondence
should be addressed
to I Vieira
Email
11285@chuc.min-saude.pt

Summary

The coexistence of neurofibromatosis type 1 (NFT1) and Turner syndrome (TS) has only been reported in a few patients and may represent a diagnostic challenge. We describe the case of a 16-year-old girl, with a prior clinical diagnosis of NFT1, who was referred to Endocrinology appointments for the etiological study of primary amenorrhea. Evaluation of the anterior pituitary function was requested and hypergonadotropic hypogonadism was detected. During the etiological study, a 45X karyotype was found and TS was diagnosed. The fact that NFT1 can also be associated with short stature, short broad neck and hypertelorism was likely responsible for TS being diagnosed in late adolescence. As both TS and NFT1 are relatively common genetic disorders, it is important to be alert to the possibility that the presence of one disease does not invalidate the other.

Learning points:

- The concomitant presence of two syndromes in the same patient is unlikely and represents a diagnostic challenge.
- Some phenotypic characteristics and clinical manifestations may be shared by several syndromes.
- Some syndromes, such as neurofibromatosis type 1 may have very heterogeneous presentations.
- It is important to be alert to the characteristics that are not explained by the initial diagnosis.
- If such features are present, diagnostic work-up must be performed regardless of the initial syndromic diagnosis.

Background

Neurofibromatosis type 1 (NFT1) or Von Recklinghausen's disease results from germline mutations in the tumor suppressor gene *NF1*. It is an autosomal dominant disease, with variable expression, a high rate of spontaneous mutations and an incidence of 1:2500 to 1:3000 (1). The diagnosis can usually be made through the clinical criteria defined by the National Health Institute. The patient must meet at least two criteria: ≥ 6 café-au-lait spots (>5 mm diameter in pre-pubertal individuals; >15 mm in post-pubertal individuals); ≥ 2 neurofibromas of any type, or 1

plexiform neurofibroma; freckling in axillary or inguinal regions; optic glioma; ≥ 2 Lisch nodules (iris hamartomas); a distinct osseous lesion (sphenoid dysplasia; tibial pseudoarthrosis); ≥ 1 first degree relative with type 1 neurofibromatosis (2). More recently, the detection of a pathogenic germline *NF1* variant in heterozygosity in normal tissue cells has been proposed as an additional criterion (3). About 12% of NFT1 patients present a Noonan-like phenotype with short stature, short broad neck and hypertelorism (4). In fact, a distinct entity called

neurofibromatosis-Noonan syndrome (NFT1-NS) has been described (5).

Turner syndrome (TS) is a sex chromosome disorder, characterized by the complete or partial absence of one of the X chromosomes, that affects about 1:2000 newborns (6). It is associated with gonadal dysgenesis, retarded growth and a characteristic phenotype that has some similarities with that of NS (7).

The coexistence of NFT1 and TS has only been reported in a few patients, with less than ten cases described in the literature (5). We report a rare case of coexistence of both syndromes and discuss its practical implications.

Case presentation

A 16-year-old girl, with a prior diagnosis of NFT1, was referred to Endocrinology appointments for the etiological study of primary amenorrhea.

The child had been born from a pregnancy with adequate surveillance, with intrauterine growth restriction. The delivery was eutocic at 37 weeks, and at birth, she weighed 2210 g and 44 cm in length.

In her first months of life, several abnormalities were detected. A suspicious phenotype with large and low-implantation earlobes, short neck, and hypertelorism was noted. At 5 months of age, congenital hip dysplasia was diagnosed and treated conservatively. When she started walking, at 15 months of age, dyspnoea and peripheral cyanosis were described by her parents. This led to the diagnosis of an ostium secundum persistent interatrial communication which was surgically corrected when she was 18 months old. During her first years of life, she also had failure to thrive. After correction of the interatrial communication, there was a slight improvement in weight (she crossed from below the 3rd to 25th percentile), with no significant improvement in height (which maintained below the third percentile). Developmental delay and attention deficit hyperactivity disorder were also diagnosed, and the child required learning support. Several

otorhinolaryngological abnormalities, including nasal obstruction and sleep apnoea due to adenoid hyperplasia, were detected precociously and the patient was submitted to adenoidectomy when she was 27 months old. During her childhood, she had several middle-year infections, and at the age of 6, she was submitted to plasty of the auricular cartilage.

There was family history of NFT1 in her father and grandfather, therefore there was a high level of suspicion when several café-au-lait spots were detected. At age 7, due to clinical suspicion during an ophthalmologic examination, magnetic resonance was requested which described optic chiasm and optic nerves thickening mostly on the left, probably translating to an optic nerve glioma. (Fig. 1)

At age 16, due to the absence of pubertal development, she was observed in endocrinology appointments for the first time. She was 131 cm tall, weighed 34 kg and lacked secondary sexual characteristics. Besides the above-mentioned phenotypical characteristics, she also displayed several cutaneous neurofibromas. A bone evaluation had been performed and revealed a bone age of 12 years and 3 months for a chronological age of 16 years and 3 months with a 75% maturation delay.

Investigation

A comprehensive study was requested. Laboratory study revealed normal kidney function, discrete elevation of liver enzymes – alanine aminotransferase 152 U/L (<34); aspartate aminotransferase 36 U/L (<31); alkaline phosphatase 164 U/L (47–119) and gamma-glutamyl transferase 89 U/L (4–24) – an A1C of 5.8% and a lipid profile within the reference range. Evaluation of the anterior pituitary function was indicative of hypergonadotropic hypogonadism – FSH 152 mUI/mL (<9.6), LH 27 mUI/mL (<12), estrogen 18 pg/mL (10–200) and progesterone <0.2 mg/mL (<1.5). Abdominal and pelvic ultrasound showed a horseshoe kidney and a pre-puberal configuration of

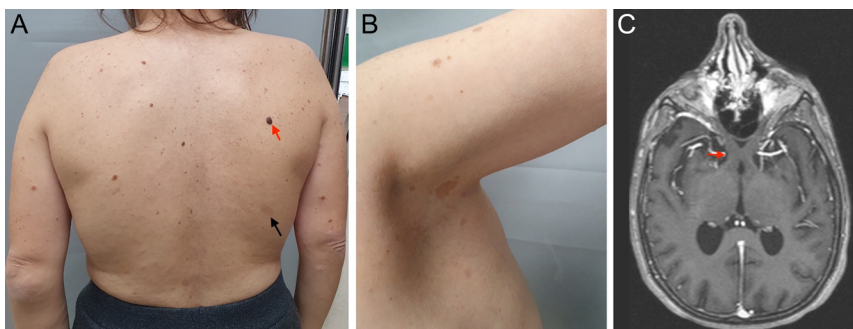


Figure 1

Phenotypical characteristics suggestive of NFT1: (A) black arrow points toward a café-au-lait spot and the red arrow signals a neurofibroma; (B) freckling in the axillary region; (C) magnetic resonance showing optic nerve thickening consistent with the presence of an optic glioma (red arrow). NFT1, neurofibromatosis type 1.

the uterus, a small right ovary and the left ovary was not visualized. A skeletal x-ray study revealed dextroconvex scoliosis in the dorsal spine and rectification of the physiologic lordosis in the lumbar spine.

Due to the presence of a suspicious phenotype, (Fig. 2) prior history of hip dysplasia, atrial septum defects, and hypergonadotropic hypogonadism a karyotype evaluation was requested. Chromosomal analysis was performed on metaphases with GTG bands obtained from peripheral blood lymphocyte culture, and a 45X karyotype was found thus making the diagnosis of TS

Treatment

The patient was initiated on hormone replacement therapy with estradiol and dydrogesterone with some development of secondary sexual characters. Growth hormone was not initiated because, due to her bone age, the patient did not fill the criteria for reimbursed treatment in our country and there were also concerns regarding cardiac implications.

Outcome and follow-up

She is currently 27 years old and has reached a height of 135 cm (significantly below her target family height of 165 cm) but has a normal BMI (21.9 kg/m²). During the follow-up, she presented two HbA1c values of 5.8%; however, a return to normoglycemia was achieved through lifestyle measures. Heterogeneous echogenicity of the thyroid gland and positive anti-peroxidase antibodies were detected, making the diagnosis of autoimmune thyroiditis. The patient has been kept under multidisciplinary follow-up and no further endocrine abnormalities have been found so far.

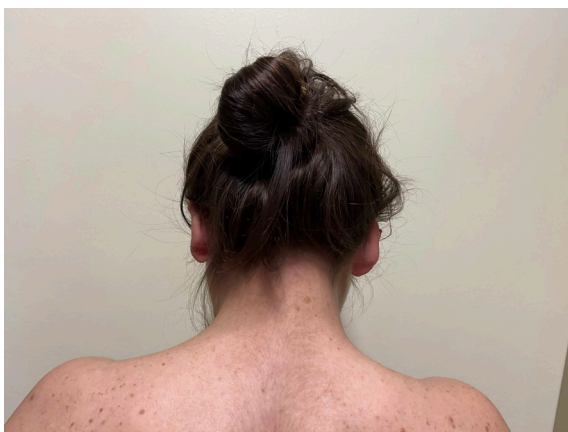

Figure 2
Phenotypical characteristics suggestive of TS with large and low-implantation earlobes, short neck and hypertelorism. TS, Turner syndrome.

Discussion

We present a rare case of coexistence of NFT1 and TS. In retrospect, there were several leads for the diagnosis of TS in the first years of life: the suggestive phenotype, difficulty thriving, cardiac abnormalities, adenoid hyperplasia, medial ear infections and outer ear deformities. However, the fact that NFT1 can be associated with a Noonan-like phenotype was likely considered an explanation for the child's phenotype. Comparing to NFT1, NFT1-NS presents with additional phenotypical characteristics of NS, such as short stature, short broad neck, low-set ears and ocular hypertelorism (4). These features overlap with the phenotype of TS that the patient presented. Short stature has been described in 8–33% of NFT1 patients (8). Atrial septal defects are most frequently associated with TS (7), but its prevalence is also increased in NS (9) and in NFT1 (10). Several features of TS are also common in NS, but have not been specifically described in the NFT1-NS phenotype. Figure 3 depicts which of the patient's clinical features fit in each of the syndromes.

All the above-mentioned factors probably contributed to the late diagnosis of TS. NFT1 may be associated with precocious puberty, especially in cases such as this with chiasmatic involvement with the glioma (8). Pubertal delay is less frequently reported, and it was this factor which motivated the referral of this patient. Regardless of the presence of a tumor affecting the chiasm, NFT1 may rarely be associated with hypergonadotropic hypogonadism. The finding of hypergonadotropic hypogonadism, however, is not expected, and its investigation outside of the context of NFT1 was a red flag of the presence of another entity.

Both TS and NFT1 require multidisciplinary follow-up, with special attention to the most common comorbidities and complications. The additional diagnosis of TS adds several risks to this patient, leading to increased morbidity and reduced lifespan (estimated about 13–15 years compared to the general population). This is mainly due to the augmented risk of cardiovascular diseases (responsible for 50% of the excess mortality), autoimmune endocrine diseases (such as diabetes mellitus and thyroiditis), osteoporosis, anemia and diseases of the digestive system (7).

In this case, the coexistence of NFT1 led to a delay in the diagnosis of TS. As several phenotypical aspects may be common to different syndromes, distinguishing which characteristics do not fit in a particular syndrome and considering the presence of a second one certainly represents a diagnostic challenge. However, especially in the setting of common genetic disorders, more than one

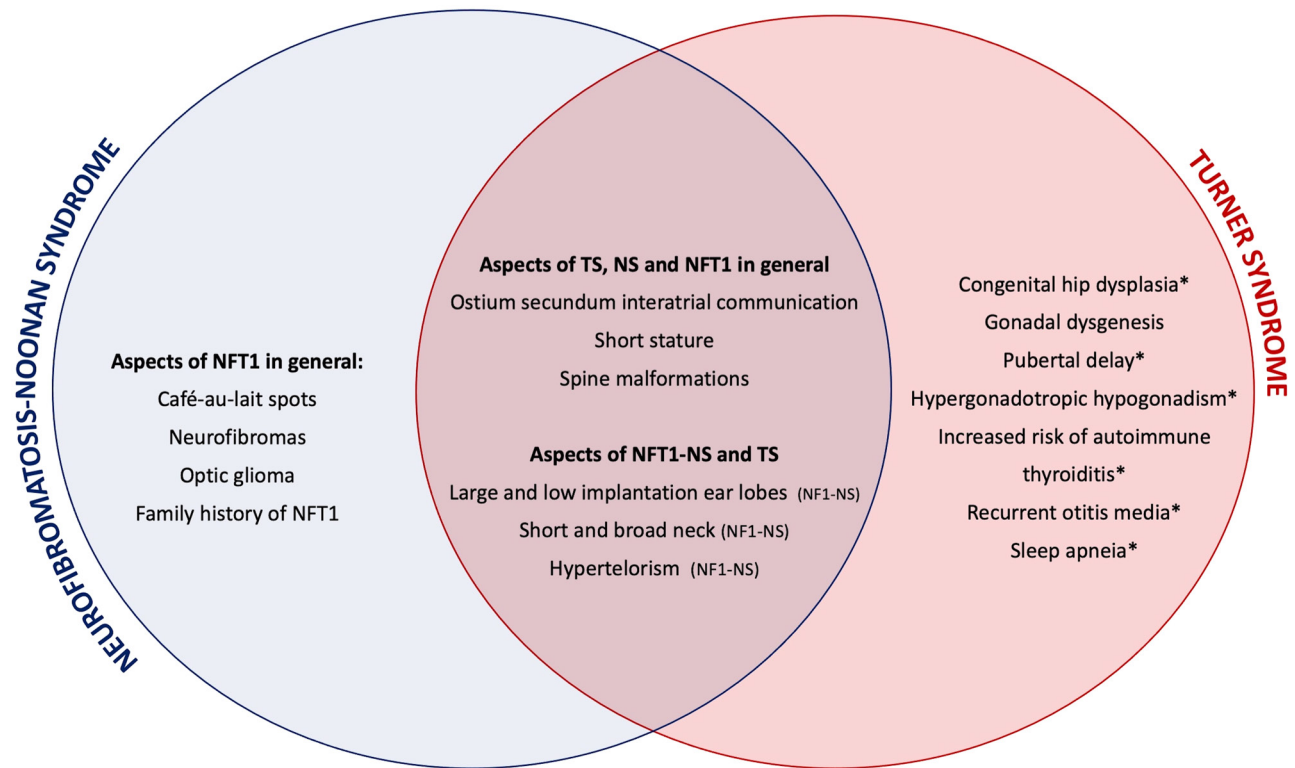


Figure 3

Illustration of the patient's features attests which fit in the diagnosis of NFT1-NS syndrome and which features are only explained by the coexistence of Turner Syndrome. Some aspects have also been reported in NS but have not specifically been described in NFT1-NS (marked with *). Others have only been frequently described in Turner Syndrome. NFT1, neurofibromatosis type 1; NFT1-NS, neurofibromatosis-Noonan Syndrome; TS, Turner syndrome.

may rarely coexist. Adequate surveillance of these patients is essential, as they have a greater cumulative risk of serious manifestations. The presented case has a longer follow-up than the cases of TS and NFT1 previously reported in the literature which allows the evaluation of the impact of the disease on adult life and attests to the possibility of ameliorating these consequences through an adequate follow-up.

Declaration of interest

The authors declare that there is no conflict of interest that could be perceived as prejudicing the impartiality of the research reported.

Funding

This work did not receive any specific grant from any funding agency in the public, commercial, or not-for-profit sector.

Patient consent

Written informed consent for publication of their clinical details and/or clinical images was obtained from the patient/parent/guardian/relative of the patient.

Author contribution statement

I V and S L produced the report and performed the literature review. L R and D R assisted in the production of the report and the literature review. I P oversaw the creation of the report and was involved in the care of the patient. All the authors approved the final version to be published.

References

- 1 Ferner RE, Huson SM, Thomas N, Moss C, Willshaw H, Evans DG, Upadhyaya M, Towers R, Gleeson M, Steiger C, *et al*. Guidelines for the diagnosis and management of individuals with neurofibromatosis 1. *Journal of Medical Genetics* 2007 **44** 81–88. (<https://doi.org/10.1136/jmg.2006.045906>)
- 2 The National Institutes of Health (NIH) consensus development program: neurofibromatosis [Internet]. [cited 14 Feb 2021]. (available at: <https://consensus.nih.gov/1987/1987Neurofibromatosis064html.htm>)
- 3 Legius E, Messiaen L, Wolkenstein P, Pancza P, Avery RA, Berman Y, Blakeley J, Babovic-Vuksanovic D, Cunha KS, Ferner R, *et al*. Revised diagnostic criteria for neurofibromatosis type 1 and Legius syndrome: an international consensus recommendation. *Genetics in Medicine* 2021 **23** 1506–1513. (<https://doi.org/10.1038/s41436-021-01170-5>)
- 4 Jett K & Friedman JM. Clinical and genetic aspects of neurofibromatosis 1. *Genetics in Medicine* 2010 **12** 1–11. (<https://doi.org/10.1097/GIM.0b013e3181bf15e3>)
- 5 Rare presentation of neurofibromatosis and Turner syndrome in a pediatric patient [Internet]. [cited 8 Nov 2021]. (<https://doi.org/10.4081/pr.2017.6810>)



- 6 Ranke MB & Saenger P. Turner's syndrome. *Lancet* 2001 **358** 309–314. ([https://doi.org/10.1016/S0140-6736\(01\)05487-3](https://doi.org/10.1016/S0140-6736(01)05487-3))
- 7 Gravholt CH, Viuff MH, Brun S, Stochholm K & Andersen NH. Turner syndrome: mechanisms and management. *Nature Reviews: Endocrinology* 2019 **15** 601–614. (<https://doi.org/10.1038/s41574-019-0224-4>)
- 8 Oliveira C, Santos-Silva R & Fontoura M. Implicações no crescimento e desenvolvimento pubertário da neurofibromatose tipo 1. *Revista Portuguesa de Endocrinologia, Diabetes e Metabolismo* 2019 **14** 180–186.
- 9 Burch M, Sharland M, Shinebourne E, Smith G, Patton M, McKenna W. Cardiac abnormalities in Noonan syndrome: phenotypic diagnosis and echocardiographic assessment of 118 patients. *Am J Cardiol*. 1993 **72** 1189–1192. ([https://doi.org/10.1016/0735-1097\(93\)90436-5](https://doi.org/10.1016/0735-1097(93)90436-5))
- 10 Pinna V, Daniele P, Calcagni G, Mariniello L, Criscione R, Giardina C, Lepri FR, Hozhabri H, Alberico A, Cavone S, et al. Prevalence, type, and molecular spectrum of NF1 mutations in patients with neurofibromatosis type 1 and congenital heart disease. *Genes* 2019 **10** 675. (<https://doi.org/10.3390/genes10090675>)

Received in final form 14 April 2022

Accepted 18 May 2022