

# Early-onset Pseudoexfoliation Syndrome following Multiple Intraocular Procedures

Heydar Amini<sup>1</sup>, MD; Ramin Daneshvar<sup>2</sup>, MD; Yadollah Eslami<sup>1</sup>, MD  
Sasan Moghimi<sup>1</sup>, MD; Nima Amini<sup>3</sup>, MD

<sup>1</sup>Eye Research Center, Farabi Eye Hospital, Tehran University of Medical Sciences, Tehran, Iran

<sup>2</sup>Eye Research Center, Mashhad University of Medical Sciences, Mashhad, Iran

<sup>3</sup>Department of Pathology, University of California-Irvine, Irvine, CA, USA

**Purpose:** To present early-onset ocular manifestations of pseudoexfoliation syndrome in young patients who had undergone multiple intraocular procedures.

**Methods:** This is an observational case series, introducing four cases with histories of multiple intraocular procedures for glaucoma.

**Results:** All reported cases demonstrated typical manifestations of pseudoexfoliation unilaterally in the eye that had undergone multiple surgeries. The diagnosis of pseudoexfoliation was made prior to the age of 50 in all subjects and the earliest manifestation was at the age of 18 in a case with primary congenital glaucoma

**Conclusion:** The role of multiple surgical procedures, in addition to genetic predisposition, should be further investigated as a possible inciting factor predisposing to pseudoexfoliation in younger individuals.

**Keywords:** Exfoliation Syndrome; Glaucoma; Intraocular Surgery

*J Ophthalmic Vis Res* 2012; 7 (3): 190-196.

**Correspondence to:** Ramin Daneshvar, MD. Assistant Professor of Ophthalmology, Khatam-al-Anbia Hospital, Ghareni Blvd., Mashhad 91959-61151, Iran; Tel: +98 (511) 728 9911; email: radaneshvar@gmail.com

**Received:** February 4, 2012

**Accepted:** June 11, 2012

## INTRODUCTION

Pseudoexfoliation syndrome (PXF) was first described by the Finnish ophthalmologist, John G Lindberg in 1917.<sup>1</sup> PXF is the most common identifiable cause of secondary open angle glaucoma worldwide.<sup>2</sup> This condition is both epidemiologically and socioeconomically important because of its high prevalence in the elderly population and the increased risk of glaucoma in PXF patients; besides, there is a higher risk of complications in PXF eyes during intraocular procedures especially cataract surgery.<sup>3,4</sup>

Although a genetic basis for PXF has recently been described, environmental factors seem to be equally important in its pathogenesis

and age of onset as well.<sup>5</sup> The incidence of PXF increases steadily with age and most affected patients are older than 50 years of age, on the other hand there are few reported PXF cases younger than 40 years.<sup>6-8</sup> Noticeably, these cases share previous intraocular surgery as a common feature in their history; this may denote a simple coincidental association or some sort of causal relationship.

Herein, we describe four patients with glaucoma younger than 50 years with early signs of PXF subsequent to multiple intraocular procedures.

## METHODS

This is a retrospective, observational case series

including four patients with early manifestations of pseudoexfoliation. The presented cases were encountered among glaucomatous patients regularly visited for glaucoma management who had clinical findings of pseudoexfoliation earlier than the age of 50 discovered during one of their prior visits. In addition to their glaucomatous backgrounds, all cases shared multiple intraocular surgeries in their past ocular histories. Patients' medical and surgical records were thoroughly reviewed; positive findings were recorded and reported for each case, accordingly. We specifically focused on surgical and family histories of the selected subjects.

The current report adheres to the tenets of the declaration of Helsinki; written informed consent was obtained from all participants prior to enrollment. The Ethical Committee of Tehran University of Medical Sciences approved the study protocol.

## RESULTS

### Case 1

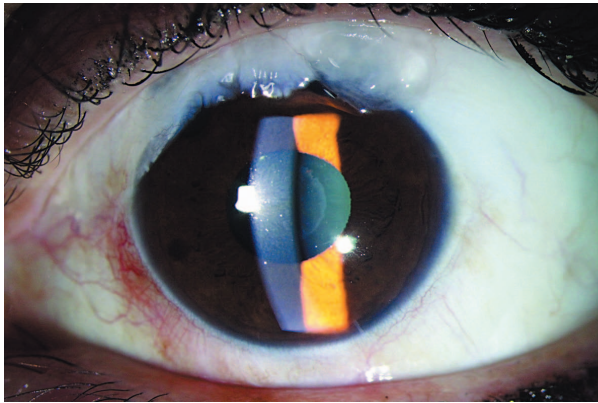
A 28-year-old female physician, with no family history of glaucoma, was diagnosed with advanced bilateral juvenile glaucoma in 1994. Pretreatment intraocular pressure (IOP) was

in the range of 40 mmHg. Although records of the procedure were not available, based on gonioscopic findings, initially a laser procedure, probably argon laser trabeculoplasty (ALT), had been performed which turned out to be ineffective. One year after diagnosis, bilateral full-thickness incisional surgery (posterior lip sclerectomy) was performed within a one-month interval. She then underwent reformation of the anterior chambers 3 days after the operation. Four years following initial surgery in 1999, mild bleb leakage was observed in her left eye that was conservatively managed with simple patching. IOP in the left eye was fairly controlled but required gradual increase in the number of topical antiglaucoma medications up to 2006 when it reached 25 mmHg on four topical antiglaucoma medications. Guarded filtration surgery (trabeculectomy) was performed on the left eye and was successful in reducing IOP to the target level. Clinical examination had revealed no exfoliative material up to 3 years after the last surgery, at the time which characteristic signs of PXF were noted in the left eye for the first time (Fig. 1, Table 1); exfoliative deposits were also detected upon gonioscopic evaluation of angle structures. During the following 4 years, no manifestation of exfoliative material was observed in the right eye and IOP remained well controlled in both eyes. There was bilateral

**Table 1.** Summary of patients with early PXF

Case number	Year of birth	Age at glaucoma diagnosis (date of diagnosis)	Sex	Affected eye	Surgical history (date of intervention)	Age at PXF diagnosis (date)
1	1966	28 (1994)	F	L	ALT (1994) PLS (1995) Late bleb leakage (1999) Trabx (2006)	43 (2009)
2	1967	27 (1994)	F	L	Trabx (1994) Trabx (1994) AGV procedure (2003)	40 (2007)
3	1966	36 (2002)	M	L	ALT (2002) Trabx (2003) AC reformation (2003)	40 (2006)
4	1987	<1 (1987)	F	L	Trabeculectomy (1987) Trabx (1993) Trabx (1997) Blebitis (2001) Blebitis (2001) Trabx (2004) AGV procedure (2005)	18 (2005)

PXF, pseudoexfoliation; F, female; M, male; L, left eye; ALT, argon laser trabeculoplasty; PLS, posterior lip sclerectomy; Trabx, trabeculectomy; AGV, Ahmed glaucoma valve; AC, anterior chamber

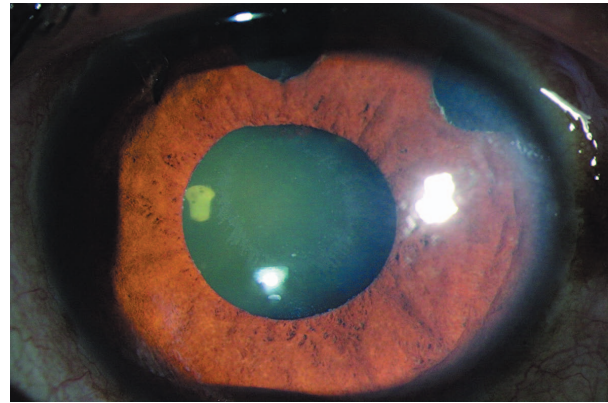


**Figure 1.** Left eye of case 1, characteristics exfoliative material is present on the anterior lens capsule. Multiple blebs are also evident.

advanced glaucomatous optic nerve damage with constricted visual fields and visual acuity of 20/25 in both eyes.

### Case 2

A 27-year-old housewife with history of glaucoma in her daughter presented with intense headaches in 1994. With high IOP levels in the range of 50 mmHg, she was diagnosed with bilateral open angle glaucoma, meanwhile no evidence of exfoliation or causes of secondary glaucoma was noticed. The patient underwent trabeculectomy in both eyes within a one-month interval. Failure of the initial procedure and uncontrollable high IOP levels led to a repeat trabeculectomy on the left eye four months following initial surgery. In 2003, the left eye required an Ahmed glaucoma valve (AGV, New World Medical Inc., Rancho Cucamonga, CA, USA) procedure due to intractable glaucoma. Four years after the shunt procedure, typical exfoliative deposits were observed on the lens surface, pupillary margin and angle structures of the left eye (Fig. 2, Table 1). During the subsequent 7 years, IOP was well controlled bilaterally; at the last ocular examination IOP of 16 mmHg was detected in the right eye without any antiglaucoma medications, however, three antiglaucoma medications had been used in the left eye to achieve an IOP of 17 mmHg. Best corrected visual acuity (BCVA) was 20/30 and 20/50 in the right and left eyes, respectively. The patient was a poor performer on visual field



**Figure 2.** Left eye of case 2; exfoliative material deposition on the anterior lens capsule and pupillary border is evident. Peripheral iridectomies and the Ahmed glaucoma valve tube (10 o'clock position) are visible.

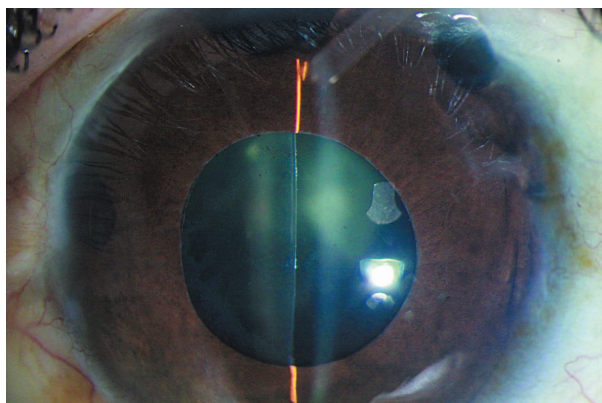
testing, nevertheless, moderate to advanced glaucomatous cupping was apparent in both eyes.

### Case 3

A 36-year-old male engineer was diagnosed with advanced glaucoma in 2002 with no evidence of PXF in either eye. Noticeably, the patient had history of coronary artery disease, diagnosed during the second decade of life. None of the family members had history of glaucoma or blindness. Both eyes underwent ALT which was followed by a trabeculectomy procedure on the left eye one year later in order to achieve adequate IOP control. On postoperative day 4, the patient required anterior chamber reformation in the left eye; however, no further intervention was required afterwards. After 3 years, exfoliative material became evident on slit lamp and gonioscopic examinations of the left eye (Table 1). The patient's condition was bilaterally stable during the following 8 years and at the last follow-up, IOP reached 14 and 18 mmHg in the right and left eyes, respectively. One antiglaucoma medication had sufficiently controlled IOP in the left eye, whereas no medication had been used in the right eye. BCVA of 20/25 and 20/20 were noted in the right and left eyes, respectively. Advanced glaucomatous optic nerve damage was noted accompanied by severely constricted visual fields, in both eyes.

#### Case 4

A 10-day-old girl presented with primary congenital glaucoma in 1987. She had a strong family history of severe, early-onset glaucoma. The patient underwent bilateral trabeculotomies during the neonatal period. At the age of 6 years, trabeculectomy was required for both eyes to control IOP and a repeat trabeculectomy was later performed bilaterally when she was 10 years old in order to assist IOP control. Unfortunately, the patient suffered unilateral vision loss in the right eye following an episode of endophthalmitis necessitating enucleation. There was a functional filtration bleb in the left eye and IOP was well-controlled for the subsequent 4 years, when two episodes of blebitis were finally accompanied by bleb scarification and failure. A third trabeculectomy procedure was performed in 2004, which was temporarily successful in controlling IOP for about 10 months. In 2005, the patient underwent an Ahmed glaucoma valve shunt procedure to control IOP. Exfoliation signs had not been noted up to this stage. However 6 months after the shunt procedure, typical PXF manifestations were observed in the anterior segment of the left eye for the first time (Fig. 3, Table 1). During the next 5 years, IOP was fairly controlled with two topical antiglaucoma medications. At the last follow-up, BCVA was 20/70 and there was a moderate posterior subcapsular cataract with advanced glaucomatous optic nerve damage.



**Figure 3.** Left eye of case 4; following multiple intraocular surgeries, exfoliative deposits are recognized on the pupillary border and anterior lens capsule. Multiple iridectomies and the Ahmed glaucoma valve tube are evident.

#### DISCUSSION

PXF is an age-related systemic condition, characterized by production of extracellular fibrillar material in various tissues and organs, including the anterior segment of the eye. PXF is present worldwide, yet represents quite a variable incidence among different ethnic groups, ranging from actually no known cases in Greenland Eskimos to a prevalence of 20-25% in the Nordic countries of Finland and Iceland.<sup>9-11</sup> PXF prevalence in Yemen and Iran has been reported to be 19.53% and 13.1%, respectively, on the other hand, a striking high prevalence of 38% was reported in the Navajo population of Arizona.<sup>12-14</sup> Globally, it is estimated that 60-70 million people are affected by PXF.<sup>4</sup> Different studies have not demonstrated any sex predilection, but a consistent increase occurs in the prevalence of PXF with age.<sup>12,13,15,16</sup>

PXF may exhibit significantly different clinical features between patients and even between two eyes of the same patient. For proper clinical diagnosis or at least raising the suspicion of one, careful slit lamp examination with sufficient mydriasis is essential. Although PXF is a systemic condition, the clinical findings are frequently evident in one eye only. Various studies have estimated the probability of developing PXF in the unaffected eye to range from 6.8% to 30% over a period of 5 years.<sup>17,18</sup> However, the fellow eye of a clinically diagnosed "unilateral" case almost invariably shows microscopic evidence of PXF deposition in the conjunctiva.<sup>19</sup>

From a pathophysiological standpoint, PXF is an age-related microfibrilopathy, characterized by gradual synthesis, accumulation and deposition of exfoliation material in the anterior segment as well as other tissues in the body.<sup>2</sup> Although the exact pathogenesis of PXF is still unknown, it is believed that inadequate breakdown and/or excessive production of elastic fibrillar components are mainly involved.<sup>20,21</sup> Apparently, PXF is a systemic condition with exfoliative material present throughout the body. The presence of exfoliative material has been associated with cardiovascular and cerebrovascular morbidity,

and sensorineural hearing loss,<sup>22-24</sup> similar to the third case presented herein in whom early-onset coronary heart disease was observed.

Marked familial aggregation of PXF has been known for many years and mutations in the lysyl oxidase-like 1 gene (LOXL1) has recently been found to be strongly associated with this disorder.<sup>5</sup> LOXL1 belongs to the lysyl oxidase family of extracellular enzymes, involved in oxidative deamination of lysine residues that allow proper orientation and crosslinking of tropoelastin into elastin polymers.<sup>5</sup> LOXL1 expression decreases considerably with age, therefore, even small alterations in LOXL1 expression may become more pronounced with age, explaining the age-related nature of PXF.<sup>25</sup>

Furthermore, several authors have reported an unexpectedly high incidence of PXF in married couples, indicating the possible influence of an environmental/transmissible factor on this condition.<sup>26,27</sup> There is molecular and biochemical evidence implying that PXF arises from a stress-induced elastic microfibrilopathy.<sup>28</sup> Surgical trauma, inflammation, radiant energy, oxidative stress and many other unknown factors could exert such stresses to vulnerable individuals; indeed, trauma may likewise result in a clinically similar situation known as true exfoliation.<sup>29-33</sup>

Elevated levels of serum alpha-1 antitrypsin in PXF patients particularly denotes the presence of some sort of inflammation in these patients.<sup>34</sup> Besides, elevated plasma homocysteine levels, vascular dysregulation and accompanying blood flow disturbances have also been associated with PXF.<sup>35</sup> There is evidence in favor of the role of oxidative stress in PXF patients as well.<sup>36</sup> We speculate that trauma due to multiple intraocular surgeries could elicit inflammation and oxidative stress as a trigger for the PXF cascade.

On the other hand, it has been proposed that there are protective genes or environmental factors that retard the development of PXF and exfoliative glaucoma.<sup>5</sup> Taking all of these together, it seems that PXF is a complex disorder that likely involves multiple genes and/or environmental influences.<sup>5</sup> We assume that, this could be a possible explanation for development of PXF following trauma of multiple intraocular

procedures in our patients.

A comprehensive review of the available literature reveals that there are limited reported PXF cases diagnosed under the age of 50 years. Kuchle and Naumann reported the occurrence of PXF following penetrating keratoplasty for keratoconus in 3 eyes of two patients under 40 years of age.<sup>6</sup> The authors proposed coincident occurrence, non-specific reaction to surgery or to postoperative medications, immunogenic reaction to donor tissue, or a potentially transmissible disease as possible explanations for the condition.<sup>6</sup> We believe that surgical trauma in genetically predisposed patients would be an alternative explanation for the condition in their cases.

Konstas and associates reported exfoliation syndrome in a 17-year-old girl who was a case of unilateral primary congenital glaucoma with history of trabeculectomy and large peripheral iridectomies during early infancy.<sup>7</sup> Clinical and histological examination performed at the age of 17 years revealed classic findings of exfoliation. The authors attributed the early presentation of exfoliation to iris surgery early in life.<sup>7,37</sup>

Yuksel and associates reported a 13-year-old girl with presumed PXF six years after extracapsular cataract extraction and posterior chamber intraocular lens implantation.<sup>8</sup> This is the youngest patient reported in the literature and shares surgical trauma as a probable predisposing factor in the pathogenesis of the condition.

In the current study, for the first time in the literature, we report a series of four patients with early-onset PXF following multiple intraocular operations. This could be noteworthy regarding the possible role of surgical trauma in triggering the exfoliation cascade in genetically predisposed individuals. We recommend careful examination of the anterior segment in young patients who have a history of intraocular surgery for early detection of PXF ophthalmic manifestations. This would be particularly important in patients with a family history of PXF glaucoma.

#### Conflicts of Interest

None.

REFERENCES

1. Tarkkanen A, Kivela T, John G, Lindberg and the discovery of exfoliation syndrome. *Acta Ophthalmol Scand* 2002;80:151-154.
2. Ritch R, Schlötzer-Schrehardt U. Exfoliation syndrome. *Surv Ophthalmol* 2001;45:265-315.
3. Shingleton BJ, Crandall AS, Ahmed II. Pseudoexfoliation and the cataract surgeon: preoperative, intraoperative, and postoperative issues related to intraocular pressure, cataract, and intraocular lenses. *J Cataract Refract Surg* 2009;35:1101-1120.
4. Belovay GW, Varma DK, Ahmed II. Cataract surgery in pseudoexfoliation syndrome. *Curr Opin Ophthalmol* 2010;21:25-34.
5. Challa P. Genetics of pseudoexfoliation syndrome. *Curr Opin Ophthalmol* 2009;20:88-91.
6. Kuchle M, Naumann GO. Occurrence of pseudoexfoliation following penetrating keratoplasty for keratoconus. *Br J Ophthalmol* 1992;76:98-100.
7. Konstas AG, Ritch R, Bufidis T, Morales J, Qi Y, Streeten BW. Exfoliation syndrome in a 17-year-old girl. *Arch Ophthalmol* 1997;115:1063-1067.
8. Yüksel B, Schlötzer-Schrehardt U, Pehlivan O, Topaloglu E. A 13-year-old girl with presumed pseudoexfoliation. *Acta Ophthalmol Scand* 2005;83:626-627.
9. Forsius H. Exfoliation syndrome in various ethnic populations. *Acta Ophthalmol Suppl* 1988;184:71-85.
10. Lantukh VV, Piatin MM. Features of ocular pathology among the indigenous inhabitants of Chukotka. *Vestn Oftalmol* 1982;4:18-20.
11. Forsius H. Prevalence of pseudoexfoliation of the lens in Finns, Lapps, Icelanders, Eskimos, and Russians. *Trans Ophthalmol Soc U K* 1979;99:296-298.
12. Al-Shaer M, Bamashmus M, Al-Barrag A. Point prevalence of pseudoexfoliation syndrome in patients scheduled for cataract surgery in eye camps in Yemen. *Middle East Afr J Ophthalmol* 2010;17:74-77.
13. Nouri-Mahdavi K, Nosrat N, Sahebghalam R, Jahanmard M. Pseudoexfoliation syndrome in central Iran: a population-based survey. *Acta Ophthalmol Scand* 1999;77:581-584.
14. Faulkner HW. Pseudo-exfoliation of the lens among the Navajo Indians. *Am J Ophthalmol* 1971;72:206-207.
15. Desai MA, Moon CS, Bretana ME, Ehliès F, Winnick M, Lee RK. Pupillary block glaucoma secondary to phacodonesis in pseudoexfoliation. *Ophthalmic Surg Lasers Imaging* 2010;9:1-7.
16. Krause U. Frequency of capsular glaucoma in central Finland. *Acta Ophthalmol (Copenh)* 1973;51:235-240.
17. Henry JC, Krupin T, Schmitt M, Lauffer J, Miller E, Ewing MQ, et al. Long-term follow-up of pseudoexfoliation and the development of elevated intraocular pressure. *Ophthalmology* 1987;94:545-552.
18. Slagvold JE. The follow-up in patients with pseudoexfoliation of the lens capsule with and without glaucoma. 2. The development of glaucoma in persons with pseudoexfoliation. *Acta Ophthalmol (Copenh)* 1986;64:241-245.
19. Schlötzer-Schrehardt U, Kuchle M, Naumann GO. Electron-microscopic identification of pseudoexfoliation material in extrabulbar tissue. *Arch Ophthalmol* 1991;109:565-570.
20. Lucero HA, Kagan HM. Lysyl oxidase: an oxidative enzyme and effector of cell function. *Cell Mol Life Sci* 2006;63:2304-2316.
21. Liu X, Zhao Y, Gao J, Pawlyk B, Starcher B, Spencer JA, et al. Elastic fiber homeostasis requires lysyl oxidase-like 1 protein. *Nat Genet* 2004;36:178-182.
22. Shrum KR, Hattenhauer MG, Hodge D. Cardiovascular and cerebrovascular mortality associated with ocular pseudoexfoliation. *Am J Ophthalmol* 2000;129:83-86.
23. Detorakis ET, Chrysochoou F, Paliobei V, Konstas AG, Daniilidis V, Balatsouras D, et al. Evaluation of the acoustic function in pseudoexfoliation syndrome and exfoliation glaucoma: audiometric and tympanometric findings. *Eur J Ophthalmol* 2008;18:71-76.
24. Papadopoulos TA, Naxakis SS, Charalabopoulou M, Vathylakis I, Goumas PD, Gartaganis SP. Exfoliation syndrome related to sensorineural hearing loss. *Clin Experiment Ophthalmol* 2010;38:456-461.
25. Behmoaras J, Slove S, Seve S, Vranckx R, Sommer P, Jacob MP. Differential expression of lysyl oxidases LOXL1 and LOX during growth and aging suggests specific roles in elastin and collagen fiber remodeling in rat aorta. *Rejuvenation Res* 2008;11:883-889.
26. Ringvold A, Blika S, Elsas T, Guldahl J, Brevik T, Hesstvedt P, et al. The Middle-Norway eye-screening study. I. Epidemiology of the pseudoexfoliation syndrome. *Acta Ophthalmol (Copenh)* 1988;66:652-658.
27. Klouman OF. Pseudoexfoliation in ophthalmic practice. *Acta Ophthalmol (Copenh)* 1967;45:822-828.
28. Khan TT, Li G, Navarro ID, Kastury RD, Zeil CJ, Semchyshyn TM, et al. LOXL1 expression in lens capsule tissue specimens from individuals with pseudoexfoliation syndrome and glaucoma. *Mol Vis*

- 2010;16:2236-2241.
29. Yamamoto N, Miyagawa A. True exfoliation of the lens capsule following uveitis. *Graefes Arch Clin Exp Ophthalmol* 2000;238:1009-1010.
30. Karp CL, Fazio JR, Culbertson WW, Green WR. True exfoliation of the lens capsule. *Arch Ophthalmol* 1999;117:1078-1080.
31. Brodrick JD, Tate GW Jr. Capsular delamination (true exfoliation) of the lens. Report of a case. *Arch Ophthalmol* 1979;97:1693-1698.
32. Burde RM, Bresnick G, Uhrhammer J. True exfoliation of the lens capsule. An electron microscope study. *Arch Ophthalmol* 1969;82:651-653.
33. Callahan A, Klien BA. Thermal detachment of the anterior lamella of the anterior lens capsule; a clinical and histopathologic study. *AMA Arch Ophthalmol* 1958;59:73-80.
34. Cumurcu T, Ozyurt H, Demir HD, Yardim H. Serum alpha-1-antitrypsin levels in patients with pseudoexfoliative syndrome. *Curr Eye Res* 2008;33:159-162.
35. Yüksel N, Pirhan D, Altıntaş O, Çağlar Y. Systemic high-sensitivity C-reactive protein level in pseudoexfoliation syndrome and pseudoexfoliation glaucoma. *J Glaucoma* 2010;19:373-376.
36. Cumurcu T, Gunduz A, Ozyurt H, Nurcin H, Atis O, Egri M. Increased oxidative stress in patients with pseudoexfoliation syndrome. *Ophthalmic Res* 2010;43:169-172.
37. Konstas AG, Williamson TH. Co-existence of exfoliation syndrome, previous iris surgery, and heterochromia. *Acta Ophthalmol (Copenh)* 1993;71:850-852.