

Isolated blunt abdominal aortic injury without concomitant abdominal injuries treated with endovascular stent grafting

Monica N. Khattak, Eric V. Olivero, MD, Michael A. Curi, MD, Ajay K. Dhadwal, MBBS, Frank T. Padberg Jr, MD, and Joe T. Huang, MD, Newark, NJ

Blunt injury of the abdominal aorta is a rare event, seen in only 0.07% to 0.17% of all blunt traumas. These injuries are frequently associated with other intra-abdominal injuries, with high rates of morbidity and mortality. We present a case of isolated blunt abdominal aortic trauma to the infrarenal aorta without concomitant abdominal or spinal injuries. The patient was treated with endovascular aortic stent grafting and is without complications 12 months after the procedure. (*J Vasc Surg Cases* 2015;1:258-60.)

Blunt abdominal aortic injuries are rare, accounting for only 5% of all blunt aortic injuries¹ and only 0.7% to 0.17% of all blunt traumas.^{1,2} These patients typically present with concomitant intra-abdominal injuries, with high morbidity and mortality rates. We present a case of isolated blunt abdominal aortic trauma, without associated abdominal or spinal injuries, successfully treated with endovascular stent grafting. The patient's consent was obtained before publication.

CASE REPORT

A 53-year-old male, unrestrained driver presented to the trauma bay after suffering a high-speed, head-on motor vehicle collision. On arrival, his blood pressure was 80/20 mm Hg; heart rate was 126 beats/min. Physical examination was significant for a tender, distended abdomen with no signs of seat belt markings. Computed tomography (CT) scan demonstrated active extravasation from the infrarenal aorta with surrounding retroperitoneal hematoma (Fig 1). No associated abdominal or spinal injuries were identified. Other injuries included bilateral rib fractures, pulmonary contusions, a left ulnar fracture, and a right tibia fracture. The patient was brought emergently to the operating room and treated with two proximal aortic cuffs (Zenith; Cook Inc, Bloomington, Ind) spanning the infrarenal aorta. A 24 × 58-mm cuff was placed distally, and a 24 × 39-mm cuff was placed proximally. The inferior mesenteric artery was intentionally covered. The

patient tolerated the procedure well, and the extremity fractures were subsequently treated by an orthopedic surgeon. A follow-up CT scan within 24 hours demonstrated resolution of the extravasation and hematoma (Fig 2). The patient's surgical intensive care unit course was complicated by gram-positive sepsis, pneumonia, and respiratory failure with subsequent tracheostomy. The patient was discharged 15 days after the initial operation in ambulatory condition. One year later, the patient is without clinical sequelae, and a follow-up CT scan (Fig 3) demonstrates a normal aorta and stable graft configuration.

DISCUSSION

Whereas blunt abdominal aortic injuries are rare, accounting for 0.07% to 0.17% of all blunt traumas, isolated blunt abdominal aortic injuries, without concomitant abdominal or spinal injuries, are even rarer and seen in only 0.045% of all blunt traumas.^{1,2} However, this injury carries high prehospital (>75%) and in-hospital (32%) mortality rates.^{1,3,4} During the past 30 years, fewer than 500 cases of blunt abdominal aortic injury have been reported in the literature.^{2,4-13}

The mechanism of injury is due to the direct and indirect forces on the abdominal aorta. The aorta at this level is tethered by visceral and lumbar arteries as well as by other attachments to the spinal column and peritoneum. When sudden deceleration occurs, as in motor vehicle crashes, direct forces compress the aorta against the spinal column while indirect forces from deceleration act on a tethered aorta, both resulting in aortic injury. Given the severity of the forces needed to sustain blunt abdominal aortic injury, it frequently is manifested alongside other major abdominal injuries, including injuries to the spleen (22%), liver (20%), and bowel (19%). Lumbar spine fractures (26%) and pelvic fractures (25%) also represent a significant component of the associated injuries.²

Management of blunt abdominal aortic injuries is determined by the severity and location of the injury. According to the classification system by Starnes et al,⁵ injuries to the aorta are classified in increasing severity: intimal tears (<10 mm in length or width), large intimal

From the Division of Vascular Surgery, Rutgers New Jersey Medical School. Author conflict of interest: none.

Presented at the Thirty-sixth Annual Vascular Society of New Jersey Scientific Meeting, Belleville, NJ, March 12, 2014.

Correspondence: Monica N. Khattak, Division of Vascular Surgery, New Jersey Medical School, 150 Bergen St, Newark, NJ 07103 (e-mail: mnk8@njit.edu).

The editors and reviewers of this article have no relevant financial relationships to disclose per the Journal policy that requires reviewers to decline review of any manuscript for which they may have a conflict of interest.

2352-667X

Published by Elsevier Inc. on behalf of the Society for Vascular Surgery.

This is an open access article under the CC BY-NC-ND license (<http://creativecommons.org/licenses/by-nc-nd/4.0/>).

<http://dx.doi.org/10.1016/j.jvsc.2015.08.001>

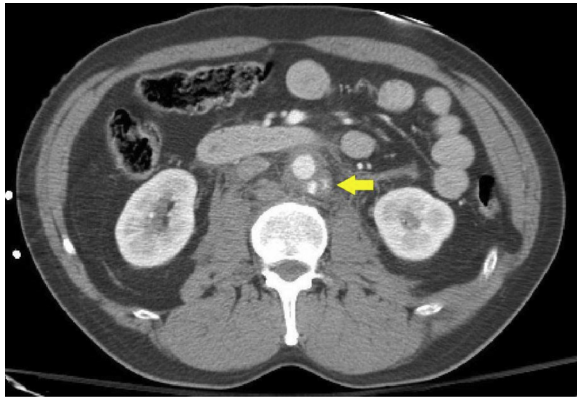


Fig 1. Computed tomography (CT) scan of infrarenal aorta with pseudoaneurysm. The *arrow* denotes pseudoaneurysm.

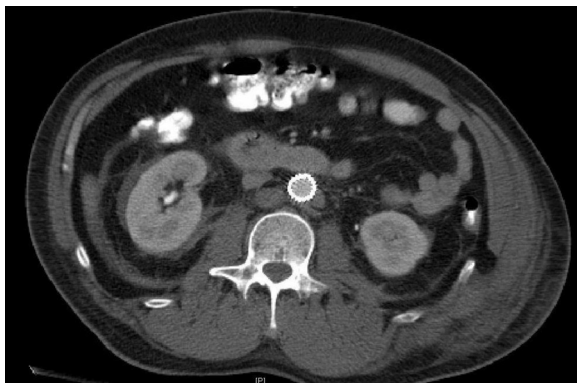


Fig 2. Postprocedure computed tomography (CT) scan with stent graft in place demonstrating resolution of extravasation.

flaps (≥ 10 mm without external contour abnormalities), pseudoaneurysms, and free ruptures. Intimal tears and uncomplicated large intimal flaps can be managed nonoperatively with blood pressure control and antiplatelet agents. Complicated large intimal flaps and pseudoaneurysms can be treated through open or endovascular repair, depending on location. Ruptures are commonly repaired through open techniques.

Blunt aortic injuries are additionally classified by location of injury. Zone I injuries are located between the diaphragmatic hiatus and superior mesenteric artery (SMA). Zone II injuries are between the SMA and the renal arteries. Zone III injuries are inferior to the renal arteries. Zone I and zone III injuries can be repaired with endovascular techniques, but zone II injuries typically require an open repair because of the proximity to the SMA and renal arteries.¹ Zone III injuries account for the majority of blunt abdominal aortic injuries ($>70\%$).^{1,2}

Our patient presented with a pseudoaneurysm located in zone III. We chose an endovascular approach using two proximal aortic cuffs because this combination of cuffs was readily available and best spanned the infrarenal aorta.

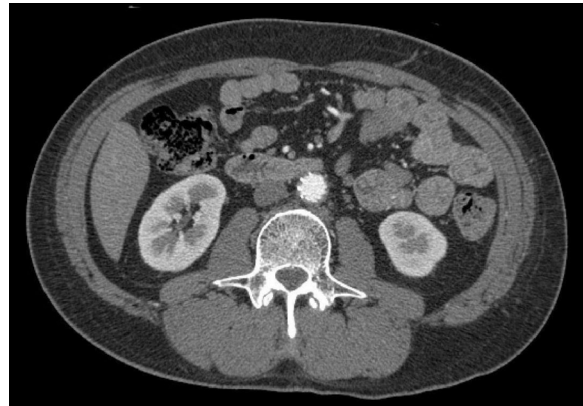


Fig 3. The 3-month follow-up computed tomography (CT) scan with stable configuration of stent graft and resolution of surrounding hematoma.

Similarly, the University of Washington group also successfully treated four of nine patients with endovascular techniques using aortic cuffs.¹

Bifurcated endografts are another option for endovascular repair. Open repairs for blunt abdominal aortic injury may include flap suture, endarterectomy, aortic interposition grafting, and open ligation with extra-anatomic bypass.² The choice of repair takes into consideration the severity of the aortic injury, location of the injury, aortic anatomy, subsequent traumatic abdominal injuries, and time of diagnosis.

CONCLUSIONS

An isolated blunt abdominal aortic injury without concomitant abdominal or spinal injuries, as reported here, is an extremely rare event. Furthermore, we demonstrate that repair for this type of injury with endovascular stent grafting is feasible and durable.

REFERENCES

1. Shalhub S, Starnes BW, Tran NT, Hatsukami TS, Lundgren RS, Davis CW, et al. Blunt abdominal aortic injury. *J Vasc Surg* 2012;55:1277-85.
2. de Mestral C, Dueck AD, Gomez D, Haas B, Nathens AB. Associated injuries, management, and outcomes of blunt abdominal aortic injury. *J Vasc Surg* 2012;56:656-60.
3. Osgood MJ, Heck JM, Rellinger EJ, Doran SL, Garrard CL III, Guzman RJ, et al. Natural history of grade I-II blunt traumatic aortic injury. *J Vasc Surg* 2014;59:334-42.
4. Harris DG, Drucker CB, Brenner ML, Sarkar R, Narayan M, Crawford RS. Patterns and management of blunt abdominal aortic injury. *Ann Vasc Surg* 2013;27:1074-80.
5. Starnes BW, Lundgren RS, Gun M, Quade S, Hatsukami TS, Tran NT, et al. A new classification scheme for treating blunt aortic injury. *J Vasc Surg* 2012;55:47-54.
6. Lalancette M, Scalabrini B, Martinet O. Seat-belt aorta: a rare injury associated with blunt abdominal trauma. *Ann Vasc Surg* 2006;20:681-3.
7. Mellnick VM, McDowell C, Lubner M, Bhalla S, Menias CO. CT features of blunt abdominal aortic injury. *Emerg Radiol* 2012;19:301-7.

8. Naude GP, Back M, Perry MO, Bongard FS. Blunt disruption of the abdominal aorta: report of a case and review of the literature. *J Vasc Surg* 1997;25:931-5.
9. Godry H, Rölleke G, Mumme A, Schildhauer TA, Gothner M. Traumatic infra-renal aortic dissection after a high-energy trauma: a case report of a primary missed diagnosis. *Orthop Rev (Pavia)* 2014;6:5031-3.
10. Azizzadeh A, Keyhani K, Miller CC III, Coogan SM, Safi HJ, Estrera AL. Blunt traumatic aortic injury: initial experience with endovascular repair. *J Vasc Surg* 2009;49:1403-8.
11. Watson J, Slaiby J, Garcia MT, Marcaccio EJ, Chong TT. A 14-year experience with blunt thoracic aortic injury. *J Vasc Surg* 2013;58:380-5.
12. Halkos ME, Nicholas J, Kong LS, Burke JR, Milner R. Endovascular management of blunt abdominal aortic injury. *Vascular* 2006;14:223-6.
13. Tobler WD, Tan TW, Farber A. Endovascular repair of a blunt abdominal aortic injury. *Int J Angiol* 2012;21:117.

Submitted Jun 21, 2015; accepted Aug 17, 2015.